

Oncogenic osteomalacia

J McCLURE, P S SMITH*

*From the Department of Pathology, University of Manchester, and the *Division of Tissue Pathology, Institute of Medical and Veterinary Science, Adelaide, South Australia*

SUMMARY Severe osteomalacia (confirmed by the examination of thin undecalcified bone biopsy sections) associated with hypophosphataemia developed in a 60 year old woman. A skeletal x-ray survey showed a lytic lesion in the right proximal femur, and this was curetted, showing a vascular tumour. The patient's symptoms improved almost immediately and serum phosphate concentrations returned to normal. Some time later the syndrome and the tumour recurred. The tumour was excised, and again the patient improved. Morphological examination of the tumour showed a lesion which closely resembled haemangiopericytoma. Review of published reports confirmed that most reported cases have been associated with "vascular" mesenchymal tumours both in intraosseous and extraosseous sites.

Throughout the world the most common cause of the osteomalacia and rickets syndrome is vitamin D deficiency due to dietary deprivation. There are, however, several other causes of the syndrome, which, although not necessarily common, are important: their recognition may lead to effective treatment; and an understanding of their pathogenetic mechanisms may give important insights into the processes of bone mineralisation. One such example is provided by the phenomenon of oncogenic osteomalacia. This seems to be a genuinely rare syndrome, in which osteomalacia is seen in association with a mesenchymal tumour (either intraosseous or extraosseous), and the osteomalacia heals when the tumour is removed. Concomitant hypophosphataemia commonly occurs.

Recently we had the opportunity of studying tumour and bone tissue from such a case and used light microscopical, ultrastructural, and undecalcified histological techniques to characterise the morphological features of the syndrome, which are detailed in this paper.

Case report

A 60 year old woman presented with increasing pain in both thighs associated with weakness, over two years. Latterly she developed increasing pain in both knees and ankles. She had been confined to a wheel

chair for 18 months. There was no history of excess antacid ingestion or nutritional deficiency. There was no family history of bone disease.

Clinical examination showed a severe weakness in all pelvic girdle muscles. There was mild weakness of the shoulder girdle muscles. All lower limb movements were limited by pain. There was no wasting, diminution of reflexes, or impairment of sensation.

Serum calcium concentration was at 2.24 mmol/l (normal range 2.20-2.60) but serum phosphate concentration at 0.40 mmol/l (normal range 0.80-1.30) and that of serum 25 hydroxycholecalciferol at 36 IU/l (normal range 40-160) were both low. Urinary calcium and phosphate concentrations were normal. The serum alkaline phosphatase activity (1326 IU/l, normal range 0-110) and the serum parathormone activity (7.8 IU/l, normal range 2.0-6.0) were raised. Continuing investigations showed a persistently low serum phosphate concentration coupled with normal serum calcium concentrations, high normal urinary calcium excretion, and low normal urinary phosphate excretion. This suggested a low tubular phosphate reabsorption. There was a low oral calcium absorption and a very high urinary hydroxyproline:creatinine ratio.

Oncogenic hypophosphataemic osteomalacia was presumptively diagnosed. A skeletal x-ray survey showed a lytic lesion in the right upper femur (fig 1). An operation was performed at which the femoral lesion was curetted, a bone biopsy was taken from the left anterior iliac crest for undecalcified histological study, and a muscle biopsy as taken from the right quadriceps femoris muscle. Postoperatively her serum

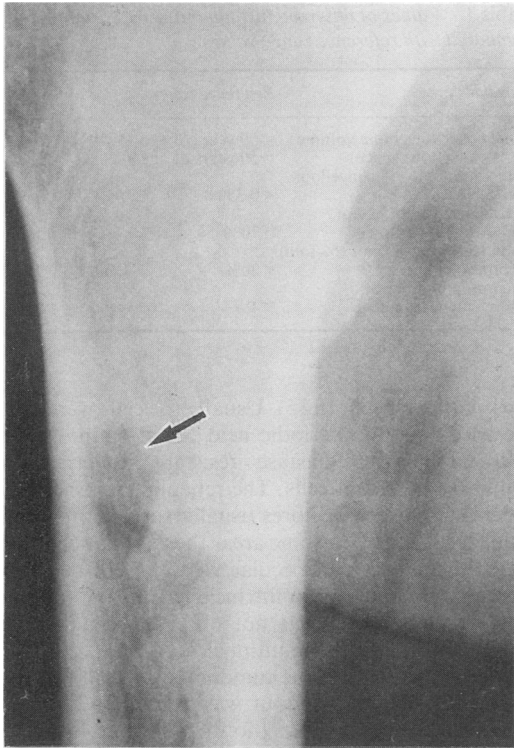


Fig 1 Radiograph of proximal femur. Lytic focus caused by intraosseous tumour is arrowed.

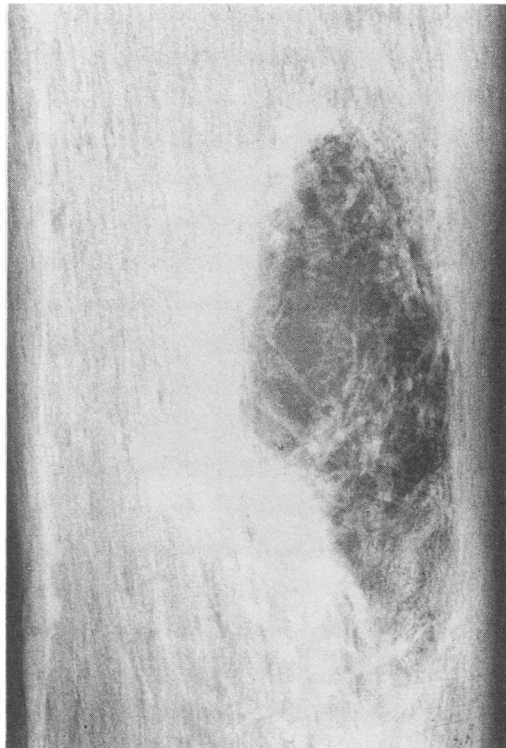

Fig 2 Contact radiograph of en bloc excision specimen showing recrudescence of tumour.

phosphate concentrations began to rise, urinary excretion fell, and the calcium absorption increased. She became mobilised and was able to walk. Her further improvement was complicated by pulmonary embolism for which she was successfully treated.

Nine months later her serum phosphate concentrations began to fall again and x-ray of the right upper femur showed a recrudescence of the lytic lesion. This area was excised en bloc (fig 2). After operation the serum phosphate concentration again returned to normal and she remains well at the time of writing.

Pathological findings

The bone biopsy specimen from the left iliac crest was fixed in buffered formalin containing a 1% solution of tetracycline for 48 hours.¹ Multiple, thin ($7\ \mu\text{m}$), undecalcified sections were cut after embedding in araldite. Sections were stained by the von Kossa technique with either the van Gieson method or haematoxylin and eosin as counter stains (fig 3). Using the van Gieson counterstained sections the total can-

cellous bone volume and the osteoid volume were estimated using a Quantimet 720 image analysis computer. The calcification fronts were shown by ultraviolet light fluorescence and their extent expressed as a percentage of the osteoid seams bearing a front. Total resorbing surfaces were estimated as the sum of the percentages of the trabecular surface occupied by either active (with an osteoclast) or inactive (without an osteoclast) resorption sites. An estimate of the thickness of the osteoid seams was obtained by counting the number of birefringent lamellae seen in polarised light and noting the maximum number.

Table 1 shows the results of these quantitative estimations. These show severe hyperosteoidosis with a severely reduced calcification front extent confirming the presence of severe osteomalacia.

The muscle biopsy specimen showed features consistent with a metabolic myopathy.

The curettings from the femoral lesion confirmed the presence of a tumour. This had a prominent vascular pattern composed largely (but not exclusively) of thin walled channels (fig 4). The intervening cellular proliferations were composed of round to oval

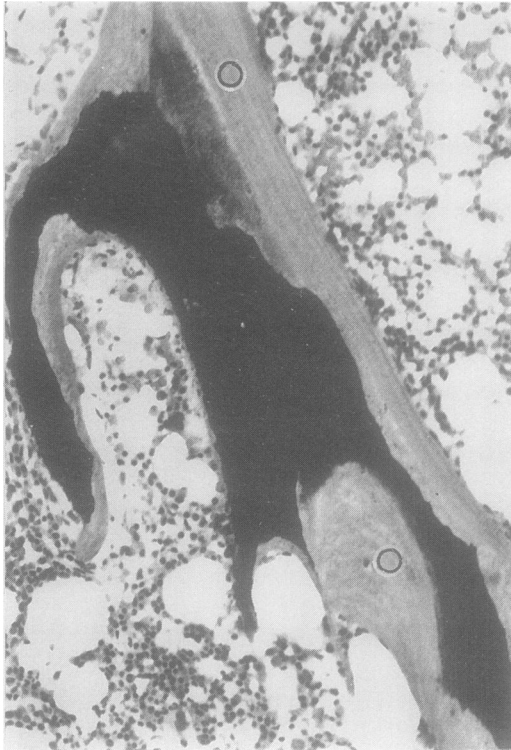

Fig 3 Undecalcified section of iliac bone. Mineralised zone (black) is greatly reduced in extent and osteoid (○) is prominent. (von Kossa, haematoxylin and eosin.) $\times 100$.

Table 1 Values of observed histoquantitative variables compared with reference range values

Variable	Reference range	Value
Total cancellous bone volume (% cancellous space)	< 50 years of age 15–29% > 50 years of age 9–20%	15.4
Osteoid volume (% cancellous space)	< 0.3%	9.5
Calcification front extent (% osteoid surface)	> 70%	15.4
Total resorbing surface (% total trabecular surface)	< 20%	9
Maximum number of birefringent lamellae	< 4	6

fairly compact cells (fig 5). Usually the cells were quite crowded, but the periodic acid Schiff stain showed thin laminae of diastase resistant material surrounding groups of cells. The reticulin stains showed a delicate pattern of fibres usually surrounding individual cells (fig 6). In some areas the vascular channels were dilated. Bone trabeculae were present but these were mature and not an intrinsic part of the tumour. Osteoid elaboration was not observed. Small numbers of osteoclast like, multinucleated giant cells were scattered throughout the tumour.

The recrudescence tumour was excised en bloc and again there was a lytic (now somewhat loculated lesion). Histologically this was identical with the initial lesion.

Material from each specimen was fixed in glutaraldehyde, then fixed in osmium tetroxide and pro-

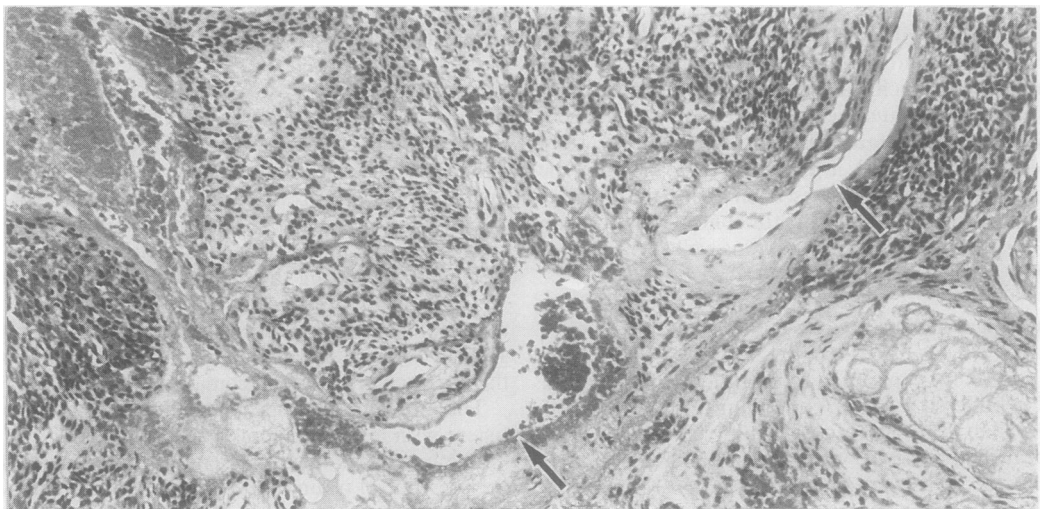


Fig 4 Photomicrograph of original tumour. Specimen obtained by curettage. Larger peripheral blood vessels are arrowed. (Haematoxylin and eosin.) $\times 100$.

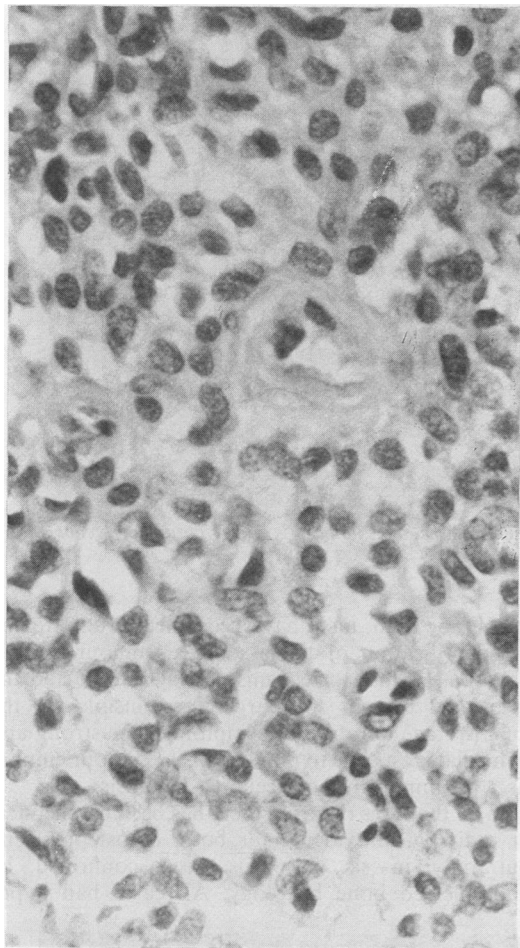


Fig 5 Perivascular disposition of tumour cells in recrudescence lesion. (Haematoxylin and eosin.) $\times 100$.

cessed into Spurr's resin for ultrastructural study. This showed mainly spindle shaped cells scattered loosely through an amorphous stroma (fig 7). There were many thin walled blood vessels with surrounding cells which intermingled with vessel basement membranes (fig 8). The cytoplasmic outlines were irregular with many fine cell processes. There was a discontinuous external lamina around the outside of most cells (fig 9) and this seemed to resemble the amorphous stromal material, although this was less organised. Collagen was not seen. Cell nuclei were unremarkable. The cytoplasm contained fair numbers of rather large vesicles with thick limiting membranes (fig 10). These were concentrated beneath the plasma membrane and many seemed to be fused with the membrane. In places there were thin dense areas beneath the plasma membrane, especially in the cell processes. Junctional complexes were not observed, although in places plasma membranes were closely apposed.

Discussion

Undecalcified bone histology showed that the patient had a severe osteomalacia, due to hypophosphataemia. The association with an intraosseous tumour whose excision improved the biochemical and clinical abnormalities of the case indicates that this was an example of the oncogenic hypophosphataemic osteomalacia syndrome. The essential feature is that either an intraosseous or extraosseous tumour exerts an influence whereby serum, and, presumably, extracellular fluid phosphate, is depleted. This results in diminished calcification either at the calcification front in adult bone or in hypertrophic cartilage in the epiphyseal plate, thereby causing either osteomalacia or rickets depending on the age of the subject.

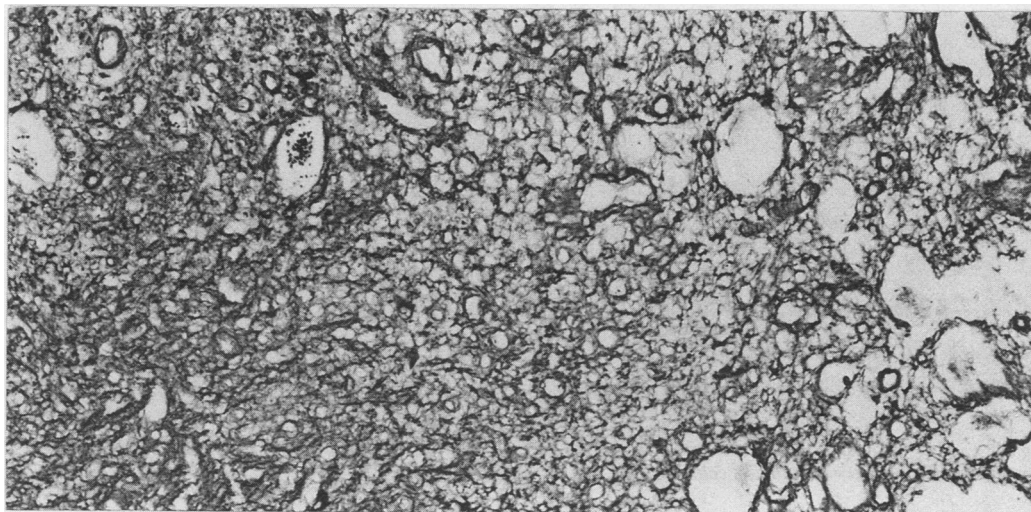


Fig 6 Reticulin pattern of excision specimen. $\times 100$.

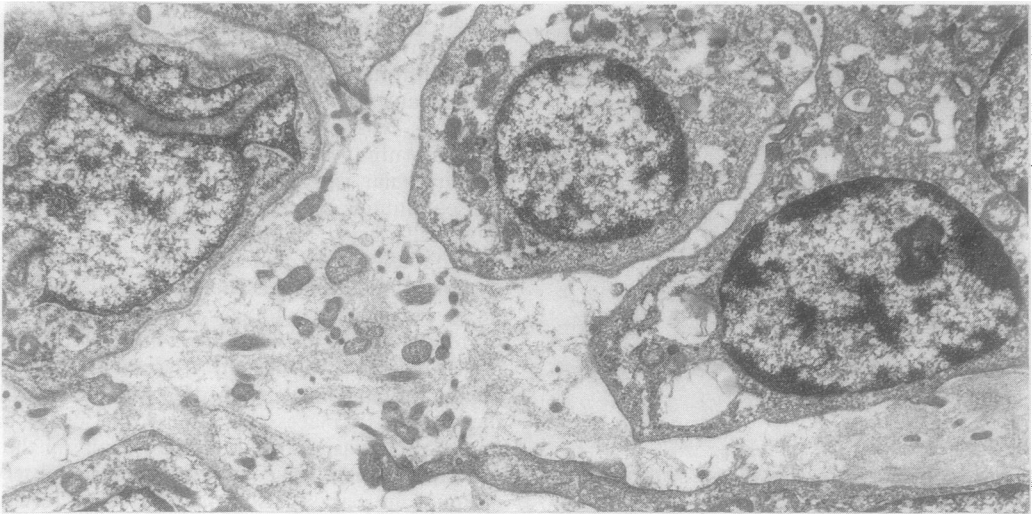


Fig 7 *Electron micrograph of cellular focus in excision specimen. Intercellular material is like glycosaminoglycans. \times 6500.*

That oncogenic hypophosphataemic osteomalacia is an unusual syndrome is illustrated by the fact that only 22 cases have been described. These comprise 12 males and 10 females with a mean age of 37 years (range 9–58). The average duration of symptoms is known from 12 cases and is an astonishingly long 5.28 years (range 0.6–17). Many of the patients were severely incapacitated by their osteomalacia and associated myopathy, being wheelchair-bound or bedridden. Although some cases have been controlled symptomatically by high doses of phosphate or vita-

min D, or both, most have been successfully treated by identification of the associated tumour and its ablation. Failure to recognise the syndrome and the associated tumour was largely responsible for the long average duration of symptoms. The strong and immediate response to removal of the tumour emphasises the importance of accurate diagnosis.

In all the cases reported there has been biochemical or radiological evidence, or both, of osteomalacia, but only in six has this been confirmed by undecalcified bone histology. All cases had hypo-

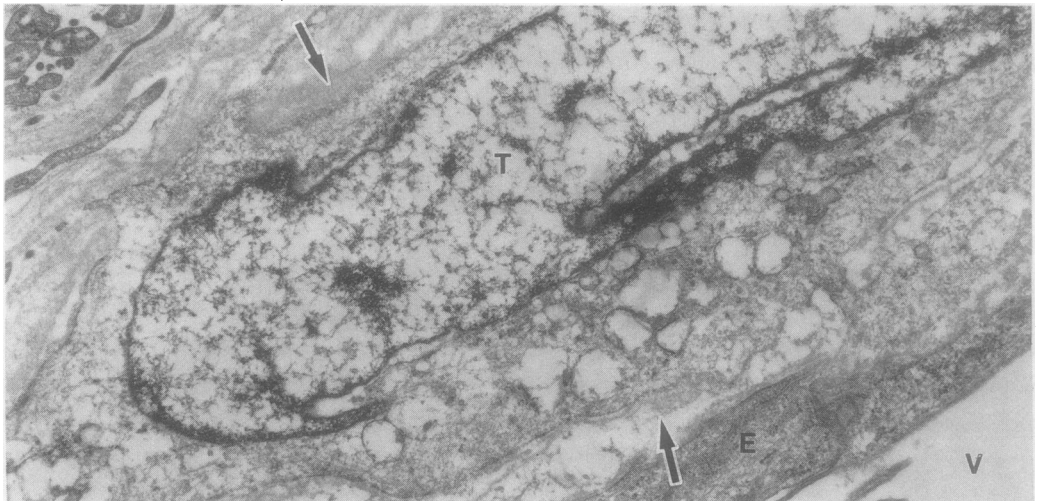


Fig 8 *Tumour cell (T) in close proximity to blood vessel, surrounded by vessel basement membrane (arrowed). V = blood vessel lumen; E = endothelial cells. \times 6500.*

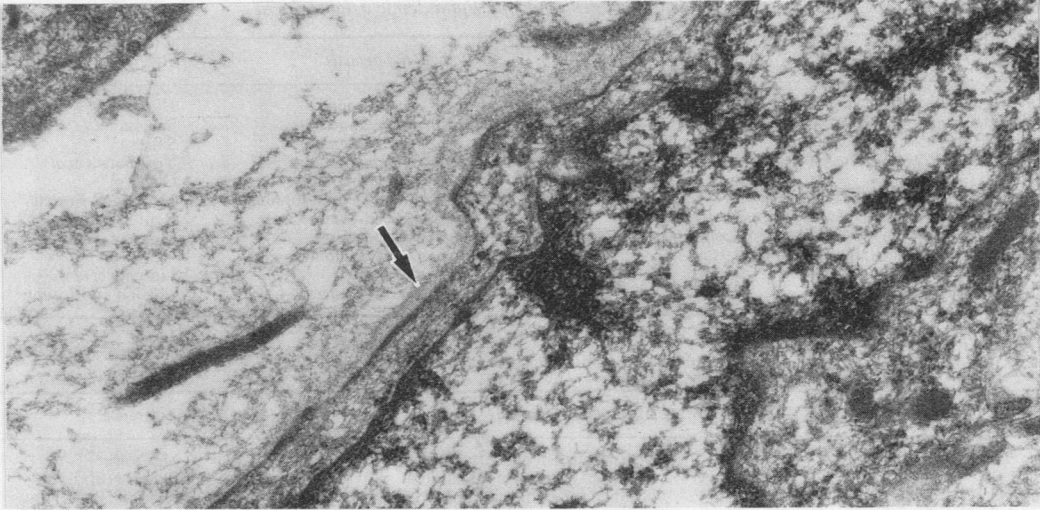


Fig9 Discontinuous external lamina surrounding tumour cell is arrowed. $\times 19\,500$.

phosphataemia and 18 had hyperphosphaturia. Serum calcium concentrations were measured in 14 instances and were uniformly normal. Glycouria was observed in three cases and a low serum $1\text{-}\alpha\text{-}25\text{-dihydroxycholecalciferol}$ concentration noted in one. Our patient had normal serum calcium concentrations but persistently low serum phosphate values. There was a low normal phosphate excretion, indicating a low tubular phosphate reabsorption. In addition there was a low serum $25\text{-hydroxycholecalciferol}$ concentration.

It is evidently important to consider the sites and nature of the associated tumours. These were either

extraosseous or intraosseous in location. Table 2 shows the location of the extraosseous lesions and table 3 that of intraosseous. McCance² reported the earliest case, and this does not seem to have been recognised as a true neoplasm. Table 4 gives a compilation of the various histological diagnoses applied to these lesions. Haemangiopericytoma is the most common diagnostic label. Evans and Azzopardi³ had the opportunity of examining the slides from several of the then reported cases and concluded that the tumours were a unitary entity, perhaps a variant of haemangiopericytoma. Considering the other histopathological labels that have been applied, several

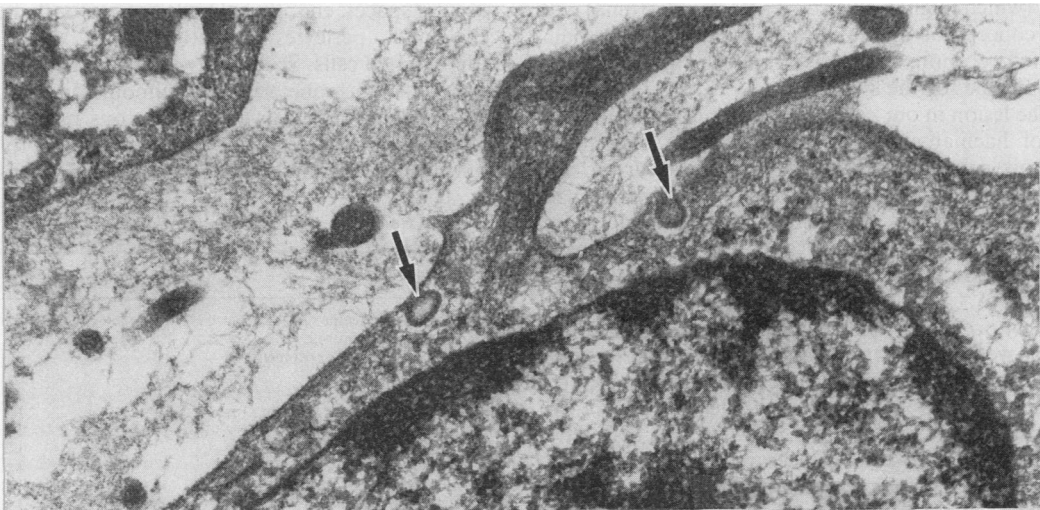


Fig 10 Intracytoplasmic sublamellar vesicles are arrowed. $\times 26\,000$.

Table 2 *Extraosseous tumours associated with oncogenic hypophosphataemic osteomalacia*

Site and gross appearances	Histological diagnosis	Reference
Left axilla and left infraclavicular area affecting scapula	Malignant neurinoma	Hauge ¹⁵
Left groin hard mass (30 × 40 mm)	Sclerosing haemangioma	Salassa ¹⁶
Medial aspect right thigh just above knee in soft tissue	Sclerosing haemangioma	Salassa ¹⁶
Behind left knee in soft tissues (40 × 25 mm)	Cavernous haemangioma	Yoshikawa <i>et al</i> ¹⁷
Pharynx	Ossifying mesenchymal tumour	Olefsky ¹⁸
Subcutaneous lump in dorsal surface of right great toe (10 × 10 cm)	Ossifying mesenchymal tumour	Moser and Fessell ¹⁹
Mass in anterior abdominal wall (100 mm in diameter)	Haemangiopericytoma	Renton and Shaw ²⁰
Mass in soft tissues below right medial malleolus (60 × 40 mm)	Haemangiopericytoma	Linovitz <i>et al</i> ¹¹
Soft tissue mass over medial aspect of right knee	Sclerosing haemangioma-angiosarcoma	Linovitz <i>et al</i> ¹¹
Tumour in left nostril	Haemangiopericytoma	Chacko and Joseph ²¹

Table 3 *Intraosseous tumours associated with oncogenic hypophosphataemic osteomalacia*

Site	Histological diagnosis	Reference
Lower end of right femur	Degenerate osteoid with trabecular structure	McCance ²
Rib	Giant cell reparative granuloma	Prader <i>et al</i> ²²
Upper end of left femur affecting the hip joint	? Malignant giant cell tumour of bone	Krane ²³
Upper end of left femur	Distinctive mesenchymal tumour; variant of haemangiopericytoma	Evans and Azzopardi ³
Right radius	Non-ossifying fibroma	Pollack <i>et al</i> ²⁴
Right distal ulna	Benign ossifying mesenchymal tumour	Willhoite ²⁵
Ethmoid bone	Haemangiopericytoma	Renton and Shaw ²⁰
Right iliac bone	Fibroblastic proliferation and numerous multinucleated giant cells	Drezner and Feinglos ¹⁴
Fourth metacarpal	Osteoblastoma	Yoshikawa <i>et al</i> ⁴
Upper one third shaft of humerus	Osteoblastoma	Yoshikawa <i>et al</i> ⁴
Multiple lytic lesions of skull, pelvis, and ribs	Haemangiomas of bone	Daniels and Weisenfeld ²⁶
Mandible	Giant cell tumour	Nitzan <i>et al</i> ²⁷

could certainly have been haemangiopericytoma, the essential nature of the lesion being obscured by other features such as osteoid formation and giant cell aggregation. It is difficult, however, to reconcile the osteoblastomas described by Yoshikawa *et al*⁴ and McCance's degenerate osteoid with trabecular structure (which might well also be an osteoblastoma) with the concept of an obscured haemangiopericytoma. Therefore more than one tumour type may be responsible for the syndrome.

The lesion in our case conforms well to the diagnosis of haemangiopericytoma. This is an uncommon tumour, originally defined by Stout and Murray⁵ and usually affecting soft tissues.^{6,7} Primary haemangiopericytoma of bone is exceptionally rare. Stout⁸ noted two in a series of 197. Marcial-Rojas⁹ described a case with metastases. Wold *et al*¹⁰ from the Mayo Clinic reported their experience with 15 cases. Formation of osteoid and giant cell accumulation were not described as a feature of these cases. Only one of the Mayo Clinic series was associated with hypophosphataemic osteomalacia. An important point made by Wold *et al* was that other tumours such as osteogenic sarcoma, synovial sarcoma, mesenchymal chondrosarcoma and malignant fibrous histiocytoma may have areas that closely resemble haemangiopericytoma, and adequate sam-

pling is therefore necessary to ensure accurate diagnosis.

Evans and Azzopardi stated that they performed ultrastructural studies in their case but did not give details. Linovitz *et al*¹¹ reported that their ultrastructural study showed a variegated pattern with vascular spaces, endothelial buds, rare smooth muscle cells and pericytes, together with less well differentiated cells. Specifically they could see no features of a hormone secreting tumour. In our case there were spindle cells with numerous processes, a discontinuous external lamina, and an amorphous non-fibrillar stroma. Subplasmalemmal densities

Table 4 *No of cases with particular diagnostic label*

Histological diagnoses	No
Haemangiopericytoma	5
Sclerosing haemangioma	3
Ossifying mesenchymal tumour	3
Osteoblastoma	2
Cavernous haemangioma	2
Giant cell reparative granuloma	1
Malignant giant cell tumour	1
Giant cell tumour	1
Non-ossifying fibroma	1
Tumour like mass of degenerate osteoid	1
Fibroblastic proliferation with numerous giant cells	1
Malignant neurinoma	1

were observed, but these could not be resolved into filaments. Although there has been some variation in the described ultrastructural features of reported cases of haemangiopericytoma,¹² the features noted in the present case were entirely consistent with that diagnosis.

A distinctive feature of our case was the presence of large cytoplasmic vesicles surrounded by thick membrane and concentrated close to the plasmalemma. These vesicles were larger than conventional pinocytotic vesicles and have not been noted in previous reports of the ultrastructural features of haemangiopericytomas (most of which have been soft tissue lesions). It is tempting to postulate, but impossible to prove, that these might have represented an exocytotic (perhaps secretory) mechanism.

This then leads to a consideration of the way in which these associated tumours might be related to hypophosphataemic osteomalacia. The speculation has been that the tumours elaborate a peptide with an effect on the renal transport of phosphate.¹³ It has been further speculated that the hypothetical substance might be like parathormone—but lacking an action on bone cells. It might activate adenyl cyclase of the proximal convoluted tubule, thus impairing phosphate reabsorption. Against this Drezner and Feinglos¹⁴ found a deficiency of 1- α , 25-dihydroxyvitamin D₃ in their patient, which, when given, was followed by resolution of the clinical and biochemical abnormalities. Excision of the tumour allowed treatment to be discontinued. Their hypothesis therefore was that these tumours produce a substance which inhibits 25-hydroxycholecalciferol-1-hydroxylase activity, causing a decrease in the synthesis of 1, 25-dihydroxy vitamin D₃, the deficiency of which is thought to cause renal phosphate wasting and the sequence of events leading to osteomalacia and myopathy.

These are as yet hypotheses as few of these interesting lesions have been studied in detail. Despite the absolute rarity of the syndrome it is of true clinical importance, because its recognition has profound implications for early and successful treatment.

References

- 1 McClure J. The demonstration of calcification fronts by in vivo and in vitro tetracycline labelling. *J Clin Pathol* 1982; 35:1278–82.
- 2 McCance RA. Osteomalacia with Looser's nodes (Milkman's syndrome) due to a raised resistance to vitamin D acquired about the age of 15 years. *Q J Med* 1947;14:33–46.
- 3 Evans DJ, Azzopardi JG. Distinctive tumours of bone and soft tissue causing acquired vitamin-D-resistant osteomalacia. *Lancet* 1972;1:353–4.
- 4 Yoshikawa S, Nakamura T, Takagi M, Imamura T, Okano K,

- Sasaki S. Benign osteoblastoma as a cause of osteomalacia. A report of two cases. *J Bone Joint Surg* 1977;59(B):279–86.
- 5 Stout AP, Murray MR. Hemangiopericytoma: a vascular tumour featuring Zimmermann's pericytes. *Ann Surg* 1942;116:26–33.
- 6 Enzinger FM, Smith BH. Hemangiopericytoma. An analysis of 106 cases. *Hum Pathol* 1976;7:61–82.
- 7 McMaster MJ, Soule EH, Ivins JC. Hemangiopericytoma. A clinicopathologic study and long-term follow-up of 60 patients. *Cancer* 1975;36:2232–44.
- 8 Stout AP. Tumors featuring pericytes: glomus tumor and hemangiopericytoma. *Lab Invest* 1956;5:217–23.
- 9 Marcial-Rojas RA. Primary hemangiopericytoma of bone. Review of the literature and report of the first case with metastases. *Cancer* 1960;13:308–11.
- 10 Wold LE, Unni KK, Cooper KI, Sim FH, Dahlin DC. Hemangiopericytoma of bone. *Am J Surg Pathol* 1982;6:53–8.
- 11 Linovitz RJ, Resnick D, Keissling P, et al. Tumor-induced osteomalacia and rickets: a surgically curable syndrome. *J Bone Joint Surg* 1976;58(A):419–23.
- 12 Battifora Hector. Hemangiopericytoma: ultrastructural study of five cases. *Cancer* 1973;31:1418–32.
- 13 Harrison HE. Oncogenous rickets: possible elaboration by a tumour of a humoral substance inhibiting tubular reabsorption of phosphate. *Paediatrics* 1973;52:432–4.
- 14 Drezner MK, Feinglos MN. Osteomalacia due to 1 α , 25-dihydroxycholecalciferol deficiency. Association with a giant cell tumor of bone. *J Clin Invest* 1977;60:1046–53.
- 15 Hauge BN. Vitamin D resistant osteomalacia. *Acta Med Scand* 1956;153:271–82.
- 16 Salassa RM, Jousey Jennifer, Arnaud CA. Hypophosphatemic osteomalacia associated with "nonendocrine tumours". *New Engl J Med* 1970;283:65–70.
- 17 Yoshikawa S, Kawabata M, Hatsuyama Y, Hosokawa O, Fujita T. Atypical vitamin-D resistant osteomalacia. *J Bone Joint Surg* 1964;46(A):998–1007.
- 18 Olefsky J, Kempson R, Jones H, Reaven G. Tertiary hyperparathyroidism and apparent "cure" of vitamin-D-resistant rickets after removal of an ossifying mesenchymal tumour of the pharynx. *New Engl J Med* 1972;286:740–5.
- 19 Moser CR, Fessell J. Rheumatic manifestations of hypophosphatemia. *Arch Intern Med* 1974;134:674–8.
- 20 Renton P, Shaw DG. Hypophosphatemic osteomalacia secondary to vascular tumors of bone and soft tissue. *Skeletal Radiol* 1976;1:21–4.
- 21 Chacko V, Joseph B. Osteomalacia associated with haemangiopericytoma. *J Indian Med Assoc* 1981;76:173–5.
- 22 Prader von A, Illig Ruth, Uehlinger E, Stalder G. Rachitis infolge knochentumors. *Helv Paediatr Acta* 1959;14:554–65.
- 23 Krane SM. Case records of the Massachusetts General Hospital. *New Engl J Med* 1965;273:494–504.
- 24 Pollack JA, Schiller AL, Crawford JD. Rickets and myopathy cured by removal of a nonossifying fibroma of bone. *Paediatrics* 1973;52:364–71.
- 25 Willhoite DR. Acquired rickets and solitary bone tumor: the question of a causal relationship. *Clinical Orthopaedics and Related Research* 1975;109:210–1.
- 26 Daniels RA, Weisenfeld I. Tumorous phosphaturia osteomalacia. Report of a case associated with multiple hemangioma of bone. *Am J Med* 1979;67:155–9.
- 27 Nitzan DW, Marmary Y, Azaz V. Mandibular tumor-induced muscular weakness and osteomalacia. *Oral Surg* 1981; 52:253–6.

Requests for reprints to: Dr J McClure, Department of Histopathology, University Hospital School of Medicine, Nell Lane, West Didsbury, Manchester M20 8LR, England.