

# Histochemistry of dipeptidyl aminopeptidase (DAP) II and IV in reactive lymphoid tissues and malignant lymphoma

M R KHALAF, N M AQEL, F G J HAYHOE

*From the Department of Haematological Medicine, University Clinical School, Cambridge*

**SUMMARY** A modified histochemical method was used to show the presence of dipeptidyl aminopeptidase (DAP) II and IV in fixed, freeze dried, cryostat sections of tonsils, lymph nodes, and skin. In 14 reactive tonsils and lymph nodes both enzyme reactions were largely confined to T dependent areas where scattered positive lymphocytes were shown in the paracortical zones, while lymphocytes of germinal centres (B dependent areas) were negative. In either site some macrophages showed strong positivity for both enzymes. In 23 lymph node and two skin biopsy specimens of non-Hodgkin's lymphoma the neoplastic lymphocytes of 12 B cell lymphomas were completely unstained, whereas in the 13 cases of T cell lymphoma the neoplastic lymphocytes showed variable reactions with positivity for DAP II in eight and for DAP IV in seven, both reactions being positive in four and negative in two. Touch imprints of a lymph node from a case of Hodgkin's disease showed that the Reed-Sternberg cells were unreactive for both enzymes. The histochemistry of DAP II and IV may supplement other histochemical and immunological markers in the cytological classification of lymphomas.

Enzyme histochemistry can identify different functional compartments in human lymphoid tissues.<sup>1</sup> B and T cell regions are clearly distinguished by 5'-nucleotidase, adenosine triphosphatase,<sup>1</sup>  $\alpha$ -naphthyl acetate esterase, acid phosphatase,<sup>2</sup> and alkaline phosphatase methods.<sup>3</sup> Table 1 summarises

the distribution of these various histochemical reactions among the cells of B and T regions in lymph nodes.

Dipeptidyl aminopeptidase II (DAP II, EC 3.4.14.2) and dipeptidyl aminopeptidase IV (DAP IV, EC 3.4.14.4) are exopeptidases<sup>4</sup> which can be shown cytochemically in haemic cells.<sup>5-10</sup> While DAP IV has been found to be confined to T dependent areas in

Accepted for publication 19 November 1986

Table 1 *Enzyme histochemical reactions in lymph nodes*

	<i>5'-N</i>	<i>ATPase</i>	<i>ANAE</i>	<i>AcP</i>	<i>AIP</i>
<i>B cell region</i>					
Germinal centre	+	-	-	-	-
Follicular mantle	++	++	-	-	-
Reticulum cells					
Histiocytic			++	++	
Dendritic	++		+	-	
<i>T cell region</i>					
T nodular lymphocytes	-	-	+	+	±
Reticulum cells					
Interdigitating	-	++	±	±	-
Fibroblasts	-	-	±	±	+

5'-N, 5'-Nucleotidase; ATPase, adenosine-triphosphatase; ANAE,  $\alpha$ -naphthyl acetate esterase; AcP, acid phosphatase; AIP, alkaline phosphatase.

peripheral lymphoid tissues,<sup>7 9 11</sup> as far as we know DAP II has not been studied in these tissues.

In this study we applied histochemical methods for DAP II and IV to frozen sections of tonsils and lymph nodes. We sought to determine whether DAP II was a T cell marker in lymphoid tissue, as has been reported for DAP IV.<sup>7 9 11</sup>

**Material and methods**

Fourteen reactive and 26 neoplastic samples were studied. The reactive samples consisted of six tonsils and eight lymph nodes. The neoplastic samples comprised 24 lymph nodes—one from Hodgkin's disease and 23 from non-Hodgkin's lymphoma including 12 B cell lymphomas and 11 T cell lymphomas—and two skin biopsy specimens of cutaneous T cell lymphomas. Diagnosis of these cases was based on examination of haematoxylin and eosin sections and immunoperoxidase results, using monoclonal antibodies on frozen sections.<sup>12</sup>

Six µm frozen sections were made from these cases and freeze dried for four to 18 hours, fixed in absolute acetone for 10 minutes at room temperature, and stored at -20°C, as described previously.<sup>13</sup>

Touch imprints were prepared by cutting through the tonsil or the lymph node, then pressing the cut surface gently against the slide.

**HISTOCHEMICAL METHODS**

The demonstration of DAP II and IV was performed according to the method of Lojda *et al*,<sup>14</sup> with slight modifications (table 2).

**Fixation study**

Freeze dried cryostat sections of tonsils were fixed in: (i) acetone for 10 minutes; (ii) acetone for 10 minutes followed by chloroform at 4°C for one minute; (iii) acetone for 10 minutes followed by formaldehyde vapour for two minutes; (iv) formaldehyde vapour for two minutes. Acetone fixed freeze dried cryostat sections of lymph nodes were then fixed in chloroform at 4°C for one minute, or formaldehyde vapour for two minutes. Touch imprints of lymph nodes were fixed in formaldehyde vapour for two minutes.

**The modified method; reagents**

Fixative: formaldehyde solution (37–40% w/v, BDH "Analar").

Substrates: lysyl-alanyl-4-methoxy-2-naphthylamide (LAMN), glycyL-prolyl-4-methoxy-2-naphthylamide (GPMN) (Bachem).

Solvent: dimethylformamide (DMF) (BDH "Analar").

Buffers: 0.1 mol/l cacodylate buffer pH 5.2, prepared from sodium cacodylate trihydrate (Koch-Light); 0.1 mol/l phosphate buffer, pH 7.2, prepared from sodium dihydrogen orthophosphate dihydrate NaH<sub>2</sub>PO<sub>4</sub>.2H<sub>2</sub>O (BDH).

Coupling agent: fast blue B salt (FBB) Stabilised diazonium salt of O-dianisidine, CI 37235 (Sigma). Counterstain: Carazzi's haematoxylin, as described previously.<sup>15</sup>

Blueing agent: Scott's tap water substitute.<sup>16</sup>

Mounting medium: Apathy mounting medium (Raymond A Lamb).

Table 2 Comparison of histochemical methods for showing dipeptidyl aminopeptidases II and IV (DAP II and IV)

	DAP II		DAP IV	
	Lojda <i>et al</i> (1979)	Present study	Lojda <i>et al</i> (1979)	Present study
Tissue	Rat kidney and spleen	Human tonsil and lymph node	Rat kidney and intestine	Human tonsil and lymph node
Pretreatment	FDCC, FC, GC	FDA + FV	FDCC, CIA, CA, UC, FC, PP	FDA
Substrate concentration in the incubation medium	0.4 mg/ml	0.6 mg/ml	0.5–1 mg/ml	0.8 mg/ml
Buffer	Cacodylate pH 5–5.5	Cacodylate pH 5.2	Phosphate or cacodylate pH 7.2–7.5	Phosphate pH 7.2
Incubation	½–1 ½ hours at 37°C	2 hours at 37°C	5–90 minutes at room temperature or 37°C	45 minutes at room temperature
Post-treatment	Several hours		Several hours	
4% Formaldehyde Counterstain		Carazzi's haematoxylin		Carazzi's haematoxylin

IM, incubation medium; RT; room temperature; FDCC, freeze dried cryostat section coated with celloidin; FC, cryostat section after block fixation in formaldehyde; GC, cryostat section after block fixation in glutaraldehyde; FDA, freeze dried cryostat section fixed in acetone for 10 minutes; FDA + FV, freeze dried cryostat section fixed in acetone for 10 minutes followed by exposure to formaldehyde vapour for 2 minutes; CIA, chloroform-acetone (1:1 by vol.) for 2–5 minutes at 4°C; CA, cryostat section fixed in acetone for 5–10 minutes at 4°C; UC, unfixed cryostat section; FP, paraffin section after formaldehyde fixation.

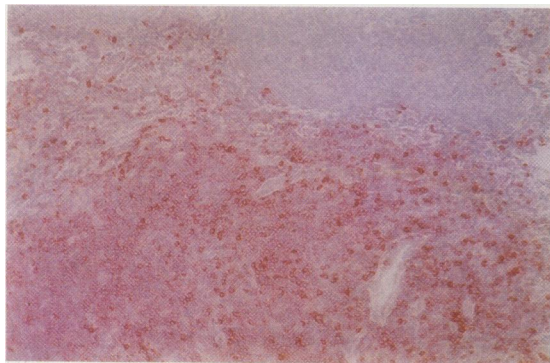


Fig 1

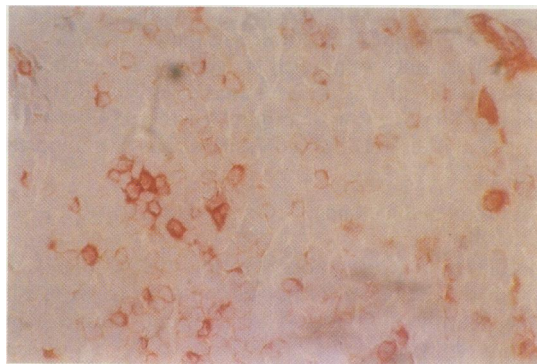


Fig 2

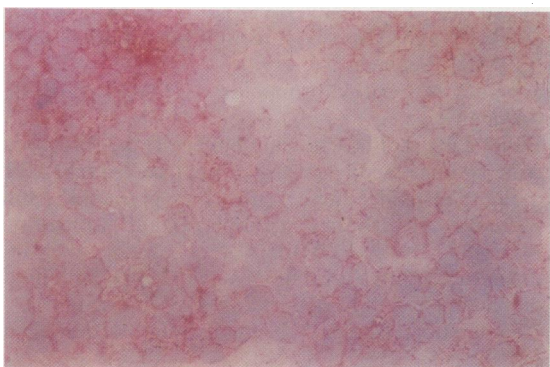


Fig 3

Fig 1 *Dipeptidyl aminopeptidase IV*, freeze dried cryostat section of a reactive lymph node. Most T lymphocytes in paracortical area are positive whereas B lymphocytes in germinal centre are negative.

Fig 2 *Dipeptidyl aminopeptidase IV*, freeze dried cryostat section of a reactive lymph node. In paracortex five macrophages with fine processes show strong positivity. Some T lymphocytes are slightly to moderately positive.

Fig 3 *Dipeptidyl aminopeptidase IV*, freeze dried cryostat section of lymph node with T-cell lymphoma. T lymphocytes show surface positivity.

#### *Incubation mixture for DAP II*

Dissolve 4 mg of LAMN in 0.25 ml of DMF. Add to 4.75 ml of cacodylate buffer and mix well. Add 5 mg of fast blue B salt and mix well. Adjust pH to 5.2 if necessary by 0.2 mol/l hydrochloric acid and filter.

#### *Incubation mixture for DAP IV*

Dissolve 3 mg of GPMN in 0.2 ml DMF. Add to 4.6 ml of phosphate buffer and mix well. Dissolve 5 mg of fast blue B salt in 0.2 ml DMF. Add to the above solution and mix well. Adjust pH to 7.2 by 0.2 mol/l hydrochloric acid if necessary and filter.

#### *Technique*

- 1 Fix freeze dried cryostat sections in acetone for 10 minutes (for DAP IV and DAP II) followed by exposure to formaldehyde vapour for two minutes (for DAP II).
- 2 In a humid chamber apply incubation mixture to sections using a 100  $\mu$ l pipette (100  $\mu$ l each section) and cover each slide with a 22  $\times$  64 mm coverslip spreading the mixture over the sections.
- 3 Incubate at 37°C for two hours (DAP II) or at room temperature for 45 minutes (DAP IV).

- 4 Remove the coverslip carefully and wash in distilled water.
- 5 Counterstain in Carazzi's haematoxylin.
- 6 Wash briefly in alkaline (hard) tap water or immerse in Scott's tap water substitute for 30 seconds and rinse in distilled water.
- 7 Mount the sections by using Apathy mounting medium.

The substrates are expensive, so preparation of large amounts of incubation media for use in Coplin jars or even smaller plastic containers is not usually justified. The alternative is to use a humid chamber.

It is feasible to study the DAP II and IV activities in smears up to several months old because of their reported stability.<sup>4,17</sup>

Azo dye reaction product fades in time. It also dissolves in oil used in microscopy, so mounting in Apathy's mounting medium was used to preserve the reaction product.

#### **Results**

Acetone fixation for 10 minutes (for DAP IV) followed by formaldehyde vapour for two minutes (for

DAP II) was the most satisfactory for histochemical demonstration of the enzymes in freeze dried cryostat sections of tonsils and lymph nodes.

The lymph node frozen sections were freeze dried and fixed in acetone because they were originally prepared for immunohistochemistry and kept in the deep freeze at  $-20^{\circ}\text{C}$  for some months. They were thawed and processed directly for DAP IV and exposed to formaldehyde vapour for two minutes for DAP II, which preserved the reaction product.

#### HISTOCHEMICAL REACTION

Both enzymes liberate the 4-methoxy-2-naphthylamine which couples promptly with the diazonium salt fast blue B in the incubation medium to form a deep red azo dye insoluble in aqueous media.

#### ACTIVITY OF DAP II AND IV IN LYMPHOID TISSUES

##### *Normal or reactive tonsils and lymph nodes*

In fixed freeze dried cryostat sections from six tonsils and eight lymph nodes the paracortical zones (T lymphocytes areas) showed scattered lymphocytes positive for DAP II and DAP IV (fig 1), but the reaction was variable both in intensity and in the number of stained cells. Positive cells displayed granular cytoplasmic staining, although some cells showed ring like positivity (DAP II), or prominent dot like patterns. In the paracortex macrophages with branching cytoplasmic processes were strongly positive for both DAP II and DAP IV (fig 2). In the germinal centre (B lymphocyte area) no positive lymphocytes were seen but few macrophages were positive for both enzymes. In medulla some macrophages showed DAP II and DAP IV activity. Endothelial cells of lymph sinuses of tonsils and lymph nodes showed the DAP IV reaction.

##### *B Hodgkin's disease*

In lymph node imprints Reed-Sternberg cells were

negative for DAP II and IV, while some lymphocytes were positive.

##### *Non-Hodgkin's lymphoma*

Fixed freeze dried cryostat sections from 12 cases of B cell lymphoma were studied. The neoplastic B lymphocytes were completely unstained, whereas the few scattered reactive T lymphocytes were positive for both enzymes. In 13 cases of T cell lymphoma most neoplastic lymphocytes of eight cases were positive for DAP II and those of seven cases were positive for DAP IV. Of the 13 cases, four showed positivity for both DAP II and IV, and two were negative for both enzymes (table 3).

#### Discussion

Our previous report,<sup>8,9</sup> using the DAP II cytochemical test on erythrocyte rosetting lymphocytes from peripheral blood confirmed that the enzyme is present in both rosetting T and non-rosetting B lymphocytes. In contrast to the circulating mature lymphocytes, the lymphoid cells of germinal centres of tonsils and lymph nodes did not contain the enzyme. A few scattered macrophages in the germinal centre were the only cells showing the presence of DAP II. There may be a progression in appearance of DAP II in B lymphocytes, the enzyme being absent from the germinal centre yet fully developed in the circulating lymphocytes.

In T cell areas like paracortical zones and in the medullary cords some scattered lymphocytes and many macrophages were positive for both DAP II and DAP IV. These results are different from those of DAP IV on the lymphoid tissues,<sup>7,11</sup> which reported that this enzyme is exclusively present in T lymphocytes and the endothelial cells of lymphatic vessels, whereas macrophages were negative. This may be due to the different processing of the lymph nodes including use of a different fixative which might not inhibit the macrophage enzyme.

It is important to realise that certain other lysosomal enzymes occur in circulating B and T lymphocytes but cannot be found in either B or T lymphocyte subpopulations in tonsils and lymph nodes. Examples of these are acid phosphatase (EC 3.1.3.2),  $\beta$ -glucuronidase (EC 3.2.1.31), N-acetyl- $\beta$ -glucuronidase (EC 3.2.1.30), and 5'-nucleotidase (EC 3.1.3.5); all are also expressed in the circulating lymphocytes. In tonsils and lymph nodes the first three enzymes are restricted to T lymphocyte regions,<sup>18</sup> while 5'-nucleotidase was confined to B lymphocyte areas.<sup>1,9,10,19,20</sup> These findings confirm that the lysosomal enzyme content in circulating lymphocytes is different from that of lymphoid tissues and variable in different lymphoid compartments.

Table 3 DAP II and IV in T cell lymphoma\*

Cases	DAP II	DAP IV
1	+	-
2	-	+
3	+	-
4	+	+
5	+	+
6	-	+
7	+	+
8	-	-
9	-	+
10	+	-
11	+	+
12	-	-
13	+	+

\*All cases were lymph node biopsy specimens except cases 3 and 9 which were skin biopsy specimens.

The histochemical demonstration of DAP II and DAP IV provides a more reliable test for T lymphocytes in lymph nodes than does the demonstration of  $\alpha$ -naphthyl acetate esterase and  $\beta$ -glucuronidase, because the first two enzymes do not occur in B lymphocytes while the latter two are shown in some B lymphocytes.<sup>21 22</sup> In this study the neoplastic lymphoid cells of all B cell lymphomas were devoid of both DAP II and IV. This confirmed previous reports that DAP IV is absent in B neoplasms.<sup>7-9 23</sup>

In the 13 specimens from patients with T cell lymphoma eight were positive for DAP II and seven for DAP IV. Only four cases showed positivity for both enzymes. This is in line with a previous study on DAP IV,<sup>24</sup> in which seven of 23 cases of T lymphoblastic lymphoma/leukaemia showed positivity, which was not clearly correlated with surface antigen patterns detectable by a battery of monoclonal antibodies, although all positive cases seemed to react with both T4 and T8. Whether the variability of DAP II and IV activities may be related to T cell maturation, or, as Feller *et al*<sup>24</sup> suggest, is the case for DAP IV, may indicate a particular subset of T lymphocytes, remains to be determined.

The physiological importance of DAP II and IV in lymphocytes is obscure.<sup>6</sup> DAP II catalyses the cleavage of amino terminal dipeptides from various tripeptides and DAP IV cleaves the amino terminal dipeptides from various tripeptides and oligopeptides.<sup>4</sup> The fact that the main products of the lysosomal digestion of proteins are either dipeptides or free amino acids<sup>25</sup> suggests that DAP II and IV in addition to cathepsin A and dipeptidyl aminopeptidase I (DAP I), are very active at the late stage of polypeptide digestion.

In conclusion, DAP II and IV were successfully used on fixed freeze dried cryostat sections and showed specific distribution in T dependent areas of tonsils and lymph nodes. Neoplastic lymphoid cells of B cell lymphoma were devoid of both enzymes while the enzyme activities varied in T cell lymphoma. Reed-Sternberg cells showed neither DAP II nor DAP IV activity. The histochemical techniques are suitable for routine practice and may be useful in combination with other histochemical and immunohistological markers in the study of lymphoma.

We thank Professor W Jacobson for useful discussion. We are grateful to Professor DH Wright, department of pathology, University of Southampton, and Dr J Arno, department of pathology, University of Cambridge, for supplying us with more sections from lymph nodes and skin with T cell lymphoma. We thank Mr M Barber for technical assistance, Mr R Flemans and Mr R Kimberley for photo-

graphic advice and assistance, and Mrs J Chandler for typing the manuscript.

MR Khalaf was supported by a scholarship from Asyut University Faculty of Medicine, Asyut, Egypt. FGJ Hayhoe is the Leukaemia Research Fund Professor of Haematological Medicine.

#### References

- Müller-Hermelink HK. Characterization of the B-cell and T-cell regions of human lymphatic tissue through enzyme histochemical demonstration of ATPase and 5'-nucleotidase activities. *Virchows Arch (Cell Pathol)* 1974;16:371-8.
- Leder L-D. *Der Blutmonocyt* (Experimentelle Medizin, Pathologie und Klinik, Bd 23). Berlin: Springer-Verlag, 1967.
- Lennert K, Mohri N, Stein H, Kaiserling E, Müller-Hermelink HK. Malignant lymphomas other than Hodgkin's disease. *Histology, cytology, ultrastructure, immunology*. Berlin: Springer-Verlag, 1978.
- McDonald JK, Schwabe C. Intracellular exopeptidases. In: Barrett AJ, ed. *Proteinases in mammalian cells and tissues*. 2nd ed. Amsterdam: North-Holland, 1977:311-91.
- Lojda Z. Studies on glycol-proline naphthylamidase. I. Lymphocytes. *Histochemistry* 1977;54:299-309.
- Lojda Z. Proteinases in pathology. Usefulness of histochemical methods. *J Histochem Cytochem* 1981;29:481-93.
- Chilosi M, Pizzolo G, Menestrina F, Iannucci AM, Bonetti F, Fiore-Donati L. Dipeptidyl (amino) peptidase IV (DAP IV) histochemistry on normal and pathologic lymphoid tissues. *Am J Clin Pathol* 1982;77:714-9.
- Khalaf MR, Bevan PC, Hayhoe FGJ. Comparative cytochemical study of dipeptidyl aminopeptidase DAP II and IV in normal and malignant haemic cells. *J Clin Pathol* 1986;39:891-6.
- Khalaf MR. Enzyme cytochemical studies in haemic cells. Cambridge: University of Cambridge, 1986. (Thesis.)
- Hayhoe FGJ, Quaglino D. *Haematological cytochemistry*. 2nd ed. Edinburgh: Churchill Livingstone, 1987.
- Feller AC. Cytochemical reactivity of T $\mu$  lymphocytes in human lymphatic tissue for dipeptidylaminopeptidase IV. *Histochem J* 1982;14:889-5.
- Aqel NM, Arno J, Waldmann H, Jones D, Wright D. Studies with rat monoclonal antibodies to human tissue macrophages in lymphomatous disease. In: Quaglino D, Hayhoe FGJ, eds. *The cytobiology of leukaemias and lymphomas*. New York: Raven Press, 1985:121-5.
- Aqel NM, Clark M, Cobbold SP, Waldmann H. Immunohistological screening in the selection of monoclonal antibodies: the use of isotype-specific antiglobulins. *J Immunol Methods* 1984;69:207-14.
- Lojda Z, Gossrau R, Schiebler TH. *Enzyme histochemistry: a laboratory manual*. Berlin: Springer-Verlag, 1979:187-205.
- Hayhoe FGJ. *Leucocyte cytochemistry*. Broadsheet 96, Association of Clinical Pathologists. London: BMA, 1981.
- Scott SG. On successive double staining for histological purposes (preliminary note). *J Pathol Bacteriol* 1911-1912;16:390-8.
- McDonald JK, Reilly TJ, Zeitman BB, Ellis S. Dipeptidyl-lylamidase II of the pituitary; properties of lysylalanyl-B-naphthylamide hydrolysis, inhibition by cations distribution in tissues and subcellular localisation. *J Biol Chem* 1968;243:2028-37.
- Seymour GJ, Dockrell HM, Greenspan JS. Enzyme differentiation of lymphocyte subpopulations in sections of human lymph nodes, tonsils and periodontal disease. *Clin Exp Immunol* 1978;32:169-78.
- Jondal M, Pross H. Surface markers on human B and T lymphocytes. VI Cytotoxicity against cell lines as a functional marker for lymphocyte subpopulations. *Int J Cancer* 1975;15:596-605.

- 20 Khalaf MR, Hayhoe FGJ. Improved cytochemistry of a specific 5'-nucleotidase in haemic cells and lymphoid tissue. *Histochem J* 1987 (in press).
- 21 Machin GA, Halper JP, Knowles DM. Cytochemically demonstrable beta-glucuronidase activity in normal and neoplastic human lymphoid cells. *Blood* 1980;56:1111-9.
- 22 Chilosì M, Pizzolo G, Menestrina F, Iannucci AM, Bonetti F, Fiore-Donati L. Enzyme histochemistry on normal and pathologic paraffin-embedded lymphoid tissues. *Am J Clin Pathol* 1981;76:729-36.
- 23 Feller AC, Parwaresch MR. Specificity and polymorphism of diaminopeptidase IV in normal and neoplastic T lymphocytes. *J Cancer Res Clin Oncol* 1981;101:59-63.
- 24 Feller AC, Parwaresch MR, Lennert K. Cytochemical distribution of dipeptidylaminopeptidase IV (DAP IV; EC 3.4.14.5) in T-lymphoblastic lymphoma/leukaemia characterized with monoclonal antibodies. *Leuk Res* 1984;8:397-406.
- 25 Vaes G. Digestive capacity of lysosomes. In: Hers HG, van Hoof F, eds. *Lysosomes and storage diseases*. New York: Academic Press, 1973:51-2.

Requests for reprints to: Professor FGJ Hayhoe, Department of Haematological Medicine, University Clinical School, Hills Road, Cambridge CB2 2QL, England.