

Mefenamic acid enteropathy

P E T ISAACS,* G E SLADEN,* I FILIPE†

*From the *Gastroenterology Unit, Department of Medicine; and the †Department of Pathology, Guy's Hospital, London*

SUMMARY The clinical, radiological, and histological features of two patients with severe intestinal damage induced by mefenamic acid and mimicking coeliac disease are described. Symptoms rapidly reverted on withdrawal of the drug, and in one case, did not relapse during treatment with other non-steroidal anti-inflammatory drugs.

Diarrhoea is a side effect of treatment with mefenamic acid¹; steatorrhoea due to this drug has been reported in seven patients,²⁻⁶ and mild villous damage was observed in the duodenal biopsy specimens of four of these.^{3,4} We report two patients in whom severe villous atrophy and steatorrhoea was apparently due to prolonged treatment with mefenamic acid.

Case report

CASE 1

A 66 year old woman had been taking mefenamic acid (250 mg four times a day) for 14 years for painful osteoarthritis of the hips and lumbar spine. She had persistent diarrhoea for eight years with a loss of 5 kg of body weight over two years. In 1983 at her local hospital she had been found to have steatorrhoea and villous atrophy. She began a gluten free diet but probably did not strictly adhere to this. She developed a hypochromic microcytic anaemia which did not respond to oral iron treatment but which was corrected by parenteral iron treatment. She was referred to us with a suspected pancreatic tumour and resistant coeliac disease. She then weighed 38 kg, was pallid, miserable, and had pedal oedema. Sigmoidoscopy was unremarkable, but she had gross steatorrhoea with a faecal fat excretion of 62 mmol/d, faecal wet weight 1041 g/d while eating a normal diet—that is, containing at least 50 g gluten/d and 250 mmol of fat/d.

She was anaemic (haemoglobin concentration was 9.9 g/dl), the serum albumin was only 24.8 g/dl (normal 30-40), and raised plasma gamma glu-

tamyltransferase activity (155 U/l, normal <40) and 5' nucleotidase (13 U/l, normal <6) were noted. The plasma ferritin concentration (10 ng/ml, normal 15-200) and vitamin D concentration (1.5 ng/ml, normal 3-30) were low. Abdominal ultrasound examination yielded normal results. A ⁹⁹Tc sulphur colloid scan showed reduced liver function and an increased size of the left lobe. A small bowel barium enema (enteroclysis) showed slow transit through a dilated small bowel with loss of "closing valves" in its distal two thirds. A jejunal biopsy specimen showed crypt hyperplastic villous atrophy and a moderately increased lymphoplasmacytic infiltrate in the lamina propria. The number of intraepithelial lymphocytes was not increased; the enterocytes showed pronounced vacuolation but were columnar (fig 1). The ultrastructure of enterocytes was abnormal with crowding and stunting of microvilli. During the investigations her weight fell by 5 kg. Exocrine pancreatic function was normal, the duodenal trypsin concentration being 12 U/ml, (normal >66 u/ml) after a meal. The jejunal bacterial count was 10⁵/ml (normal for this laboratory), but B₁₂ absorption was abnormal with a urinary excretion of 2.7% of an oral dose of ⁵⁷Co B₁₂ (normal 10%).

Mefenamic acid was withdrawn and she continued her gluten diet. Three weeks later the faecal fat excretion had fallen to 29 mmol/d and the faecal wet weight to 200 g/d. A repeat jejunal biopsy specimen showed improvement in villous height, reduction of the lamina propria cell infiltrate, and the return of the enterocyte appearance to normal (fig 2).

She refused all further investigations and gained 7 kg in body weight over the next three months. Parenteral vitamin D (600 000 units) and an infusion of iron was given which corrected the anaemia. The ar-

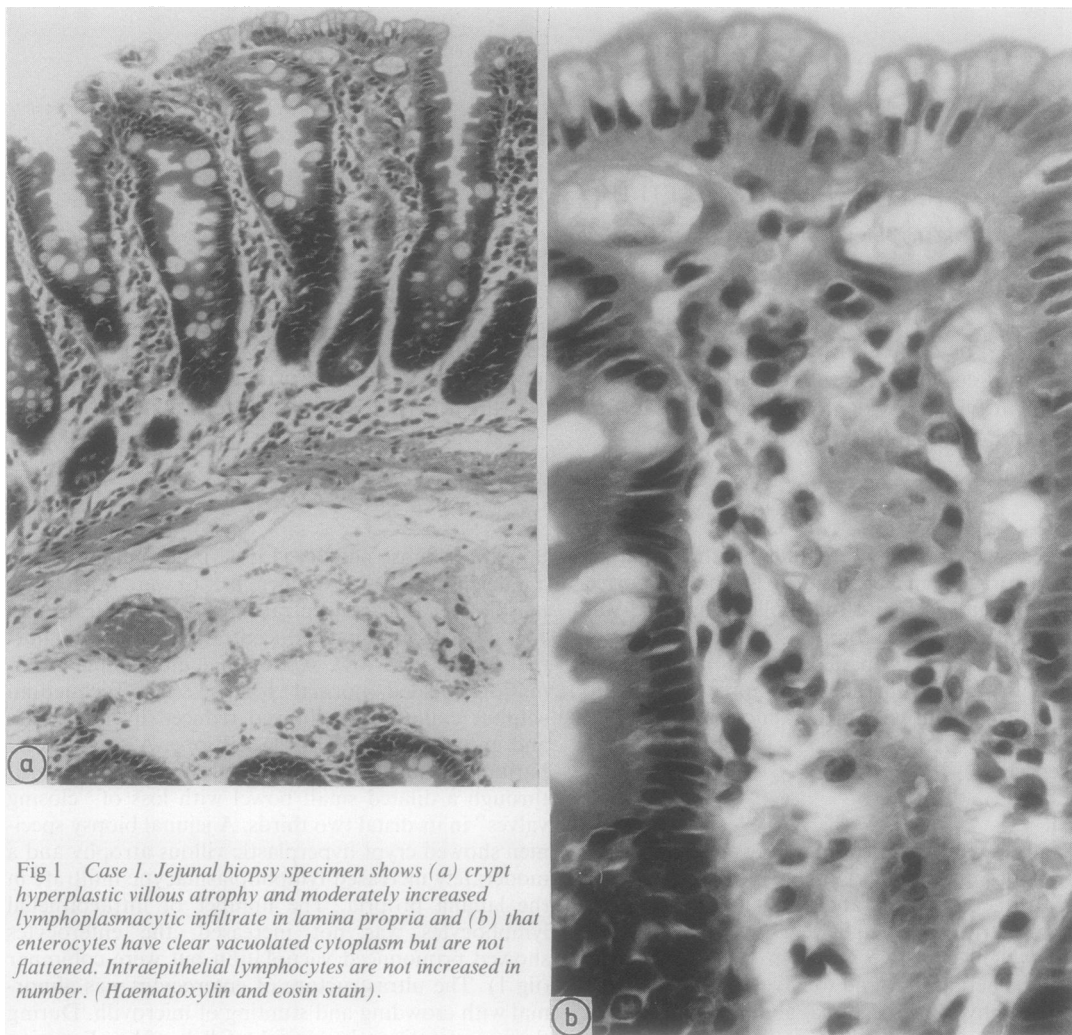


Fig 1 Case 1. Jejunal biopsy specimen shows (a) crypt hyperplastic villous atrophy and moderately increased lymphoplasmacytic infiltrate in lamina propria and (b) that enterocytes have clear vacuolated cytoplasm but are not flattened. Intraepithelial lymphocytes are not increased in number. (Haematoxylin and eosin stain).

thritic pains were successfully controlled with piroxicam during which treatment she became constipated.

CASE 2

A 73 year old woman was referred to the gastroenterology unit with a 15 month history of steatorrhoea and loss of 11 kg of body weight. Her symptoms had begun shortly after starting mefenamic acid (250 mg three times a day) for osteoarthritic pain. Four years previously she had developed diarrhoea after taking indomethacin 75 mg/day and had lost 9 kg in body weight over 12 months before stopping the drug. Apart from the weight loss, physical examination was unremarkable. Investigation results

were erythrocyte sedimentation rate 57 mm first hour, haemoglobin concentration 13.1 g/dl, white cell count $5.2 \times 10^9/l$. The plasma electrolytes, urea, calcium, phosphate concentrations, alkaline phosphatase and aspartate aminotransferase activities and bilirubin, albumin, and total protein concentrations were normal. Low concentrations of serum folate (0.85 $\mu\text{g/l}$, normal 3–5) and B_{12} (190 ng/l, normal 200–850) were found. Rheumatoid factor was absent but antinuclear factor was present to a titre of 1/2560, but the critical immunofluorescence test for anti-double stranded DNA antibodies was negative. The faecal fat excretion was excessive at 97 mmol/d, faecal wet weight 385 g/d. A biopsy specimen of the proximal jejunum showed a pattern of low ridges on dissecting

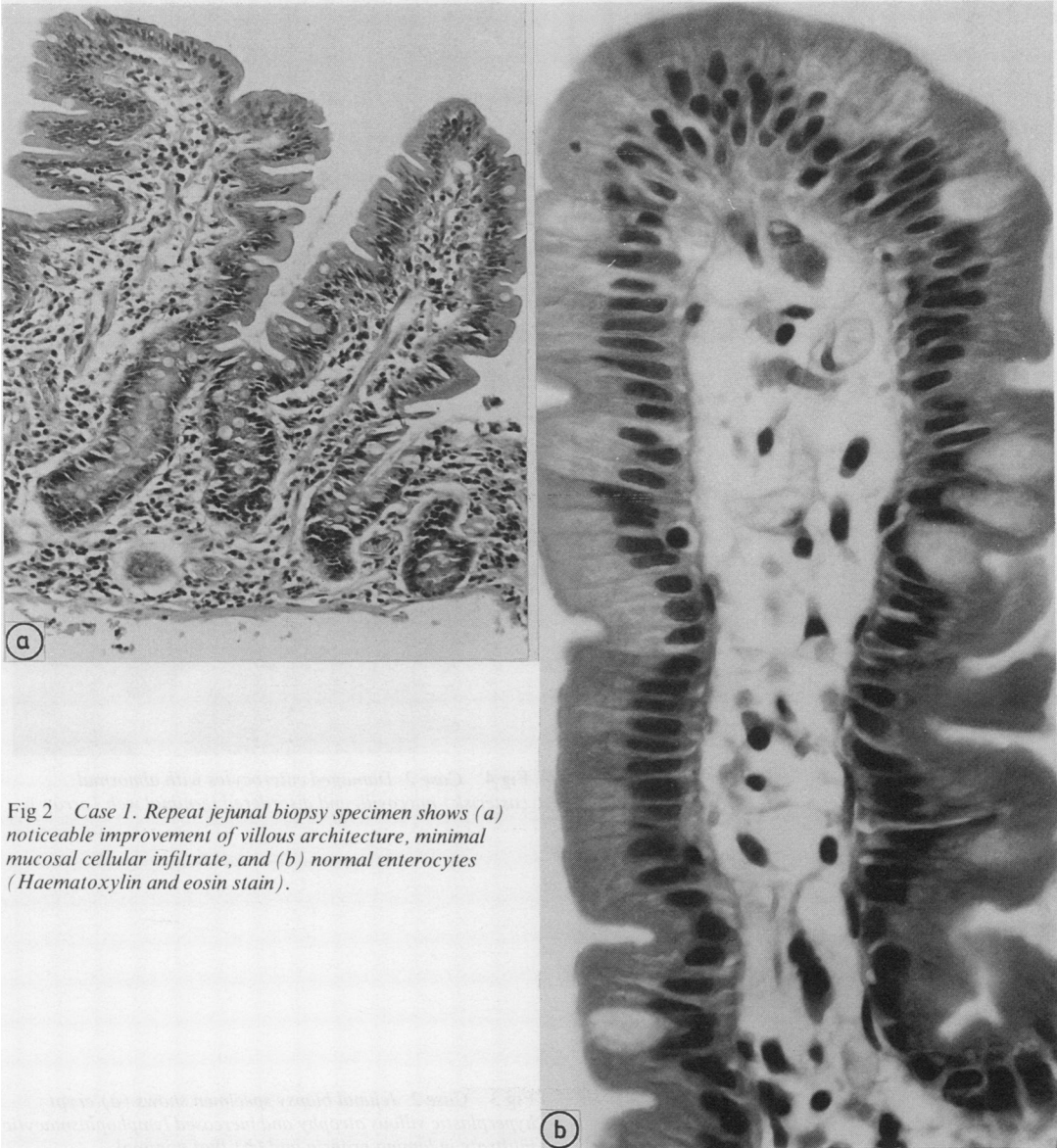


Fig 2 Case 1. Repeat jejunal biopsy specimen shows (a) noticeable improvement of villous architecture, minimal mucosal cellular infiltrate, and (b) normal enterocytes (Haematoxylin and eosin stain).

microscopy; villous atrophy with crypt hyperplasia, but no excess of intraepithelial lymphocytes in section. Electron microscopy (fig 3) showed extensive non-specific brushborder abnormality with clubbed and sparse microvilli, disorganised terminal web, and mitochondrial swelling in enterocytes (fig 4).

The mefenamic acid was then withdrawn and within three days diarrhoea stopped. The faecal fat excretion fell to 26 mmol/d, with a daily faecal weight

of 221 g. In a repeat jejunal biopsy specimen a return to normal size and shaped villi was seen (fig 5) and the ultrastructure of enterocytes was normal (fig 6).

Discussion

Few drugs cause small intestinal damage and although non-steroidal anti-inflammatory drugs other

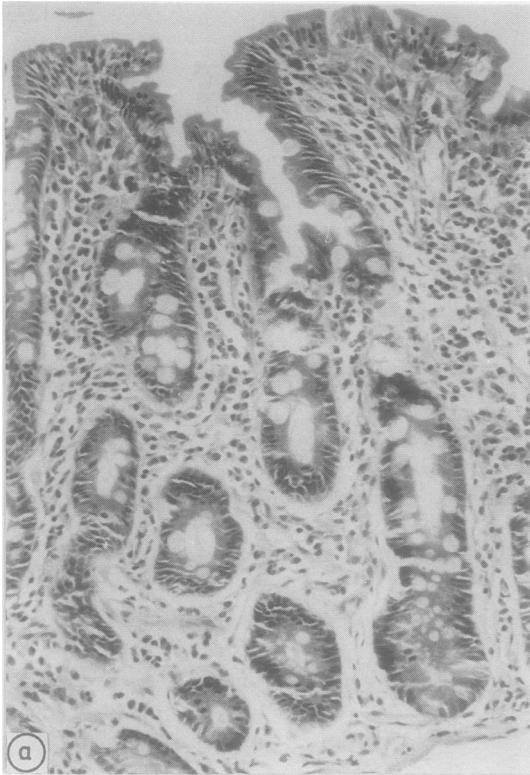


Fig 3(a)

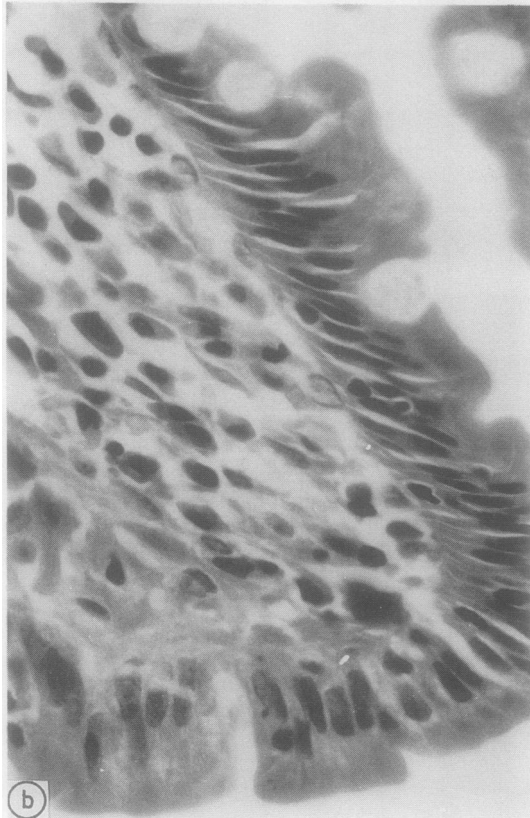


Fig 3(b)

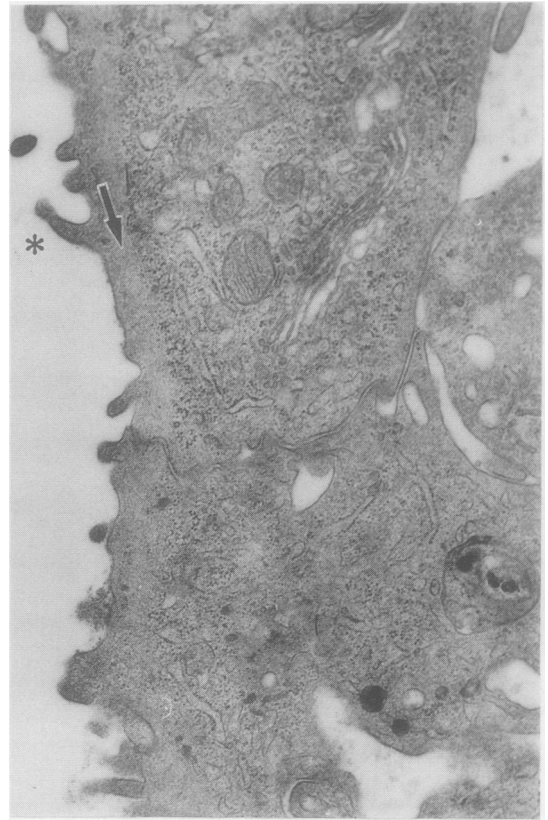


Fig 4 Case 2. Damaged enterocytes with abnormal (asterisk) microvilli and disordered terminal web (arrow).

Fig 3 Case 2. Jejunal biopsy specimen shows (a) crypt hyperplastic villous atrophy and increased lymphoplasmacytic infiltrate in lamina propria and (b) that minimal intraepithelial lymphocytic infiltrate and enterocytes remain tall and regular. (Haematoxylin and eosin stain).

than mefenamic acid cause diarrhoea, none has been reported to cause villous atrophy. In both of the patients reported here treatment with mefenamic acid had been continued for a long time despite an extensive search for a cause of steatorrhoea in case 1 and a clear temporal relation of the onset of diarrhoea with the beginning of the drug in case 2. Clearly, in both patients gluten sensitivity played no part in the aetiology of the villous atrophy which recovered on a

gluten containing diet. The histological abnormalities seen in the jejunal biopsy specimen were similar to those seen in coeliac disease, in particular the crypt-hyperplastic villous atrophy with increased cellularity in the lamina propria. Intraepithelial lymphocytic infiltrate is minimal or absent, however, and the appearance of the enterocytes is not the same, as they may show pronounced apical vacuolation with the retention of the columnar enterocyte shape and the

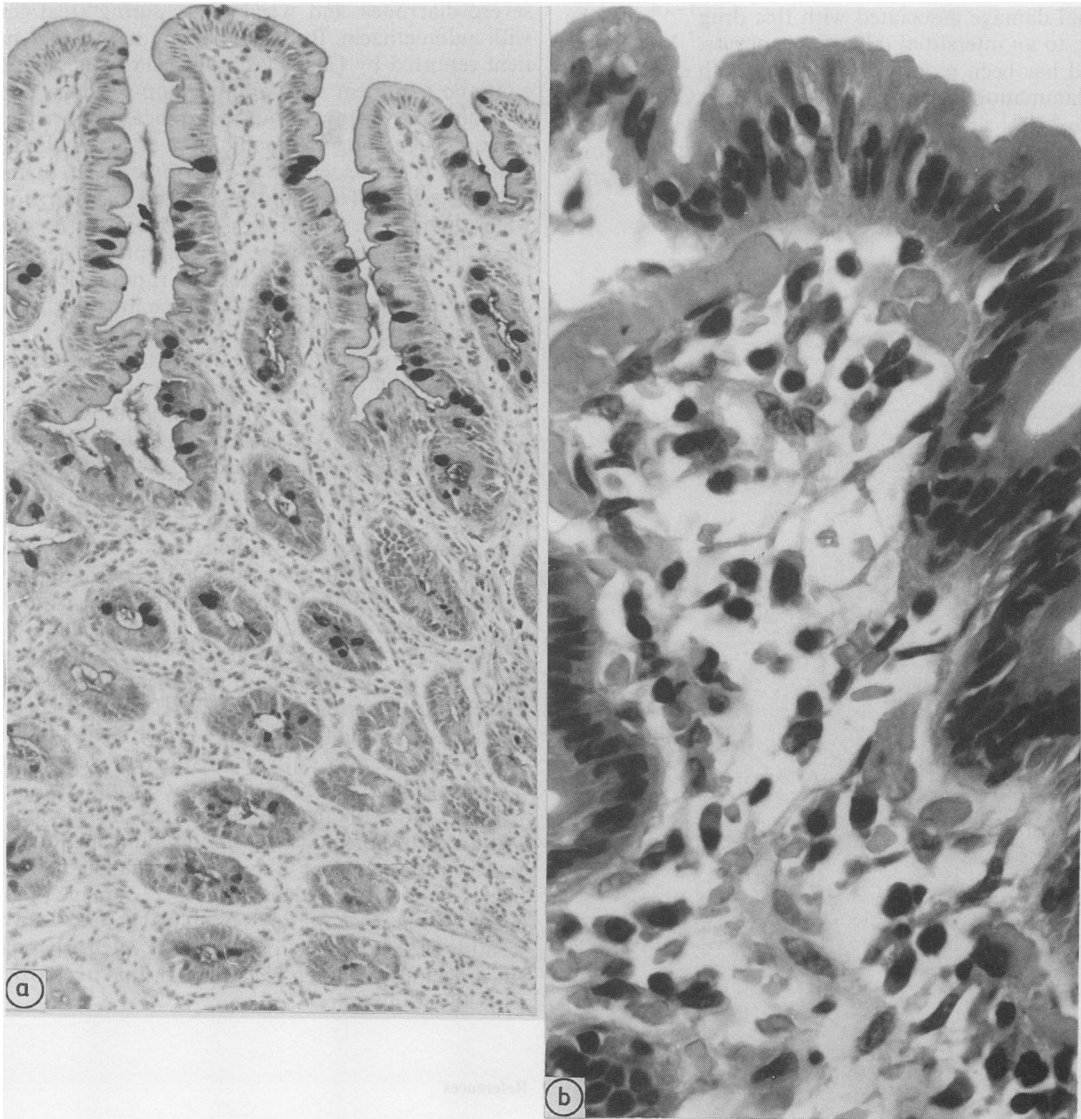


Fig 5 Case 2. Repeat jejunal biopsy specimen shows (a) return to normal size and shaped villi, with well preserved brushborder, decreased cellular infiltrate in lamina propria (Periodic and Schiff) and (b) normal enterocytes (Haematoxylin and eosin).

basal position of the nucleus. In coeliac disease the enterocytes are flattened or polygonal and the regular array of epithelial nuclei is lost. The presence of these features, especially the vacuolation of enterocytes, might provide a clue to the histopathologist that a crypt-hyperplastic villous atrophy might be due to a toxic or drug effect rather than to coeliac disease.

The mechanism of the villous damage is not clear. There were no systemic features suggestive of an allergic reaction nor did the patients have atopy, although one patient had a high titre of antinuclear factor. The renal damage associated with this drug⁷⁻¹⁰ may be due to an interstitial (allergic) nephritis.⁷ Mefenamic acid has been reported as causing both small bowel inflammation and a colitis mimicking Crohn's disease,^{4-6,11} and protracted diarrhoea occurring during treatment with mefenamic acid should, therefore, be regarded as a serious side effect and the manu-

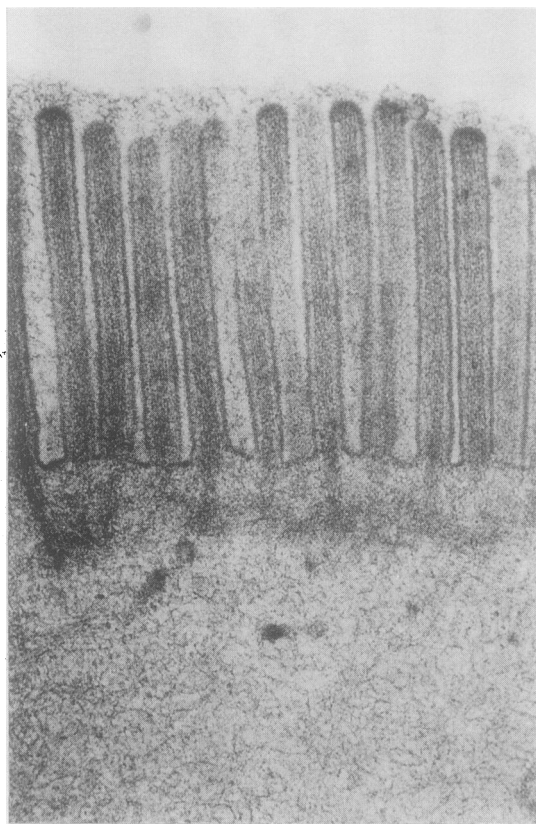


Fig 6 Case 2. Normal microvilli after withdrawal of mefenamic acid.

facturer's instruction that the drug be discontinued strictly adhered to. Notwithstanding the nutritional effects of malabsorption, it has been suggested that the fluid and electrolyte depletion caused by diarrhoea during mefenamic acid treatment may be a major factor contributing to renal failure seen in elderly patients taking this drug.⁸ Mefenamic acid may also be toxic to the pancreas.¹⁰

Steatorrhoea seems to be a side effect unique to mefenamic acid among the non-steroidal anti-inflammatory drugs, although case 2 had already had severe diarrhoea and weight loss during treatment with indomethacin. Both this patient and the one patient reported by Chadwick,³ however, were able to continue treatment with another non-steroidal anti-inflammatory drug without recurrence of diarrhoea, perhaps suggesting that inhibition of prostaglandin synthesis is not essential to this toxic effect of mefenamic acid.¹¹ The rapid reversal of the diarrhoea when the drug is withdrawn, in contrast to its slow onset after starting the treatment, has previously been noted,¹² and contrasts with the rapid deleterious effects of non-steroidal anti-inflammatory drugs on ulcerative proctocolitis.¹³

The rather small number of reports of steatorrhoea associated with mefenamic acid might indicate either that the drug was rapidly withdrawn in those patients who developed diarrhoea and who might otherwise have progressed to villous damage, or that the villous damage reflected a specific sensitivity of the jejunal mucosa of a small number of individuals. If the villous atrophy associated with mefenamic acid is an allergic reaction then the study of the mechanism of villous damage induced by mefenamic acid could be of relevance to the pathogenesis of coeliac disease.

Mefenamic acid is of no greater efficacy than aspirin in the treatment of pain due to arthritis or soft tissue injury,¹ and if it is to retain a place in current treatment it should probably be restricted to short courses for younger patients or for the relief of bone pain in disseminated malignant disease and always in strict accord with the manufacturer's instruction to withdraw it immediately, should diarrhoea occur. Several drugs may cause small bowel damage, in particular neomycin has been shown to damage villi,¹⁴ and an awareness of this possibility should lead to scrutiny of the patients' prescriptions when an apparent resistance to gluten restriction occurs in a patient with villous atrophy.

References

- 1 Gilman AG, Goodman LS, Gilman A. *The pharmacologic basis of therapeutics*. 6th ed. New York: Macmillan, 1980.
- 2 Marks JS, Gleeson MH. Steatorrhoea complicating therapy with mefenamic acid. *Br Med J* 1975;iv:442.

- 3 Chadwick RG, Hossenbocus A, Collin-Jones D. Steatorrhea complicating therapy with mefenamic acid. *Br Med J* 1976;i:397.
- 4 Hall RI, Petty AH, Cobden I, Lendrum R. Enteritis and colitis associated with mefenamic acid. *Br Med J* 1983;287:1628.
- 5 Rampton DS, Tapping PJ. Enteritis and colitis associated with mefenamic acid. *Br Med J* 1983;287:1627.
- 6 Williams R, Glazer G. Enteritis and colitis associated with mefenamic acid. *Br Med J* 1983;287:1627.
- 7 Drury PL, Asiridas LG, Bulger GV. Mefenamic acid nephropathy: Further evidence. *Br Med J* 1981;282:865-6.
- 8 Venning V, Dixon AJ, Owen DO. Mefenamic acid nephropathy. *Lancet* 1980;ii:745-6.
- 9 Prescott LF. Mefenamic acid nephropathy. *Lancet* 1980;ii:232-3.
- 10 Van Walrav G, Edels M, Fong F. Mefenamic acid and pancreatitis. *Can Med Assoc* 1982;126:894.
- 11 Hawkey CJ, Rampton DS. Prostaglandins and the gastrointestinal mucosa: are they important in its function, disease or treatment? *Gastroenterology* 1985;89:1162-88.
- 12 Phillips MS, Fehilly B, Stewart S, Dronfield MW. Enteritis and colitis associated with mefenamic acid. *Br Med J* 1983;287:1626.
- 13 Rampton DS, Sladen GE. Relapse of ulcerative proctocolitis during treatment with non-steroidal anti-inflammatory drugs. *Postgrad Med J* 1981;57:297-9.
- 14 Lewis JH. Gastrointestinal injury due to medicinal agents. *Am J Gastroenterol* 1986;81:819-34.

Requests for reprints to: Dr PET Isaacs, Department of Gastroenterology, Victoria Hospital, Blackpool FY3 8NR, England.