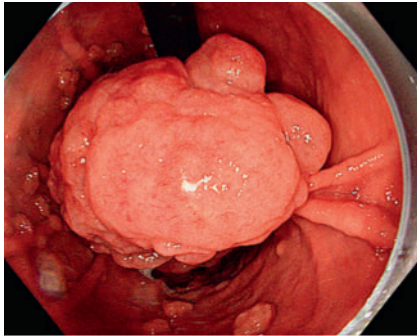


Band-and-wire pulley traction: endoscopic submucosal dissection of a gigantic gastric polyp aided by a novel adaptive traction technique

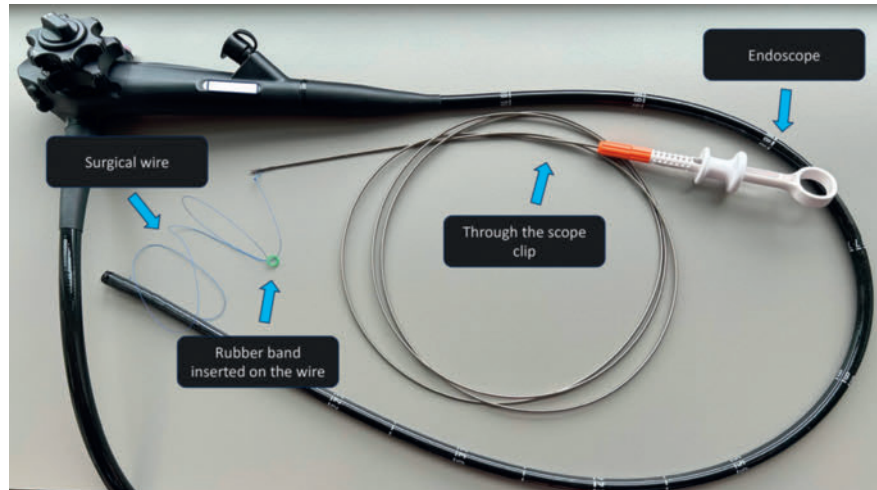
OPEN
ACCESS



► **Fig. 1** Bulky subpedunculated lesion on the lesser curve of the gastric corpus.

An 85-year-old woman presenting iron deficiency anemia and refractory dyspepsia was referred due to a gastric lesion on the lesser curve of the corpus (► **Video 1**). The lesion was subpedunculated (Paris 0-Isp), 120 × 60 mm in diameter, with a short stalk and difficult access (► **Fig. 1**). To address the challenging accessibility during endoscopic submucosal dissection (ESD), a novel adaptive traction technique was employed (► **Fig. 2**, ► **Fig. 3**).

A surgical wire with a loop at one end was clipped to the oral side of the polyp. Then, a band previously placed on the same wire was clipped to the contralateral gastric wall to provide traction for exposure of the stalk. After incision and tunneling, traction was applied on the anal side of the lesion through a second clipped wire. As dissection progressed, the traction was adapted by pulling the wires outside the patient to maintain optimal exposure of the submucosal plane. In total, three pulley traction devices were attached to the oral part of the lesion to complete the resection. The large size of the lesion precluded en bloc retrieval due to the risk of esophageal damage. Given the low suspicion of malignancy, the lesion was divided with a snare and retrieved. Closure of the resection site was not possible



► **Fig. 2** Adaptive band-and-wire pulley traction materials.

due to its size; three clips were placed centrally over the site of large vasculature divided during ESD.

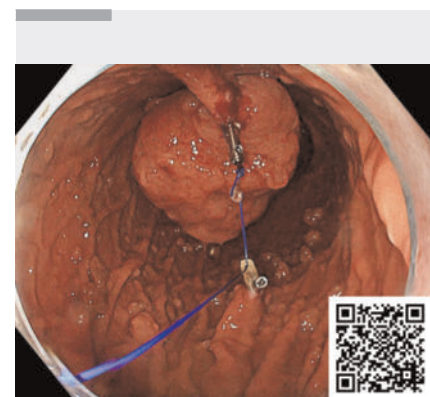
There were no complications and the patient was discharged 24 hours after the resection. Histopathology revealed a nondysplastic hyperplastic polyp. At clinical follow-up 1 month after the resection, dyspepsia and anemia had resolved.

A novel band-and-wire pulley traction technique enabled safe and rapid ESD of a gigantic gastric polyp with difficult access. This technique allows the application of adaptive traction in any direction. The band-and-wire adaptive pulley traction technique enhanced access to the submucosal space and could be considered for gastric and rectal lesions with challenging access.

Endoscopy_UCTN_Code_TTT_1AO_2AG_3AD

Acknowledgement

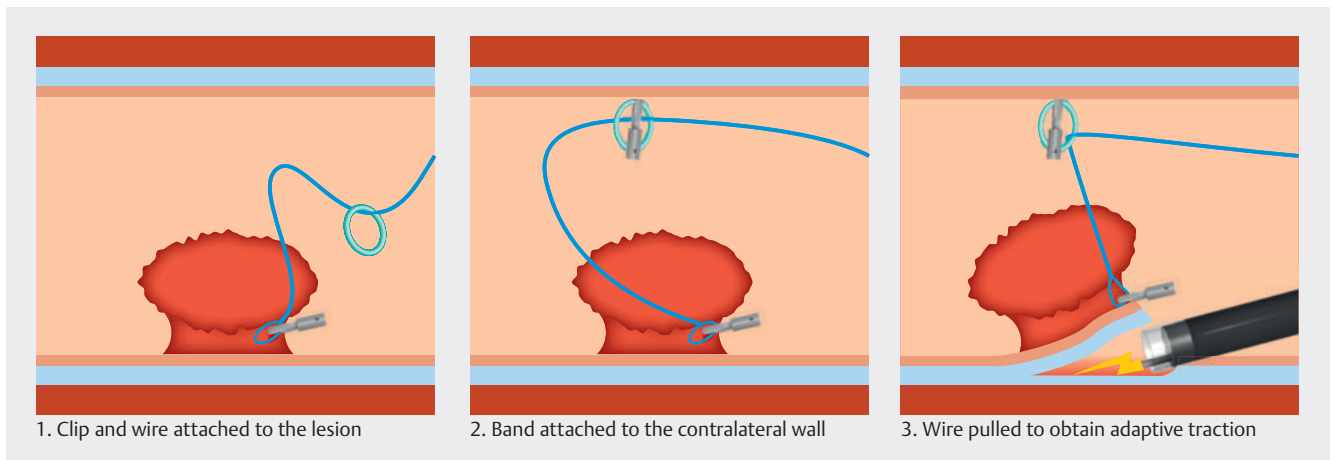
The authors acknowledge the support of the APC central fund of the university of Milan.



► **Video 1** Endoscopic submucosal dissection of a gigantic gastric polyp using the band-and-wire pulley traction technique.

Funding Information

Italian Ministry of Health
IRCCS University of Milan



► **Fig. 3** Schematic representation of the band-and-wire pulley traction technique.

Conflict of Interest

D. J. Tate is a consultant for and has received research support from Pentax Medical, Fujifilm, and Olympus. A. Sorge, M. E. Argenziano, P. J. Poortmans, L. Debels, G. E. Tontini, and M. Vecchi declare that they have no conflict of interest.

The authors

Andrea Sorge^{1,2}, **Maria Eva Argenziano**^{2,3}, **Pieter Jan Poortmans**^{2,4}, **Lynn Debels**^{2,4}, **Gian Eugenio Tontini**^{1,5}, **Maurizio Vecchi**^{1,5}, **David J. Tate**²

- 1 Department of Pathophysiology and Transplantation, University of Milan, Milan, Italy
- 2 Department of Gastroenterology and Hepatology, University Hospital of Ghent, Ghent, Belgium
- 3 Clinic of Gastroenterology, Hepatology and Emergency Digestive Endoscopy, Università Politecnica delle Marche, Ancona, Italy
- 4 Department of Gastroenterology and Hepatology, University Hospital Brussels (UZ Brussels), Brussels, Belgium
- 5 Gastroenterology and Endoscopy Unit, Fondazione IRCCS Ca' Granda Ospedale Maggiore Policlinico, Milan, Italy

Corresponding author

Andrea Sorge, MD

Department of Pathophysiology and Transplantation, University of Milan, Via Francesco Sforza 35, 20122, Milan, Italy
 Andreasorge6@gmail.com

Bibliography

Endoscopy 2024; 56: E778–E779

DOI 10.1055/a-2387-3812

ISSN 0013-726X

© 2024. The Author(s).

This is an open access article published by Thieme under the terms of the Creative Commons Attribution License, permitting unrestricted use, distribution, and reproduction so long as the original work is properly cited.

(<https://creativecommons.org/licenses/by/4.0/>)

Georg Thieme Verlag KG, Rüdigerstraße 14, 70469 Stuttgart, Germany



ENDOSCOPY E-VIDEOS

<https://eref.thieme.de/e-videos>



E-Videos is an open access online section of the journal *Endoscopy*, reporting on interesting cases

and new techniques in gastroenterological endoscopy. All papers include a high-quality video and are published with a Creative Commons CC-BY license. Endoscopy E-Videos qualify for HINARI discounts and waivers and eligibility is automatically checked during the submission process. We grant 100% waivers to articles whose corresponding authors are based in Group A countries and 50% waivers to those who are based in Group B countries as classified by Research4Life (see: <https://www.research4life.org/access/eligibility/>).

This section has its own submission website at

<https://mc.manuscriptcentral.com/e-videos>