

not attempted. We could not show bacilli in our sections of the heart by either Gram staining or immunohistological techniques.

Identification of Gram negative bacteria in tissue sections by Gram staining is difficult and can not differentiate between the species. The immunoperoxidase method has been applied very infrequently to the detection of bacteria in routinely processed tissue sections. In the few reports of which we are aware,<sup>4,5</sup> the antisera had to be purposely raised and were used to detect bacteria in the tissues of experimentally infected animals. We have shown how the antisera, which are routinely used in microbiology laboratories for the serogroup identification of salmonellae, can be successfully used to show and identify bacteria in human tissue sections.

GE BIGNARDI,\*

TY KHONG

\*Department of Microbiology and Public Health Laboratory,  
Department of Paediatric Pathology,  
John Radcliffe Hospital,  
Oxford

## References

- 1 Billingham JD, Slack MPE. Cholecystitis and subphrenic abscess caused by *Salmonella virchow*. *Postgrad Med J* 1981;**57**:308-9.
- 2 Taha A, Peden NR. Congestive heart failure complicating *Salmonella virchow* septicaemia. *J Infect* 1987;**14**:85-6.
- 3 Shilkin KB. *Salmonella typhimurium* pancarditis. *Postgrad Med J* 1969;**45**:40-3.
- 4 Finlayson J, Buxton D, Anderson IE, Donald KM. Direct immunoperoxidase method for demonstrating *Chlamydia psittaci* in tissue sections. *J Clin Pathol* 1985;**38**:712-4.
- 5 McRill CM, Kramer TT, Griffith RW. Application of the peroxidase-antiperoxidase immunoassay to the identification of salmonellae from pure culture and animal tissue. *J Clin Microbiol* 1984;**20**:281-4.

## Retroperitoneal myxoid liposarcoma presenting with hypercalcaemia

Hypercalcaemia can be an initial presentation of many benign and malignant diseases.<sup>1</sup> Soft tissue tumours can occasionally present with biochemical abnormalities. We present here a case of pelvic liposarcoma presenting with clinical hypercalcaemia in the absence of bony metastases or renal impairment.

A 72 year old woman presented with a five

week history of constipation, vague abdominal pain, and dysuria. Her medical history was of maturity onset diabetes controlled by diet and two hospital admissions—in 1979 for a urinary tract infection and in 1985 for a chest infection. She smoked 20 cigarettes a day.

On examination she was afebrile, with an ill defined minimally tender left iliac fossa mass, thought to be faeces. Investigations on admission were: sodium 138 mmol/l (normal range 132-145 mmol/l); potassium 3.2 mmol/l (3.3-4.8 mmol/l); creatinine 122  $\mu$ mol/l (60-110  $\mu$ mol/l); white cell count 16.1 and glucose 12.8 mmol/l. Plain abdominal x-ray picture showed faecal loading and a pelvic soft tissue mass, thought to be bladder. A chest x-ray picture was normal. She was treated with lactulose and amoxycillin for the urinary tract infection (a mid-stream urine specimen grew coliforms greater than  $10^5$  organisms/ml).

She made little progress, and four days after admission full biochemical analysis showed a calcium concentration of 3.48 mmol/l (2.1-2.6 mmol/l) with a corrected calcium of 3.51 mmol/l, phosphate activity of 1.04 mmol/l (0.7-1.4 mmol/l), sodium 143 mmol/l, potassium 3.2 mmol/l, bilirubin 10  $\mu$ mol/l (1-20  $\mu$ mol/l), alkaline phosphatase 96 IU/l (35-105 IU/l), creatinine 142  $\mu$ mol/l, and urea 12.7 mmol/l (2.5-8 mmol/l). She was immediately given intravenous fluids, hydrocortisone, and frusemide; she achieved a good clinical response (figure). A bone scan

showed no metastatic disease but an intravenous urogram showed a pronounced bilateral hydro-ureter and hydronephrosis, with a poor bladder outline, consistent with an obstructive uropathy. Pelvic malignancy, probably of gynaecological origin, was diagnosed.

The response to treatment confirmed the suspicion of malignant hypercalcaemia, and due to the good clinical response the anti-hypercalcaemic treatment was withdrawn. Her condition deteriorated, however, mirroring a rise in the serum calcium concentration to 3.58 mmol/l. Despite an initial response to intravenous fluids, steroids, frusemide and calcitonin, she died 21 days after admission.

Other investigations performed were a normal blood film and marrow smear, normal immunoglobulins and a parathyroid hormone concentration of 0.3 (0.2-0.7  $\mu$ g/l), with a serum calcium concentration of 3.22 mmol/l.

At necropsy there was a diffusely infiltrating pelvic tumour affecting the posterior pelvic wall, bladder, uterus and cervix, with two smaller tumour nodules present on the spleen and colon. There was dilatation of both utero-pelvic/lyceal systems, with early bilateral hydronephrosis. There was a bilateral basal bronchopneumonia. No bony metastases were found and the parathyroids were somewhat atrophic. The other organs were essentially normal. Histological examination showed that the tumour had the

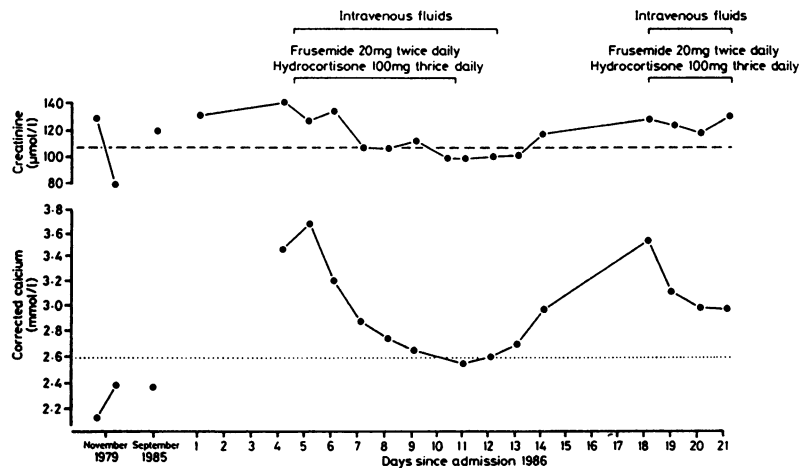


Figure Creatinine and corrected calcium concentrations on previous and last hospital admissions. Dashed and dotted lines represent upper limits of normal for each value, respectively.

characteristic appearance of a myxoid liposarcoma.<sup>2</sup>

Hypercalcaemia is associated with malignancy, either by humoral effect or by bony or renal disease.<sup>3,4</sup> Certain soft tissue tumours have been associated with hypoglycaemia<sup>2</sup> and with hypercalcaemia by the mechanisms stated above. We can find no association of liposarcoma with hypercalcaemia without pronounced renal dysfunction.

The myxoid variant of liposarcoma is the commonest type of liposarcoma (40–50% of all liposarcoma), with the retroperitoneal region being the second commonest site (after the lower limbs).<sup>2,5</sup> Retroperitoneal liposarcomata usually presents either as abdominal swellings, leg oedema, ureteric obstruction or general malaise. We feel that the calcium concentrations, taken with the mild degree of renal impairment, and the response to treatment, favour a primary malignant disease. This is, we believe, the first report of this association.

PA CROSS  
BA ENOCH\*

Departments of Histopathology and  
\*Medicine,  
North Manchester General Hospital,  
Delauney's Road,  
Manchester M8 6RB

#### References

- 1 Potts JT Jr. Diseases of the parathyroid gland and other hyper- and hypocalcaemic disorders. *Harrison's principles of internal medicine*. New York: McGraw-Hill, 1987: 1875–82.
- 2 Enzinger FM, Weiss SW. *Soft tissue tumours*. St Louis: Mosby Company, 1983.
- 3 Ralston SH. The pathogenesis of humoral hypercalcaemia of malignancy. *Lancet* 1987; ii:1443–6.
- 4 Mundy GR. Hypercalcaemia of malignancy revisited. *J Clin Invest* 1988;82:1–6.
- 5 Reitan JB, Kaalhus O, Brennhord IO, Sager EM, Stenwig AE, Talle K. Prognostic factors in liposarcoma. *Cancer* 1985;55:2482–90.

#### Peliosis thymomus: association with tuberculosis

The differentiation between vascular lesions and primary tumours in the mediastinum is of considerable clinical importance.<sup>1</sup> We describe a primary mediastinal tumour (a thymoma) which contained vascular lesions.

A 73 year old retired agricultural worker presented to an orthopaedic department with pain in his neck. Subsequent investigation suggested that he had multiple myeloma

affecting the body of the axis and the skull. He died 10 days after being admitted to hospital. Postmortem examination showed death to have been due to severe bilateral bronchopneumonia; active pulmonary tuberculosis was also evident. Multiple myeloma was confirmed as the correct diagnosis.

An incidental finding was an 80 × 60 × 50 mm tumour with a partially calcified capsule in the anterior mediastinum. On sectioning the tumour showed extensive vascularity and macroscopically it was initially considered to be a teratoma. Histological studies, however, showed it to be an epithelial thymoma containing numerous discrete vascular areas characterised by multiple small cystic blood-filled spaces (figure) lined by endothelial cells.

There is a recognised association between thymoma and myeloma,<sup>2,3</sup> as in the case described above. It is also recognised that thin walled, sometimes dilated, blood vessels are observed in some types of thymoma.<sup>4</sup> In the example described vascular spaces were particularly striking and were reminiscent of the multiple small cystic blood-filled spaces seen in the liver in peliosis hepatitis. Peliosis thymomus is perhaps an appropriate term to describe a similar condition in a thymoma.

There is a known association between peliosis hepatitis and tuberculosis,<sup>5</sup> and it is interesting to note evidence of tuberculosis in our patient. Splenic peliosis has also been described in association with tuberculosis.<sup>6</sup> Review of 14 other examples of thymoma, obtained from various Glasgow and Leeds hospitals, showed no evidence of peliotic lesions. Tuberculosis was not a feature of any of the 14 patients involved.

We propose the term peliosis thymomus to describe multiple, cystic, blood-filled spaces in a thymoma, and we further suggest that such a condition may be associated with tuberculosis, as in peliosis hepatitis.

DJ WILLIAMS\*

RNM MACSWEEN†

Departments of Pathology, \*University of Leeds, Leeds General Infirmary, Leeds LS1 3EX, and †University of Glasgow, Western Infirmary, Glasgow G11 6NT

#### References

- 1 Sabiston DC Jr. Diseases of the pleura, mediastinum and diaphragm. In: Wintrobe MM, Thorn GW, Adams RD, Braunwald E, Isselbacher KJ, Petersdorf RG, eds. *Harrison's principles of internal medicine*. 7th ed. London: McGraw-Hill, 1974:1330.
- 2 Gilbert EF, Harley JB, Anido V, Mengoli HF, Hughes JT. Thymoma, plasma cell myeloma, red cell aplasia and malabsorption syndrome. *Am J Med* 1968;44:820–9.
- 3 Lindstrom FC, Williams RC Jr, Brunning RD. Thymoma associated with multiple myeloma. *Arch Intern Med* 1968;122:526–31.
- 4 Muller-Hermelink HK, Marino M, Palestro G. Pathology of thymic epithelial tumours. In: Muller-Hermelink HK, ed. *The human thymus*. Berlin: Springer-Verlag 1986:230.
- 5 Yanoff M, Rawson AJ. Peliosis hepatitis. An anatomic study with demonstration of two varieties. *Archives of Pathology* 1964;77: 159–65.
- 6 Parsons M, Slater D, Platts M, Fox M. Splenic peliosis associated with rupture in a renal transplant patient. *Postgrad Med J* 1980; 56:796–7.

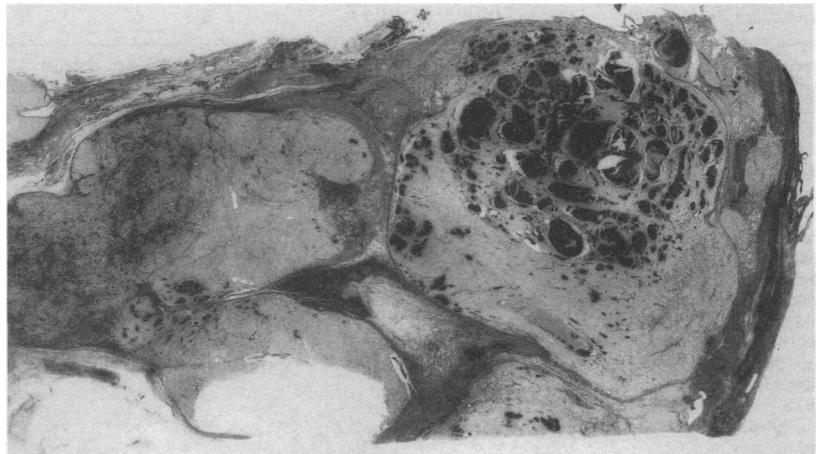


Figure Section of thymoma. Note multiple cystic blood-filled spaces. (Reticulin.)