

Atypical hyperplasia in prostates of 20 to 40 year old men

P N BRAUN,* V O SPEIGHTS,† J U CONTIN,† R J BAYARDO,† D L KUHL*

From the Departments of Anatomic Pathology, *Veterans Administration Medical Center, and †Scott and White Medical Center, Texas A&M University School of Medicine, Temple, Texas, United States of America

SUMMARY One hundred prostates from 20 to 40 year old men obtained at necropsy were completely sectioned and studied microscopically. Atypical hyperplasia was found in 10 (20%) of 20-29 year old men and in 12 (24%) of 30-40 year old men. The prostates with atypical hyperplasia had similar weights as those without, and the atypical hyperplasia was most common in the lateral lobes of the prostate and near the apex. The atypical hyperplasias were (i) usually mild in degree rather than moderate or severe; (ii) almost equally divided between circumscribed and "infiltrating" lesions; (iii) usually occurred as multiple foci within the same prostate rather than as a single focus of atypical hyperplasia; and (iv) were not associated with inflammation.

The finding that atypical hyperplasia is common in men between the ages of 20 and 40 years may be helpful in increasing the understanding of the histopathology of the prostate.

Atypical hyperplasia has been identified in prostates from men under the age of 30.¹ As far as we know there has been no other study in which the prostates of young adult men were completely sectioned to determine the prevalence, location, and other common features of atypical hyperplasia.

Material and methods

Fifty consecutive prostates from 20-29 year old men and 50 from 30-40 year old men were collected from two medical examiner offices and from the necropsy service of a Veterans Administration Hospital. All of the necropsy specimens were collected and studied in accordance with appropriate hospital and state regulations. None of the men, as far as could be determined, was known to have had prostate carcinoma.

The prostates were weighed to include the attached seminal vesicles and a 1 cm margin of bladder at the bladder neck. The prostates were fixed in 10% formalin for at least one week. The prostates were completely sectioned at 3 mm intervals perpendicular to the urethra as had been described by Kastendeick *et al.*² An average of eight complete cross sections were obtained from each prostate. The prostates were processed in the normal way, cut at a thickness of

5 μ m, placed on large slides, stained with haematoxylin and eosin and studied microscopically.

The prostates were divided into the distal, middle and proximal thirds to identify the location of the atypical hyperplasia. The distal third contains the apex of the prostate and, the proximal third the base of the prostate. The prostates were also divided into three roughly equal concentric zones: the central zone adjacent to the urethra; the peripheral zone adjacent to the surgical capsule of the prostate; and the middle zone. The prostates were also divided into posterior, lateral, and anterior lobes.

Atypical hyperplasia has been defined in numerous studies.²⁻⁶ Briefly, it consists of collections of abnormal glands whose precise oncological importance is unknown. It is usually classified as mild, moderate, or severe, depending on the shape and size of the glands (figs 1 and 2). Mild cytological atypia, including nucleoli, may be present in atypical hyperplasia.⁷ The degree of cytological atypia may increase slightly with progression from mild to severe atypical hyperplasia, but the major distinction is the degree of architectural atypia.

Atypical hyperplasia may consist of collections of abnormal glands that are circumscribed or that seem to be "infiltrating". The oncological importance of "infiltrating" glands is difficult to evaluate in an organ in which glands and stroma are normally diffusely blended.⁸ Furthermore, the prostate does not contain obvious "landmarks" such as muscularis mucosae in

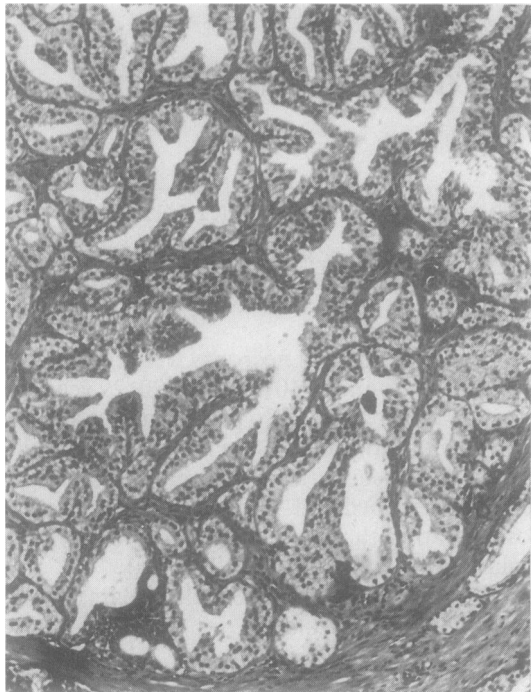


Fig 1 Mild atypical hyperplasia comprising circumscribed nodule containing glands with shapes and sizes that are mildly abnormal. (Haematoxylin and eosin.)

which infiltration or invasion can definitely be established.²

Prostatic lesions designated as intraductal dysplasia⁹ or cribriform hyperplasia¹⁰ were not classified as atypical hyperplasia. Intraductal dysplasia has epithelial proliferation but maintains the normal architecture of the prostate. Cribriform hyperplasia consists of benign glands with a complex intraductal or intraglandular pattern which resembles cribriform prostate carcinoma. Atypical hyperplasia consists of abnormal glands with clearly defined architectural atypia.

Full cross sections of the prostate reduced the possibility of confusing seminal vesicles, periurethral ducts, or fortuitous sectioning with atypical hyperplasia. Lobules superficially resembling atrophy but probably representing a developmental phase of the normal architecture of the prostate are common in young adult prostates.¹

Results

The ethnic origin of the 100 prostates was known in many of the cases: about 50% of the prostates were from caucasians, 30% from hispanics, and 20% from

blacks. Ninety eight of the cases were obtained from medical examiners' offices; the most common causes of death were accidents and homicides. The two remaining cases were from a Veterans Administration Hospital and included a death due to cardiomyopathy and one due to metastatic colon carcinoma.

The characteristics of the atypical hyperplasia are shown in figs 3 and 4. Atypical hyperplasia was found in 10 (20%) of the 20–29 year olds and in 12 (24%) of the 30–40 year olds. Atypical hyperplasia was most common in the distal third of the prostate, in the lateral lobes, and in the middle and peripheral zones. The prostates with atypical hyperplasia usually contained multiple foci rather than a single focus of atypical hyperplasia, which was usually mild, and almost equally divided between circumscribed and "infiltrating" lesions. Inflammation was not a prominent feature.

The 50 prostates from the 20–29 year old age group had an average weight, including seminal vesicles, of 33.5 g (range 15–49 g). The average weight of the 10 prostates with atypical hyperplasia was 34.1 g (range 15–46 g). Those from the 30–40 year old men had an average weight, including seminal vesicles, of 36.3 g (range 13–59 g). The 12 with atypical hyperplasia had an average weight of 37.3 g (range 13–59 g).

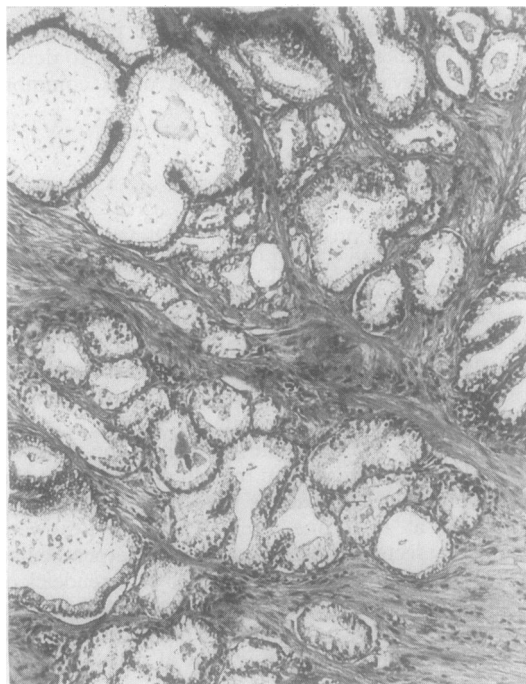
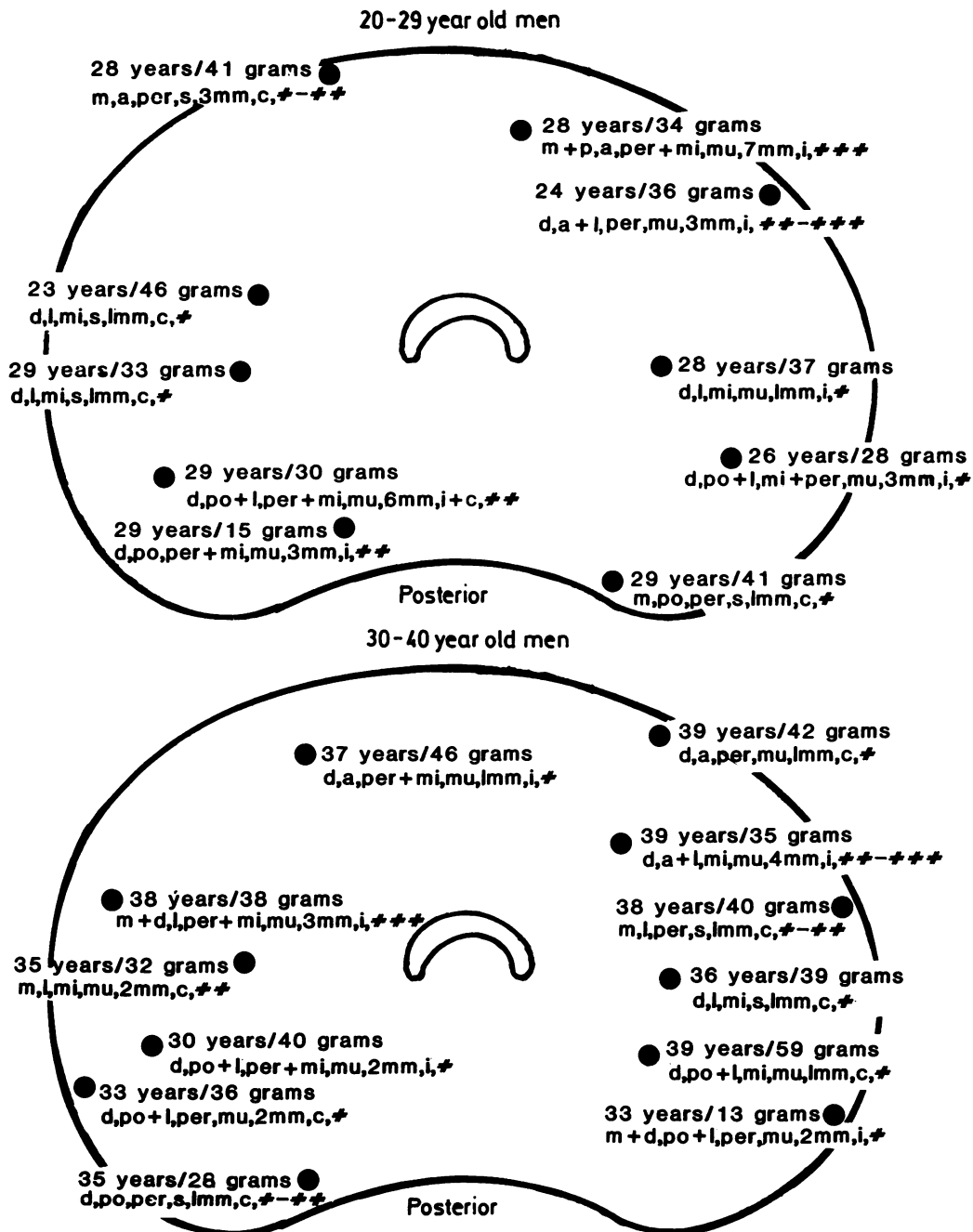


Fig 2 Moderate to severe atypical hyperplasia. The glands are not entirely circumscribed and there is a suggestion of an "infiltrating" pattern. (Haematoxylin and eosin.)



Figs 3 and 4 Diagram of a cross section of the prostate depicting location and other characteristics of atypical hyperplasia in 20-29 year old and in 30-40 year old men.

Top line—age of subject/weight of prostate. Bottom line—d = distal one third of prostate (apex), m = middle one third of prostate, p = proximal one third of prostate (base); a = anterior lobe, l = lateral lobe, po = posterior lobe; per = peripheral concentric zone, mi = middle concentric zone; s = single lesion, mu = multiple lesions; mm = size of the atypical hyperplasia; c = circumscribed, i = infiltrating, # = mild atypical hyperplasia, ## = moderate atypical hyperplasia, ### = severe atypical hyperplasia.

The extent of atypical hyperplasia varied up to 7 mm, but as it could be measured accurately in only two dimensions it was probably an underestimate of the true size. Furthermore, as the prostates were completely sectioned at 3 mm intervals, and many of the atypical hyperplasias were 2 mm or less in size, additional atypical hyperplasias might have been identified with further sectioning of the prostate specimens.

Discussion

Atypical hyperplasia may occur by itself or in association with prostate carcinoma. Helpap found 524 cases of prostate carcinoma in 4300 transurethral resections of prostate, needle biopsy, or total prostatectomy specimens.³ Of the 524 cases, 259 contained atypical hyperplasia, defined as showing numerous histological glandular formations, verging on a carcinomatous pattern, adjacent to the prostate carcinoma. Atypical hyperplasia had occurred without prostate carcinoma in 122 of the 4300 cases. Kastendeick completely sectioned 180 prostates removed for prostate carcinoma.⁴ Atypical hyperplasia was present in 106 of the 180 (58.9%) prostates, and in 67 cases a topographic association was found between atypical hyperplasia and carcinomatous foci.

Gardner and Culberson collected 51 prostates from men aged between 19 and 29 years and studied at least one stained complete cross section of the prostate at the level of the verumontanum. Proliferative changes were identified in 27 of the 51 cases. Three (6%) of the 51 cases (patients aged 19, 22, and 26 years) had at least one area of stromal infiltration by proliferating glands. Each of these areas was accompanied by multiple foci of atypical hyperplasia.

The histological detail of atypical hyperplasia is similar in men under and above the age of 40. The major distinction is that atypical hyperplasia in young adult men is usually an independent lesion while atypical hyperplasia in older men is often seen adjacent to prostate carcinoma. It is difficult to evaluate the oncological importance of this type of atypical hyperplasia as it is not known whether atypical hyperplasia is a precursor, associated feature, or consequence of prostate carcinoma. To assess the oncological importance of atypical hyperplasia in 20–40 year old men long term follow up and other

appropriate investigations are necessary. These studies may indicate that some atypical hyperplasias in 20–40 year old men are, in fact, prostate carcinomas, or that some are premalignant with a significant likelihood of developing into prostate carcinoma, or that other areas of the prostate are at increased risk of malignant transformation, or, indeed, that some have little or no oncological importance. At present, it seems prudent to regard atypical hyperplasia in 20–40 year old men as of undetermined oncological importance.

We thank medical photographers Robert McEachern and Bobby Poff and medical illustrator Gordon Purser of the Texas A&M University School of Medicine, Veterans Administration Medical Center, Temple, Texas for providing the photomicrographs and illustrations for this study.

References

- 1 Gardner WA Jr, Culberson DE. Atrophy and proliferation in the young adult prostate. *J Urol* 1987;137:53–6.
- 2 Kastendeick H, Altenahr E, Husselmann H, Bressel M. Carcinoma and dysplastic lesions of the prostate. *Z Krebsforsch* 1976;88:33–54.
- 3 Helpap B. The biological significance of atypical hyperplasia of the prostate. *Virchows Arch A (Pathol Anat)* 1980;387:307–17.
- 4 Kastendeick H. Correlation between atypical primary hyperplasia and carcinoma of the prostate. *Pathol Res Pract* 1980;169:366–87.
- 5 Brawn PN. Adenosis of the prostate. A dysplastic lesion that can be confused with prostate adenocarcinoma. *Cancer* 1982;49:826–33.
- 6 McNeal JE. Age related changes in prostatic epithelium associated with carcinoma. In: Griffiths K, Pierrepoint G, eds. *Some aspects of the aetiology and biochemistry of prostatic cancer*. Cardiff, Wales: Alpha Omega Alpha Publishing Co, 1970: 23–32.
- 7 Helpap B. Observations on the number, size and localization of nucleoli in hyperplastic and neoplastic prostatic disease. *Histopathology* 1988;13:203–11.
- 8 Franks LM. Latent carcinoma of the prostate. *J Pathol Bacteriol* 1954;68:603–16.
- 9 McNeal JE, Bostwick DG. Intraductal dysplasia: a premalignant lesion of the prostate. *Hum Pathol* 1986;17:64–71.
- 10 Ayala AG, Srigley JR, Ro JY, Abdul-Karim FW, Johnson DE. Clear cell cribriform hyperplasia of the prostate. *Am J Surg Pathol* 1986;10:665–71.

Requests for reprints to: Dr Peter N Brawn, Chief of Anatomic Pathology, Veterans Administration Medical Center, Texas A&M University School of Medicine, Temple, Texas 76501, USA.