

most common route nowadays is by bacteraemic infection of pre-existing aneurysms or other lesions.<sup>3</sup> Organisms have been grown more frequently from the contents of perforated rather than from electively resected aortic aneurysms, which suggests that infection may be an important predisposing factor to rupture,<sup>4</sup> but in many case reports it has been impossible to tell whether the aorta was aneurysmal before infection occurred.

The source of the *Haemophilus influenzae* in this case is unknown. Presumably there was bacteraemic seeding of an atheromatous lesion in the patient's undilated aorta, which progressed to perforation of the arterial wall. This may have been encouraged by steroids. A normal abdominal computed tomography scan should not exclude the diagnosis of infective aortitis.

G BYRNE,  
P BARBER,  
M FARRINGTON

Departments of Medicine, Histopathology,  
and Clinical Microbiology  
and Public Health Laboratory,  
Addenbrooke's Hospital, Hills Road,  
Cambridge.

#### References

- Dall L, Barnes WG, Gibbs HR, Nohinek B, Zee-Cheng C. Endocarditis caused by beta-lactamase-producing *Haemophilus influenzae*. *Southern Med J* 1987;80:405-6.
- Powell M, Koutsia-Carouzou C, Voutsinas D, Seymour A, Williams JD. Resistance of clinical isolates of *Haemophilus influenzae* in United Kingdom 1986. *Br Med J* 1987;295:176-9.
- Ewart JM, Burke ML, Bunt TJ. Spontaneous abdominal aortic infections. Essentials of diagnosis and management. *Am Surg* 1983;49:37-50.
- Buckels JAC, Fielding JWL, Black J, Ashton F, Slaney G. Significance of positive bacterial cultures from aortic aneurysm contents. *Br J Surg* 1983;72:440-2.

thelium. It was therefore suggested that immune mediated mechanisms may be responsible for the thrombocytopenia,<sup>4</sup> and we report a case in support of this hypothesis.

#### Case report

A 52 year old man, who had been in close contact with vermin, was admitted with a typical history of frontal headaches, rigors, myalgia and increasing jaundice. Initial investigations showed renal impairment (serum urea 20.3 mmol/l, normal range 4-8; serum creatinine 400  $\mu$ mol/l, normal <110), and thrombocytopenia (platelet count  $45 \times 10^9$ /l, normal range  $150-350 \times 10^9$ /l). Treatment with benzyl penicillin was begun (1.2 g six hourly) and continued for 10 days, during which time the diagnosis was confirmed with increasing titres for leptospira icterohaemorrhagica (complement fixation test from 1/10 to 1/1280 and microcopic agglutination test from 1/80 to 1/2560).

He developed anuric renal failure and became mildly confused. Following haemodialysis, he became comatose, a computed tomogram of the brain suggested cerebral oedema and he was electively hyperventilated. His renal failure was managed with continuous haemofiltration. Porcine heparin was used as the anticoagulant, the infusion rate titrated to achieve whole blood clotting times of 100-140 s with a thrombotest reaction (median heparin dose 1000 IU/hour).

A lumbar puncture showed both an increased total protein concentration of 90 mg/dl (normal <4) and an IgG to albumin

ratio of 32% (normal <16%). Tests for serum immune complexes were also positive (polyethylene glycol extraction 20%, normal <4%). A trial of pulsed methyl prednisolone was therefore started.

He had remained thrombocytopenic since admission and the platelet count had fallen to below  $20 \times 10^9$ /l despite the transfusion of 24 units of platelets (figure). Bone marrow examination showed an active marrow with plentiful megakaryocytes, Coombs' tests were negative as was a screen for disseminated intravascular coagulation. Platelet antibodies were sought before administration of steroids, and these were positive for both IgG at 740 ng/ $10^6$  platelets (normal 2-10 ng/ $10^6$  platelets) and IgM at 333 ng/ $10^6$  platelets (normal <2.5 ng/ $10^6$  platelets). C3d was also bound to the platelet surface at 40 ng/ $10^6$  platelets (normal <3.3 ng/ $10^6$  platelets).

The peripheral platelet count responded to four daily doses of 1 g methyl prednisolone and fell again when the steroids were stopped. Further treatment with hydrocortisone (50 mg six hourly) was associated with both an increase in platelet count and an improvement in consciousness.

Platelet antibody titres were repeated on discharge from the intensive care unit when the peripheral platelet count was in the normal range at  $150 \times 10^9$ /l. All titres had fallen: IgG to 74 ng/ $10^6$  platelets, IgM to 26 ng/ $10^6$  platelets, and C3d to 5.5 ng/ $10^6$  platelets, and no circulating immune complexes were detected.

This case supports the role of immune mediated platelet destruction as the cause of

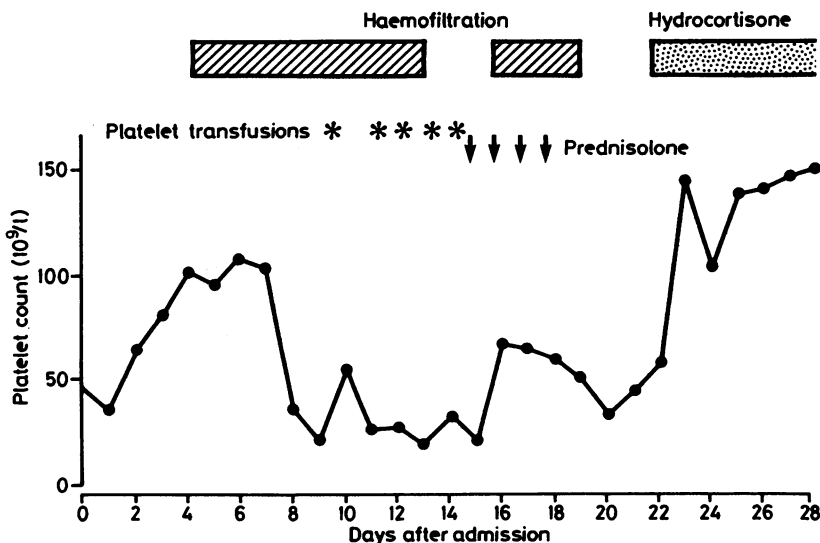


Figure Platelet count during admission showing response to steroids.

#### Is thrombocytopenia seen in patients with leptospirosis immunologically mediated?

Thrombocytopenia is a complication of severe leptospiral infection.<sup>1</sup> Initially it was suggested that thrombocytopenia developed following platelet activation at the sites of endothelial damage, resulting in a disseminated intravascular coagulopathy,<sup>2</sup> but more recent studies have failed to support this theory.<sup>3</sup> Infection with leptospirosis results in an initial septicaemic phase followed by a later immunological phase associated with widespread damage to the vascular endo-

thrombocytopenia in severe leptospirosis, as shown by the high titres of surface bound immunoglobulin and C3d, the response to both pulse methyl prednisolone and hydrocortisone, and the prompt fall in platelet count after discontinuing the methyl prednisolone. Although both penicillin and heparin have been reported to cause immune mediated thrombocytopenia, the patient was thrombocytopenic before taking either drug, and both dose of heparin used and the time course of the thrombocytopenia argue against a drug mediated thrombocytopenia.<sup>5</sup>

A DAVENPORT\*

FP RUGMAN†

MJ DESMOND‡

R GANTA‡

Departments of \*Renal Medicine,  
†Haematology, and ‡Intensive Care,  
Royal Liverpool Hospital,  
Prescot Street,  
Liverpool L7 8XP.

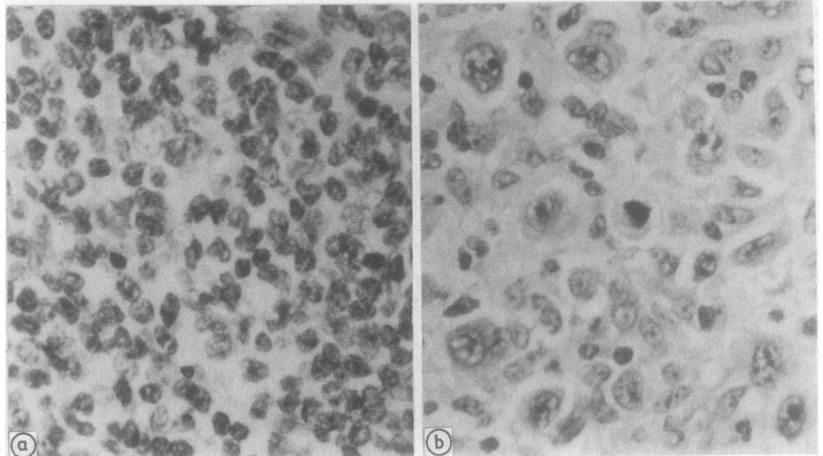


Figure (a) Nodule from right thigh. Sections show a follicular centroblastic-centrocytic non-Hodgkin's lymphoma. (b) Inguinal lymph node. Sections show lymphocyte depleted Hodgkin's disease.

#### References

- 1 Edwards CN, Nicholson GD, Everard COR. Thrombocytopenia in leptospirosis. *Am J Trop Med Hyg* 1982;31:827-9.
- 2 Sitprija V, Pipatanagul V, Mertowidojojo K, *et al.* Pathogenesis of renal disease in leptospirosis: clinical and experimental studies. *Kidney Int* 1980;17:827-31.
- 3 Edwards CN, Nicholson GD, Hassell TA, *et al.* Thrombocytopenia in leptospirosis; the absence of evidence for disseminated intravascular coagulation. *Am J Trop Med Hyg* 1986;35:352-4.
- 4 Kahn JB. A case of Weil's disease requiring steroid therapy for thrombocytopenia and bleeding. *Am J Trop Med Hyg* 1982;31:1213-15.
- 5 Berndt MC, Castaldia PA. Drug mediated thrombocytopenia. *Blood Review* 1987;1:111-18.

#### Non-Hodgkin's lymphoma and Hodgkin's lymphoma in the same patient

A 66 year old white man was referred with a subcutaneous swelling behind the right mid-thigh that had been present for one year. The indurated and oedematous swelling was resected. Histological assessment showed that it was non-Hodgkin's lymphoma (NHL)—small lymphocyte type (fig 1a). There was no evidence of lymphoma elsewhere. Peripheral blood cell marker tests showed no conclusive evidence of monoclonal B cells. No other treatment was given; he was followed up three monthly. After 14 months of good health he reported with a four week history of severe diarrhoea,

anorexia, and weight loss. He was dehydrated and had an upper abdominal mass separate from an enlarged spleen and a mass of enlarged lymph nodes in the right iliac fossa. The right leg was oedematous. An ultrasound scan showed infiltration in the liver and para-aortic, mesenteric, and pelvic adenopathy. The only laboratory abnormalities were a normocytic anaemia of 8.6 g/dl with an erythrocyte sedimentation rate (ESR) of 92 mm in one hour, hypoalbuminaemia, and a grossly raised alkaline phosphatase activity. There was variable expression of T cell receptors on peripheral blood mononuclear cells with a CD4:CD8 ratio of 1 and increased expression of CD25. There was no evidence of B cell monoclonality.

Surprisingly, a node biopsy specimen showed a typical picture of lymphocyte depleted Hodgkin's disease (HD) (fig 1b). After chemotherapy there was no detectable bulk disease at three months. Repeated endoscopic biopsy specimens have shown chronic inflammatory changes only and his bowel symptoms slowly resolved. He remains on follow up one year later.

The term discordant lymphoma has been reserved for those cases with different histological types occurring in different anatomical sites. Kim *et al* used the term composite lymphoma to include those cases with both Hodgkin's disease and non-Hodgkin's lymphoma within a single anatomical site.<sup>1</sup> Patients with discordant lymphoma with HD and NHL are well recognised, most often with NHL following treatment for Hodgkin's disease. Carrato *et*

*al* found five instances of Hodgkin's disease developing after treatment for NHL from 2019 documented lymphoma cases with a latent period of between five to 23 years.<sup>2</sup> Lymphocyte depleted Hodgkin's disease was not found in this group. The pathogenesis of Hodgkin's disease is unclear and both T and B cells have been implicated by various workers. A proliferation of B cells which might provoke a T cell reaction eventually predisposing to Hodgkin's disease has been reported<sup>3</sup> in cases of nodular Hodgkin's paraneoplasms, but our case was firmly diagnosed as NHL. Viral infection causing a change in T cell surface antigen expression may produce a chronic immune reaction leading to the appearance of neoplastic reticulum cells.<sup>4</sup> We found variability of T cell antigen expression, evidence of interleukin 2 receptor expression, and disturbance of the CD4:CD8 ratio during the second illness which may have been due to immunological response to the disease rather than a residual feature of a T cell reaction before the development of Hodgkin's disease. It is difficult to ascribe the development of Hodgkin's disease after treated NHL to the treatment itself because many more cases would be expected. It is even less common to find this sequence of events without intervening treatment. In this unusual case it seems that either the appearance of the two disorders was purely coincidental or that the lesion with clear features of NHL represented a stage in the development of the eventual Hodgkin's disease. It was interesting to find that the only peripheral nodal disease at the presentation of Hodgkin's disease was in the