

Letters to the Editor

Pathology of the spleen in large granular lymphocyte leukaemia

Large granular lymphocyte (LGL) leukaemia is an uncommon disorder characterised by clonal expansion of large granular lymphocyte subsets in bone marrow, spleen, and peripheral blood.¹ We describe an analysis of the spleen from a 56 year old woman with LGL leukaemia which shows a pattern of LGL accumulation that seems to be characteristic of this disorder and therefore of potential diagnostic value.

The presenting clinical features described previously² included anaemia—haemoglobin 9.4 g/dl and a white cell count $15.1 \times 10^9/l$ with a differential of neutrophils 14%, monocytes 4%, lymphocytes 82% (95% large granular type). The lymphocytes showed a CD2 + CD3 + CD8 + Leu7 + CD11b - CD16 - surface antigen phenotype. Within 12 months the haemoglobin concentration fell to 6.6 g/dl and the patient had to be transfused regularly. Her spleen was removed which resulted in an initial improvement of the anaemia followed by relapse (haemoglobin 7.0 g/dl, white cell count $70 \times 10^9/l$). Subsequent treatment with cyclophosphamide (100 mg/day) improved and stabilised the haematological indices (haemoglobin 11.5 g/dl, white cell count $8.0 \times 10^9/l$).

The spleen weighed 520 g, the cut surface showed even distribution of multiple, pale nodules about 1 mm in diameter. Microscopically the splenic architecture was preserved, the white pulp was increased, and as well as apparently normal peri-arteriolar lymphocyte cuffs, there were many germinal follicles. The red pulp showed a homogeneous infiltration of sinusoids and cords by small, apparently mature lymphocytes. The few previous reports of the morphological detail of the spleen in LGL leukaemia

also noted red pulp infiltration by lymphocytes, together with white pulp preservation, including prominent germinal follicles,^{3,5} suggesting that this histological pattern is highly characteristic. Comparison with the splenic histology in other lymphoproliferative disorders indicates clear differences that may be of value in the differential diagnosis: in B cell chronic lymphocytic leukaemia and well differentiated B cell lymphomas the white pulp is usually infiltrated, whereas in conditions with red pulp infiltration—for example, hairy cell leukaemia—usually atrophy or obliteration of the white pulp occurs.

The immunohistochemical staining reactions of the various splenic zones are shown in the table. The normal white pulp populations of small lymphocytes were preserved, there was no white pulp infiltration by LGL phenotype cells. The phenotype of lymphocytes infiltrating the red pulp was characteristic of LGLs, although it differed from the circulating cells by the possession of the CD16 marker corresponding to the IgFc gamma receptor. A similar difference in IgFc gamma receptor expression between splenic and blood LGLs has also been noted in a previous case.⁵ The reason for this discrepancy is unclear but is unlikely to be due to selective accumulation of CD16+ cells in the spleen as we were not able to show any increase in circulating CD16+ cells after removal of the spleen.

Although most cases of LGL leukaemia are now diagnosed by circulating cell surface antigens, some may still be diagnosed only when the spleen is removed, as at presentation 50% have splenomegaly and 30% do not have a lymphocytosis.¹ Recognition of the characteristic histological pattern of splenic disease described here should expedite confirmation of the diagnosis by the appropriate lymphocyte marker studies.

DFR GRIFFITHS,
B JASANI,
GR STANDEN*

References

- Loughran TP, Starkebaum G. Large granular lymphocyte leukaemia, report of 38 cases and review of the literature. *Medicine* 1987;66:397-405.
- Standen GR, Masters G, Pill R, Matthews N, Booth M, Baines P. Production of haemopoietic growth factors and gamma interferon by large granular lymphocytes from patients with T-gamma lymphocytosis. *Int J Cell Cloning* 1987;5:302-14.
- Thien SL, Catovsky D, Oscier D, et al. T-chronic lymphocytic leukaemia presenting as primary hypogammaglobinaemia—evidence of a proliferation of T-suppressor cells. *Clin Exp Immunol* 1982;47:670-6.
- Brisbane JU, Berman LD, Osband ME, Neiman RS. T8 chronic lymphocytic leukaemia, a distinctive disorder related to T8 lymphocytosis. *Am J Clin Pathol* 1983;80:391-6.
- Loughran TP, Kadin ME, Starkebaum G, et al. Leukaemia of large granular lymphocytes: association with clonal chromosomal abnormalities and autoimmune neutropenia, thrombocytopenia, and haemolytic anaemia. *Ann Intern Med* 1985;102:169-75.

Diagnosis of intestinal microsporidiosis in patients with AIDS

Microsporidia are tiny protozoal parasites of the phylum Microspora.¹ The only species yet recognised in human enterocytes is *Enterocytozoon bienersi*^{1,2} and diagnosis is difficult. Most identifications have been made at electron microscopy.^{2,4} Previous reports, however, have indicated that they are visible in sections stained with haematoxylin and eosin.^{5,6}

Table Results of immunoperoxidase studies on frozen sections, paraffin wax embedded tissue sections* and cytospin smears† derived from enriched LGL suspensions on which FACS analysis‡ was performed

| | Leu7 | CD3 | CD4 | CD5 | CD8 | CD16 | CD19 | CD45 | CD45* | CD45RT* | L26* |
|--------------------------|------|-----|-----|-----|-----|------|------|------|-------|---------|------|
| White pulp | | | | | | | | | | | |
| Periarteriolar zone | + | - | +++ | +++ | ++ | - | - | +++ | +++ | - | - |
| B cell zone | | | | | | | | | | | |
| Germinal centre | + | - | ++ | + | + | - | +++ | +++ | ++ | - | +++ |
| Mantle zone | - | - | + | + | + | - | +++ | +++ | +++ | + | +++ |
| Marginal zone | - | - | ++ | ++ | + | - | + | +++ | +++ | - | ++ |
| Red pulp | +++ | +++ | + | + | +++ | +++ | - | +++ | + | - | + |
| Circulating LGLs† | ++ | +++ | + | + | +++ | - | | | | | |
| Circulating LGLs‡ (FACS) | 63% | 93% | 13% | | 72% | 7% | | | | | |

Semi-quantitative scoring: - = absent; + = <5%; ++ = 5%-50%; +++ = more than 50% of cells positive for the marker.

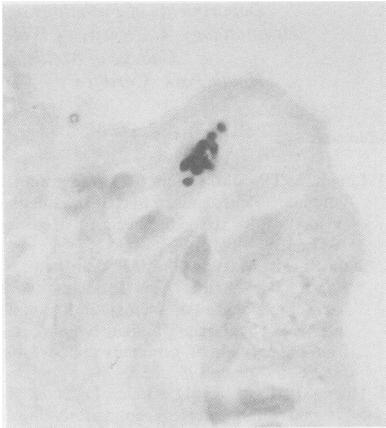


Fig 1 Duodenal enterocyte containing eight supranuclear microsporidium spores. (Brown-Brenn Gram stain.)

We have been examining endoscopic duodenal or Crosby capsule jejunal biopsy specimens since 1985 from 77 HIV-1 seropositive African patients in Kampala, Uganda, and Lusaka, Zambia, who had the chronic diarrhoea and wasting ("slim" syndrome) which is characteristic of AIDS in Africa. Nearly half these patients had *Cryptosporidium* or *Isoospora belli* infections which had been identified by faecal smear (modified Ziehl-Neelsen technique) or histopathological assessment⁷ (Lucas, Conlon, unpublished observations).

The specimens were formalin fixed, processed to paraffin wax, and serial sections were stained with haematoxylin and eosin, periodic acid Schiff, Ziehl-Neelsen and Brown-Brenn Gram stain (some microsporidial forms are Gram positive⁸). Three

duodenal and two jejunal biopsy specimens showed microsporidia.

In small numbers of surface enterocytes supranuclear clusters of 1–2 μm diameter bodies were seen, usually four to ten in each cell. Brown-Brenn Gram stain showed that they were round or oval, and polar with blue and red staining ends, standing out clearly from the yellow background colour (fig 1). In the sections stained with haematoxylin and eosin the bodies were refractile with clear cytoplasm and a basophilic nucleus, particularly well seen when viewed at high magnification with the substage condenser removed (fig 2). Material from three of these cases was deparaffinised and reprocessed into Araldite for electron microscopic examination. Two showed probable microsporidial spores in semithin sections (stained with toluidine blue) and at transmission electron microscopy (but were too poorly preserved). One case had clearly visible spores in the semithin sections (fig 3) and identifiable microsporidia by electron microscopy (fig 4). The size (1 \times 0.6 μm), position of the nucleus, and polar filament coils confirmed that it was a microsporidium, and that it was consistent with *Enterocytozoon bieneusi*. No spores were periodic acid Schiff or Ziehl-Neelsen positive.

Cases of intestinal microsporidia may therefore be confidently identified by light microscopic examination, supplemented by electron microscopy, even though the material is imperfectly fixed and processed for electron microscopy. The larger forms (sporonts) of *E. bieneusi* are less distinct in haematoxylin and eosin and Gram stains than spores. We have now found that the haematoxylin and eosin stain alone suffices to detect spores. Differential diagnosis from *Cryptosporidium* is straightforward as those

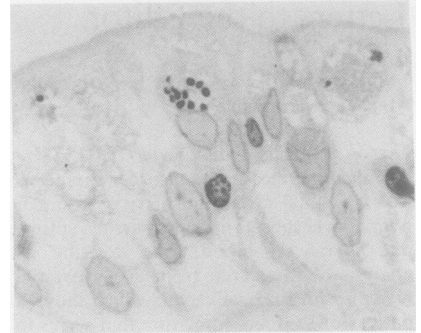

Fig 3 Duodenal biopsy specimen: semithin section showing microsporidia. (Toluidine blue.)

parasites are seen on the luminal surface of enterocytes. The various intra-enterocyte life cycle stages of *Isoospora belli* and *Sarcocystis* spp may be confused with those of microsporidia. They are larger parasites, however, seen as schizonts (with elongated zoites in late stages) or gametes (with radially arranged nuclei⁹), and are often periodic acid Schiff positive. Both isosporiasis and sarcocystosis are more readily detected in faecal smears by their characteristic oocysts than by biopsy. Dab smears of distal duodenal biopsy specimens stained with Giemsa may show spores of microsporidia even more

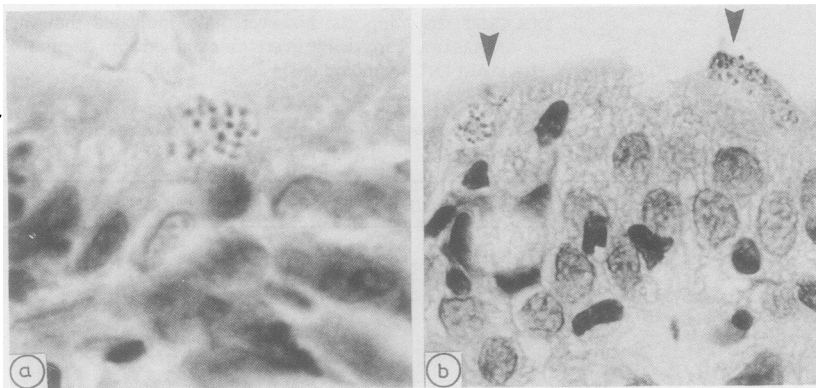


Fig 2 Duodenal enterocytes with supranuclear refractile spores containing distinct nuclei. (Haematoxylin and eosin.)

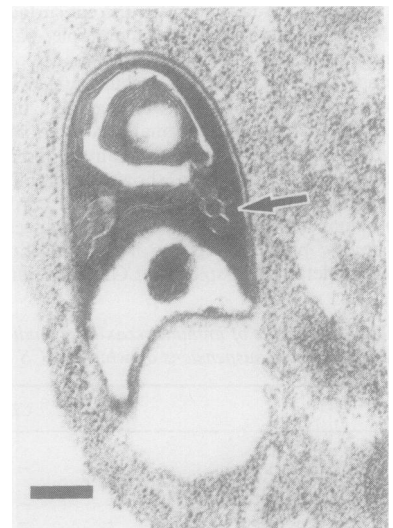


Fig 4 Electron photomicrograph of microsporidium spore showing cross sections of polar filaments (arrowhead) and nucleus; consistent with *E. bieneusi*. Bar = 200 nm.

readily than microscopical examination of processed tissue,⁶ but this has not been systematically tested.

These five cases of microsporidia represent 6.5% of the African HIV positive patients with intestinal symptoms that we saw. Three of the patients also had cryptosporidiosis (diagnosed on faecal smears, though not seen on histological examination). Irrespective of the degree of inflammation, no microsporidia have been identified in 36 small bowel biopsy specimens from HIV negative Ugandan and Zambian controls; no microsporidia have been seen in over 50 rectal biopsy specimens from HIV negative or HIV positive patients.

More intestinal biopsy specimens from patients with AIDS should be examined for microsporidia. This group of parasites infects most phyla of invertebrates and all classes of vertebrates; yet *E bienewisi* has only been described in human enterocytes in association with HIV-1 infection.¹ It is unresolved whether they are genuine pathogens rather than mere passengers. The enterocytes containing microsporidia in our material and that of other workers do not show obvious damage by light or electron microscopy. The aetiology of the diarrhoea in AIDS is multifactorial, and microsporidia may be involved, possibly by affecting secretion.

SB LUCAS*
LUCIENNE PAPADAKI*
C CONLON†
N SEWANKAMBO‡
R GOODGAME‡
D SERWADDA‡

*Department of Histopathology, University College and Middlesex Hospital School of Medicine, University Street, London WC1

†Department of Medicine, University Teaching Hospital, Lusaka, Zambia,

‡Department of Medicine, Mulago Hospital, Kampala, Uganda.

References

- 1 Canning EU, Hollister WS. Microsporidia of mammals—widespread pathogens or opportunistic curiosities? *Parasitol Today* 1987;3:267-72.
- 2 Desportes L, Le Charpentier Y, Galian A, et al. Occurrence of a new microsporidian: *Enterocytozoon bienewisi* n.g., n.sp., in the enterocytes of a human patient with AIDS. *J Protozool* 1985;32:250-4.
- 3 Dobbins WO, Weinstein WM. Electron microscopy of the intestine and rectum in acquired immunodeficiency syndrome. *Gastroenterol* 1985;88:738-49.
- 4 Curry A, McWilliam LJ, Haboubi NY, Mandal BK. Microsporidiosis in a British patient with AIDS. *J Clin Pathol* 1988;41:477-8.

- 5 Modigliani R, Borles C, Le Charpentier Y, et al. Diarrhoea and malabsorption in acquired immunodeficiency syndrome: a study of four cases with special emphasis on opportunistic protozoal infestations. *Gut* 1985;26:179-87.
- 6 Rijpstra AC, Canning EU, van Ketel, RJ, et al. Use of light microscopy to diagnose small-intestinal microsporidiosis in patients with AIDS. *J Infect Dis* 1988;157:827-31.
- 7 Sewankambo N, Goodgame R, Carswell WJ, et al. Enteropathic AIDS in Uganda: a microbiological and histopathological study. *AIDS* 1987;1:9-13.
- 8 Nicholls G. Microsporidiosis in AIDS. *Communicable Diseases Report CDR* 86/21. London: PHLS, 1986:3-4.
- 9 Brandborg LL, Goldberg SB, Breidenbach WC. Human coccidiosis—a possible cause of malabsorption. The life cycle in small-bowel biopsies as a diagnostic feature. *N Engl J Med* 1970;283:1306-13.

Visual aid for quick assessment of coronary artery stenosis at necropsy

A chart was designed to give a quick visual assessment of the degree of coronary artery stenosis at necropsy. It was intended for routine cases in which coronary artery angiography and formal morphometric analysis of processed segments of vessel were not to be undertaken. The method described here is not the most accurate, but it is preferable to simple subjective categorisation into simple, moderate, and severe degrees of artery stenosis.

Ischaemic heart disease is one of the leading causes of death in Great Britain. Quantification of coronary artery stenosis as part of the necropsy is necessary to estimate the functional importance of any atherosclerotic disease present. The cross sectional area of the vessel lumen, compared with that contained within the elastic lamina, expressed as a percentage, is a widely used method of estimating the degree of luminal area narrowing within a vessel.¹ A narrowing by 75% reduces coronary blood flow at times of stress and exertion; narrowing by 90% means that coronary blood flow is severely reduced at rest.² Even in the absence of coronary thrombosis, cardiac death may occur if there is one segment of luminal area which has narrowed by more than 85%, although most of these patients have multiple foci of stenosis.³

Coronary angiography can be used routinely at necropsy⁴ to show the luminal diameter and it can also show all branches of the coronary vessels. Formal morphometry with the use of either point counting,⁵ or plan-

imetry of multiple cross sections of vessels that have been fixed, decalcified, and stained for elastin, give a good estimation of luminal area narrowing. Vessels that have been perfused and fixed at physiological pressures before dissection give the most meaningful results.⁶ An alternative, but the most routinely used method, is simple subjective assessment of a serially sliced vessel at the time of necropsy into categories of mild, moderate, and severe stenosis.

The first two methods are obviously more accurate, and the merits and demerits of each have been discussed elsewhere.⁷ The aim of our method is not to replace or compete with these methods but to make simple, immediate, subjective assessment more accurate and scientific.

Examination of coronary arteries by serial transverse slicing at 3 mm intervals is widely practised. Most pathologists open the heart first and then slice the vessels while gripping the artery, with forefinger outside the heart and thumb inside. A sharp brain knife allows a "clean slice" to be made even with moderate vessel calcification.

Once the vessels have been serially sliced, the cut surface is compared with the chart (figure). The vessels have been drawn with concentric round, eccentric round, and slit shaped lumina representing the three main patterns seen at necropsy. The diagrams have been photoreduced following the calculation of the areas on graph paper. Arteries that are distended at physiological pressure are almost circular in shape.¹ The

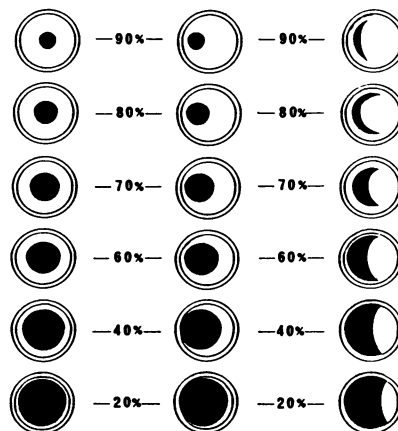


Figure Schematic diagram representing a percentage reduction in cross sectional area of coronary artery vessels. The outer circle represents vessel exterior, inner circle represents the elastic lamina, and black area represents the lumen.