

THE BRITISH JOURNAL
OF
OPHTHALMOLOGY

DECEMBER, 1937

COMMUNICATIONS

EXFOLIATION OF THE SUPERFICIAL LAYER
OF THE LENS CAPSULE (VOGT) AND ITS
RELATION TO GLAUCOMA SIMPLEX*

BY

EIVIND HÖRVEN

FROM THE OPHTHALMIC SECTION OF THE UNIVERSITY CLINIC
IN OSLO. CHIEF: PROFESSOR HAGEN

My former chief, Professor Hagen, has asked me to give an account of my investigations respecting exfoliation of the superficial layer of the lens capsule and its relation to glaucoma simplex, and I feel deeply thankful for the honour thus shown me. Meanwhile I fear that much of what I have to say is already well known to my hearers, and therefore perhaps of little interest.

It was in 1925 that the Swiss author, Vogt, described the disease to which he later gave the name "Exfoliatio superficialis capsulae anterioris," in which we see a round, grayish-white disc on the surface of the lens in the pupillary area ("Pupillarscheibe"). Outside this there is a part where the capsule seems normal, and then comes in the periphery a ribbon-shaped, denticulated, whitish portion resembling a coronet. Besides these changes there are seen in nearly all cases scurf-like flakes on the pupillary border.

* Paper read before members of the North of England Ophthalmological Society in Oslo, June 6, 1937. Published in *Acta Ophthalm.*, Vol. XIV, 1936.

Vogt had already in 1921 depicted this condition in his "Atlas der Spaltlampenmikroskopie," but he then mistook it for a remnant of the pupillary membrane. The flakes on the pupillary border and the central disc on the surface of the lens he described in 1923, and then regarded them, with doubt, as an exudate resulting from an operation the patient had undergone.

In Scandinavian literature these flakes on the pupillary border had been described by the Finnish writer Lindberg in 1917, and the change on the capsular surface by the Norwegian Malling in 1923, but neither of these works aroused any attention and they are not mentioned by the authors who have later dealt with the subject.

Since Vogt's first description some 40 or 50 papers on the disease have been published, and I shall now try to give an account of these and of my own investigations.

In English literature the subject has received little attention. In 1932 Sohby Bey published in the *Brit. Jl. of Ophthalm.* a "Contribution to the study of Exfoliation of the Lens Capsule or Glaucoma capsulo-cuticulare, with anatomical preparations," and John Foster described a case of glaucoma capsulo-cuticulare in 1933.

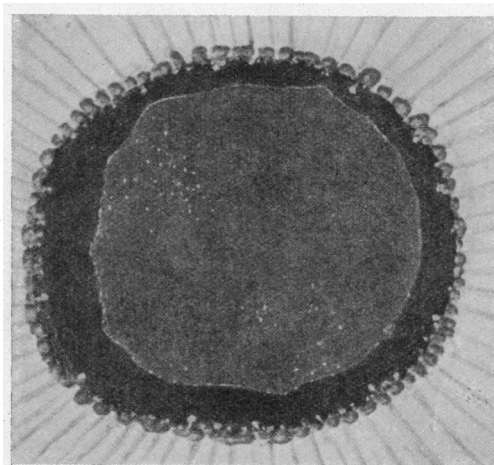
The clinical picture of the exfoliation comprises: (1) the flakes on the pupillary border, (2) the central disc and the peripheral band on the lens capsule and (3) changes in the zonule of Zinn, to which I shall revert later.

The flakes on the pupillary border resemble very small particles of scurf, situated on the pigment epithelium. They are never seen on the iris stroma itself, even when the stroma is dark in colour, so that the white particles should be easily visible. On the other hand, they can be seen on the posterior surface of the cornea, and where we have remnants of the pupillary membrane they can be seen lying close together on the fibres, like rime on a telegraph wire. They are constantly changing in number, some disappearing, others coming instead, and after an operation they may disappear altogether. They must therefore be assumed to lie quite loosely attached to the iris. If the patient is subjected to iridectomy, there may be seen immediately after the operation dense masses of these flakes on the pigment epithelium along the coloboma edge. This would seem to indicate that they had been there also before the operation and gives reason to believe that they are as a rule to be found dispersed over the whole of the pigment epithelium in the posterior chamber.

These flakes never occur as an isolated phenomenon. They appear only together with a change in the lens capsule. They are therefore considered to be of secondary character, having originated from the surface of the capsule and having detached

themselves spontaneously or been rubbed off during the movements of the pupil and afterwards depositing themselves on the pupillary border.

The central disc on the anterior surface of the lens has the shape and size of the pupil. Vogt has been able to show that it decreases in size when the patient is treated for some time with miotics, and he therefore believes that its size corresponds to the minimum dilatation of the pupil. The disc is always of uniform structure, in contrast to the peripheral band, which is usually granulated, and the reason for this difference in structure is

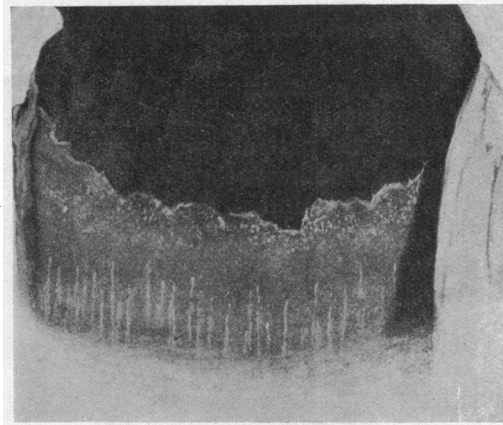


Vogt: 1923.

unknown. In some cases the disc may be very difficult to see, showing itself only as a faint milky fleck without sharply marked boundary. It can then be most easily seen when the beam of light is directed tangentially upon the surface of the lens. In other cases it is conspicuous, with a clearly defined edge, which is often curled up.

Outside the disc comes an area where the lens capsule appears quite normal, but very often one or more bridges stretch across this area from the disc to the peripheral band, these bridges being then of granular structure.

The peripheral band is the most prominent feature of the changes in the lens capsule and is therefore the most easily seen. Mostly it lies in the outer third of the distance from the anterior pole of the lens to the equator, but it may also be situated nearer to the centre or quite on the periphery. The width of the band may vary, being in some cases very narrow, in others broad.



Vogt: In the area of a coloboma.

The boundary towards the equator may assume two different forms: either it is quite indefinite, so that the band with uniformly decreasing distinctness merges into a capsule of normal appearance, or else it is clearly visible and is then in almost all cases denticulated, the projections having an exactly radial direction and being often high, narrow and strikingly regular. The cause of these peripheral projections is not known. Vogt asks whether they might not possibly have some relation to the attachment of the suspensory ligament. No curling up or exfoliation of the equatorial border has ever been observed.

In almost all cases the distinctness of the band increases uniformly from the equator towards the axial edge. This latter is always sharply defined and in form either curved or undulating or else denticulate, the projections then being radially directed, but according to my experience never so high or regular as the peripheral projections. These projections are by Vogt and Busacca believed to be due to the configuration of the posterior surface of the iris. The axial border may be smooth, but a smaller or larger part thereof is often loosened and curled up.

In some particular cases we see within the axial border another, considerably less conspicuous band, composed of very small granulations, which seems to lie deeper in the capsule than the peripheral band itself. It gives the impression of being of newer origin than the more peripherally situated one, and Vogt and others regard this as representing a new degeneration of the lens capsule at a place where the earlier exfoliation has been scraped away.

The peripheral band is invariably present in all patients who have exfoliation. It is the only member of the triad consisting


of flakes, central disc and peripheral band which is constantly present, and we therefore cannot preclude the existence of exfoliation in a patient before we have an opportunity of ascertaining that the peripheral band is absent.

The cause of this peculiar division of the changes in the capsule into a central disc and a peripheral band separated from the disc by an unaffected space is by Vogt and others thought to lie in the movements of the pupil. Originally the affection of the capsule extends over the entire surface of the lens, but afterwards (or perhaps according as it develops) the growth is rubbed off in the parts touched by the edge of the pupil during its movements.

If this were correct, it should follow that the central disc would be present just as constantly as the peripheral band. This is, however, not the case. In about 10 per cent. of our cases we cannot detect it. Whether it is really absent in these cases, or is merely so little developed that we cannot see it, we cannot with our present appliances as yet decide.

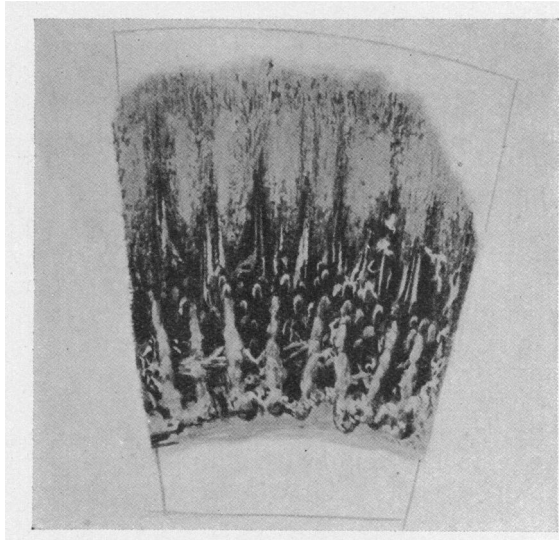
When we have had an opportunity of investigating several cases of exfoliation, we are struck by the fact that the appearance presented in all of them is similar, but we must admit that we do not know anything as to the development of the exfoliation. We do not know its first beginning and neither do we know whether it starts over the whole surface at once or begins, for example, in the periphery and spreads out therefrom.

That together with the affection of the capsule there also occurs a typical change in the zonule (of Zinn) has hitherto not been generally known. Trantas in 1929 described a case in which



Drawing of the zonule of Zinn.

iridectomy had been performed and the lens displaced so that the ligament could be seen, the fibres being then found to be densely covered with scurf-like flakes. Vogt in 1931 depicted a case in which iridectomy had been carried out, so that the suspensory ligament was visible, and he remarks: "Im Kolombereich sind die Firstlinien der Ansätze der Zonulafasern sichtbar. Als graue parallele Linien liegen sie in der Fortsetzung des Häutchens." And it is surely not unreasonable to suppose that the same change has occurred here.



Drawing of the ciliary body.

Neither of these descriptions, however, has attracted any particular attention, and they are not mentioned in the later works on exfoliation.


From my own investigations, carried out both on patients and on eyes excised on account of absolute glaucoma, where the iris had been removed in its entirety and the zonular fibres exposed, I feel justified in asserting that these zonular changes are of constant nature and form an integral part of the clinical picture of exfoliation. In excised eyes where exfoliation is present they are never wanting, and neither are they wanting in patients with exfoliation, if the suspensory ligament is at all visible. In all cases the fibres are found to be densely covered with white scurf-like particles, of the same appearance as the flakes on the pupillary border.

Whether this affection of the zonular fibres is of secondary origin, like the flakes on the pupillary border, or whether it is

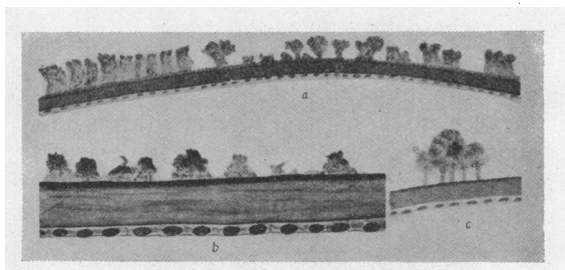
primary, a degenerative change in the fibres quite analogous to the affection of the capsule, we do not yet know.

The histological picture of the exfoliation is known chiefly from Busacca's and Vogt's works. Busacca claims to have demonstrated that the exfoliation consists in the deposition of a granular substance which he presumes is normally to be found in solution in the aqueous humour. Vogt assembles the changes he finds into three type groups:—

(1) The capsule is everywhere of normal thickness and structure, but a superficial lamella detaches itself as an exfoliation.



Vogt: Pastry-like part of the capsule.



Section showing bud-like exfoliation of hyaline layer of anterior lens capsule. From Busacca.

(2) The capsule is in some parts thickened and puffy, so that it looks like pastry.

(3) These puffed-up parts of the capsule gradually get rubbed off, so that it again becomes smooth, but considerably thinner than normal.

In one single case he also found vacuoles lying deep down in the capsule.

As regards age, all the patients showing exfoliation are elderly, only 4 or 5 cases being recorded in persons aged between 40 and 50, and in younger persons it has hitherto not been observed.

Relation to Glaucoma

As early as in 1917 Lindberg was aware that the flakes on the pupillary border occurred more frequently in glaucoma patients than in others. He says:—

“ Among 60 cases of chronic primary glaucoma I found these flakes in 50 per cent. I do not thereby pretend to come forward with a new glaucoma symptom. On the contrary, it is my opinion that the flakes in most cases are the result of an earlier exudation.”

Likewise Malling in 1923 draws attention to this circumstance. He says : “ The disc seems preferably to appear in cases where the ocular tension is temporarily or permanently increased. It has therefore only once or twice been observed in patients in whom the tension was found on examination to be normal, while among 81 eyes with increased tension it was detected in no less than 33. It must therefore probably be permissible to conclude that the formation of film and increase of tension are in some way or other connected with each other.”

And from Vogt's first report of cases, published in 1925, it is seen : “ That the affection represents no rare symptom of chronic glaucoma. For of twelve persons affected no fewer than nine are suffering from advanced chronic glaucoma.” And one more was later attacked thereby.

Vogt therefore at once submitted the question :—Is the exfoliation the cause or the consequence of the glaucoma? And in his first paper he was inclined to accept the latter alternative.

But in his next, in 1926, he declared that the exfoliation must be the cause of the glaucoma. He has since steadily maintained this view, and he has chosen a special name for this form of glaucoma: Glaucoma capsulare (capsulo-cuticulare).

The cause of the glaucoma is by Vogt supposed to be that the flakes which have been rubbed off choke up the ducts for the aqueous humour. The flakes, which occur in relatively large numbers, are difficult to dissolve and non-absorbable and they deposit themselves in course of time in the ducts and thus lead to a rise of tension. The more so because in most cases we have to do with persons of advanced age in whom these ducts have more or less deteriorated.

Busacca and others agree with this view.

If I am right in maintaining that the zonular changes are constant, we could also explain the occurrence of the glaucoma as being in accordance with the diaphragm theory.

Clinically the capsular glaucoma always manifests itself as a chronic glaucoma simplex. I have been able to find only two exceptions: Busacca's Case 13, which is designated as “ Entzündliches chron. Glaukom,” and Foster's case, which is described as being subacute.

The relation between exfoliation and glaucoma must be regarded from two points of view :—

(1) How frequently is glaucoma met with among the patients with exfoliation?

Vogt 1925:	12 pat. with exfol., of whom	9 had glaucoma.
Vogt 1931:	45 " " " " "	34 " " (about 75%)
Busacca 1927:	30 " " " " "	27 " "
Trantas 1929:	42 " " " " "	14 " "
Rehsteiner 1929:	78 " " " " "	50 " "
	(collected from literature)	
Grzedzielski 1931:	156 pat. with exfol., of whom	90 " "
	(collected from literature)	
Baumgart 1933:	46 pat. with exfol., of whom	29 " " (63%)

The figures show good concordance and we may regard it as established that between 60 and 70 per cent. of the patients who have exfoliation are at the same time suffering from glaucoma.

The next important question then is:—

(2) How often do we find exfoliation in the patients suffering from chronic glaucoma (glaucoma simplex)?

Among 60 cases of chronic, in part absolute, primary glaucoma Lindberg found flakes on the pupillary border in 50 per cent.

Malling found a film on the lens surface in 33 cases among 81 eyes with increased tension. It would seem, however, that from chronic glaucoma (glaucoma simplex)?

Busacca examined 38 glaucoma patients, all over 60 years old, and found exfoliation in 60 per cent. of them.

Vogt (Dr. Rohner) found among 185 cases of so-called primary glaucoma treated in the course of 4 years 13 cases of glaucoma capsulare, *i.e.*, 7 per cent.

Reckoning with only the 150 cases of chronic glaucoma, the percentage of glaucoma capsulare in chronic glaucoma will be 8.6.

Blaickner found among 84 carefully examined glaucoma patients 5 patients with glaucoma capsulare in both eyes. Most of his patients had been subjected to iridencleisis with meridional iridotomy, so that the lens surface could easily be examined, and his figures should therefore have some weight.

Baumgart examined 59 cases of glaucoma simplex, where the pupils had been dilated by subconjunctival injection of adrenaline, and found exfoliation in 29 cases, or 49 per cent.

I have myself examined with the slit-lamp altogether 150 patients, all of whom had been operated on in the Ophthalmic Section of the University Hospital by iridencleisis with meridional iridotomy by Holth's method. All of them were examined after the operation, so that the periphery of the lens was well visible in the coloboma area.

Of these 150 patients 55 were women and 95 men.

The distribution according to age was:—

40—50 years	...	3	(2 positive, 1 negative)
50—60 "	...	11	(10 " 1 ")
60—70 "	...	66	(57 " 9 ")
70—80 "	...	58	(47 " 11 ")
80—90 "	...	12	(12 " 0 ")

The result of the examination accordingly was that of these 150 patients operated on by iridencleisis for glaucoma simplex 128 (85·33 per cent.) had typical exfoliation of the lens capsule.

I have also examined a series of patients with glaucoma simplex before the operation, under mydriasis produced by instillation of "linksglaucosan." There are altogether 43 cases, representing the total number of patients treated for glaucoma simplex at the hospital during a certain period of time. Among these I found exfoliation in 40 patients, or 93 per cent.

It is difficult to give any explanation of the enormous difference between Vogt's and Blaickner's findings (about 5 per cent.) and my findings (80-90 per cent.). The most reasonable explanation probably is that the material dealt with is not quite the same, as it is possible that the form they call chronic glaucoma is not identical with what we here call glaucoma simplex—that there may, for example, among their cases be many chronic inflammatory glaucomas, a form which seldom occurs here.

From the results of my investigations I am more and more inclined to believe that the exfoliation offers us an excellent basis for the classification of our glaucomas, seeing that glaucoma simplex must be regarded as identical with glaucoma capsulare, while on the other hand exfoliation does not occur in cases of acute glaucoma or chronic inflammatory glaucoma.

I shall now proceed to deal with the next important question: How frequently do we find exfoliation of the lens capsule in old persons who have not glaucoma simplex?

On this point opinions are divided, and the figures furnished by the various investigators differ greatly from each other.

Handmann writes in 1926: "Although I almost every day examine elderly persons by aid of the slit-lamp, and since I saw my first case have directed attention especially to this matter, yet I have since 1919 seen only 3 cases."

Lindberg examined the pupillary border in 60 normal cases and found flakes in 4 of them, or about 6·6 per cent.

Rehsteiner examined 238 inmates from 7 old age homes in Zürich and its neighbourhood. All of them were examined with the slit-lamp, and in 148 cases one or both pupils were dilated

by means of homatropine or cocaine, while in the others these agents either could not be used or else did not take effect. All the persons examined were over 60 years old.

Among these he found 4 cases of exfoliation, and of these 4 one was blind from glaucoma, two had increased tension and only one was without signs of glaucoma. Taking all the cases together the incidence is 4 in 238, or 1·7 per cent.

In a later work (1931) Vogt remarks that Rehsteiner's figures represent the minimal value, because he appears to have directed attention mainly to the flakes on the pupillary border, and they are not constantly present.

This seems to conflict with Rehsteiner's own words. He states expressly that the pupil was dilated in order that the largest possible part of the lens surface might be surveyed, and this must be said to indicate that his attention was directed to the lens surface itself.

Trantas examined 112 women and 125 men, all over 55 years of age and selected from among 1,540 new patients. From the report it does not appear how the selection was made. Among these patients he found exfoliation in 36, and on renewed examination in a further 6, so that there were altogether 42 cases of exfoliation. Of these 42 patients 14 had glaucoma.

He adds that in reality the frequency of exfoliation was much greater, because a large number of the patients were examined without mydriasis, and the exfoliation may thus have been overlooked. He therefore believes one would not be far from the truth in assuming that at least 25 per cent. of all persons over 55 years old have exfoliation of the lens capsule.

Baumgart examined 611 patients at the hospital in Bologna, all over 50 years of age, and among these she found exfoliation in 46 cases (7·5 per cent). She remarks that the figure should possibly be higher, as mydriatics could not be employed in all cases. Of these 46 cases of exfoliation 29 showed glaucoma. The total number of glaucoma cases in the series seems to have been 59. Her figures might therefore be re-arranged as follows:—

Of 611 patients	46 had exfoliation (7·5%)
including <u>59</u> glaucoma patients,	of whom <u>29</u> „ „ (49%)
leaving 522 patients without glaucoma,	„ 17 „ „ (3%)

The conditions of examination have not been quite the same for the two groups. The glaucoma cases were examined after subconjunctival injection of adrenaline, the others after instillation of the usual mydriatics, and some also without use thereof.

I have myself examined 152 elderly people who did not show

signs of glaucoma. The examination was conducted at the same place and with the same apparatus as in case of the glaucoma patients, and in all cases the pupils were dilated by means of homatropine and cocaine.

The material falls into 3 groups :—

(1) 69 inmates of old age homes in Oslo, called in for examination for this special purpose. They comprised 44 women and 25 men and the distribution according to age was :—

50—60 years	...	4
60—70 "	...	12
70—80 "	...	41, of whom 4 had exfoliation.
80—90 "	...	12

Among these I found 4 cases of exfoliation. 2 of these had increased tension (several measurements) and, deducting them, the result will therefore be: among 67 inmates of old age homes without signs of glaucoma 2 were found to have senile exfoliation of the lens capsule.

(2) 30 patients from the Ophthalmic Section of the University Hospital and its out-patient department, treated for other diseases than cataract and glaucoma. They comprise 19 women and 11 men, divided into the following age-groups :—

60—70 years	...	9, of whom 1 had exfoliation.
70—80 "	...	15, " " 4 " "
80—90 "	...	5
90—100 "	...	1

Here I found exfoliation in 5 patients.

(3) 55 patients, admitted to the Ophthalmic Section for operation for cataract. 35 women and 20 men, with the following age distribution :—

50—60 years	...	4
60—70 "	...	15
70—80 "	...	12, of whom 8 had exfoliation.
80—90 "	...	12, " " 2 " "

Thus I found here 10 patients with exfoliation.

I can furnish no explanation of the remarkable fact that exfoliation is found more frequently in patients with cataract than in the inmates of old age homes, but other investigators have found the same results.

Lindberg examined the pupillary border in 142 patients with cataract and found exfoliation in 28 of them, or about 30 per cent. And Busacca examined 27 cataract patients, all over 60 years of age, and found exfoliation in 26 per cent. of them.

I have also examined 34 eyeballs excised in the dissecting room from the bodies of old people, whose eyes could not be examined before death. 13 were women and 21 men, and the age-distribution was:—

50—60 years	...	4
60—70 "	...	20
70—80 "	...	9, of whom 1 had exfoliation.
80—90 "	...	1

The cornea was cut away, the iris carefully removed and the whole of the lens surface and zonular fibres exposed and examined.

Here I found exfoliation in 1 case, that is to say, exactly the same frequency as I found among the inmates of old age homes.

On now comparing the results of my investigations regarding the occurrence of exfoliation we find the following facts:—

Among 150 patients operated on for glaucoma simplex I find exfoliation in 128 cases, or 85 per cent.

Among 43 patients, embracing all cases treated for glaucoma simplex in the Ophthalmic Section of the University Hospital during a certain period, examined under glaucosan mydriasis, I find exfoliation in 40, or 93 per cent.

Among 67 inmates of old age homes, without signs of glaucoma, I find exfoliation in 2.

Among 34 eyeballs excised from the bodies of old persons in the dissecting room I find exfoliation in 1 case.

Among 55 patients with cataract I find exfoliation in 10.

Among 30 hospital patients, without cataract or glaucoma, I find exfoliation in 5.

The difference in frequency of exfoliation in glaucoma simplex on the one hand and in old people without glaucoma on the other hand is so enormous that it cannot be explained away.

And it does not seem possible to find any other explanation than that senile exfoliation of the lens capsule must in some way or other be the cause of the form of glaucoma which we call glaucoma simplex.

