

cataract than the retinal lesion itself. This point is being more fully investigated.

The cataract is not due to a disturbance in the blood supply to the eye; the vessels of the retina and choroid were found to be healthy at the time of onset of the lens changes; the iris and ciliary body were found to be normal. Nor is it likely that the cataract results from some general metabolic disturbance, since the two eyes of an animal are not always affected to the same extent. The animals appear to be healthy and their diet is adequate in all known dietary essentials.

It is interesting to note that Jess (1925) described an hereditary and congenital cataract occurring in a colony of white rats. Thirty-four per cent. of the 300 eyes examined by him were affected. The cataract consisted of granular opacities in the anterior cortex; the number, size and density of these opacities varied greatly, often appearing as a thick "bee-swarm" in an otherwise clear lens. From this description it appears that Jess's cataract is different from the one described here.

#### REFERENCES

- BOURNE, M. C., and GRUNEBERG, H.—To be published.  
 JESS, A.—*Klin. Monatsbl. f. Augenheilk.*, Vol. LXXIV, p. 49, 1925.

We are indebted to the Medical Research Council and to the Birmingham and Midland Eye Hospital for expenses grants to M.C.B. and D.A.C. respectively. We also wish to record our thanks to Miss M. Marshall, of the Pathological Department of the Birmingham Eye Hospital, for her valuable assistance in preparing sections.

---

## HEREDITARY DEGENERATION OF THE RAT RETINA

BY

MARGHERITA COTONIO BOURNE, DOROTHY ADAMS  
 CAMPBELL *and* KATHARINE TANSLEY

*from*

THE DEPARTMENT OF PHYSIOLOGY AND BIOCHEMISTRY, UNIVERSITY COLLEGE,  
 LONDON, AND THE MID AND BIRMINGHAM EYE HOSPITAL

IN the preceding paper (p. 608) a form of cataract occurring in rats and associated with a particular form of retinal degeneration was described. It was shown that the retinal defect is hereditary and that the mode of inheritance is that of a Mendelian recessive factor. The purpose of the present communication is to describe

the histological examination of the origin and progress of the retinal degeneration.

Apart from colobomata, which occur frequently in rabbits, there are few records of hereditary retinal defects in animals, and the rats which we were fortunate enough to acquire have provided an unusual opportunity of following the progress of a retinal degeneration, due to an hereditary defect, through all its stages.

The retinal lesion itself proved to be of especial interest, since in our opinion it bears a striking resemblance to the microscopic appearance described in certain cases of retinitis pigmentosa (Verhoeff, 1931), (Stock, 1908).

### Experimental

The strain of rats in which the retinal lesion occurred has already been described (p. 609). The eyes of 115 animals were examined microscopically at different ages varying from five days to twenty-one months. The animal was killed with chloroform and the eyes removed immediately after death; or the eyes were removed under local anaesthesia with novocaine. The latter method enabled us to compare the two eyes of one animal at different stages of development.

*Histological Technique.*—Most of the eyes of the younger animals were fixed in Zenker's solution, a few in Fleming's solution both with and without the acetic acid, and a few in Bouin's solution. One or two were also treated by de Castro's method for nerve fibres. Paraffin sections were cut at  $8\mu$  and the following stains used; haematoxylin and eosin, the Azan modification of Mallory's triple connective tissue stain, Feulgen's method for nuclei, and Heidenhain's iron haematoxylin with a counterstain of aniline blue and orange G. In addition a few of the eyes were stained with Bodian's (1936) method for nerve fibres, and a few others with Mallory's phosphotungstic acid haematoxylin for glia.

The eyes from the older animals were fixed in  $\frac{3}{4}$  strength Bouin's solution, prepared as celloidin sections and stained with haematoxylin and eosin. In these preparations sections of the whole eye including the lens were cut and examined.

*Results.*—It is well known that the eye of the rat is immature at birth (Fig. 1) and does not reach maturity (Fig. 3) until the animal is about 17 days old. It was found that rats of the stock under consideration passed through the normal stages of development between birth and about 17 days. Fig. 2 shows a section of an eye of one of these rats at 10 days and it will be seen that it is impossible to detect any abnormality whatever. Changes in the retina were first observed at about 3 weeks of age. The lesion

was in all cases bilateral, and during the first four months progressed at about the same rate in different animals and in the two eyes of the same animal. In its later stages the degeneration might proceed at different rates in different individuals.

The general course of the disease may be conveniently divided into stages as follows.

1. Death of the rod nuclei of the outer nuclear layer (3 weeks).
2. Complete degeneration of the outer nuclear layer, with disintegration of the rods themselves (3-7 weeks).
3. Disappearance of the degenerate outer nuclear and rod layers, with replacement of these by a network of glial fibres. Alteration of the pigment epithelium accompanied by adhesions of this tissue to the retina, associated with the appearance of strands of thickened glial fibres, together with the alteration of the inner nuclear layer structure by the passage through it of these strands (over 7 weeks).
4. Convolution of the whole retina apparently as a result of the tension exerted by the glial strands (about 11 months).
5. Complete loss of the layered structure of the retina. This may be followed by intra-ocular haemorrhages and inflammatory reactions in the vitreous (in the course of the 2nd year).

The following is a detailed description of the microscopic appearance in each stage:

*Stage 1.*—The first obvious sign of abnormality made its appearance at 21 days of age. With Feulgen's method of staining it could be seen that a considerable number of the outer nuclei were degenerate, and that the outer limbs of the rods were swollen, giving the appearance of a row of pale pink drops replacing the tips of the rods (normally the outer limbs of the rods stain pinkish-purple with this method). This early degeneration of the outer ends of the rods could also be demonstrated very clearly with connective tissue stains, such as the orange G.-aniline blue mixture used in the Azan method. There was some evidence that a slight degeneration of the outer nuclear layer could be detected as early as 17 days, but it was difficult to be certain whether the number of dead cells was significant, since degenerate cells normally occur during the development of the retina (Glücksmann, 1930). However, it may certainly be said, in view of the relatively large number of nuclei which are degenerate at 21 days, that the process must start at least a few days earlier.

*Stage 2.*—The degeneration of the cells of the outer nuclear layer continued, until during the 5th week it was difficult to find a single normal rod nucleus in the whole layer (Fig. 4), while the few cone nuclei (Walls, 1934, and Fig. 8)\*, were normal.

---

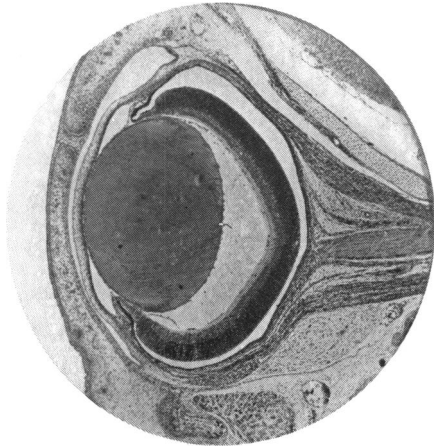
\* We are indebted to Dr. Walls for the loan of the slide from which this photograph was made.

From 5 to 8 weeks a disappearance of the dead cells resulted in a gradual thinning of the layer, until at 9 weeks it had entirely disappeared with the exception of the cone nuclei (Figs. 5 and 9). As might be expected, the degeneration of the rods ran parallel with that of the nuclei; between 28 and 42 days they lost the characteristic differential staining of inner and outer limbs (Tansley, 1933), and though they still formed a good layer they did not appear to be healthy. As the outer nuclear layer disappeared, the rods also lost their structure, and at 7 weeks the space between the dead outer nuclear cells and the pigment epithelium was filled with a homogeneous mass which gradually became reduced in thickness, and was later replaced by a glial network formed by proliferation of Müller's fibres (Fig. 11). In one litter in which the fresh retinae were examined after the animals had been kept in the dark overnight, it was found that visual purple was still present at 5 weeks but had disappeared a week later. Histological examination of the other eye which was removed at the same time, showed that visual purple was present so long as the outer limbs showed the characteristic differential staining, even though the nuclei were already dead.

The disappearance of the rod debris was accomplished, partially at least, by phagocytosis. At about 9 weeks Müller's fibres became very much thickened in the inner fibre layer (Figs. 9, 12 and 13), and by 11 weeks these thick fibres could be traced into the inner nuclear layer, while a little later they formed a reticular network between this layer and the pigment epithelium (Fig. 11).

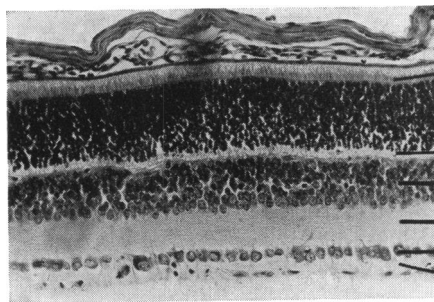
*Stage 3.*—At about 12 weeks the pigment epithelium became much altered in appearance (Fig. 13). As early as 7 weeks this tissue might show signs of abnormality in an irregular thickening which continued until the epithelium was quite invisible over some areas, and several cells thick in others. Since cell division was never seen, the thickening was probably due to a migration of the cells. In the thick patches the nuclei looked normal but the cell boundaries were not recognisable. These alterations of the pigment epithelium were accompanied by an adhesion of this tissue to the retina, so that in those sections where the retina had become detached from the back of the eyeball during fixation, the break tended to occur between the pigment epithelium and the choroid, and not, as is usually the case, between the pigment epithelium and the retina (Fig. 13).

At this stage, also, it was possible to recognise the first signs of an actual tissue connection between the pigment epithelium and the retina. This took the form of fibre bundles running from one tissue into the other. These bundles were apparently composed mainly of glia with a few connective tissue fibres among them. It was impossible to be certain whether they penetrated



**FIG. 1.**

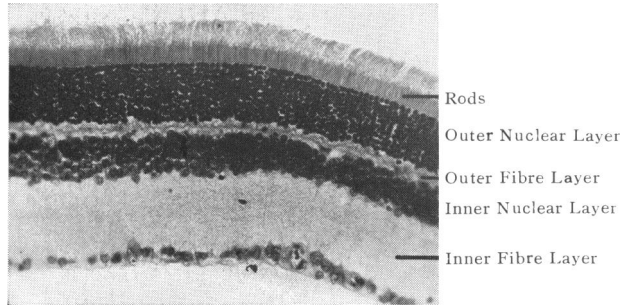
**Section through the rat eye at birth.  
Bouin. Haematoxylin and eosin.**



Rods  
Outer Nuclear Layer  
Outer Fibre Layer  
Inner Nuclear Layer  
Inner Fibre Layer  
Ganglion Cells  
Optic Fibre Layer

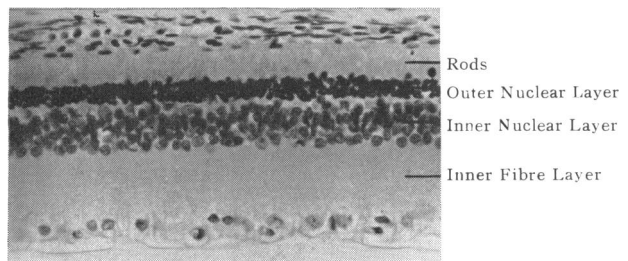
**FIG. 2.**

**Section through the retina of a rat from the affected stock aged 10 days. The retina is perfectly normal for an animal of this age. Bouin. Haematoxylin and eosin. (X160.)**



**FIG. 3.**

Section through the normal adult retina.  
 Bouin. Haematoxylin and eosin. ( $\times 150$ .)



**FIG. 4.**

Section through the retina of a rat from the affected stock  
 aged 7 weeks. The outer nuclear layer is completely  
 degenerate and the rods have lost their microscopic  
 structure (2nd stage). Zenker. Feulgen. ( $\times 250$ .)

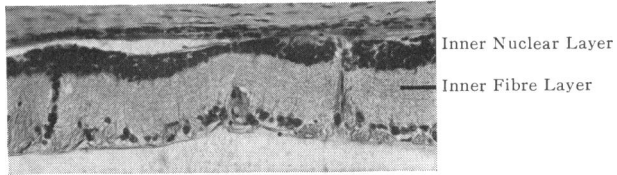


FIG. 5.

Section through the retina of a rat from the affected stock aged 17 months. The outer nuclear layer has disappeared and the fibre bundles which begin to appear at this stage are easily recognisable (3rd stage). 3/4 Bouin. Haematoxylin and eosin. ( $\times 120$ .)

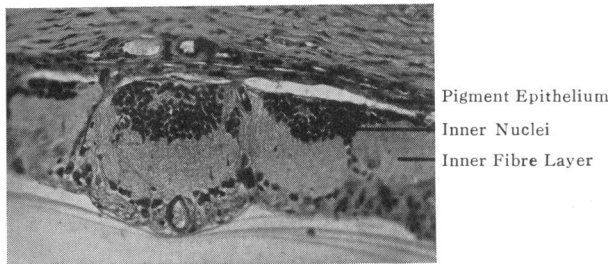


FIG. 6.

Section through the retina of a rat from the affected stock aged  $17\frac{1}{2}$  months. The retina is beginning to become distorted and the fibre bundles have completely divided the inner nuclear layer (4th stage). 3/4 Bouin. Haematoxylin and eosin. ( $\times 120$ .)

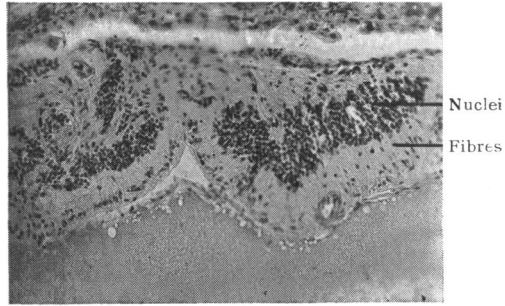


FIG. 7.

Section through the retina of a rat from the affected stock aged 17 months. The layered structure of the retina has been lost and the whole tissue is violently distorted (5th stage). 3/4 Bouin Haematoxylin and eosin. (X240.)

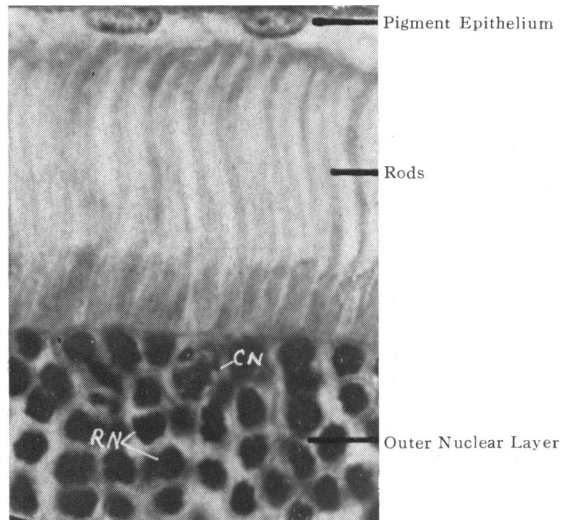


FIG. 8.

Section through the normal adult rat retina showing difference between rod and cone nuclei. Kolmer. Iron haematoxylin and phloxine. This section was lent by Dr. G. L. Walls. C.N., Cone Nucleus. R.N., Rod Nuclei. (X1250.)



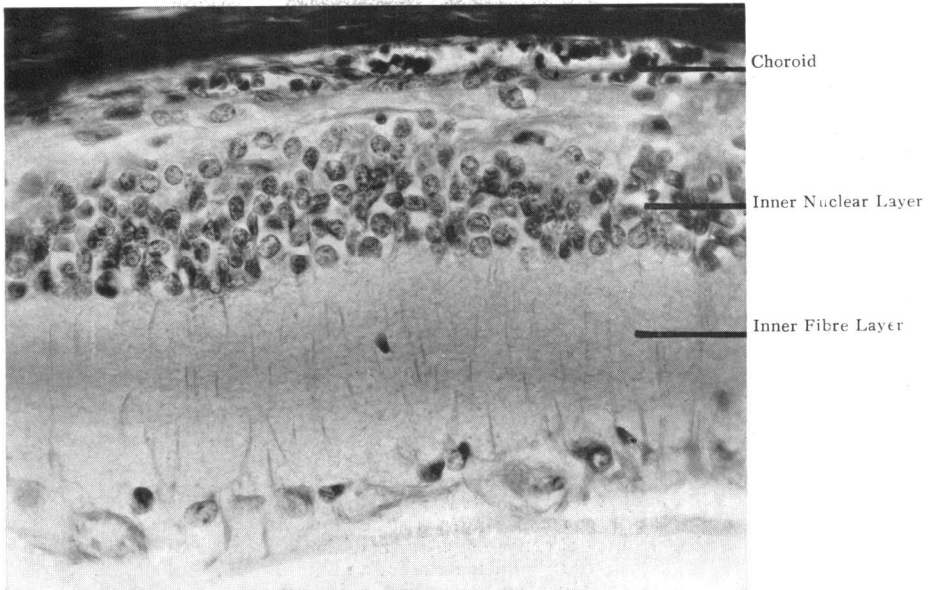


FIG. 9.

Section through the retina of a rat from the affected stock aged 19 weeks. The outer nuclear layer has completely disappeared. Note the prominence of Müller's fibres in the inner nuclear layer. (*cf.* Verhoeff 1931.) Zenker. Iron haematoxylin, aniline blue and orange G. ( $\times 400$ .)

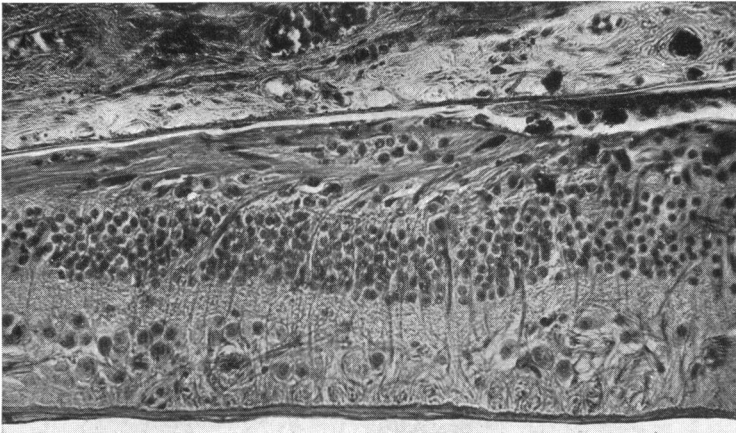


FIG. 10.

A section from a case of human retinitis pigmentosa. (Reproduced from Verhoeff, *Arch. of Ophthal.*, Vol. V, p. 392, 1931.) Fig. 2, "Gliosis of the retina. Müller's fibres extend through the retina and replace the neuro-epithelium with a layer of neuroglia fibrils running parallel with the retina. On the right the limiting membrane has been destroyed. The normal chorio-capillaris of the choroid is well shown. Phosphotungstic acid haematoxylin."

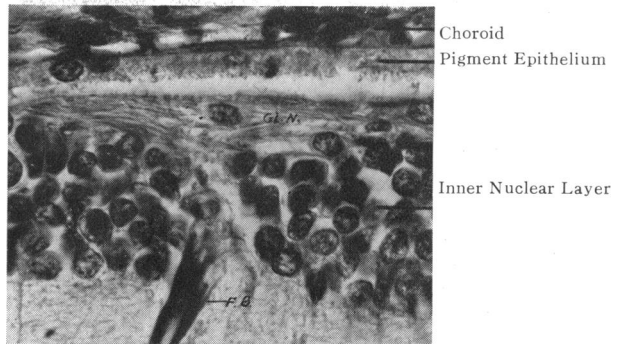


FIG. 11.

Section through the retina of a rat from the affected stock aged 19 weeks. Note the bundle of fibres running through the inner nuclear layer and the network composed of glial fibres between this layer and the pigment epithelium. Zenker. Iron haematoxylin, aniline blue and orange G. Gl. N., Glial Network. F.B., Fibre Bundle. (X550.)

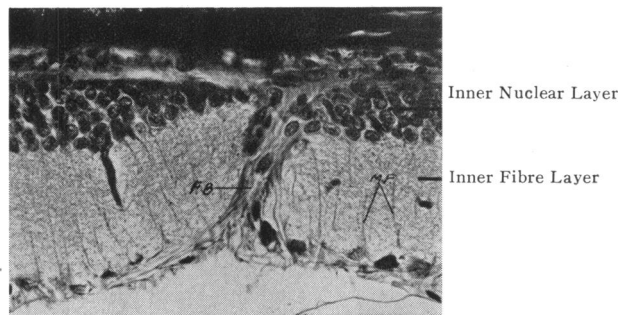


FIG. 12.

Another part of the same section. Detail of one of the fibre bundles running between the pigment epithelium and the retina. Note also the thickened Müller's fibres in the inner fibre layer. Zenker. Iron haematoxylin, aniline blue and orange G. M.F., Müller's Fibres. F.B., Fibre Bundle. (X240.)

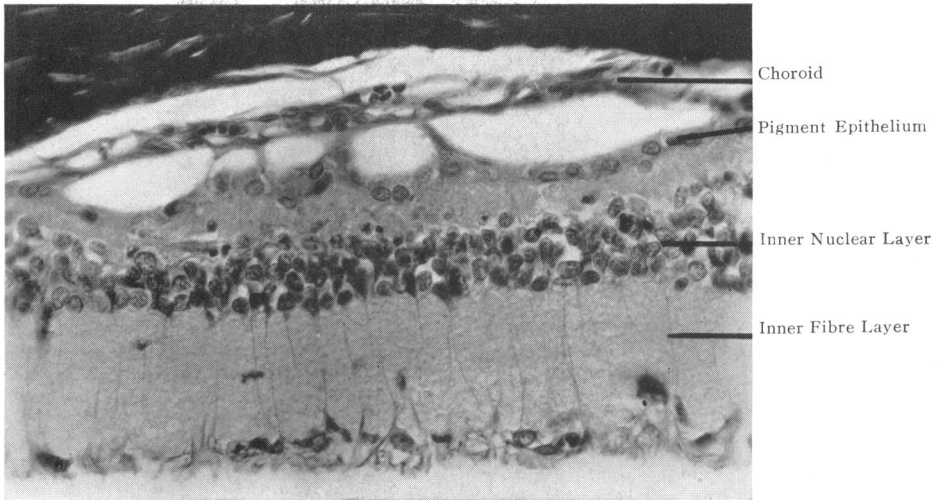


FIG. 13.

The periphery of the section photographed in Fig. 9. The pigment epithelium has become stuck to the retina and its nuclei are crowded together. Note that the condition is not so far advanced in this part of the retina as it is nearer the centre (Fig. 9). Zenker. Iron haematoxylin, aniline blue and orange G. ( $\times 400$ )

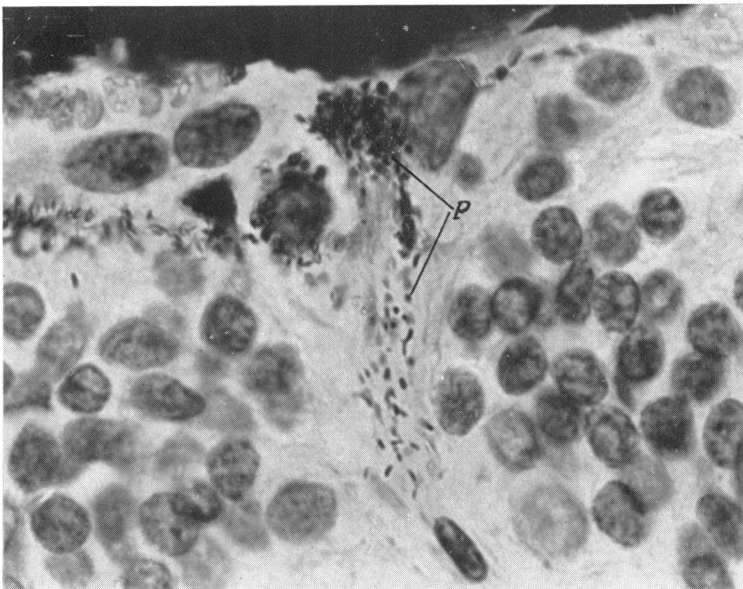


FIG. 14.

Section through the retina of a pigmented rat from the affected stock aged 24 weeks. The pigment of the pigment epithelium is moving into the retina along the path made by one of the fibre bundles. Zenker. Feulgen. P., Pigment Granules. ( $\times 1280$ .)

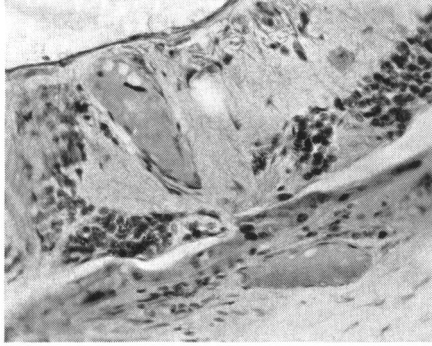


FIG. 15.

Section through the retina of a rat from the affected stock aged 9½ months. Large vessels are present both in the retina and in the choroid. 3/4 Bouin. Haematoxylin and eosin. (X240.)

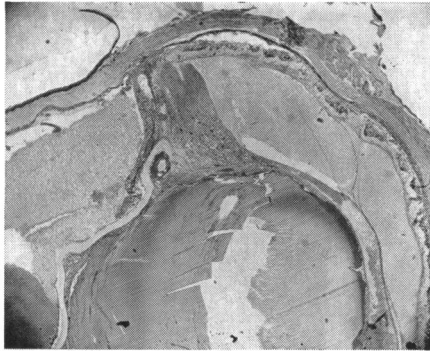


FIG. 16.

Section through the eye of a rat from the affected stock aged 18 months, giving a general picture of the most advanced stage of degeneration. There has been a haemorrhage into the posterior chamber which is also full of débris from the cataractous lens. There is fibrosis at the posterior pole of the lens, and in the posterior angles. 3/4 Bouin. Haematoxylin and eosin. (X40.)

the retina from the pigment epithelium or vice versa (Figs. 5 and 13), but it is probable that the glial fibres were contributed by the retina, and that the pigment epithelium cells migrated into the retina along the paths thus made.

The pigment epithelium was, in most cases, unpigmented in these rats, since they were either albinos or pink-eyed piebald agouties, but a few animals did show a deeper colouring. These had pigmented eyes, and at this stage some movement of pigment into the retina could be seen. The migration did not begin until tissue connection with the retina was established, and the pigment granules always followed the path made by the connecting fibres (Fig. 14).

The groups of fibres might on occasion be accompanied by blood vessels and there is no doubt that these originated in the retina.

*Stages 4 and 5.*—As the third stage passed into the fourth, the fibre strands appeared to distort the retina. The first sign of alteration of the general retinal structures was seen in the inner nuclear layer which was completely divided where the bundles of fibres passed through it (Fig. 6). Nuclei resembling those of this layer were also found lying along the course of the bundles, and it looked as though these had either migrated or been drawn into this position.

The distortion of the retina became more violent as the condition progressed. Towards the end of the first year the whole structure was altered (Fig. 7), apparently owing to the increasing fibrosis, and the cells of both the inner nuclear and ganglion cell layers became more and more scattered.

At this stage changes could be seen in the walls of the blood vessels of the retina and choroid. They stained poorly and had a hyaline appearance (Fig. 15).

Later still, the sections showed what appeared to be fibrous strands between the retina and the posterior cortex of the lens, and at the posterior angle behind the ciliary body. There was also a tendency for gross intra-ocular haemorrhages which usually occurred from the retinal vessels. These were observed both clinically and microscopically, and in the latest stages of degeneration it was common to find blood corpuscles both in the posterior and anterior chambers. Accumulations of lens debris were also found in the posterior chamber of those eyes in which the retinal defect was accompanied by cataract, and this was associated with an inflammatory reaction consisting of a fine fibrosis and the appearance of leucocytes (Fig. 16).

The terminal stages of the degeneration did not usually occur until the animals were over 18 months of age.

It was observed that, after the death of the rod cells and as soon as the secondary changes had begun, the lesion was always more severe in the centre than in the periphery of the retina, and this difference tended to become more marked as the condition advanced. Thus, at about 8-12 months it was common to find the retina much distorted round the optic disc, while in the ciliary area the different layers were in their normal position, with the exception of the outer nuclear and outer fibre layers which had, of course, long since disappeared.

In spite of the total loss of its outer part, the retina did not become markedly thinner as the condition progressed, owing to thickening of the inner fibre layer.

*Other Tissues of the Eye.*—The choroid in the affected eyes was often thicker than in the normal eyes of this stock, but in the early stages at least, was not thicker than may be found in the eyes of rats of other stocks. The thickening was chiefly due to an increase in the connective tissue, and the blood vessels remained unaffected at least in the early stages of degeneration.

The iris and ciliary body were most carefully examined at all stages of the disease but no abnormality whatsoever could be detected.

The posterior cortical cataract associated with the retinal condition has already been described and its possible relation to the retinal degeneration has been discussed (p. 608).

*Note on the Condition of the Blood Vessels of the  
Choroid and Retina by Dorothy S. Russell*

A SPECIAL microscopical examination was made of the blood vessels of the choroid and retina in this series of rats, including normal controls. Assuming that the rod and cone layer is dependent for its nutrition upon the vessels of the choroid it is obvious that great importance would attach to the finding of any pathological change in these vessels at an early stage of the retinal degeneration.

The sections examined were taken from rats exhibiting all stages of retinal degeneration, the ages of the animals ranging from 5 to 267 days. Preparations stained with haematoxylin and eosin and by the Azan method were selected for examination; the latter method in particular gives a sharp picture of arteriolar and capillary structure, enabling slight changes to be detected. Preparations stained for elastic fibrils were not available.

At all stages there is considerable, sometimes great, dilatation and engorgement of the capillaries of the choroid. In early phases of the retinal degeneration (rats of 49 days) there is also slight oedema. These two factors are together responsible for a

moderate expansion of the choroid as a whole. In a few instances there are recent haemorrhages. Haemorrhage and engorgement of capillaries are, however, also present in the controls. This and the absence of iron pigment in specimens representing later stages of the disease indicate that the haemorrhages probably arise from manipulative trauma during removal of the eye. Apart from this no changes whatever were found in any vessels of the choroid.

Similarly, no structural change was found in the vessels of the retina at any stage apart from a slight focal hyaline thickening of the walls of a few capillaries in one rat only. This rat exhibited a late stage of retinal degeneration (124 days). The basement membranes of these capillaries show focal hyaline expansions, the outline at such points being obscured by the presence in the adjacent tissue of small, spheroidal, hyaline masses, apparently of similar composition to the substance distending the basement membrane, which occupy but are strictly limited to the adjacent tissue. The arterioles in these two specimens are unaltered.

It is clear, therefore, that, if hyaline changes in the blood vessels appear at a later stage of the degeneration than is represented in this series, these changes must be regarded as of a secondary character.

### Discussion

The pathological condition which we have described is a progressive degeneration of the retina beginning with the death of the rod nuclei. The visual cells are able to attain their full development, but almost immediately after reaching maturity they begin to degenerate and eventually disappear. The subsequent alteration in the structure of the retina leading ultimately to the disintegration of the inner nuclear and ganglion cell layers appears to be the result of the disappearance of the neuro-epithelium. The degeneration was certainly not the result of vascular changes; nor of gross changes in the blood vessels of the choroid, for these remained unaffected until an advanced stage of retinal degeneration. In short, it is an unusual pathological condition for which it is difficult to find a comparison. On consideration, we are impressed by the striking resemblance which the histological picture in certain stages of the development of this lesion bears to the microscopic appearance described in certain cases of retinitis pigmentosa.

The case described by Verhoeff (1931) was that of a man, aged 64 years, who had been blind for over twenty years. In youth he had been unable to read in a subdued light, and read fine print more easily than large print. Both retinae showed the pigmentation characteristic of retinitis pigmentosa. The right eye, removed

on account of a tuberculous process which was too recent to have produced any changes in the posterior part of the eye, was fixed in Zenker's fluid immediately after enucleation and examined microscopically. The findings may be summarised as follows: The choriocapillaris and the choroid were normal with the exception of some of the arteries which showed senile endarteritis in moderate degree. The retinal vessels showed a reduction in calibre and hyaline degeneration. The rods were entirely gone, but there were remains of cones in places and the neuro-epithelial layer had been replaced more or less completely by neuroglia. The nuclei of the inner nuclear layer were well preserved but the layer was greatly distorted in places by the large number of Müller's fibres that had penetrated through it. The pigment epithelium was greatly altered; in places it was entirely absent, elsewhere it retained a close resemblance to its normal morphology but was generally almost free from pigment; in other places it had become changed into a layer of spindle cells. The pigment had migrated into the outer part of the retina and had collected around the retinal vessels. The ganglion cells were still abundant and there was no atrophy of the optic nerve. The histological picture described by Verhoeff is almost identical with that described by us as the third stage of degeneration in the rat retina (compare Figs. 9 and 10).<sup>\*</sup> In addition, Stock (1908) and Redslob (1933) have each described cases of retinitis pigmentosa in which they observed microscopically an ingrowth of pigment epithelium similar to that which occurred in the rat retina in the third stage of degeneration (Figs. 13 and 14).

The microscopic observations of Verhoeff on his case led him to agree with Leber (1916) and with Treacher Collins (1919) that the essential lesion in retinitis pigmentosa is a degeneration of the neuro-epithelium, the rods being first affected. He concluded that the choroid and the choriocapillaris are not concerned in the process, whereas a theory commonly held in this country is that the primary lesion is a vascular one and that the death of the nerve cells follows a degeneration of the choriocapillaris which is said to nourish the outer part of the retina.

There is no doubt that diminution in calibre and hyaline degeneration of the retinal vessels, disappearance of the choriocapillaris, and sclerosis of the larger choroidal vessels are found microscopically in some cases. On the other hand there is no doubt that the pathological changes characteristic of retinitis pigmentosa can occur in the absence of a choroidal lesion. Treacher Collins (1919) cites four undoubted cases in which there was no discoverable sclerosis of the choroidal vessels. Redslob (1933)

---

<sup>\*</sup> We are indebted to Dr. Verhoeff for permission to reproduce this photograph and the *Arch. of Ophthalm.*, for the loan of the block.



described the case of a young patient, a girl 20 years old, where the choroid was thickened but the vessels were normal. Verhoeff considered that the reduction in calibre of the retinal vessels observed in his case was a secondary change due to the thickening of the vessel walls by connective tissue.

It is impossible to reconcile these two views regarding the aetiology of retinitis pigmentosa. The pathological evidence is inadequate for the solution of the problem; comparatively few careful microscopic studies are available, and in these, since most of the cases were old patients in whom the disease was long standing, it is impossible to distinguish the primary from the secondary changes. Nevertheless, we venture to suggest that the knowledge that the series of pathological changes observed in these rats can occur in the absence of vascular change, and that such a degeneration can be initiated by death of the rod cells and disappearance of the neuro-epithelium, lends support to the theory of Treacher Collins that there is a type of retinitis pigmentosa resulting from the spontaneous death of the visual cells due to what Nettleship (1907) called "a hereditary tissue liability present, although seldom manifest, at birth." Clinically the first symptom of the disease is night blindness which suggests that there is a primary affection of the rods.

Other eye diseases of the same clinical group which one might expect to have a similar pathological basis are retinitis pigmentosa sine pigmento, congenital night-blindness, retinitis punctata albescens, and Oguchi's disease. Retinitis pigmentosa sine pigmento is usually regarded as an early form of retinitis pigmentosa, congenital night-blindness and retinitis punctata albescens are non-progressive conditions of which there are no histological records, and Oguchi's disease is characterised by the deposition of lipid in the cells of the pigment epithelium.

The available data suggest that the lesion occurring in the rats is more closely related to retinitis pigmentosa and that these other diseases are not comparable with it. Apart from the fact that in these rats we are dealing for the most part with unpigmented eyes, and therefore pigment migration is not visible, the only other important difference lies in the distribution of the lesion. In retinitis pigmentosa, "bone corpuscle" pigment occurs first at the periphery, and according to microscopic evidence the degeneration is also usually more advanced at the periphery than towards the centre, in fact the central vision remains undisturbed for a long time. But in rats, the degeneration proceeds more rapidly, in the area around the disc. If it be granted that the primary lesion in retinitis pigmentosa is a degeneration of the rod cells, then the preservation of the central vision in retinitis pigmentosa is explained by the fact that the rods are at a minimum in this

area and the cones are spared until a later stage of degeneration. Further, the paracentral scotoma which is always the first loss of the visual field to occur, corresponds to a lack of function of the visual cells in an area where, according to Osterberg (1935), the rods are at a maximum and the cones at a minimum. In Verhoeff's case, and also in these rats, remains of cones were present in the degenerate neuro-epithelial layer. There are comparatively few cones in the rat retina and they are certainly not massed together in any one area. In the early stages of this lesion, when only the rod nuclei are involved, the degeneration proceeds equally throughout the retina, later the degeneration is more advanced in the central area which is the oldest part of the retina, morphologically.

As far as we are aware, there has been no previous description of this lesion occurring in rats, nor of the exact mode of progress of any hereditary retinal lesion. A few cases of retinitis pigmentosa in dogs have been recorded and the ophthalmoscopic and microscopic findings have been described (Magnusson 1911, 1917, Yataka 1935). Keeler (1924, 1926), described an hereditary retinal defect in a strain of mice ("rodless mice"). In these animals the neuro-epithelium failed to develop at all, and the condition is therefore fundamentally different from that described by us.

In conclusion, we should perhaps offer an apology for venturing to compare a hitherto unknown pathological condition in rats, with the human disease of retinitis pigmentosa, but the resemblance is too close to pass unregarded. It appears that Gowers' theory of abiotrophy or premature senility of a tissue (in this case, the neuro-epithelium) is a possible explanation of both conditions. It has been regarded with disfavour as a hopeless theory which completely excludes any possibility of combating the condition by therapy. The problem of the moment is why the nervous elements of the retina are able to pass through a normal embryological development and then are unable to maintain adult life. The defect is obviously not due to faulty nutrition, as far as the circulation is concerned, but their failure to survive is possibly due to some metabolic inadequacy of the cells themselves. In view of the great strides made by recent workers in the field of genetics in identifying the chemical factors carried by specific genes, it should not be beyond the bounds of possibility to discover the vital factor concerned in the production of this lesion.

#### REFERENCES

- BODIAN, D.—*Anat. Rec.*, Vol. LXV, p. 89, 1936.  
 COLLINS, E. TREACHER.—*Trans. Ophthal. Soc. U.K.*, Vol. XXXIX, p. 165, 1919.  
 GLÜCKSMANN, A.—*Zeitschr. f. d. ges. Anat.*, abt. 1, Vol. XCIII, p. 35, 1930.  
 KEELER, C. E.—*Proc. Nat. Acad. Sci.*, Vol. X, p. 329, 1924: *Ibid.*, Vol XII, p. 225, 1926.

- LEBER, T.—*Græfe-Saemisch Handb.*, Vol. VII (pt. 2), p. 1105, 1916.  
 MAGNUSSON, H.—*Arch. f. vergl. Ophthalm.*, Vol. II, p. 147, 1911; *Arch. f. Ophthalm.*, Vol. XCIII, p. 404, 1917.  
 NETTLESHIP.—*Roy. Lond. Ophthalm. Hosp. Repts.*, Vol. XVII, 1907.  
 OSTERBERG, G.—Thesis, "Topography of the layer of rods and cones in the human retina." Copenhagen University, 1935.  
 REDSLOB, E.—*Ann. d'Ocul.*, Vol. CLXX, p. 140, 1933.  
 STOCK, W.—*Klin. Monatsbl. f. Augenheilk.*, Vol. XLVI, (1), p. 225, 1908.  
 TANSLEY, K.—*Brit. Jl. of Ophthalm.*, Vol. XVII, p. 321, 1933.  
 VERHOEFF, F. H.—*Arch. of Ophthalm.*, Vol. V (N.S.), p. 392, 1931.  
 WALLS, G. L.—*Jl. Comp. Psychol.*, Vol. XVIII, p. 363, 1934.  
 YATAKA, T.—*Acta Soc. Ophthalm. Jap.*, Vol. XXXIX p. 264, 1935 (quoted from *Zentralbl. f. d. ges. Ophthalm.*), Vol. XXXVI, 1936.

*Acknowledgements.*—We are indebted to the Medical Research Council, the Birmingham and Midland Eye Hospital and the *Brit. Jl. of Ophthalm.* for the financial assistance which made this work possible. We are greatly indebted to Dr. R. J. Lythgoe for taking the photographs of the retinal sections and to Miss M. Marshall for preparing many of the sections.

---

## ANNOTATION

---

### Protection of Welding Workers Employed in the Mines

We have received a report on this subject by a sub-committee of the Prevention of Accidents Committee of the Rand Mutual Assurance Co., Ltd., S. Africa. This sub-committee was instructed to review and bring up to date the recommendations made in March, 1932, with a view to protection of welding workers.

The principal hazard connected with welding is that due to the generation of ultra-violet and infra-red rays by the oxy-acetylene flame or by the arcs used in electric welding processes. The former are of short wave length and high penetrative power; the latter are of long wave length and no great penetrative power. Both are capable of damaging the eye.

The intensity of ultra-violet rays is proportionate to the amperage used in the electric welding process. The oxy-acetylene flame is relatively weak in these rays. Methods of eye protection must, therefore, vary with the intensity of the amperage used. And in connexion with welding there is danger from sparks and particles of metal either entering the eyes, setting clothes on fire, or burning the skin.

The following are the main subsections of this valuable report:—

#### 1. INCIDENCE OF ACCIDENTS.

The Sub-Committee notes with satisfaction that since the issue of its circular in March, 1932, great advance has been