

lymphadenopathy, splenomegaly, mediastinal changes and later involvement of the right lacrymal gland were the chief clinical features.

## LITERATURE

- BERING, F.—*Derm. Z.*, Vol. XVII, p. 404, 1910.  
 BLEGVAD, O.—*Acta Ophthal. Kbh.*, Vol. IX, p. 180, 1931.  
 BOECK, C.—*Jl. Cutan. Dis.*, Vol. XVII, p. 543, 1899; *Arch. Derm. Syph. Wien.*, Vol. LXXIII, p. 301, 1905; *Ibid* Vol. CXXI, p. 707, 1915.  
 COPPEZ, H. and DUJARDIN, B.—*Arch. Ophthal.*, Vol. II, p. 497, 1938.  
 FRAENKEL, E.—*Beitr. Klin. Tuberk.*, Vol. L, p. 441, 1922.  
 HABERMANN, R.—*Zentralbl. Haut. u. Geschlkr.*, Vol. XXIV, p. 592, 1927.  
 MEYER, F. W.—*Klin. Monatsbl. f. Augenheilk.*, Vol. C, p. 377, 1938.  
 MYLIUS, K.—*Zeitschr. f. Augenheilk.*, Vol. LXV, p. 71, 1928.  
 OSTERBERG.—*Brit. Jl. Ophthal.*, Vol. XXII, p. 145, 1939.  
 PAUTRIER, L. M.—*Ann. Derm. Syph.*, Vol. VII, p. 433, 1936.  
 REIS, W. and ROTHFIELD, J.—*v. Graefe's Archiv. f. Ophthal.*, Vol. CXXVI, p. 357, 1931.  
 SCHOEPPE, H.—*Klin. Monatsbl. f. Augenheilk.*, Vol. LXV, p. 812, 1920.  
 SCHUMAEKER, G.—*Münch. med. Wochschr.*, Vol. LVI, p. 2664, 1909.  
 SEEFELDER, R.—*Arch. f. Augenheilk.*, Vol. CV, p. 664, 1932.  
 STALLARD, H. B. and TAIT, C. B. V.—*Lancet*, p. 440, February, 1939.  
 STUMPKE, G.—*Derm. Z.*, Vol. XX, p. 199, 1913.

---

## A CASE OF CHRONIC GRANULOMA OF THE LACRYMAL SAC

BY

H. B. STALLARD

R.A.M.C.

THE following case of a swelling in the lacrymal sac is of some interest from the point of view of differential diagnosis. It also illustrates the necessity for a thorough examination in such cases. In this instance radiography played a very important part in determining the cause of the swelling which was eventually confirmed by the microscope.

R. H., aged 68 years, was referred to the Radium Institute in March, 1939, on account of a swelling of the right inner canthus which was believed by his ophthalmic surgeon to be a malignant neoplasm and for which he considered radiotherapy was necessary. Mr. Roy Ward invited me to see this patient.

For 33 years the patient had suffered from right dacryocystitis and for 3 years there had been a swelling at the right inner canthus which was increasing in size.

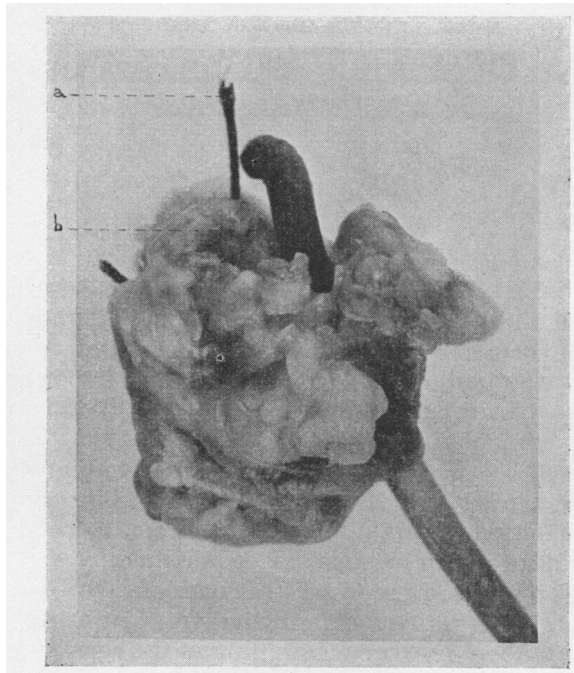
The inner canthus was enlarged and drawn downwards and nasalwards. A firm elastic swelling 2.5 cm. long by 1.5 cm. wide, occupied the site of the lacrymal sac and the caruncle and it was

attached to the lacrymal and ethmoidal bones. There was a muco-purulent discharge from both puncta and from the surface of the pinkish, nodular, fungating swelling which replaced the caruncle.

On syringing the lacrymal passages the saline returned immediately along the canaliculus through which irrigation was attempted. It was evident that the lacrymal sac was occluded. Nasal inspection and general medical examination revealed no abnormality. The Wassermann and Sigma reactions were negative.

Radiography showed the presence of a metal style in the right naso-lacrymal duct and some thickening of the mucosa of the right maxillary antrum. The patient was unaware that a style had been left in the naso-lacrymal duct during treatment for epiphora 33 years ago.

*Operation.*—Through a curved incision over the lacrymal fossa the swelling was dissected out. It was attached by dense adhesions to the lacrymal bone and frontal process of the maxilla



Photograph of chronic granuloma tranversed by blackened silver style.

- a.* Suture identifying upper pole.
- b.* Style.

and also to the conjunctiva at the inner canthus. After removal of the swelling the canaliculi were curetted, the conjunctiva and skin of the inner canthus were reconstructed by a plastic procedure. Post-operative healing was uneventful.

*Pathological report.*—The figure is a photograph of the macroscopic appearance of the excised mass with the blackened silver style running through it. Transverse and vertical sections showed squamous epithelium overlying fibrotic granulation tissue infiltrated by plasma cells, lymphocytes and eosinophils. In some areas there were deposits of metallic pigment. There was no evidence of malignancy.

### Comment

This case is an example of chronic inflammation set up by the retention of a metallic foreign body. The author recollects a specimen sent to the Pathological Laboratory at The Royal London Ophthalmic (Moorfields Eye) Hospital of an "orbital neoplasm" removed by exenteration of a socket, the eye had been excised some years before at a provincial hospital and the pathological report could not be traced. The surgeon who exenterated the socket was of opinion that the hard swelling in the orbit and the brownish-black conjunctival discharge suggested a malignant melanoma, possibly a recurrence from such a growth in the uveal tract for which the eye might have been removed. The specimen contained a blackened silver filigree ball inserted into Tenon's capsule after excision of the eye. The interstices and centre of the filigree were filled with dense fibrous and granulation tissue. The presence of this foreign body explained the inflammation and brownish-black discharge.

### Summary

The case reported is a chronic granuloma of the right lacrymal sac due to the accidental retention of a silver style for 33 years.

---

---

## ANNOTATION

---

### Incidence and Distribution of Trachoma in the United States

The sight-saving review of March, 1940, contains an interesting paper dealing with trachoma in the United States by Dr. Harry S. Gradle. He finds that trachoma is distributed roughly as follows: (a) among the American born Caucasians in endemic form; (b) among foreign immigrants; (c) among Asiatics and Mexicans who have