

# THE BRITISH JOURNAL

OF

## OPHTHALMOLOGY

OCTOBER, 1941

### COMMUNICATIONS

---

#### HEREDITARY OPTIC ATROPHY WITH DOMINANT TRANSMISSION AND EARLY ONSET

BY

J. GRAHAM SCOTT

GLASGOW

#### Review of Published Cases

CASES of dominant heredity with early onset have been reported by Batten,<sup>1</sup> Doyne,<sup>2</sup> Knapp,<sup>3</sup> Gunn,<sup>4</sup> Lawson,<sup>5</sup> Clemesha,<sup>6</sup> Posey,<sup>7</sup> Fisher,<sup>8</sup> Griscom,<sup>9</sup> Alsberg,<sup>10</sup> Herzog,<sup>11</sup> Isayama,<sup>12</sup> Thompson and Cashell,<sup>13</sup> and Riedl.<sup>14</sup>

In 14 families, there are reports of 83 cases of optic atrophy.

(1) *Inheritance*.—In almost every case the atrophy is directly inherited from an affected parent; from a male in 20 cases, from a female in 19 cases.

In two cases (Griscom's) the atrophy is passed on from an unaffected parent. In this pedigree, as in Thompson's, there is evidence of sex linkage.

In two pedigrees (Knapp and Alsberg) the atrophy is transmitted from a case of Leber's disease.

(2) *Sex Incidence*.—Of affected cases, 47 are male, and 36 are female.

(3) *Age of Onset*.—It is difficult to record the age at which early failure of vision occurs.

If one may assume that the presence of nystagmus indicates a congenital failure of central vision, 11 cases of the 83 are congenital, 25 are stated to be congenital. 30 cases are noted about school age, 9 are not known, and 8 are first noted between 8 and 12 years of age.

(4) *Signs and Symptoms*.—It is exceptional for the onset of blurring of vision to be noticed.

In few cases is there a history of any improvement or of any marked deterioration of the condition.

Except in Lawson's and Gunn's cases, both eyes are affected.

(5) *Fields of Vision*.

Recorded in 44 cases. Contraction of periphery in 22 cases. Central scotoma in 5 cases. Paracentral scotoma in 8 cases. Riedl finds examples of hemianopic and quadrantic colour defects.

(6) *Ophthalmoscopic Appearance*.

The fundus in all affected cases shows a pale disc with clear cut edges (the pallor being more marked on the temporal half).

In some cases the vessels are normal, and in others they are contracted. Deep cupping is noted in most cases. The remainder of the fundus is normal except in Griscom's cases where he notes some fine scattered retinal pigmentation.

(7) *Association with other disabilities*.

There is no association with other disabilities.

X-Ray of sella shows no enlargement.

In one case, a cellular shadow fills the sella. (Fisher.)

No case of abnormal adiposity, of diabetes, of hypo- or of hypergenitalism is reported.

### Author's Cases

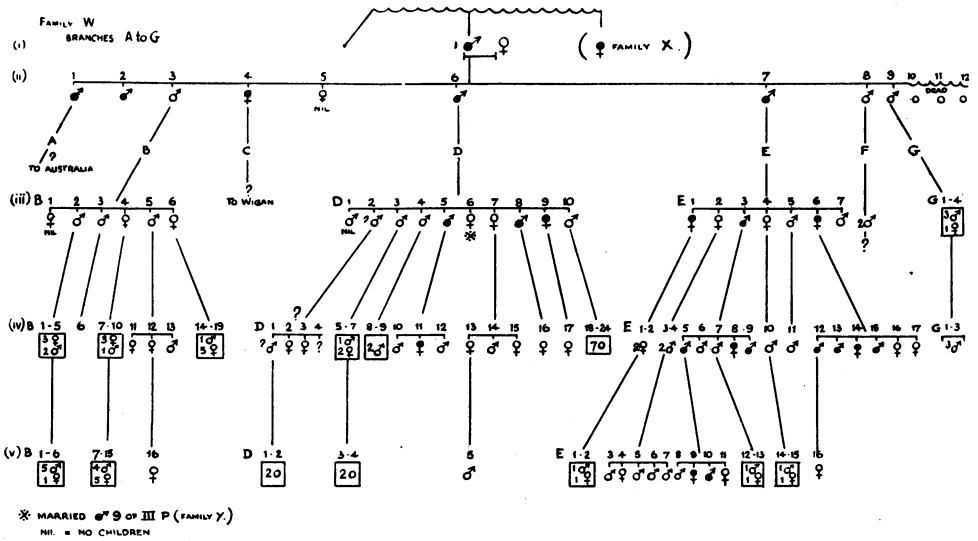
It is desired to record two families, totalling over 250 members, presenting 61 cases of optic atrophy. For convenience in recording, one family has been divided into "family W" and "family X"; the other is "family Y." The branches are called A, B, C, etc. Family Y is reputed to inter-marry.

The two families live in the same district, but no relationship is claimed. The individuals are healthy, industrious, long-lived, with no family defect other than optic atrophy.

There is no mental deficiency, or obvious endocrine dysfunction. There are no signs of specific disease and the Wassermann reaction is negative in 6 cases. No case with deafness or with loss of smell or taste is found. The causes of death present no significant factor.

I have seen 32 of the affected cases, 22 in their home, 8 as out-patients and 2 as in-patients in hospital.

The 10 hospital patients had a complete examination of C.N.S., 6 had blood count and Wassermann reaction test, 4 had X-Ray of sella and of sinuses. The 2 in-patients had a 24-hour urine test and C.S.F. examination. These tests showed no abnormality. I have also examined 37 unaffected members and find them normal.



FAMILY W.

Generation (ii) are all dead, but the wife of 9, Generation (ii) is alive, and is able to give me information about the parents Generation (i) with whom she lived for nine years.

No. 1 of Generation (i) was a preacher, and used to be able to read the Bible, but always had difficulty in recognising his friends in the street. Glasses did not help him. His wife was illiterate, but wore glasses and was able to see quite well. They were not related before marriage. There were brothers and sisters of whom she can remember little.

The same informant is able to give me the following information about the members of Generation (ii). This has been substantially confirmed by the members of Generation (iii).

GENERATION (ii).

- 1.—Always had poor sight. Went to Australia.
- 2.—Had poor sight and did not marry.
- 3.—Was an engine driver and had good sight.
- 4.—Had bad sight, and some of her children have poor sight, but they moved to Wigan, and cannot be traced.

5.—Had good sight but no children.

6.—Always had bad sight, which is confirmed by his daughters. Died aged about 70 years, and had diabetes in his latter years.

7.—Had bad sight, and stated that it was just the same all his life. He was able to go about by himself until the last three years, when cataract developed. He died aged 71 years of "old age." He stated frequently that he was able to see better at night. He found glasses no use and his sight did not change at all until cataract developed.

8.—Had good sight. Went to Crewe; his two sons have good sight.

9.—Had good sight. Died aged 40 years of pernicious anaemia.

10, 11, 12.—There were 3 still-born children, whose placing in the family is not known.

#### GENERATION (iii).

5B.—Aged 56 years. Good sight. Can see all colours. Vision R. and L. 6/9. J.1. Fundi normal. Agrees with daughter that there is no bad sight in their side of the family.

2D.—This case moved to Halifax, and little is remembered about him. He has been "bombed out" recently, and cannot be traced. There is contradictory evidence as to whether he and his family have poor sight.

5D.—Aged 58 years. Always had poor sight. Can see better in the dark. Sees no colours. Vision R. and L. 3/60. Can read less than J.20. Fields normal at periphery (tested by hand). Discs white, clear edges. No cupping. Vessels normal. Works as miner.

6D.—Aged 54 years. Vision R. and L. 6/9. J.1. All colours. Fundi normal. This was surprising as her children had atrophic discs. It transpired that her husband, who died aged 40 years of peritonitis, had always had bad sight. An investigation into the husband's family showed that hereditary optic atrophy of early onset was present. No relationship is known or can be established by inquiry. The children are shown in Pedigree Y.

7D.—Aged 52 years. Vision R. and L. 6/9. J.1. All colours. Fundi normal. Remembers father passing her in the street, and that his sight was always bad.

1E.—Aged 68 years. Sight always poor. Worse in last ten years with cataract. R. cataract removed when aged 64 years. Vision R. 4/60. Reads J.20. Vision L. Hand-movements. Disc R. white. No cupping. Edges clear cut. Vessels slightly narrow. No degeneration at macula. Disc L. cannot be seen due to cataract.

2E.—Aged 66 years. Vision R. and L. 6/9. J.2. Colours fair. Fundi normal.

3E.—Aged 64 years. Always had poor sight. First noted when

he went to school. Sight has not altered. Vision R. and L. 5/60. J.12. No colours. Fields normal at periphery. Discs white with deep cupping. Vessels normal.

4E.—Aged 63 years. Good sight. Vision R. and L. 6/9. Reads J.1. All colours. Fields normal. Fundi normal. Slight lens changes.

6E.—Aged 60 years. Poor sight. Noted before she went to school. Sight has not altered until recently, when it has become worse. Fields normal at periphery with 3/330. No central scotoma with 5mm./1000. (Great difficulty in seeing smaller spots.) Discs strikingly white. Deep cupping. Central nervous system and blood pressure normal. No deafness. X-Ray shows normal sella. Wassermann reaction negative. Vision R. and L. 2/60. Reads less than J.20. Colours —.\*

#### GENERATION (iv).

11B.—Aged 36 years. Vision R. and L. 6/6. Reads J.1 and all colours. Fundi normal.

12B.—Aged 32 years. Vision R. 6/6. J.1. All colours. Vision L. 6/36. J.8. Few colours. Fundus R. and L. normal. No strabismus. L. eye hypermetropic.

13B.—Aged 20 years. Vision R. and L. 6/6. J.1. All colours. Fundi normal.

1D.—Supposed to have bad sight, but the family have been bombed out, and it has not been possible to trace them. 11D knows him, and thinks his sight is as bad as hers.

11D.—Aged 27 years. Sight has always been bad. First noted at school. Left school in standard 7. Vision R. 6/60. J.12. Colours x. Vision L. 4/60. J.20. Colours —. Discs pale with deep cupping on temporal side.

12D.—Aged 19 years. Vision R. and L. 6/6. J.1. All colours. Fundi normal.

13D.—Aged 32 years. Vision R. and L. 6/6. J.1. All colours. Fundi normal.

14D.—Aged 28 years. Vision R. and L. 6/6. J.1. All colours. Fundi normal.

15D.—Aged 11 years. Vision R. and L. 6/6. J.1. All colours. Fundi normal.

1E.—Aged 34 years. Vision R. and L. 6/6. J.1. All colours. Fundi normal.

4E.—Aged 33 years. Vision R. and L. 6/6. J.1. Red-green blind. Fundi normal.

5E.—Aged 32 years. Always had poor sight. First noted at school. Vision R. 6/60. J.12. Colours —. Vision L. 4/60. J.20.

\* Colour —, x, or xx, is explained in Table of Visual Acuity.

Colours —. Fields normal at periphery. Discs white with cupping. Remainder of fundus normal, except usual reflex absent from macula. Vessels normal.

6E.—Drowned at 7. Sight was good.

7E.—Aged 30 years. Vision R. and L. 6/6. J.1. All colours. Fundi normal.

8E.—Aged 24 years. Always had poor sight. First noted at school. Enjoys reading novels. Vision R. and L. 6/24. J.8. Colours x. Peripheral fields normal. Discs notably white, more so in temporal half.

9E.—Aged 19 years. Has always had poor sight. Vision R. and L. 6/36. J.8. Colours xx. Peripheral fields normal. Discs grey-white. No bright reflex at macula. Vessels normal.

10E.—Aged 40 years. Vision R. +5.00 D. sph. +1.50 D. cyl. 135°. 6/12. J.2. L. +6.00 D. sph. 6/6. J.1. All colours. Fundi normal. Internal strabismus (only without glasses).

11E.—Aged 21 years. In R.A.F. Reports that vision is 6/6.

12E.—Aged 31 years. Always had poor sight. First noted when he went to school. Vision R. and L. 3/60. Less than J.20. Colours x. Fields, normal with 10/330 and 3/330 in periphery. Limited to 25° with 10/2000. To 8° with 6/2000, and to 3° with 4/2000. A 2/2000 spot could not be seen. The 4/2000 spot was seen more clearly away from the fixation spot.

Colours could not be recognised with 10/1000 spot, but with 10/100 spot red was recognisable at roughly 20° and tended to fade as it approached 0°. Fading was not confirmed with other colours.

Discs, pale with deep white cup extending to temporal side. Vessels normal. Wassermann reaction negative. Blood count normal. C.N.S. normal.

13E.—Aged 28 years. Saw well at primary school, but he found at seven that sight was poor (at secondary school), and had to sit in front. Left school at 14 in standard 7. Has been working as fitter's labourer, but could not accept promotion on account of difficulty in reading instruments. Has noticed no variation in sight. Vision R. and L. 6/60. J.8. Colours x. Fields, normal with 10. 3. and 1 mm. spot/330. Limited to 10° with 4/2000 spot, but 2/2000 spot not seen anywhere. The 4/2000 spot was seen as well at 0° as at 5° or 10°.

Colour fields are full in the periphery with 10/330 spot but cannot be recognised with 5/330 spot. There was difficulty in recognising a 20/1000 colour spot, but, with 20/600, colour was recognised more easily at 10° than at 0°. Red and green fields are similar, and both are greater than blue. Acuity of vision in the periphery is as good as that of two normal persons, as tested by minimum visible separation of two 3/330 white spots (5° apart, 45° out).

Discs grey, with deep white cupping. Remainder of fundus normal, but no normal reflex at macula. Urine: no albumin, and no sugar. C.N.S. no abnormality. Wassermann reaction negative. X-Ray: normal sella. Blood count 4,983,000 reds, 6,800 whites. Differential count: Polymorphs 52 per cent., Lymphocytes 43 per cent., Mononuclears 4 per cent., Eosinophiles 1 per cent., no Punctate Basophilia. Lumbar puncture, no increased pressure. Fluid clear. White cells 10 per c.mm. Protein 30 mg. per cent. no organisms. There was no hyperaemia of disc following puncture.

14E.—Aged 26 years. Has never been able to recognise friends in the street for as long as she can remember. Sat in front row at school. Had to come out to see the board. Glasses no help. Sight has not varied. Vision R. 3/60. J.20. Vision L. 3/60. J.12. Colours x. Peripheral fields normal with 3 mm./330. No central scotoma on Bjerrum screen 5/1000, but 1/1000 cannot be seen. No difference in shade of colour in periphery or centre with 20/1000, though colour not easily recognised. Fundus grey, with deep white cupping extending up to temporal margin. Edge clear cut. C.N.S. no abnormality. Wassermann reaction negative. X-Ray, sella within normal limits. Blood count: no abnormality.

15E.—Aged 23 years. Always had poor sight. Had to sit in front at school. Vision R. and L. 4/60. J.12. Colours x. Fields R. and L. slight peripheral contraction with 3/330. No central scotoma on Bjerrum screen with 10/1000, but 2/1000 could not be seen. Pupils react to light, but sluggishly on accommodation. There is a paresis of the right external rectus. He had diphtheria at the age of 7 years. Central nervous system presents no other abnormality. Wassermann reaction negative. Blood count normal. Discs grey nasal half, white temporal half, deep cupping. Vessels normal.

16E.—Aged 22 years. Vision R. and L. 6/9. J.1. Colours good. R. and L. fundus normal, but both present very deep physiological cupping. (Striking physical resemblance to mother who has optic atrophy.)

17E.—Aged 19 years. Vision R. and L. 6/6. J.1. All colours. Fields very full with 3 mm./330 white.

#### GENERATION (v).

16B.—Aged 3 years. Sight stated to be perfect. Disc R. and L. normal.

5D.—Aged 11 years. Vision R. and L. 6/6. J.1. Red-green blind.

1E.—Aged 4 years. Sight said to be good. Can see distant aeroplane. Fundi normal. Choroidal vessels visible in periphery.

2E.—Aged 2 years. Sight said to be good. Fundi no gross abnormality (undilated).

8E.—Aged 12 years. Vision R. and L. 6/6. J.1. All colours. Fundi normal.

9E.—Aged 10 years. Poor sight. First noted when she went to school, when she had to sit in front. Now can sit a little further back. Vision R. and L. 6/24. J.1. Colours x. Disc R. grey, with normal cupping. Disc L. similar, with one spot of pigment near nasal margin. Normal peripheral fields for white 3/330. Fields for red and green 25°, and 10° for blue, on Bjerrum screen at 1 m. with 22 mm. spot. No central scotoma for white with 2/1000.

10E.—Aged 7 years. Poor sight. First noted when he went to school when he had to sit in front. Iris brown (from healthy mother). Vision R. and L. 6/36. J.1. Disc R. grey nasal half, deep cupping extending to temporal margin. Disc L. grey and pale, with normal cupping. Normal peripheral fields for white 3/330. Colour fields, 30° for red and green, 20° for blue on Bjerrum screen at 1 m. with 22 mm. spot. Reads the following Ishihara numbers:—

Correct: 12.8.29. 5.15. 2.97. 5.16.—.—26.35.

R.: 12.8. 2.—.15.—.18.—.—.—26.35.

Correct: 12.6.57.3.74.6.45. 7.73.—.—42.96.

L.: 12.8.15.8.11.8.—.—.—.—42.96.

11E.—Aged 4 years. Sight said to be good. Fundi R. and L. normal.

12E.—Aged 7 years. Vision R. and L. 6/6. J.1. All colours. Fundi normal. Alternating strabismus.

13E.—Aged 4 years. Normal fundi.

14E.—Aged 12 years. Vision R. +5.00 D. sph. +1.00 D. cyl. 120°. 6/12. J.2. Vision L. +5.00 D. sph. +1.00 D. cyl. 120°. 6/6. J.1. Colour vision R. and L. normal. Fundus R. and L. normal.

15E.—Aged 10 years. Vision R. and L. 6/6. J.1. All colours. Fundi normal.

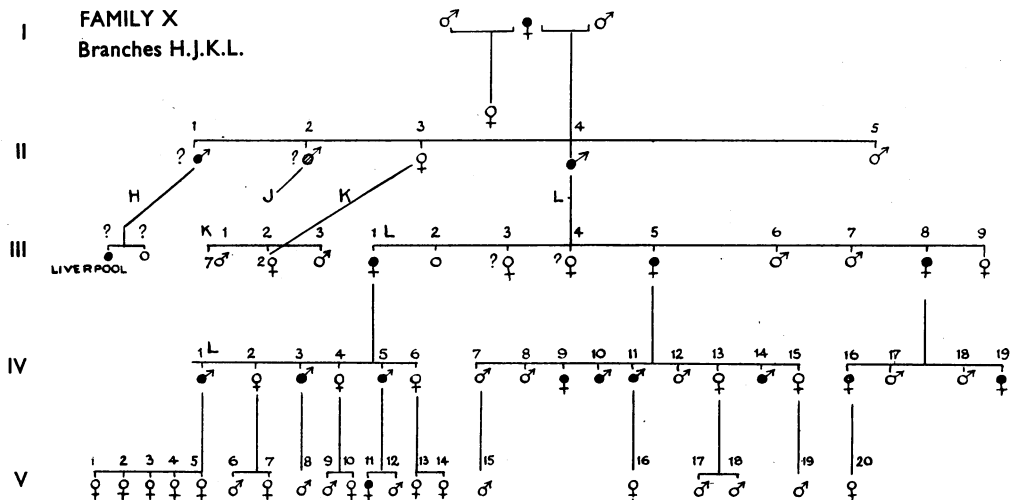
16E.—Aged 19/12. Can see aeroplane. There is no nystagmus. Disc R. very deep cupping. Temporal half of disc is pale, but within normal limits. Fundus L. normal. (Examined under atropine).

#### FAMILY X.

I am indebted to i) L of Generation (iii) (aged 74 years) for most of my information about generations (i) and (ii). Mrs. i) L states that her father and an uncle always had poor sight, and also her aunt in later life.

They all inherited it from her grandmother, whom she thinks was a sister or cousin of i) generation (i) of family W.





She states that branch H of the family have many cases of "the bad sight," but can give no details, and has lost touch with them.

She can give no information about branches J and K.

I traced the youngest son of K, who tells me that his mother's sight was good until she became old, and that none of his seven brothers or two sisters have poor sight, although he knows it runs in the family. His grandmother married twice, and was related to family W by birth.

#### GENERATION (iii).

*H*.—It is said that some members of branch H and their children have bad sight, but difficulties of travel have prevented further investigation.

*3K*.—Aged 69 years. Vision R. and L. 6/9. J.4. All colours. Fundi normal.

*1L*.—Aged 74 years. Vision R. and L. 4/60. J.20. Colours nil. Discs R. and L. white. No pigment changes. Vessels normal. Fields normal in periphery by hand.

*2L*.—Died young. Three and 4L are stated to have good sight.

*5L*.—Aged 61 years. Vision R. and L. 2/60. Less than J.20. Colours nil. Disc white with deep cupping. No change in vessels. Fields tested by hand, are contracted, but there is lack of concentration. Sight has not altered.

*8L*.—Aged 50 years. Always had poor sight. Passes husband in street, but can get around on her own. Vision R. and L. 4/60. J.20. No colours. Discs white with deep cupping extending to temporal border. Fields normal with 3mm. spot/330. No scotoma on Bjerrum screen with 5mm. spot at 1000. Cannot see 5/2000 spot.

## GENERATION (iv).

1L.—Aged ? . Has always had bad sight. Was told by specialist that nerve was dead and that no one could help him. He declined to be examined.

3L.—Aged 40 years. Vision R. and L. 6/60. J.12. Colours —. Disc atrophic with deep cup. Fields normal in periphery.

9L.—Aged 34 years. Sight always bad. Sat in front at school, but had to ask the others what was on the board. Thinks sight is worse in last five years, *e.g.*, cannot see to read so well; she used to be able to recognise her friends in the street, but cannot do so now. Vision R. and L. 5/60. J.20. Colours nil. Disc very atrophic. Deep cup extends to temporal margin, and well over to nasal margin, which is grey. The arterioles crossing the nasal margin do not dip. Vessels normal. Fields normal in periphery by hand.

11L.—Aged 29 years. Sight has always been poor. Has not altered. Vision R. and L. 3/60. J.12. Colours x. Fundus R. and L. Pale with deep cup. Edge clear. Fields normal in periphery with 3/330 white. No scotoma with 5/1000 white, but 5/2000 cannot be seen. Colour fields reduced to 5° with 20/330 red and green, and to 3° for blue. Blood count normal. Wassermann reaction negative. C.N.S. No abnormality. C.S.F. Clear fluid, no increased pressure. Cells 5 per c.mm., protein 20 m.g.m., chlorides 780 m.g.m., no organisms. Wassermann reaction negative. Lange oooooooooo. No hyperaemia of disc after lumbar puncture.

13L.—Aged 24 years. Vision R. and L. 6/6. J.1. All colours. Fundus R. and L. deep physiological cupping. Very marked in left fundus.

14L.—Aged 23 years. Sight has always been bad. Vision R. and L. 3/60. Less than J.20. No colours. Field normal by hand. Disc white with cupping. Vessels normal.

15L.—Aged 21 years. Vision R. and L. 6/6. J.1. All colours. Fundi normal.

16L.—Aged 24 years. Has always had poor sight. First noted when she went to primary school from the age of 5 to 11 years. She was then sent to blind school in case her sight should get worse. She is the only member in the two families who went to blind school. Her sight has never varied. Vision R. and L. 6/60. J.12. No colours. Discs R. and L. white, with deep cupping. No other abnormality. Fields very full with 3mm. spot/330. No central scotoma on Bjerrum screen with 10/1000. Could not see 2/1000.

17L.—Joined Army as A1. Sight presumed to be good.

18L.—Aged 18 years. Has always had good sight and has noticed no change whatsoever in either eye. Vision R. and L. 6/6.

J.1. Colours practically all correct but read haltingly by R. and L. eye. Fields by hand—normal. Fundus R. striking pallor of temporal half of disc with cupping. Fundus L. normal disc.

19L.—Aged 13 years. Began school aged 4 years. She happened to be seated near the board, and had no difficulty in seeing the letters until she moved to the "Big" school at the age of 12 (in September, 1940). She then found she could not see the board, but had previously noticed that her sight had begun to fail in the last two years (since February, 1939), when she was 10. Her periods began in April, 1940. On enquiry, it was found that she had annual tests at school, and she stated that she could read to the foot of the card until June, 1940, when she could only see the top three rows; also, she used to be able to recognise friends in the street, but about two years ago noticed she could not see their faces until they were close. On being asked if she had noticed anything else, replied "I used to be able to see the colour of my friends' dresses further off than I can do now." Vision R. and L. 6/24. J.2. Colours as follows:

Correct: 12.8.6.29.57.5.3.15.74. 2.6.97.45.5.7.16.73.—.—.—.26.42.35.96.

R.: 12.8.6.28.57.5.3.15.97. 8.6.87.46.3.4.16.23. 5.—.46.—.26.46.35.90.

L.: 12.8.5.29.57.5.8.46.97.13.6.67.48.6.7.46.—.—.—.46.—.76.—.46.—.

Discs: Pale temporal half, grey nasal half, with normal cupping. Vessels normal. Fields normal with 3mm. spot/330. No central scotoma on Bjerrum screen with 5/1000 but could not see 2/2000 spot. Central nervous system, no abnormality.

#### GENERATION (v).

1L.—Aged 20 years. Vision R. and L. 6/6. J.1. All colours. Fundi normal.

3L.—Aged 16 years. Vision R. and L. 6/6. J.1. All colours. Fundi normal.

4L.—Aged 14 years. Vision R. and L. 6/6. J.1. All colours. Fundi normal. "Other two sisters have perfect vision" it is stated.

8L.—Aged 4 years. Appears to have good vision. Discs pale, but within normal limits.

11L.—Aged 8 years. Vision R. and L. 6/60. J.12. Colours xxx. Fundus R. and L. bluey white temporal half of disc, nasal half grey. Normal cupping.

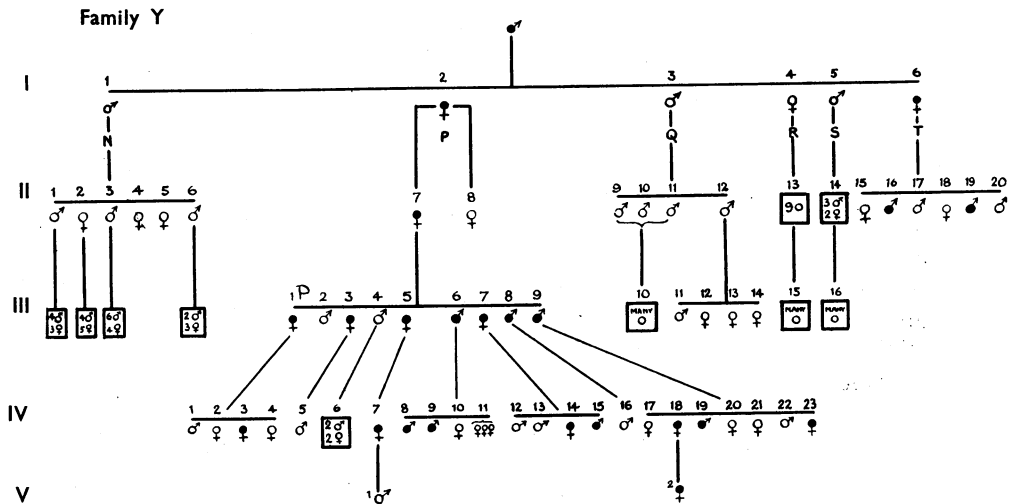
16L.—Aged 4 years. Fundi examined under atropine. Disc R. normal. Fundus presents few scattered spots of pigment. Disc L. pale, but within normal limits. No marked cupping. No bluish appearance.

17L.—Aged 2½ years. Appears to see well. Fundi could not be seen.

18L.—Aged 4/12 years. Can follow a light. No nystagmus.

19L.—Aged 9/12 years. Can recognise mother 300 yards away.

20L.—Aged 11/12 years. Fundi examined under atropine. Discs normal. Few scattered spots of pigment in periphery of fundus.



### FAMILY Y

I am indebted to Mrs. W (5N of Generation (ii), aged 78 years) for most of my information about the earlier generations of this family.

Much of her information has been corroborated by Mr. W, the father of 7P, Generation (iv), who was in the same class as 19T, Generation (ii), and remembers the latter having to sit in front at school. Mr. W married 5P, Generation (iii), and remembers her relations well.

Mrs. W (5N) remembers her grandfather very slightly, but has heard her father speak of the former's poor sight, and that he could not get glasses to help him.

She remembers her aunts (2 and 6 of Generation (i)) who always had poor sight.

Her own branch of the family has no eye trouble, and she has heard of none in branches Q, R and S, where there are by now many relations.

13Q of Generation (iii) was able to confirm this, but was unable to say how many first and second cousins she had.

Branch T all went to America and have sent no news.

## GENERATION (iii).

8P.—Aged 65 years. Always had poor sight, which ran in the family, and came from his mother's side. Vision R. 3/60. J.20. Colours +. Vision L. 2/60. Less than J.20. Colours —. Fundus R. atrophy of disc with cup. Vessels normal. Fundus L. cannot be clearly seen owing to lens changes.

9P.—Died at 40 of peritonitis. Married 6D, Generation (iii) of family W. His brother (8P) states that 9P always had bad sight, and his wife knows that he could get no glasses to help him.

13Q.—Aged 46 years. Sight has always been good, and states there is no bad sight on her side of the family. Her cousins have all good sight.

## GENERATION (iv).

7P.—Bad sight noticed when she went to school aged about 4 years. She was able to see when seated in front at primary school, but was unable to see the board at secondary school where the boards are higher and not so well illuminated. She can see better outside at night. Thinks sight is somewhat worse in last three years. She taught for a few years at school, but was unable to read the children's writing. Vision R. and L. 6/60. J.6. Colours ++. Discs atrophic with deep cup. Vessels normal.

11P.—3 died young.

18P.—Aged 30 years. Always had poor sight. Vision R. 6/60. J.20. Colours —. Vision L. 6/36. J.12. Colours x. Disc R. and L. white with normal cup. Vessels normal. Fields normal by hand.

20P.—Aged 22 years. Vision R. and L. 6/6. J.1. All colours. Fundi normal.

23P.—Aged 17 years. Always had poor sight. First noted at school. Vision R. and L. 6/60. J.12. Colours x. Disc white with deep cup, more marked on temporal side. There is a spot of pigment on left disc. Fields normal by hand.

## GENERATION (v).

1P.—Aged 4 years. Tested by his mother. Can see father at 300 yards. Sight supposed to be good. Fundus R. very deep cup and pallor of temporal disc margin. The nasal half is pink. Appearance is frankly suspicious. Fundus L. normal. Disc edges R. and L. clear cut.

2P.—Aged 4 years. Happy healthy child, full of vitality. Mother is sure her sight is good. Disc—blue-white, R. and L. more marked in temporal half. An attempt was made to test vision and colours. Both appear to be less than normal, but she can recognise her mother at 100 yards.

### Discussion of Cases

(1) *Mode of Inheritance*.—In every case the inheritance is direct from an affected parent; from a male in 29 cases and from a female in 29 cases.

The following table illustrates the distribution in the two families:

		Inheritance from	
		Male	Female
Family W	...	17	4
Family X	...	5	10
Family Y	...	7	15
Total	...	29	29

There is no evidence of a sex-linked transmission.

In no case did atrophy develop from an unaffected parent.

In one case, an unaffected female of family W married an affected male of family Y. Their children were not affected more heavily than those of other branches.

These facts suggest a dominant autosomal inheritance from one parent heterozygous affected. On this point, the author's cases differ from some of the published pedigrees.

In the families, almost without exception, the colour of the iris is blue. It was wondered if the introduction of a brown iris from a healthy parent would affect the transmission. This is not so. Case 10E, Generation (v) inherits brown irides from his healthy mother, but inherits optic atrophy from his father who has blue eyes. It was also wondered if inheriting a strong family resemblance would carry the taint, but 16E, Generation (iv), who is a typical member of family W, has healthy eyes.

Cases 4E and 6E, Generation (iii), are identical in appearance, but only one has optic atrophy.

(2) *Sex Incidence*.—The following table illustrates the sex incidence in the affected branches:

		Affected		Unaffected	
		Males	Females	Males	Females
Family W	...	14	8	15	13
Family X	...	8	8	10	16
Family Y	...	10	13	13	13
Total	...	32	29	38	42

(3) *Age of Onset*.—As no case presents nystagmus, the onset is not congenital.

As the earliest atrophic disc is seen in a case aged 4, it is presumed that the age of onset is about 3 years of age.

In most cases, onset is not discovered until at Primary school (age 5) or, in a few cases, until at Secondary school (age 7).

One case (19L, gen. iv) gives a history of noticing onset at 10. Her brother (age 18) has noticed no change in vision (which is 6/6) but has one disc of more than normal pallor.

(4) *Signs and Symptoms*.—Thirty of the 32 cases seen were unaware of defective sight until it was discovered at school, when they had to sit in front. Most patients claim to see as well, or better, at night. A history of failing or improving sight is exceptional. Glasses do not help.

Common complaints are: (1) being unable to recognise friends in the street; (2) having to refuse promotion on account of poor vision. Only one case (16L) was educated at a Blind school.

No case is myopic and the majority have +1.0 or +2.0 D. of hypermetropia. Corrected visual acuity is recorded in the following tables:

It will be seen that the distant vision varies only slightly between cases aged 4 and cases aged 74. The reading vision shows a gradual change, but it is noticeable that the younger children can see remarkably well, and that there is little variation from 20 to 60 years. It is when we come to colour tests that the most notable differences are seen. Practically none of Generation (iii) can see any colours, but some in Generation (v) have normal colour vision, and all can distinguish bright colours with ease.

The colour test used throughout was that of the coloured numbers devised by Ishihara. The No. 12, composed of red dots on a bright blue background, presented difficulty to most. If the patient could distinguish no colours, he was marked —. If he could distinguish red and blue, but no number, he was marked x. If he could read No. 12, he was marked xx. If he could see a few of the following numbers he was marked xxx. Most numbers xxxx. All numbers xxxxx.

It was noteworthy that no case saw the "Blank" numbers, designed to be seen by the colour blind.

Two of the normal cases were found to be red-green colour blind, but the remainder had perfect colour vision.

*Vision in the Dark*.—Four cases were tested in a very poor light, and could see nearly as well as in bright daylight.

*Pupil Reflexes*.—In all cases (except one who has had diphtheria) pupils are circular and equal: they react briskly to light and on accommodation. Consensual reflex is present. There is no hippus. In no case is nystagmus found. The range of eye movements is full and normal.

(5) *Fields of Vision*.—Except in two cases, peripheral field of vision is normal. 10 cases tested with 3/330 Lister perimeter and 11 cases by hand. With the smallest visible spot it is not possible

TABLE OF  
CORRECTED VISUAL ACUITY  
in FAMILIES 'W. & X.' and 'Y.'  
arranged in corresponding generations.

GENERATION (iii)

Case No.	5D		1E		3E		6E		1L		5L		8L		8P	
	R	L	R	L	R	L	R	L	R	L	R	L	R	L	R	L
Snellen Type ...	3	3	4	@	5	5	2	2	4	4	2	2	4	4	3	2@
Jaeger Type ...	60	60	60	60	60	60	60	60	60	60	60	60	60	60	60	60
Colour ...	20	20	20	—	12	12	—	—	20	20	20	20	20	20	20	—
Age ...	58	68	64	60	74	61	50	65								

GENERATION (iv)

Case No.	11D		5E		8E		9E		12E		13E		14E		15E		3L		9L		11L		14L		16L		19L		7P		18P		23P				
	R	L	R	L	R	L	R	L	R	L	R	L	R	L	R	L	R	L	R	L	R	L	R	L	R	L	R	L	R	L	R	L					
Snellen Type ...	6	4	6	6	6	6	6	6	3	3	6	6	3	3	6	6	6	6	6	5	5	3	3	3	3	6	6	6	6	6	6	6	6	6	6	6	
Jaeger Type ...	60	60	60	60	24	26	36	36	60	60	60	60	60	60	60	60	60	60	60	60	60	60	60	60	60	60	60	60	60	60	60	60	60	60	60	60	60
Colour ...	12	20	12	20	8	8	8	8	—	—	8	8	20	12	12	12	12	12	12	20	20	12	12	—	—	—	—	—	—	—	—	—	—	—	—	—	—
Age ...	27	32	24	19	31	28	26	23	40	34	29	22	24	30	32	30	17																				

GENERATION (v)

Case No.	14D		9E		10E		11K	
	R	L	R	L	R	L	R	L
Snellen Type ...	6	6	6	6	6	6	6	6
Jaeger Type ...	24	24	24	24	36	36	60	60
Colour ...	?	?	2	2	1	1	12	12
Age ...	4	12	7	8				

NOTE :—@ = cataract.

The signs used in denoting colour vision are :—

— = No colours.

x = Red and blue of (12) but can see no numbers.

xx = (12) but no other numbers.

xxx = (12) and some others.

xxxx = Nearly all numbers.

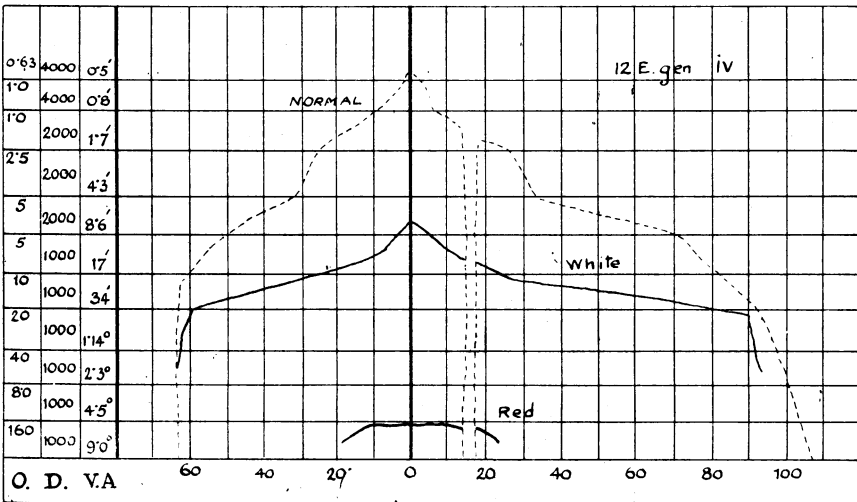
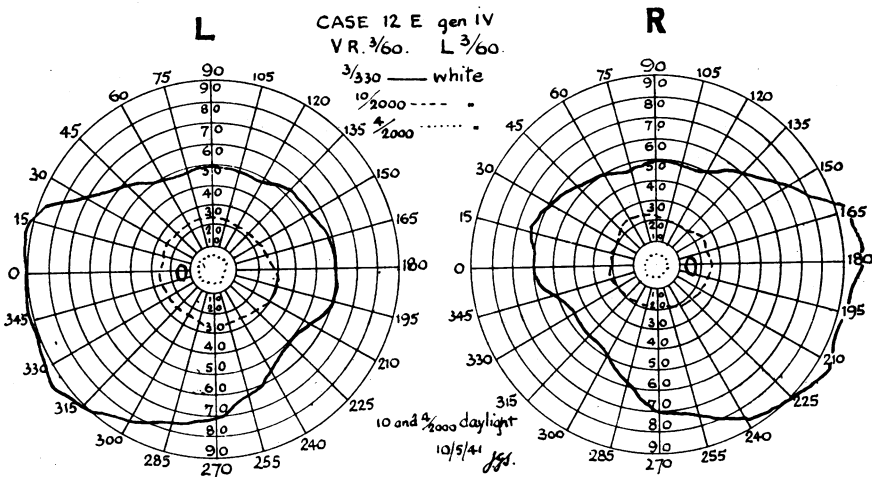
xxxxx = All numbers of Ishihara colour test.

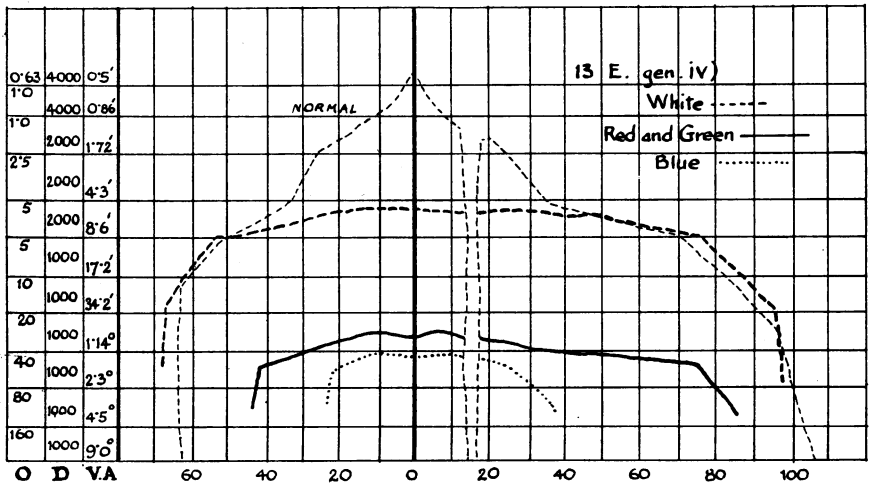
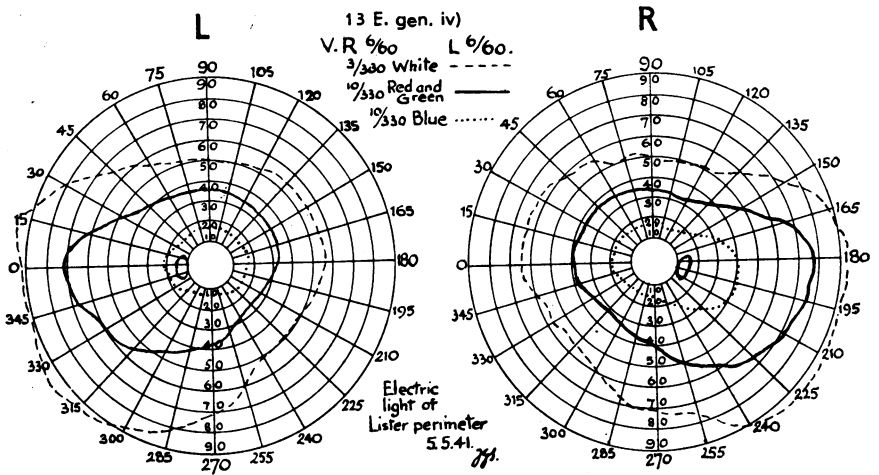


to demonstrate any scotoma which could be confirmed later. However, as the accompanying diagram shows, there is a scotoma involving the whole "peak" of the "hill of vision" (Traquair).<sup>15</sup>

Colour fields present a similar hill with larger visual angles, and there is an indication of an inverted tip at the peak of vision, but owing to the difficulty in recognising colours, this is not stressed.

It is noted that colour fields are reversed (*i.e.*, blue lies within red), and generally are contracted out of proportion with white. The blind spot presents no abnormality.





(6) *Ophthalmoscopic Appearance.*—The disc is pale. This is more marked in the temporal half, where a deep cup gives a blue-whiteness. The cup extends in some cases to the temporal margin. The nasal half is grey. The edges are clear cut and the vessels are normal.

Three cases do not present a deep cup, but the pallor is distinct, and they differ in no other respect.

No change is detected in the remainder of the fundus, with the exception that the normal reflex at the macula is replaced by a diffuse light reflex.

Apart from the degree of cupping, all affected discs are markedly similar.

(7) *Associated Disabilities*.—There is no association with any other disability.

### Summary

Sixty-one cases of hereditary optic atrophy have been investigated and the following points are made:

- (1) The inheritance is direct from affected male or female.
- (2) 32 males and 29 females are affected.
- (3) Onset is at about three years of age.
- (4) Onset is gradual and unnoticed. Colour vision is not lost early. There is no subsequent deterioration or improvement of visual acuity.
- (5) The base of the "hill of vision" is normal, but the peak is lost.
- (6) The disc is white, edges clear cut, deep cup.

The remainder of the fundus is normal, bar the absence of the normal light reflex at the macula.

I wish to thank the Army for permission to publish this article, my colleagues at a military hospital for their help, and Professor W. J. B. Riddell for advice.

### REFERENCES

1. BATTEN.—*Trans. Ophthalm. Soc. U.K.*, Vol. XVI, p. 125, 1896.
2. DOYNE.—*Ped.* 52, in Bowman Lecture. By Nettleship, *Trans. Ophthalm. Soc. U.K.*, Vol. XXIX, 1909.
3. KNAPP.—*Arch. of Ophthalm.*, Vol. XXXIII, p. 383, 1904.
4. GUNN.—*Trans. Ophthalm. Soc. U.K.*, Vol. XXVII, p. 221, 1897.
5. LAWSON.—*Trans. Ophthalm. Soc. U.K.*, Vol. XXVII, p. 169, 1907.
6. CLEMESHA.—*Amer. Jl. Ophthalm.*, Vol. XXVII, p. 139, 1910.
7. POSEY.—*Ann. of Ophthalm.*, Vol. XXIV, p. 423, 1915.
8. FISHER.—*Trans. Ophthalm. Soc. U.K.*, Vol. XXXVI, p. 298, 1916; Vol. XXXVII, p. 251, 1917.
9. GRISCOM.—*Amer. Jl. Ophthalm.*, Vol. IV, p. 347, 1921.
10. ALSBERG.—*Klin. Monatsbl. f. Augenheilk.*, Vol. LXXIX, p. 832, 1927.
11. HERZOG.—*Klin. Monatsbl. f. Augenheilk.*, Vol. LXXXIV, p. 536, 1930.
12. ISAYAMA.—*Acta Soc. Ophthalm. Japan*, Vol. XXXVIII, p. 144, 1934.
13. THOMPSON and CASHELL.—*Proc. Roy. Soc. Med.*, Vol. XXVIII, p. 1415, 1935.
14. RIEDL.—*Klin. Monatsbl. f. Augenheilk.*, Vol. XCV, p. 332, 1935.
15. TRAUQUAIR.—Introduction to Clinical Perimetry.

The majority of the cases have been summarised by Julia Bell in Treasury of Human Inheritance, Vol. II, Part 4, 1931; and by Riedl (14).