

Intra-nasal medication, supplemented, if necessary, by double antrostomy, may give sufficient confirmation, by the patient's recovery, without the necessity for exploration.

REFERENCES

1. CARROLL, F. D.—*Arch. of Ophthal.*, Vol. XXIV, p. 54, July, 1940.
2. FORD, ROSA.—*Proc. Roy. Soc. Med.*, Vol. XXIV (Sect. Ophthal.), pp. 35-40, May, 1931.
3. STEWART, D. STENHOUSE.—*Brit. Jl. Ophthal.*, Vol. XII, p. 413, 1928.
4. DUKE-ELDER, SIR STEWART.—*Text-book of Ophthal.*, Vol. III, p. 2988.

THE TONIC PUPIL SYNDROME

BY

PERCIVAL W. LEATHART

LIVERPOOL

IN 1924 and later in 1931 Foster Moore described this syndrome calling it "non luetic Argyll Robertson pupil." In 1931 Holmes described it under the name "partial iridoplegia." In 1931-32 Adie described it, introducing the term "tonic pupil." In their papers these pioneers do not suggest a lesion capable of producing the physical signs of the syndrome they describe. This paper is an attempt to do so.

The syndrome is recognised by three physical signs each of which points to some interference with the nervous mechanism of the internal muscles of the eye.

1. The pupillary reaction to light is absent or sluggish.
2. The affected pupil is larger than its fellow but will dilate further in the dark, and to atropine.
3. The pupillary reaction to convergence is slower than normal in spite of the fact that near vision is unaffected. The rest of the eye is normal in all respects. There is no external muscular paresis, no ptosis or nystagmus and no en- or exophthalmos. In a certain number of cases the knee jerks and ankle jerks are absent or reduced. The syndrome is commoner in women.

Before entering into a discussion with regard to the location of a lesion capable of producing the above physical signs, it is necessary to describe in some detail the anatomy of the primary ocular reflexes concerned. In this description reference to decussations is omitted for the sake of simplicity.

Rough diagrams are appended in order to make the descriptions less confusing.

Anatomy

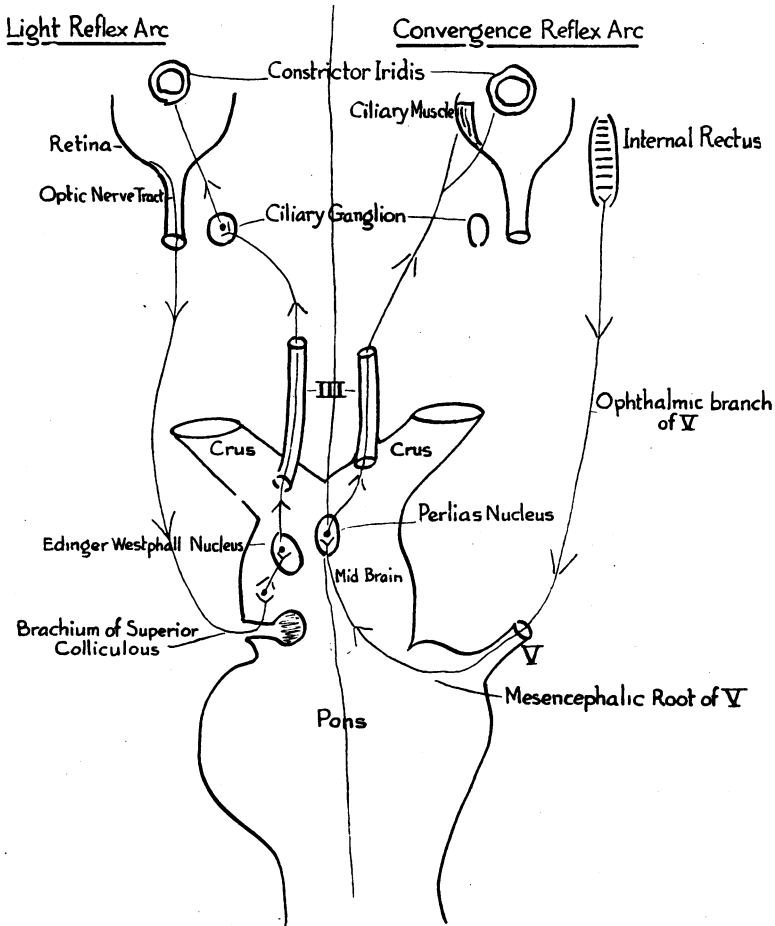
The nucleus of the parasympathetic portion of the motor oculi nerve consists of two portions.

1. *The Edinger-Westphall nucleus* which is a bilateral structure and is the nucleus of that portion of the parasympathetic which subserves the pupillary constrictor reflex to light.

2. *The nucleus of Perlia*—a mid-line structure—the nucleus of that part of the parasympathetic which subserves the convergence reflex and its ancillary pupillary constriction.

The light reflex consists of three parts, an afferent limb, a nucleus and an efferent limb.

The afferent limb leaves the retina and travels in the optic nerve and tract to reach the mid brain via the brachium of the superior colliculus. It by-passes this body to reach cells in the pretectal



area from which after a relay it passes to the Edinger-Westphall nucleus and here the afferent limb ends.

The efferent limb starting from the nucleus passes in the motor oculi nerve into the orbit, and leaves it via the nerve to inferior oblique to reach and relay in the ciliary ganglion. From this structure it passes via the short ciliary nerves to the constrictor iridis. This reflex arc is activated by light. See diagram.

The convergence reflex is activated by proprioceptive impulses initiated by contraction of the two internal recti muscles and also consists of three parts, an afferent and efferent limb and a nucleus.

The afferent limb, starting from the internal rectus, travels in the ophthalmic division of V to reach the pons, and passes in the mesencephalic root of V to Perlia's nucleus, where it ends. The efferent limb leaves Perlia's nucleus and after a journey of unknown length in the motor oculi nerve leaves it at a point proximal to the ciliary ganglion. It reaches the ciliary muscle and the constrictor iridis without making contact with the ciliary ganglion. See diagram.

The constrictor iridis therefore has a double nerve supply, one which relays in the ciliary ganglion and one which has no connection with this structure. The former is a portion of the light reflex arc, the latter a part of the convergence reflex arc.

Discussion

It has been pointed out above that the pupillary reaction to light is absent or sluggish—we may therefore assume a lesion somewhere in the light reflex arc.

The afferent limb is unlikely to be affected, for during the whole of its course in the optic nerve and tract it is accompanied by the afferent fibres of the sympathetic dilator reflex. This reflex is normal, moreover there is no involvement of the optic nerve or tract.

The nucleus (Edinger-Westphall) can also be excluded for it is well nigh impossible to imagine a lesion in this crowded area which would destroy the nucleus and leave adjacent structures undamaged.

We are left therefore with the efferent limb. During its passage through the motor oculi nerve this limb is normal, for there is no damage to any external ocular muscle.

The only remaining structure is the ciliary ganglion and here we must postulate a lesion caused by some error in conduction between pre- and post-ganglionic parasympathetic fibres. A lesion in this structure readily explains the absence of, or sluggish response of the pupil to light. It also gives a satisfactory explanation for the affected pupil being the larger—for the normal dilator iridis being unopposed by the paralysed constrictor of necessity produces a large pupil. There is an equally satisfactory explanation for the slow pupillary reaction to convergence.

The constrictor iridis has a double nerve supply, one which relays in the ciliary ganglion and one which by-passes this structure. The former supply is paralysed, destroying half the nerve supply to the constrictor iridis which in consequence contracts less powerfully.

As far as the eye is concerned all the physical signs of the syndrome described as the "tonic pupil" can be produced by a destructive lesion of the ciliary ganglion and since it would appear impossible to produce them by a lesion in any other situation we may postulate a lesion due to defective conduction between pre- and post-ganglionic fibres in this structure with some confidence.

In a certain number of cases the physical signs are not confined to the eye, for in some the knee and ankle jerks are either absent or reduced.

When this physical sign is discovered in a patient whose pupil does not react to light, but will react to convergence, it may well be that tabes is suspected.

There should be no difficulty, however, in distinguishing between the two conditions for a careful examination will reveal physical signs which clearly separate tabes from the tonic pupil. In the first place tabetic pupils are almost invariably bilateral, the tonic pupil nearly always unilateral.

In tabes when the knee and ankle jerks are absent Rombergism, loss of sensation and absence of the vibration sensation to the tuning fork, will be discovered. In the tonic pupil, although the knee jerks and ankle jerks may be absent, yet there is no Rombergism and both sensation and vibration to the tuning fork are normal.

After ascertaining these facts, should there still be any doubt examination of the cerebro-spinal fluid and blood will decide the presence or absence of the Wassermann reaction.

From the above it is clear that the lesion responsible for the loss of knee and ankle jerks in tabes and in the tonic pupil syndrome respectively must have a different anatomical position in the two conditions. In tabes, as is well known, the lesion affects the fibres which pass from the posterior root ganglion to the spinal cord—the stretch reflex being disturbed on its afferent side. In the tonic pupil, however, the lesion cannot be in this situation because vibration-sense and sensation are normal and Rombergism is absent.

Further it is unlikely that reflex is disturbed on its efferent side for there is no wasting of muscles or tenderness on palpation—in short no peripheral neuritis.

We are forced, therefore, to postulate a lesion in the sacral and lumbar segments of the cord itself, in the intercalated fibres connecting the posterior root fibres with the anterior horn cells—a lesion due to some error of conduction in the synapses there, analogous to that postulated in the ciliary ganglion for the loss of the light reflex. The pathology is obscure—its solution is a problem for the neuro-physiologist.

When we consider the salient physical signs it is clear that as far as the eye is concerned the condition is a partial iridoplegia. Since the name tonic pupil gives no descriptive clue to the anatomical position of the lesion, the term "ciliary ganglion iridoplegia" is suggested as being a more correct name.

Summary

1. The physical signs of the syndrome are given.
2. The anatomy of the ocular reflexes concerned is described with diagrams.
3. A lesion capable of producing the physical signs in the eye is postulated by deduction.
4. Physical signs which clearly differentiate the tonic pupil syndrome from tabes are pointed out.
5. The anatomical situation of the lesion responsible for the loss of knee and ankle jerks in the tonic pupil syndrome is postulated.
6. A descriptive name is suggested.

THE SIGNIFICANCE OF A LESION OF THE OPTIC NERVE

BY

G. JOLY DIXON

LONDON

THOUGH the optic nerve can be visually inspected at the beginning of its course, and its functions measured accurately both quantitatively and qualitatively, it is surprising how often the diagnosis of lesions in this structure remains doubtful. True, such lesions are often only part of a pathological process occurring elsewhere in the body, and the symptoms that have led to the discovery of the lesion in the optic nerve are really related to some much more generalised process, and, further, two entirely different processes may, for a time at least, produce the same syndrome in the optic nerve.

For example, an appearance at first indistinguishable from the papilloedema that so often accompanies cerebral tumour was seen in the following two cases of hypertension :—

Case 1.—A man aged 48 years attended the Royal Westminster Ophthalmic Hospital for the first time on February 13, 1939, under the care of Mr. Hine and Dr. Hickling, because a few days