

Progression of hepatitis non-A, non-B to chronic active hepatitis

A histological follow-up of two cases

STEN IWARSON, JOHAN LINDBERG, AND PER LUNDIN¹

From the Department of Infectious Diseases, University of Göteborg, East Hospital, S-416 85 Göteborg, and the ¹First Department of Pathology, University of Göteborg, Sahlgren's Hospital, S-413 45 Göteborg, Sweden

SUMMARY Two patients with histologically verified acute hepatitis but without any serological evidence of hepatitis A or hepatitis B infection are described. In both cases the acute attack of hepatitis type 'non-A, non-B' progressed histologically and clinically to chronic active hepatitis within a two-year period. One of the patients died from liver insufficiency a year later, while the other is still alive after eight years of follow-up. The two cases illustrate that a progression of acute hepatitis 'non-A, non-B' to chronic liver disease may occur just as has been reported for hepatitis B infection.

By using sensitive radioimmunoassays to identify hepatitis A and hepatitis B virus infections another variant of acute hepatitis has been discovered in which no immunological markers of hepatitis A or B can be detected (Feinstone *et al.*, 1975). The agent(s) responsible for this type of hepatitis, called 'non-A, non-B', have not yet been identified, and the diagnosis is essentially one of exclusion. The disease may be defined as a type of acute hepatitis, clinically and histologically indistinguishable from hepatitis A and B but lacking serological markers for the two latter types.

Progression of acute hepatitis B to chronic liver disease is well documented whereas no such progression has been documented for hepatitis A infection. We describe two patients in whom acute hepatitis type non-A, non-B progressed to chronic liver disease.

Case reports

CASE 1

A 55-year-old woman had a cholecystectomy in June 1970 and received five units of blood. Seven weeks later she became ill with nausea, fatigue, and jaundice. Liver function tests indicated acute liver cell failure with raised serum levels of bilirubin about two times the upper limit of normal and aminotransferases (ALAT, ASAT) about 10 times

the upper limit of normal. Hepatitis B surface antigen (HBsAg) and its antibody (anti-HBs) were not demonstrable in serum (with the gel diffusion method used at that time). Paper electrophoresis showed a normal serum protein pattern. Liver histology was consistent with viral hepatitis showing acute liver cell damage and cellular infiltration (Fig. 1). Liver function tests became normal within three months without any specific treatment.

Two years later the patient returned because of nausea and fatigue. Liver function tests showed slightly raised levels of aminotransferases only. A new liver biopsy revealed histological signs of chronic active hepatitis (Figs 2 and 3). HBsAg and anti-HBs were still not demonstrable in serum. Paper electrophoresis now showed raised levels of IgG (18 g/l) but otherwise a normal pattern. Auto-antibodies were not demonstrable in the serum.

Because of the histological signs of progression prednisolone treatment was started in a daily dosage of 15 mg, which was reduced to a maintenance dose of 5-10 mg after eight weeks. This treatment was continued for about three years but was stopped in 1975 when liver function tests had returned to normal. The patient was, however, still not able to return to work as a shop-assistant, and a third liver biopsy taken shortly after this revealed persisting signs of chronic active hepatitis.

In 1977 analyses of freeze-stored serum specimens from 1972 and 1975 for HBsAg and anti-HBs were performed by sensitive radioimmunoassay (Ausria II and Ausab, respectively; Abbott Laboratories)

Received for publication 25 September 1978

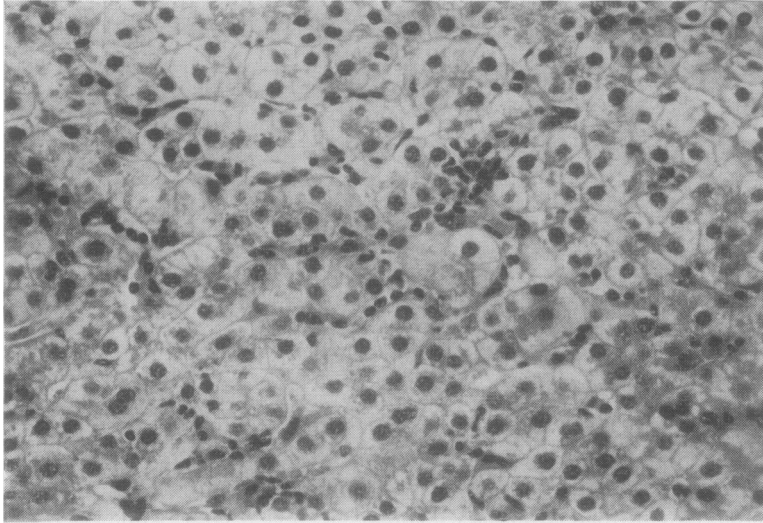


Fig. 1 Case 1. First attack of acute hepatitis type. Moderate signs of hepatocellular damage with hydropic degeneration and Kupffer cell hyperplasia. ($\times 300$)

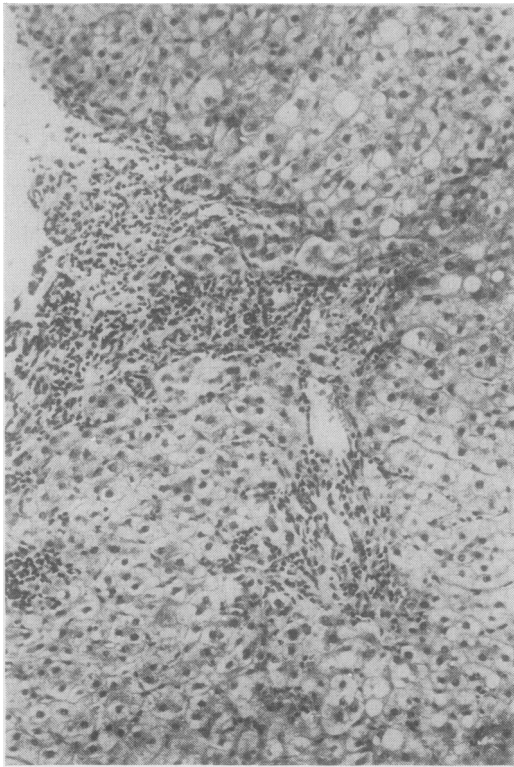


Fig. 2 Case 1. Biopsy two years after first attack. Signs of chronic disease with portal and periportal inflammatory mononuclear reaction and tendency to septal formation. ($\times 160$)

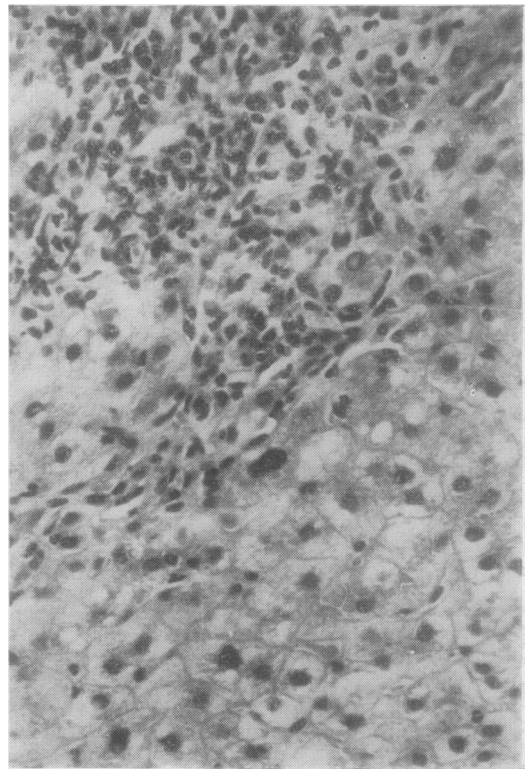


Fig. 3 Case 1. Same reaction as in Fig 2. Periportal inflammation and slight hydropic degeneration of hepatocytes. ($\times 300$)

and found to be negative. Also analyses for antibodies to the hepatitis B core antigen (anti-HBc) by immunoelectro-osmophoresis (Hansson and Johnsson, 1971) and hepatitis Be antigen (HBeAg) and its antibody by immunodiffusion (Magnius *et al.*, 1975) were found to be negative. Analyses for antibodies against hepatitis A virus (anti-HAV) by radioimmunoassay (Frosner *et al.*, 1977) also showed negative results. The liver function tests in 1977 were still normal. The only abnormality in agar gel electrophoresis was a raised level of IgG (19 g/l).

CASE 2

A 65-year-old man with a history of arthralgia and hypertension was admitted to our clinic in 1973 because of jaundice. Liver function tests showed normal levels of serum bilirubin but raised aminotransferases about 10 times the upper limit of normal. Liver histology was consistent with acute viral hepatitis (Figs 4 and 5) but tests for HBsAg were negative and neither anti-HBs nor anti-HBc developed during the course of illness or on follow-up.

A liver biopsy one year later revealed progression to chronic active hepatitis with signs of cirrhosis (Fig. 6). Serological tests for hepatitis B (HBsAg and anti-HBs) were still negative. The serum protein pattern was quite normal at the onset of symptoms in 1973 (albumin 43 g/l and IgG 14 g/l) but progressed to an extremely abnormal pattern (albumin 22 g/l and IgG 38 g/l) during the follow-up period of about two years.

Autoantibodies were not demonstrable in serum at the onset of illness but developed during follow-up, and after about two years high levels of smooth muscle antibodies (1/100) and of antinuclear antibodies (1/100) were observed. In 1977 freeze-stored serum specimens from 1973 and 1975 were tested for HBsAg, anti-HBs, antiHBc, HBeAg, and anti-HAV. All serum specimens were negative for these hepatitis A and hepatitis B markers.

Prednisolone treatment was given continuously (in a daily dose of 10-15 mg) from 1974 onwards.

The patient died from liver failure about three years after the first symptoms had appeared.

Histology of liver biopsy specimens

Both cases initially presented histological features of an acute reaction of hepatitis type (de Groote *et al.*, 1968) (Figs 1 and 4). The changes were more pronounced in case 2 (Figs 4 and 5) with disarray of the architecture, pronounced hydropic degeneration, ballooning, and single cell hyaline necrosis. There was also a slight increase in the number of Kupffer

cells with accumulation of pigments. The portal areas showed an infiltration of mononuclear inflammatory cells. Signs of intrahepatic cholestasis were also seen in case 2 (Figs 4 and 5). In both cases a slight macrovesicular steatosis was observed.

In the two follow-up liver biopsy specimens, one (Fig. 6) and two years (Figs 2 and 3), respectively, after the initial attack of jaundice, a significant portal and periportal reaction with accumulation of mononuclear cells and a slight fibrosis with tendency to septal proliferation was observed in both cases. The hepatocytes in case 1 showed diffuse damage with slight hydropic degeneration (Figs 2 and 3). In case 2 (Fig. 6), more pronounced hepatocellular damage with fairly marked hydropic degeneration and some ballooning was seen. In both cases there was erosion of the limiting plates and loss of individual cells in the periportal parenchyma (piecemeal necrosis).

Thus at the onset of symptoms a histological picture consistent with acute viral hepatitis and, in addition, slight steatosis was seen. At follow-up one and two years later chronic inflammatory changes resembling chronic active hepatitis had developed. In the second case progressive hepatocellular damage was apparent, and the patient died from liver insufficiency within three years of the onset of symptoms.

Discussion

Hepatitis type non-A, non-B may, like hepatitis B infection, progress to chronic liver disease in certain cases. Hoofnagle and his associates (1977) observed development of chronic hepatitis in two of six subjects experimentally infected with hepatitis type non-A, non-B. In a study on post-transfusion hepatitis, Knodell *et al.* (1977) found 10 cases of chronic liver disease among 44 patients with non-A, non-B hepatitis.

The two patients in the present report are examples of a histologically confirmed progression from acute hepatitis, serologically classified as type non-A, non-B, to chronic active hepatitis. They also had clinical and immunological abnormalities consistent with a progression to chronic liver disease.

It may be argued that the histological changes seen at the onset of illness, even if hepatitis-like, may have been caused by exogenous factors such as drugs or alcohol, especially since both patients had a slight steatosis. However, both patients denied the use of known hepatotoxic drugs. In both cases, a moderate weekly intake of alcohol may explain the slight steatosis found.

The true incidence of chronic liver disease after hepatitis type non-A, non-B is not known. The

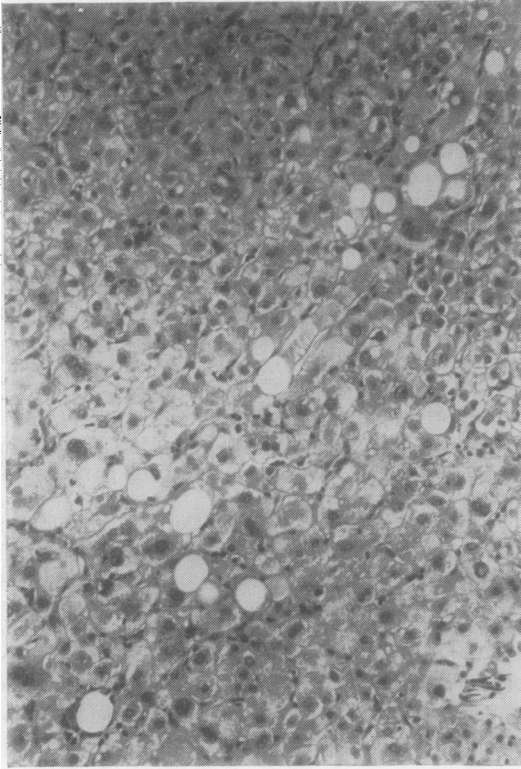


Fig. 4 *Case 2. First attack with prominent hepatocellular damage, hydropic degeneration and ballooning of hepatocytes, and a few large fat vacuoles. ($\times 160$)*

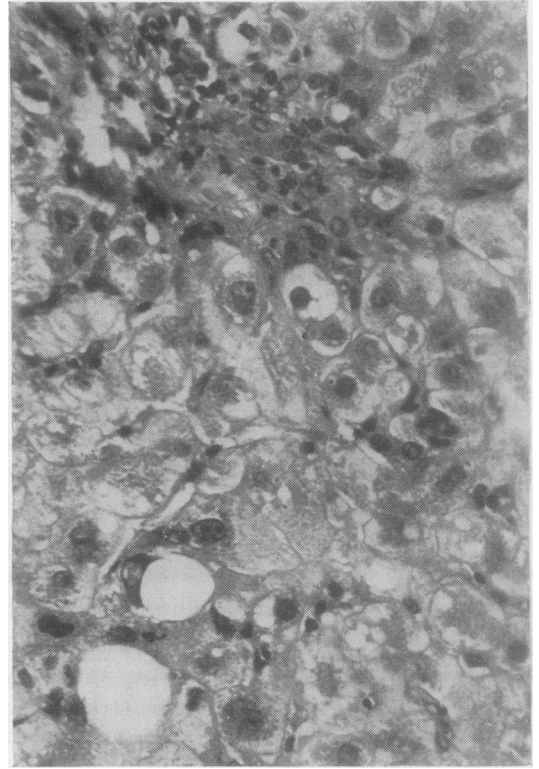


Fig. 5 *Same section as in Fig. 4.*

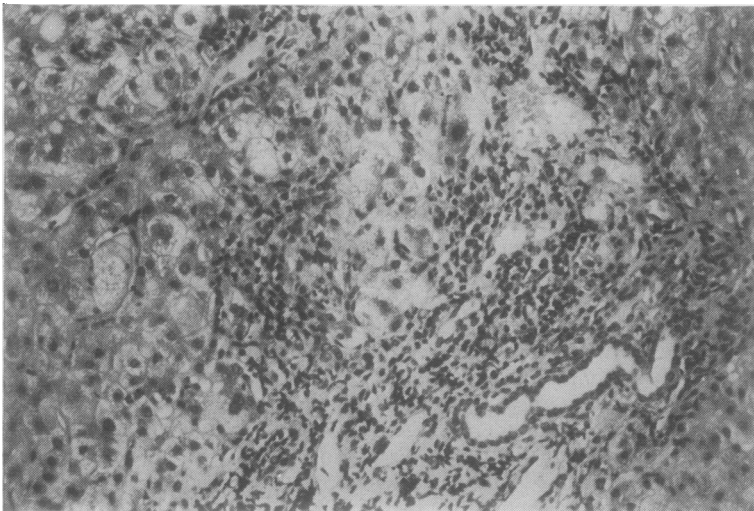


Fig. 6 *Case 2. Chronic hepatitis one year after the acute attack. Portal and periportal mononuclear cell infiltration with erosion of the limiting plate and piecemeal necrosis. ($\times 160$)*

incidence found by Hoofnagle *et al.* (1977) and Knodell *et al.* (1977) was 33% and 25%, respectively.

However, it seems unlikely that as many as one-third to one-fourth of non-A, non-B hepatitis cases progress to chronic liver disease, since among 56 cases of acute non-A, non-B hepatitis followed up in Gothenburg, Sweden (Norkrans *et al.*, 1979) only four patients (7%) had abnormal liver function tests for more than one year. In that material only seven patients (14%) had received transfusions of blood or blood products, and it is possible that non-A, non-B hepatitis not associated with blood transfusions bears a better prognosis.

The two cases presented here were found when 44 patients with chronic active hepatitis (CAH) were investigated for the presence of hepatitis A and B markers in serum (Lindberg *et al.*, 1978). Nine of these patients showed histological progression from acute viral hepatitis to CAH. Three of the patients had hepatitis B markers in serum, four had hepatitis A markers, while two patients (those of the present report) were lacking both A- and B-markers in the serum; no increased frequency of anti-HAV antibodies was found in CAH patients compared to age-matched healthy controls, and an aetiological relationship between hepatitis A virus and CAH therefore seems unlikely. Hence, the presence of anti-HAV in patients with acute viral hepatitis developing CAH does not exclude the fact that the disease may in fact be induced by a non-A, non-B infection. Thus, in two to six of the 44 patients (5-14%), CAH may be regarded as possibly having been induced by hepatitis non-A, non-B.

Hepatitis virus non-A, non-B, although still not demonstrable, must be taken into account in the search for aetiological factors in chronic hepatitis and cryptogenic cirrhosis. The true incidence of cases attributable to this agent, however, remains to be determined.

References

- De Groote, J., Desmet, V. J., Gedigk, P., Korb, G., Popper, H., Poulsen, H., Scheuer, P. J., Schmid, M., Thaler, H., Uehlinger, E., and Wepler, W. (1968). A classification of chronic hepatitis. *Lancet*, **2**, 626-628.
- Feinstone, S. M., Kapikian, A. Z., Purcell, R. H., Alter, H. J., and Holland, P. V. (1975). Transfusion-associated hepatitis not due to viral hepatitis type A or B. *New England Journal of Medicine*, **292**, 767-770.
- Frösner, G. G., Overby, L. R., Flehmig, B., Gerth, H. J., Haas, H., Decker, R. H., Lind, C. M., Zuckerman, A. J., and Frösner, H. R. (1977). Seroepidemiological investigation of patients and family contacts in an epidemic of hepatitis A. *Journal of Medical Virology*, **1**, 163-173.
- Hansson, B. G., and Johnsson, T. (1971). Improved technique for detecting Australia antigen by immunoelectroosmophoresis. *Vox Sanguinis*, **21**, 531-539.
- Hoofnagle, J. H., Gerety, R. J., Tabor, E., Feinstone, S. M., Barker, L. F., and Purcell, R. H. (1977). Transmission of non-A, non-B hepatitis. *Annals of Internal Medicine*, **87**, 14-20.
- Knodell, R. G., Conrad, M. E., and Ishak, K. G. (1977). Development of chronic liver disease after acute non-A non-B post transfusion hepatitis. *Gastroenterology*, **72**, 902-909.
- Lindberg, J., Frösner, G. G., Hansson, B. G., Hermodsson, S., and Iwarson, S. (1978). Serologic markers of hepatitis A and B in chronic active hepatitis. *Scandinavian Journal of Gastroenterology*, **13**, 525-527.
- Magnius, L. O., Lindholm, A., Lundin, P., and Iwarson, S. (1975). A new antigen-antibody system. Clinical significance in long term carriers of hepatitis B surface antigen. *Journal of the American Medical Association*, **231**, 356-359.
- Norkrans, G., Frösner, G. G., Hermodsson, S., and Iwarson, S. (1979). Clinical, epidemiological and prognostical aspects of hepatitis non-A, non-B—a comparison with hepatitis A and B. *Scandinavian Journal of Infectious Diseases*, (In press).
- Request for reprints to: Professor Sten Iwarson, Department of Infectious Diseases, Faculty of Medicine, University of Göteborg, Ostra Sjukhuset, S-416 85 Göteborg, Sweden