

Campylobacter colitis

C. P. WILLOUGHBY, J. PIRIS, AND S. C. TRUELOVE

From the Nuffield Department of Clinical Medicine and the Department of Morbid Anatomy, Radcliffe Infirmary, Oxford, UK

SUMMARY A patient is described in whom a campylobacter enteritis closely resembled ulcerative colitis on clinical, sigmoidoscopic, and histological grounds. Selective stool culture techniques may be necessary to differentiate campylobacter colitis from ulcerative colitis proper.

Campylobacter jejuni is an important cause of infectious diarrhoea in man (Skirrow, 1977). We have recently seen a patient who had clinical, sigmoidoscopic, and histological features which initially suggested a diagnosis of ulcerative colitis, but in whom stool culture revealed the presence of heat-tolerant campylobacteria. Her illness resolved rapidly with appropriate antibiotic treatment and has not recurred during one year of follow-up.

Case report

A 26-year-old woman was admitted to hospital with a 48-hour history of colicky lower abdominal pain relieved by defaecation. The discomfort was associated with about 20 watery stools per day, which contained mucus and blood. There were no other relevant symptoms. She was afebrile, and the only abnormal physical sign was mild, diffuse abdominal tenderness, which was most marked in the left iliac fossa.

Sigmoidoscopy showed moderate inflammation of the mucosa without contact bleeding or ulceration. The appearances closely resembled those of mild ulcerative colitis, and a rectal biopsy specimen was taken. A full blood count, sedimentation rate, and plasma biochemistry were normal.

No pathogens were isolated on routine stool culture, but specimens were also inoculated on a campylobacter-selective medium (Columbia agar (Oxoid) containing 7% lysed horse blood, vancomycin 10 µg/ml, polymyxin B 2.5 IU/ml, and trimethoprim 5 µg/ml) and incubated microaerophilically at 40°C. Examination of the plates after 18 hours and 42 hours revealed the presence of typical flat, non-haemolytic mucoid colonies; Gram-staining showed vibrio forms. The organisms were

oxidase- and catalase-positive, showed a characteristic 'darting' mobility under phase-contrast microscopy, and were sensitive to erythromycin. No serological investigations were performed.

The patient improved a little on symptomatic treatment but was still having frequent loose motions five days later. Sigmoidoscopically, the rectal mucosa still looked inflamed, and a further biopsy specimen was taken. In view of the stool culture report, she was given erythromycin, 500 mg twice daily for three weeks. Her illness rapidly resolved and, at the end of the antibiotic course, she was asymptomatic, stool cultures were negative, and the sigmoidoscopic appearances had returned to normal. She has remained well, on no treatment, over the succeeding year.

PATHOLOGY

The appearances of the initial biopsy specimen are shown in Figure 1. The surface epithelium is flattened and depleted of goblet cells. The crypt walls are infiltrated by polymorphonuclear leucocytes, and numerous crypt abscesses are present. There is a mixed inflammatory infiltrate in the lamina propria comprising polymorphs, lymphocytes, and plasma cells. The changes were reported to be consistent with moderately active ulcerative colitis. Gram-staining and silver nitrate impregnation failed to demonstrate vibrios in the tissue sections.

The rectal biopsy taken five days later shows reappearance of a tall columnar surface epithelium with mild goblet cell depletion. There are no crypt abscesses. The acute inflammatory component of the lamina propria infiltrate has virtually disappeared, but there is still an excess of chronic inflammatory cells, particularly plasma cells (Fig. 2).

The final biopsy specimen, taken a month after the start of the illness, is shown in Figure 3. The rectal mucosa has returned entirely to normal.

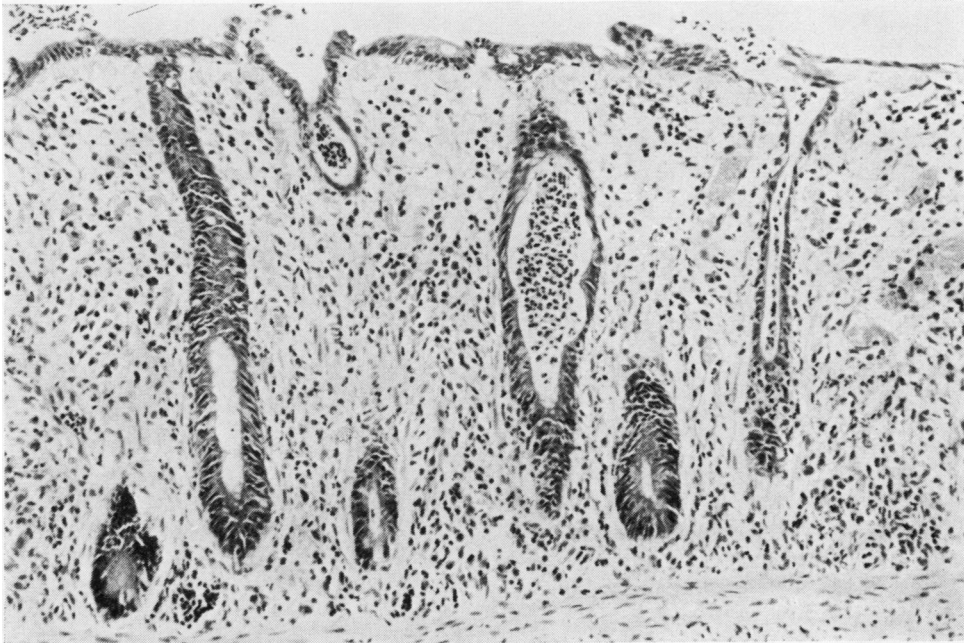


Fig. 1 *Histological appearances of the first biopsy specimen.*

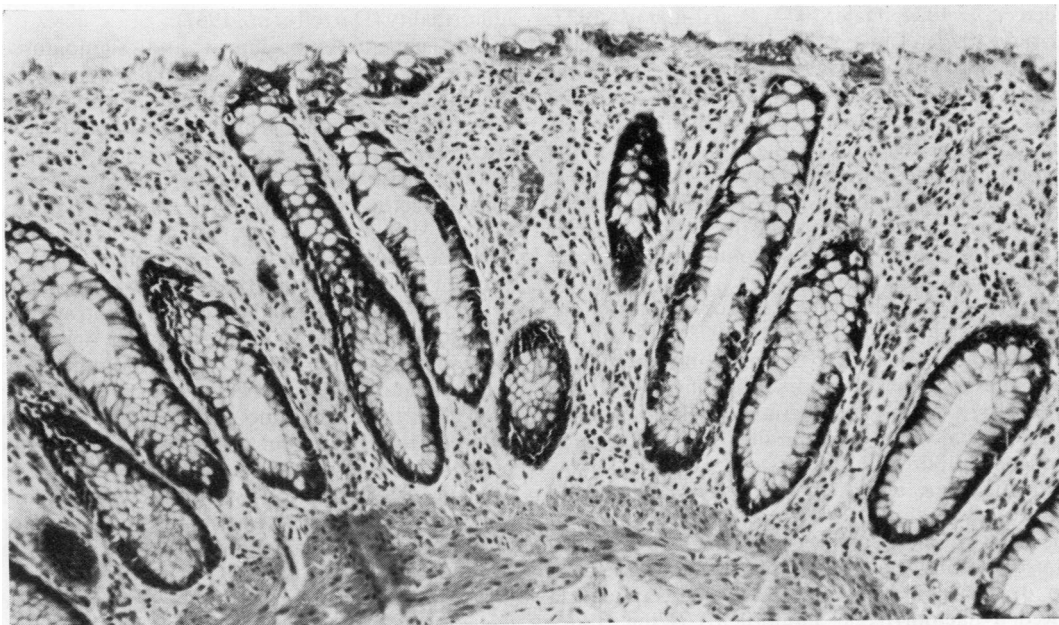

Fig. 2 *Histological appearances of the second biopsy specimen.*

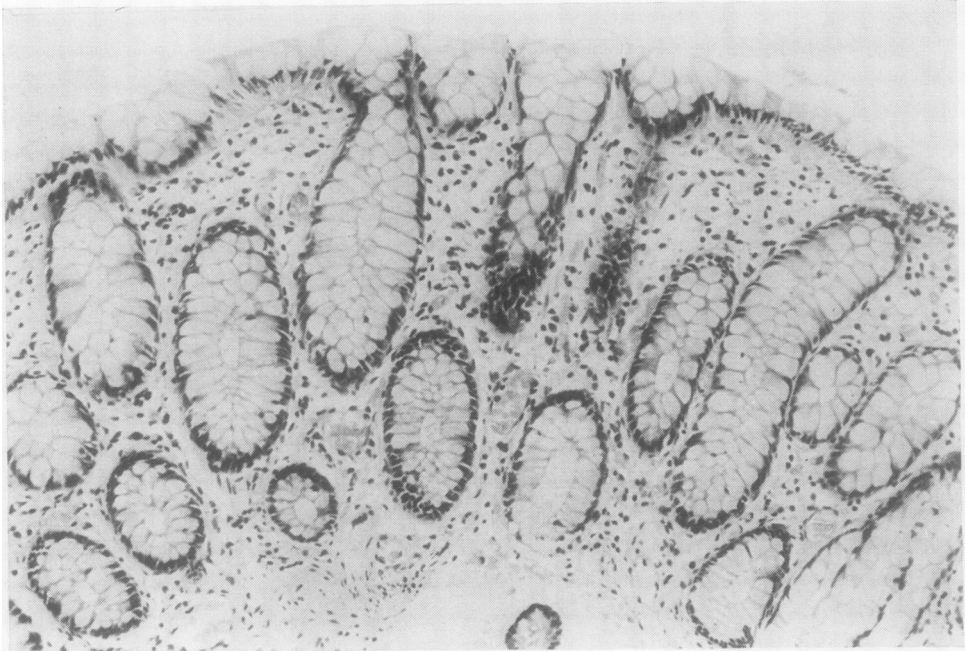


Fig. 3 *Histological appearances of the final biopsy specimen.*

Discussion

Campylobacteria account for 4.2 to 13.9% of all cases of infectious diarrhoea in the United Kingdom (Bruce *et al.*, 1977; Dale, 1977; Pearson *et al.*, 1977; Skirrow, 1977; Tanner and Bullin, 1977; Telfer Brunton and Heggie, 1977). During an attack the patient's stools frequently contain blood, pus, and mucus. Abdominal pain, fever, and vomiting are other common features of the illness. Sources of infection include poultry (Bruce *et al.*, 1977; Skirrow, 1977), dogs and cats (Wheeler and Borchers, 1961; Blaser *et al.*, 1978; Hastings, 1978), cattle (King, 1957), and possibly contaminated water supplies (Pearson *et al.*, 1977).

The jejunum and ileum are the usual sites of the gastrointestinal lesion (Lancet, 1978). A similar vibronic enteritis in calves involving the upper small intestine has been described by Jones and Little (1931). Campylobacteria have been isolated from intestinal secretions aspirated from the jejunum of infected children (Lauwers *et al.*, 1978). Skirrow (1977) mentions a patient who was subjected to laparotomy because of a suspected bowel perforation; most of the ileum was found to be inflamed and oedematous. Two fatal cases of the disease have been described in which postmortem examination showed a haemorrhagic jejuno-ileitis (King, 1962; Evans and Dadswell, 1967); in neither of these

patients were colonic lesions found. In another severe case, there was no sigmoidoscopic evidence of colitis during the acute illness, and a later post-mortem report does not mention any colonic abnormality (Darrell *et al.*, 1967).

Our patient had clinical and sigmoidoscopic features which suggested an attack of ulcerative colitis. The appearances of the first biopsy specimen were consistent with this diagnosis, although Morson (1972) has pointed out that similar histological changes may be found in other inflammatory diseases affecting the colon. The histology of rectal biopsy specimens from patients with infective diarrhoea has recently been reported by Dickinson *et al.* (1979). The majority of such biopsies showed a mild to moderate inflammatory infiltrate in the lamina propria. In addition, in about one-third of cases there were epithelial cell abnormalities, focal erosions, and small numbers of poorly formed crypt abscesses; the changes do not seem to have been as severe as those in the first biopsy specimen from our patient. Histological features strongly suggestive of chronic inflammatory bowel disease were found in only two of their patients, one of whom had salmonellosis; repeat biopsies a month after the acute illness showed normal mucosa.

Vibrios morphologically similar to *Campylobacter jejuni* have been reported to produce a form of swine dysentery (Doyle, 1944). In this condition, the

pathological changes were confined to the colon, and vibrios could be demonstrated deep in the crypts and invading the superficial parts of the mucosa. Attempts to stain vibrios in the rectal biopsy specimens from our patient were unsuccessful.

Occasional patients are encountered who apparently have a single attack of ulcerative colitis and who then remain symptom-free over prolonged periods of follow-up without any treatment (Edwards and Truelove, 1963). The present report suggests that some of these cases may be examples of campylobacter colitis and that, unless suitable selective stool culture techniques are employed routinely, they may be difficult to differentiate from cases of ulcerative colitis proper.

We thank Mr Norman Thomas for technical assistance.

References

- Blaser, M., Cravens, J., Powers, B. W., and Wang, W. L. (1978). Campylobacter enteritis associated with canine infection. *Lancet*, **2**, 979-981.
- Bruce, D., Zochowski, W., and Ferguson, I. R. (1977). Campylobacter enteritis (Letter). *British Medical Journal*, **2**, 1219.
- Dale, B. (1977). Campylobacter enteritis (Letter). *British Medical Journal*, **2**, 318.
- Darrell, J. H., Farrell, B. C., and Mulligan, R. A. (1967). Case of human vibriosis. *British Medical Journal*, **2**, 287-289.
- Dickinson, R. J., Gilmour, H. M., and McClelland, D. B. L. (1979). Rectal biopsy in patients presenting to an infectious disease unit with diarrhoeal disease. *Gut*, **20**, 141-148.
- Doyle, L. P. (1944). A vibrio associated with swine dysentery. *American Journal of Veterinary Research*, **5**, 3-5.
- Edwards, F. C., and Truelove, S. C. (1963). The course and prognosis of ulcerative colitis. Part II. Long-term prognosis. *Gut*, **4**, 309-315.
- Evans, R. G., and Dadswell, J. V. (1967). Human vibriosis (Letter). *British Medical Journal*, **3**, 240.
- Hastings, D. H. (1978). Campylobacter enteritis in pets. *Lancet*, **2**, 1249-1250.
- Jones, F. S., and Little, R. B. (1931). Vibrionic enteritis in calves. *Journal of Experimental Medicine*, **53**, 845-851.
- King, E. O. (1957). Human infections with *Vibrio fetus* and a closely related vibrio. *Journal of Infectious Diseases*, **101**, 119-128.
- King, E. O. (1962). The laboratory recognition of *Vibrio fetus* and a closely related vibrio isolated from cases of human vibriosis. *Annals of the New York Academy of Sciences*, **98**, 700-711.
- Lauwers, S., De Boeck, M., and Butzler, J. P. (1978). Campylobacter enteritis in Brussels (Letter). *Lancet*, **1**, 604-605.
- Lancet (1978). Campylobacter enteritis (Leading article). *Lancet*, **2**, 135-136.
- Morson, B. C. (1972). In *Gastrointestinal Pathology*, edited by B. C. Morson, and I. M. P. Dawson, pp. 465-470. Blackwell, Oxford.
- Pearson, A. D., Suckling, W. G., Ricciardi, I. D., Knill, M., and Ware, E. (1977). Campylobacter-associated diarrhoea in Southampton. *British Medical Journal*, **2**, 955-956.
- Skirrow, M. B. (1977). Campylobacter enteritis: a 'new' disease. *British Medical Journal*, **2**, 9-11.
- Tanner, E. I., and Bullin, C. H. (1977). Campylobacter enteritis (Letter). *British Medical Journal*, **2**, 579.
- Telfer Brunton, W. A., and Heggie, D. (1977). Campylobacter-associated diarrhoea in Edinburgh. (Letter). *British Medical Journal*, **2**, 956.
- Wheeler, W. E., and Borchers, J. (1961). Vibrionic enteritis in infants. *American Journal of Diseases of Children*, **101**, 60-66.

Addendum

Since this case report was submitted for publication, Lambert and his colleagues (1979) have described sigmoidoscopic abnormalities in 8 out of 11 patients with proven campylobacter infections. Seven rectal biopsy specimens were abnormal, and three of their patients had histological changes suggesting ulcerative colitis. They too suggest that campylobacter colitis should be included in the differential diagnosis of a first attack of ulcerative colitis.

Lambert, M. E., Schofield P. F., Ironside, A. G., and Mandal, B. K. (1979). Campylobacter colitis. *British Medical Journal*, **1**, 857-859.

Requests for reprints to: Dr S. C. Truelove, Nuffield Department of Clinical Medicine, John Radcliffe Hospital, Headington, Oxford OX3 9DU, UK.