

# Technique, Safety, and Accuracy Assessment of Percutaneous Pedicle Screw Placement Utilizing Computer-Assisted Navigation in Lateral Decubitus Single-Position Surgery

ANNA-KATHARINA CALEK, MD<sup>1,2,3</sup>; BETTINA HOCHREITER, MD<sup>1,2,3</sup>; AND AARON J. BUCKLAND, MBBS, FRACS<sup>1,3</sup>

<sup>1</sup>Melbourne Orthopedic Group, Melbourne, Victoria, Australia; <sup>2</sup>Department of Orthopedics, Balgrist University Hospital, University of Zurich, Zurich, Switzerland, Europe; <sup>3</sup>Spine and Scoliosis Research Associates Australia, Melbourne, Victoria, Australia

## ABSTRACT

**Background:** Percutaneous pedicle screw (PPS) placement has become a pivotal technique in spinal surgery, increasing surgical efficiency and limiting the invasiveness of surgical procedures. The aim of this study was to analyze the accuracy of computer-assisted PPS placement with a standardized technique in the lateral decubitus position.

**Methods:** A retrospective review of prospectively collected data was performed on 44 consecutive patients treated between 2021 and 2023 with lateral decubitus single-position surgery. PPS placement was assessed by computed tomography scans, and breaches were graded based on the magnitude and direction of the breach. Facet joint violations were assessed. Variables collected included patient demographics, indication, intraoperative complications, operative time, fluoroscopy time, estimated blood loss, and length of stay.

**Results:** Forty-four patients, with 220 PPSs were identified. About 79.5% of all patients underwent anterior lumbar interbody fusion only, 13.6% underwent lateral lumbar interbody fusion only, and 6.8% received a combination of both anterior lumbar interbody fusion and lateral lumbar interbody fusion. Eleven screw breaches (5%) were identified: 10 were Grade II breaches (<2 mm), and 1 was a Grade IV breach (>4 mm). All breaches were lateral. About 63.6% involved down-side screws indicating a trend toward the laterality of breaches for down-side pedicles. When analyzing breaches by level, 1.2% of screws at L5, 13% at L4, and 11.1% at L3 demonstrated Grade II breaches. No facet joint violations were noted.

**Conclusion:** PPS placement utilizing computer-assisted navigation in lateral decubitus single-position surgery is both safe and accurate. An overall breach rate of 5% was found; considering a safe zone of 2 mm, only 1 screw (0.5%) demonstrated a relevant breach.

**Clinical Relevance:** PPS placement is both safe and accurate. Breaches are rare, and when breaches do occur, they are lateral.

**Level of Evidence:** 3.

New technology

Keywords: single position surgery, percutaneous pedicle screw, pedicle screw, lateral decubitus, fusion

## INTRODUCTION

Percutaneous pedicle screw (PPS) placement has become a pivotal technique in spinal surgery, especially for addressing thoracolumbar pathologies. The precision of PPS insertion is crucial because inaccuracies can lead to severe neurological complications and adversely affect patient outcomes.<sup>1,2</sup> Screw malpositioning not only is the most frequent complication but also entails significant biomechanical disadvantages.<sup>3</sup> While initially placed using fluoroscopy,<sup>4-7</sup> recent advances in enabling technologies have led to the integration of 3-dimensional (3D) computer-assisted

navigation systems, aiming to improve accuracy and safety.

With the aim of increasing surgical efficiency and limiting the invasiveness of surgical procedures, lateral decubitus single-position surgery (L-SPS), which combines both anterior and posterior column support through anterior lumbar interbody fusion (ALIF) and/or lateral lumbar interbody fusion (LLIF) with PPS placement performed in the lateral decubitus position, has gained popularity and evidence base.<sup>8</sup> L-SPS eliminates the need for time-consuming operating room setup changes and patient repositioning when moving from supine or lateral to prone positioning.<sup>9</sup> In addition,

when PPS is placed through small incisions, the posterior tension band is not compromised, and paraspinous muscles are not detached, which results in shorter hospital stays, less blood loss/postoperative pain, and accelerated recovery times.<sup>10</sup>

However, despite these advantages, reports on the accuracy of PPS placement in the L-SPS, particularly when evaluated using postoperative computed tomography (CT), are limited. In addition, the laterality of breaches is rarely reported, and facet joint violations have not been evaluated. Minimally invasive L-SPS is a relatively new technique, and more evidence from different sites is needed to support the use of navigation in L-SPS. Therefore, the aim of this study was to analyze the accuracy of computer-assisted PPS placement with a standardized technique in the lateral decubitus position.

## MATERIALS AND METHODS

A retrospective review of prospectively collected data was performed on patients undergoing 1- to 3-level L-SPS via LLIF, ALIF, or combined LLIF/ALIF with PPS placement between L1 and S1. Twenty-six patients (59.1%) underwent a single-level fusion, 15 patients underwent 2-level fusion (34.1%), and 3 patients (6.8%) underwent 3-level fusion. All surgeries were performed by the senior author. Patient data were reviewed from an institutional review board–approved prospective single-surgeon registry. Inclusion criteria included PPS placement in L-SPS in skeletally mature patients (radiographically closed growth plates, eg, femoral physes, triradiate cartilage, and Risser Stage V) undergoing fusion for degenerative pathologies, with the exception of 1 patient undergoing fusion for spondylosis. CT was performed at 1-year follow-up as per standard of care. Patients who presented before their 1-year follow-up were included if they had undergone intraoperative CT to assess instrumentation or required CT postoperatively for the purpose of assessing instrumentation if patient symptoms warranted. Seventeen patients (36.6%) had undergone CT prior to the 1-year follow-up. Of these 17 patients, 14 were scanned intraoperatively. Three patients complained of persistent leg pain postoperatively and underwent CT. Pedicle screw malposition could be excluded, and the pain was classified as radiculitis. This was treated with oral cortisone, and the symptoms resolved over time. Patients who had screws placed prone, open, or without navigation were excluded, as were patients treated for infection, revision, or tumor. The primary endpoint was the assessment of pedicle screw placement accuracy. Accuracy

was evaluated using the Ravi grading system based on a 2-mm increment scale.<sup>11</sup> The presence or absence of facet joint breaches by screws was also evaluated. Measurements were performed in a blinded fashion by an independent fellowship-trained orthopedic surgeon unaware of the clinical outcome.

Variables collected included patient demographics, indication for surgery, intraoperative complications, operative time, fluoroscopy time, estimated blood loss, and length of stay.

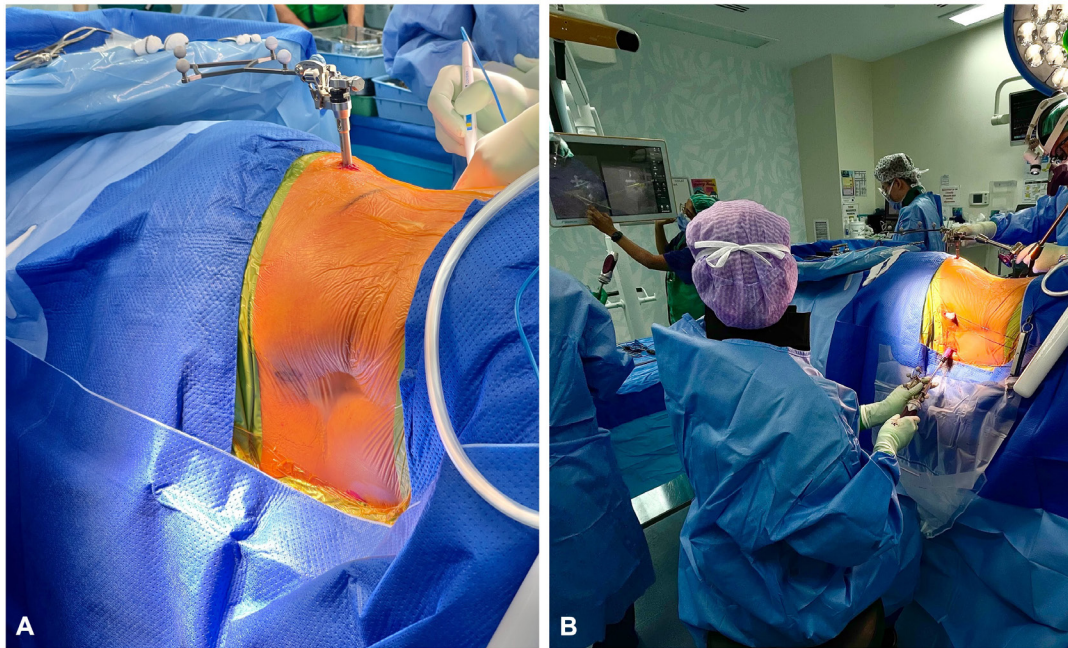
## Surgical Technique

### *Setup and Patient Positioning*

Patients were positioned in the lateral decubitus position on a radiolucent flat table and secured with silk tape with relevant pressure area care and axillary roll placement. The surgeon determined the side for positioning based on optimal factors related to patient pathology and side of symptoms, psoas anatomy, and vascular anatomy.<sup>9</sup> To avoid restricting the surgeon's ability to medialize the down-side screw, patients were positioned with their backs near the edge of the operating table. Electromyography leads were placed, and the patient was prepped and draped to allow simultaneous access to both the abdomen and posterior lumbar spine. PPSs were inserted utilizing computer-assisted navigation (Brainlab) registered with intraoperative 3D fluoroscopy. A patient reference array was attached to the iliac crest on the lateral margin to allow a line of site for instruments for anterior, lateral, and posterior procedures (Figure 1A). The tracking camera was placed at the foot of the operating table and oriented to allow line of sight of the instrument and patient arrays. Subsequently, a 3D fluoroscopic spin was performed, and data were transferred to the navigation system.

### *Navigated Wire Placement*

Bilateral para-midline “Wiltse” incisions were marked using the navigation pointer. Following the skin incisions, fascial incisions were made in line with the skin incisions bilaterally. We assume that manipulation of the patient may cause slight movement of the vertebrae relative to the patient array in the iliac crest due to intervertebral motion. The susceptibility to error, therefore, increases with increasing time and increasing distance from the navigation frame. For this reason, we started with the placement of nitinol wires at the vertebra furthest from the navigation frame (most cephalad vertebra to be instrumented) to minimize potential inaccuracies with the navigation and proceeded in a caudal



**Figure 1.** Intraoperative clinical photographs. (A) Lateral decubitus patient positioning with reference frame attached to the iliac crest. (B) Use of 3-dimensional computer-assisted navigation for placement of a percutaneous pedicle screw starting with the most proximal vertebra to be instrumented.

direction for all vertebral bodies to be instrumented (Figure 1B). Bilateral wires were placed in the cephalad vertebra prior to proceeding to the adjacent caudal vertebra. All wires were placed into the pedicles and vertebral bodies bilaterally prior to the use of a tap or screw insertion to allow for more accurate wire placement and ensure that if inaccuracies developed throughout the procedure, the accuracy would be maintained by “rail-roading” over the nitinol wires.

Jamshidi needles were positioned at a starting point located at the junction of the transverse process and lateral facet. The Jamshidi needle was placed via optimal trajectory through the pedicle to a depth of 30 mm. In certain cases, a navigated drill replaced the Jamshidi needle, especially in small pedicles (upper lumbar spine), sclerotic pedicles, or hypertrophic facet joints (Weishaupt grading  $\geq 2$ <sup>12</sup>) whereby skiving is more likely with a Jamshidi needle. Guidewires were inserted through the Jamshidi needles or navigated drill guide, which were then removed, leaving the wires in place. The wires were secured to the drapes on the cephalad side to prevent interference with the line of sight with the navigated instruments. Sequential dilators were placed over the guidewires, followed by tapping of the screw tracts and placement of cannulated screws over the wires, again starting with the most cephalad screws bilaterally and progressing caudally, similar to the sequence of wire placement. To prevent wire migration when passing instruments over the wires, the wires

were always secured with the other free hand. Screw placement was confirmed via fluoroscopy, and thresholds were checked via triggered electromyography stimulation to assess for pedicle wall breaches.

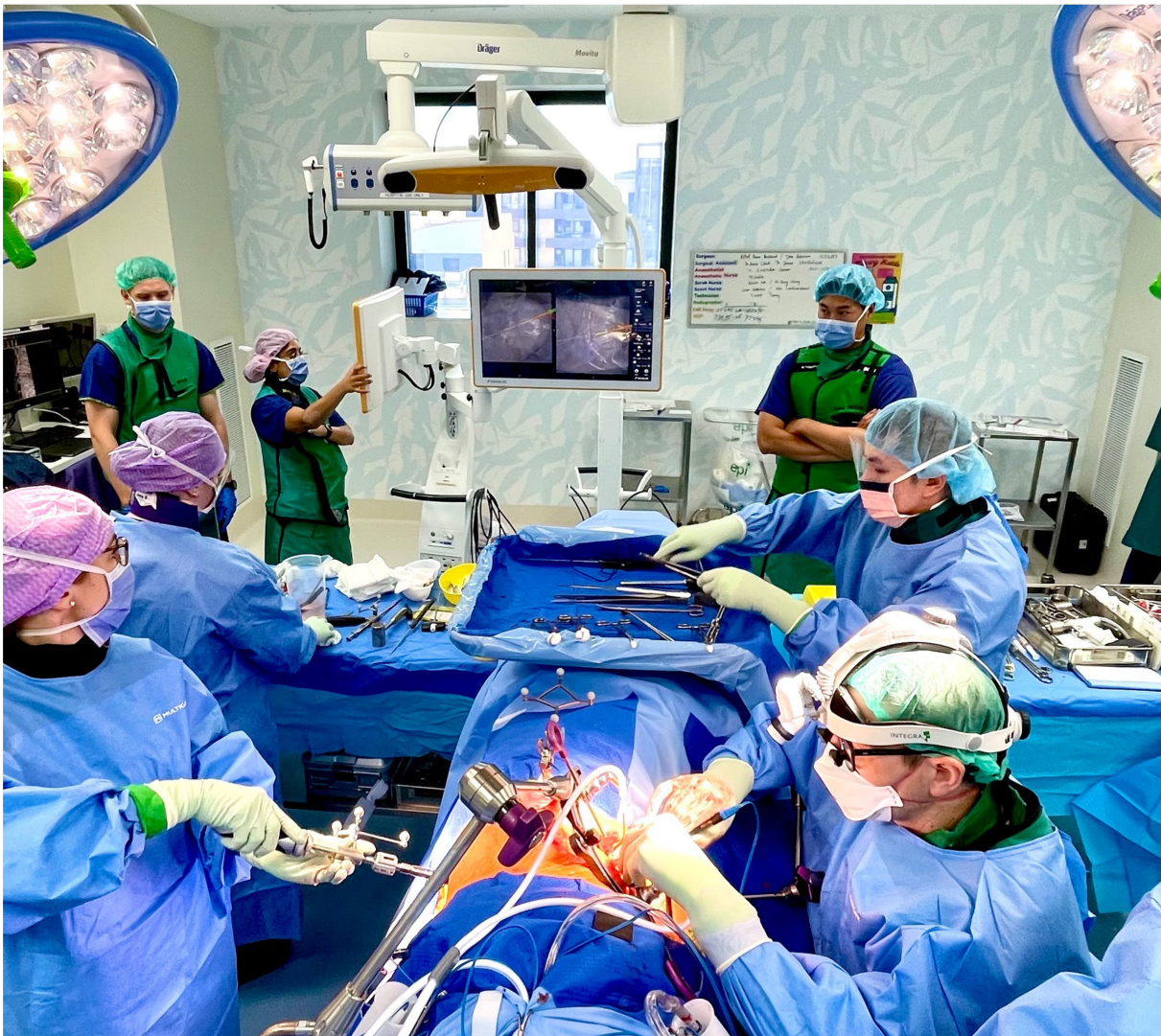### *Anterior Column Exposure*

If ALIF was being performed, an anterior retroperitoneal approach through a paramedian incision was performed by a vascular surgeon concurrently with PPS placement, aiming to minimize operative time (Figure 2). Conversely, if LLIFs were utilized, they were placed via a standard lateral retroperitoneal approach<sup>13</sup> following the placement of pedicle screws due to the requirement to drape in fluoroscopy. The screws were placed prior to any interbody work being performed to prevent unnecessary intervertebral motion or changes in alignment that would create inaccuracy in screw navigation. Following interbody cage placement, rods were percutaneously inserted on each side and secured to the screw heads with torque-limiting set screws.

### *Statistical Analysis*

Statistical analysis was performed in a descriptive fashion. Numeric variables were expressed as mean (SD) or median (range) according to data distribution, and discrete outcomes were expressed as absolute and relative (%) frequencies. Normality was assessed with the Shapiro-Wilk test. The alpha risk was set to 5% ( $\alpha$





**Figure 2.** Intraoperative clinical photograph demonstrating the operating room setup. The anterior exposure of the disc space is performed by the vascular surgeon on the right side. Simultaneously, the spine surgeon performs the percutaneous pedicle screw placement with 3-dimensional computer-assisted navigation, seen in the background. Each surgeon has their own scrub nurse.

= 0.05). Fisher’s exact test was used to compare breach rates between levels. Statistical analysis was performed with EasyMedStat (version 3.30; www.easymedstat.com) and GraphPad Prism (version 10.0.3).

## RESULTS

A total of 44 patients underwent L-SPS. The median age was 64.1 years, and there were 28 women and 16 men. Additional demographic details are provided in Table 1.

Degenerative spondylolisthesis was the primary diagnosis in 54.5% of cases. Table 2 lists the indications for fusion, operative time, estimated blood loss, and LOS. Among the patients, 79.5% underwent ALIF only, 13.6% underwent LLIF only, and 6.8% received

**Table 1.** Demographics of study participants (N = 44).

Characteristic	Value
Gender, n (%)	
Women	28 (63.6)
Men	16 (36.4)
Age, y, median (range)	64.1 (17.3–86.3)
Body mass index, mean (SD)	27.62 (5.74)
Smoking, n (%)	
Never	39 (88.6)
Former	2 (4.5)
Unknown	3 (6.8)
Diabetes, n (%)	
No	40 (90.9)
Yes	4 (9.1)
Osteoporosis, n (%)	
No	24 (54.5)
Yes	2 (4.5)
Unknown	18 (40.9)
Charlson Comorbidity Index, median (range)	2 (0–8)

**Table 2.** Treatment and procedural outcome measures ( $N = 44$ ).

Outcome Measure	Value
Indication for surgery, $n$ (%)	
Degenerative spondylolisthesis	24 (54.5)
Degenerative disc disease	12 (27.3)
Foraminal stenosis with radiculopathy	6 (13.6)
Facet arthropathy	1 (2.3)
Spondylolysis/pedicle fracture	1 (2.3)
Prior surgery, $n$ (%)	
No	36 (81.8)
Yes	8 (18.2)
Levels fused, $n$ (%)	
1	26 (59.1)
2	15 (34.1)
3	3 (6.8)
Median (range)	1 (1–3)
ALIF cage levels, $n$ (%)	
0	6 (13.6)
1	24 (54.5)
2	14 (31.8)
LLIF cage levels, $n$ (%)	
0	34 (77.3)
1	7 (15.9)
2	3 (6.8)
Cages, $n$ (%)	
ALIF only	35 (79.5)
LLIF only	6 (13.6)
Combination of ALIF and LLIF	3 (6.8)
Most commonly treated levels, $n$ (%)	
L5/S1	46.2%
L4/5	36.9%
L3/4	10.8%
L2/3	6.2%
Lateral position, $n$ (%)	
Left side up	36 (81.8)
Right side up	8 (18.2)
Neuromonitoring, $n$ (%)	
Yes	44 (100.0)
Operative time, min, median (range)	110 (53–293)
Fluoroscopy time, sec, median (range)	98.5 (12.8–283)
Estimated blood loss, mL, median (range)	100 (100–1900)
Length of stay, d	2 (1–14)

Abbreviations: ALIF, anterior lumbar interbody fusion; EMG, electromyography;

LLIF, lateral lumbar interbody fusion.

\*EMG and free-running EMG.

a combination of both ALIF and LLIF (Table 2). The most commonly treated level was L5/S1 (46.2%) followed by L4/5 (36.9%), L3/4 (10.8%), and L2/3 (6.2%; Table 2).

There were no intraoperative complications associated with pedicle screw insertion.

### Pedicle Screw Assessment

Eleven screw breaches were identified among 220 screws, accounting for 5%: 10 were Grade II breaches (<2 mm), and 1 was a Grade IV breach (>4 mm; Figure 3). These breaches were identified in 5 patients: 3 breaches were identified in 1 patient (3 of 6 pedicle screws) and 2 breaches were identified in another patient (2 of 4 pedicle screws). Taking into account a safe zone of 2 mm,<sup>14,15</sup> only 1 screw (0.5%) exhibited a breach exceeding this threshold. All breaches were lateral. Of

all breaches, 7/11 involved down-side screws indicating a trend toward the laterality of breaches for down-side pedicles (Table 3).

The Grade IV breach involved an up-side screw (1 of 4 up-side breaches). The Grade IV lateral breach involved an L2 pedicle and was due to a narrow “V-shaped” pedicle. The Grade IV breach was an intentional “in-out-in” technique given that the “perfect” pedicle trajectory would have resulted in facet joint violation (Figure 4: blue line).

When analyzing breaches by level, 1.2% of screws at L5 exhibited a Grade II breach, 13.0% at L4, and 11.1% at L3 demonstrated Grade II breaches (Figure 5).

A comparison of breach rates between levels showed significantly higher breach rates at L4 compared with L5 and S1 ( $P = 0.0043$  and  $P = 0.0073$ , respectively). No differences were found when comparing the other levels.

Hypertrophic facet joints were present in 6 of 10 screws with a Grade II breach, resulting in lateral screw deviation (Figure 6). No facet joint violations were noted.

## DISCUSSION

This study demonstrates that PPS placement utilizing computer-assisted navigation in the L-SPS is both safe and accurate; breaches are rare, and when breaches do occur, they are lateral. An overall breach rate of 5% was found; considering a safe zone of 2 mm, only 1 screw (0.5%) demonstrated a relevant breach.

L-SPS has proven to increase surgical efficiency with improved perioperative metrics and reduced complications.<sup>9</sup> Radiological outcomes, sagittal alignment parameters, and fusion rates of L-SPS have been extensively evaluated and compared with prone and “flip” techniques,<sup>8</sup> but limited data exist on the accuracy of PPS placement using computer-assisted navigation in L-SPS. Posterior instrumentation remains a relevant barrier to the adoption of this novel technique.

In evaluating the published literature, a notable heterogeneity is observed in terms of grading schemes interpretation (eg, Grade I is defined as no breach in one study<sup>16</sup> and as a breach in others),<sup>6,17</sup> imaging methods, and screw insertion techniques used to evaluate pedicle screw accuracy. Ouchida et al<sup>16</sup> reported a 1.8% misplacement rate for PPS in 228 screws undergoing L-SPS. In this study, only pedicle screws with a breach greater than 2 mm were considered malpositioned, which puts their results in a more favorable light. The present study demonstrated a 0.5% rate of breach by >2 mm, compared with 1.8% reported by Ouchida et al.<sup>16</sup>

## Frequency distribution

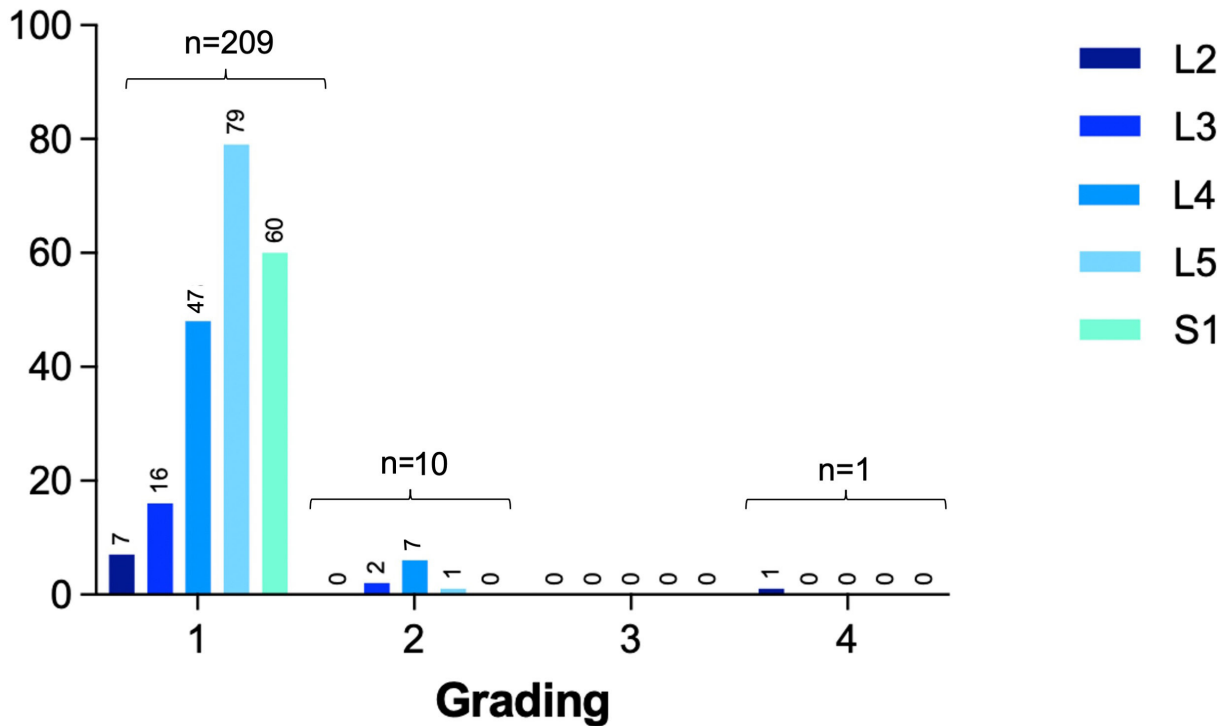


Figure 3. Frequency distribution of pedicle screws according to grading (Grades I-IV).

The overall reported pedicle screw breach rate, considering different screw insertion techniques and different imaging methods reported in the literature, ranges from 1.5% to 14.3%.<sup>4,6,18-23</sup> However, so far, only 3 other studies<sup>16,17,24</sup> have analyzed pedicle screw positions on CT images after computer-assisted PPS placement in L-SPS (Table 4). Okuda et al<sup>17</sup> analyzed two patient cohorts based on intraoperative positioning and reported pedicle wall breach rates of 4.6% in the lateral decubitus position and 4% in the prone position, which is comparable to the current study. In our study, hypertrophic facet joints were present in 6/10 screws with a Grade II breach, resulting in lateral screw deviation (Figure 5). In one case in the current series, a Grade II breach was intentionally chosen due to the small size of the pedicles. An in-out-in technique was used to obtain a satisfactory screw purchase. Although neural structures are situated within 2 mm of the pedicle,<sup>25</sup> clinically

relevant issues tend to arise with larger breaches and medial or caudal breaches. We did not identify any medial or caudal breaches in our study, whereas Okuda et al<sup>17</sup> reported 3 (14.3%) medial breaches. Focusing on the cases of significant breaches (Grades III and IV), Okuda et al<sup>17</sup> reported a rate of 2.2% compared with 0.5% in our study. Possible reasons, such as facet hypertrophy or pedicle dimensions for these breaches, were not evaluated in their study.

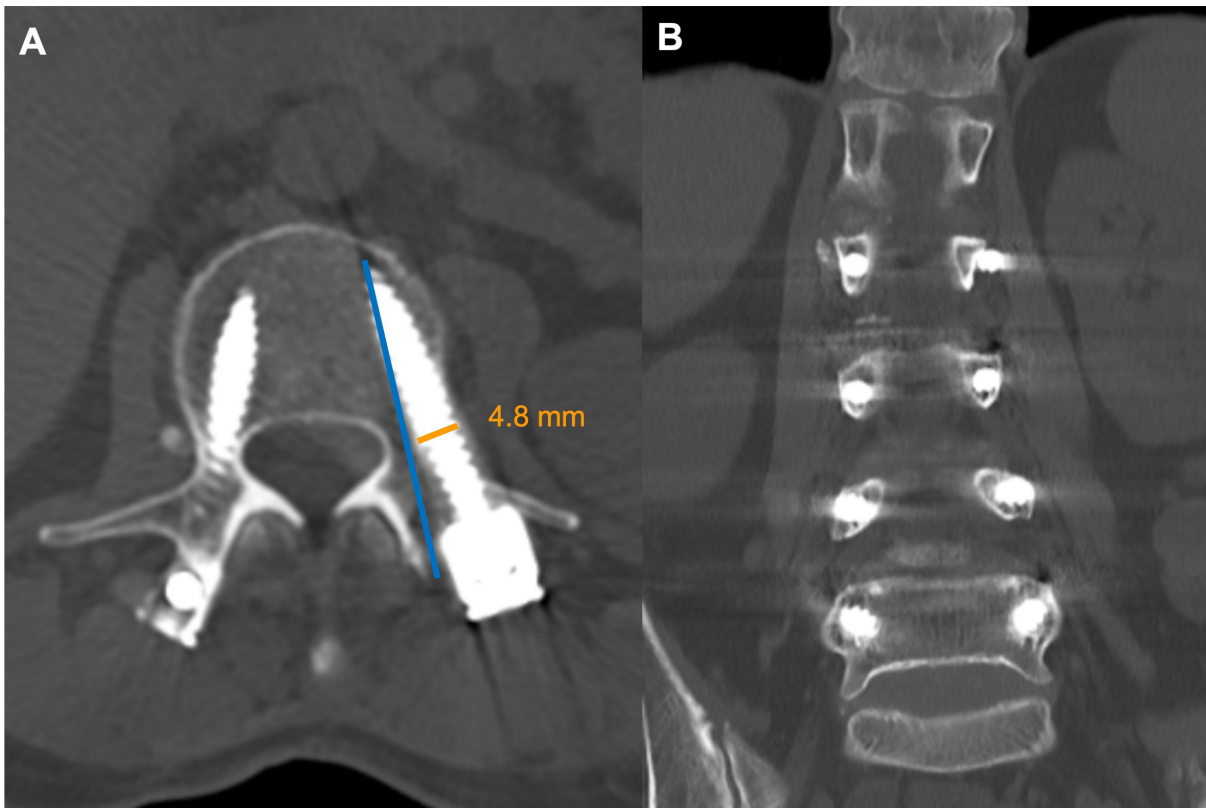
Hiyama et al<sup>24</sup> analyzed 728 pedicle screws and reported a breach rate of 1.9%, which is lower than in the present study. However, their rate of significant breaches was higher (1.2% vs 0.5%), and the breach laterality, which is of great interest, was not assessed.

The current study further examined the laterality of breaches in relation to the pedicle's position relative to the floor during instrumentation. A tendency for breaches to occur on the down-side pedicles was observed. This observation aligns with the findings of Okuda et al,<sup>17</sup> who similarly observed a trend toward lateralization of down-side screws, attributing it to the patient's orientation relative to the operating table. This problem can be considered one of the technical challenges with SPS and should be anticipated.

Table 3. Lateral breach location as a function of pedicle orientation during instrumentation.

Pedicle Orientation	n
Down-side screw	7
Up-side screw	4
<b>Total</b>	<b>11</b>

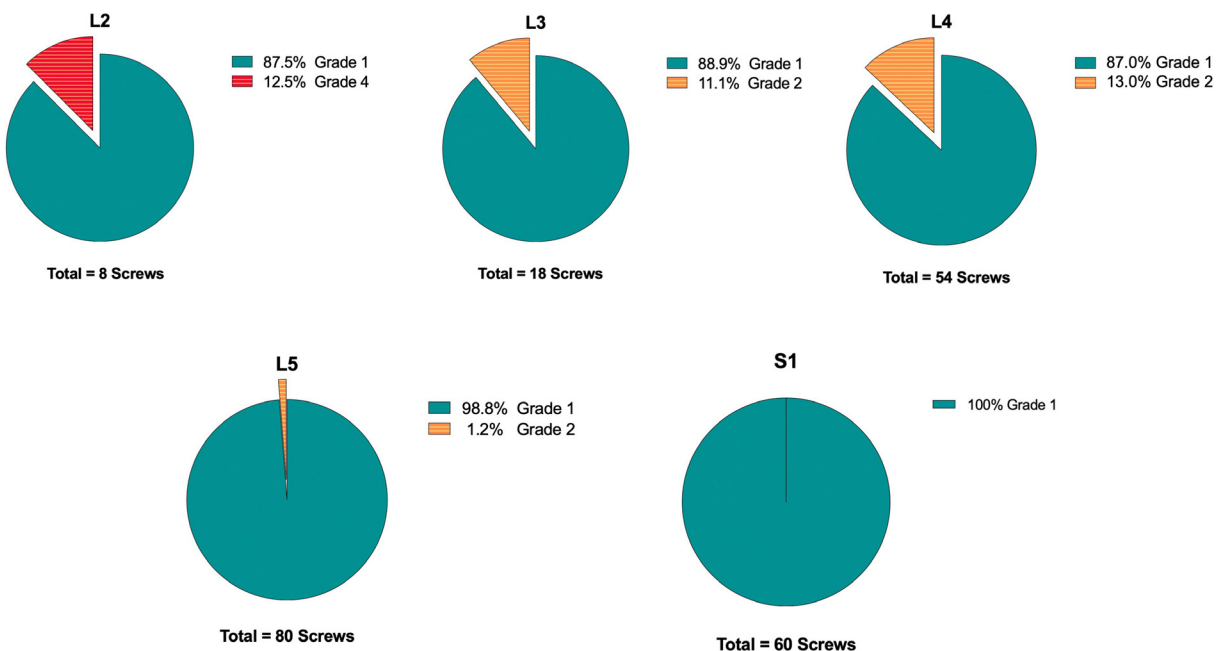




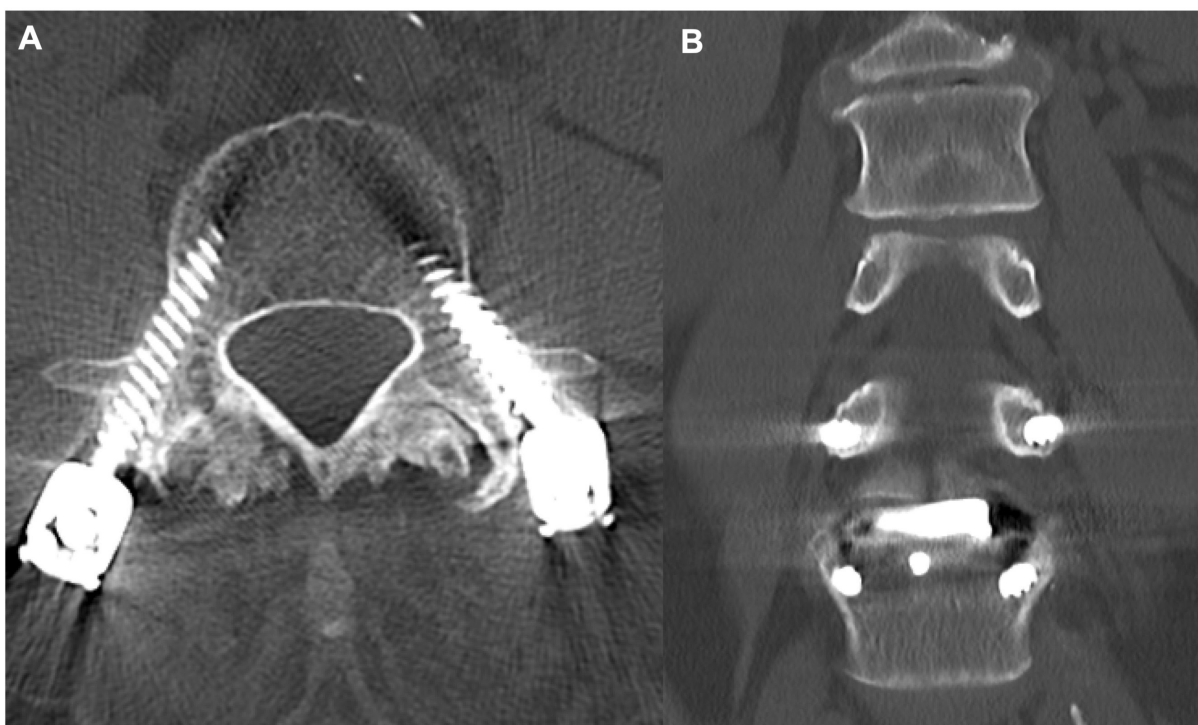
**Figure 4.** Illustrative case with axial (A) and coronal (B) postoperative computed tomography images demonstrating a Grade IV lateral breach (orange line: 4.8 mm) of the left L2 pedicle due to pedicle orientation. Had the “perfect” pedicle trajectory been followed (blue line), facet joint violation would have been inevitable. The coronal view (B) demonstrates a narrow “V-shaped” pedicle on the left side.

Patients should be positioned with the posterior aspect of the lumbar spine approximately 2 inches from the edge of the operating table to avoid interference with

instruments when performing the down-side PPS placement trajectory.<sup>8,26</sup> Interestingly, body habitus does not seem to play a role in screw deviation, as no significant



**Figure 5.** Pedicle screw breaches according to level.



**Figure 6.** Illustrative case with axial (A) and coronal (B) postoperative computed tomography images demonstrating a Grade II lateral breach of both L4 pedicles with hypertrophic facet joints at L3/4.

differences in body mass index were found between patients with and without a breach.

No clear pattern was discernible in the frequency of breaches per level in relation to the distance from the navigation frame: S1: 0%, L5: 1.2%, L4: 13%, L3: 11.1%, and L2: 12.5%. It is possible that the low number of screws in more cephalad levels and smaller pedicle diameters may contribute to these differences in accuracy rates; however, due to our current sample size, we only found statistically significant differences between L4 and S1 and between L4 and L5. Accuracy was excellent at S1 and L5, most likely due to the

limited motion between the navigation frame and the screw, which seems to improve accuracy. However, no screws required revision at any vertebral levels, nor were there any neurological complications or pedicle fractures observed.

In one case, a Grade IV breach was noted referring to an intentional in-out-in trajectory in an L2 pedicle with a narrow “V-shaped” pedicle (Figure 4). Had the “perfect” pedicle trajectory been followed, facet joint violation would have been inevitable, potentially accelerating adjacent segment degeneration and increasing the likelihood of revision. Furthermore, from a

**Table 4.** Published rates of percutaneous pedicle screw accuracy in lateral decubitus single-position anterior-posterior surgery assessed by computed tomography.

Author	Year	Insertion Technique	No. of Screws	Breach Rate	Breach Grading	Breach Laterality	Facet Joint Violations
Blizzard et al <sup>6</sup>	2018	Fluoroscopy	300	5.1%	Grade II: 84.6% Grade III: 15.4%	Medial: 69.2% Lateral: 23.1%	-
Ouchida et al <sup>16</sup>	2020	Computer-assisted navigation	228	1.8%	Grade II: unknown Grade III: 100%	-	-
Okuda et al <sup>17</sup>	2023	Computer-assisted navigation	453	4.6%	Grade II: 52.4% Grade III: 27.3% Grade IV: 18.2%	Medial: 14.3% Lateral: 85.7%	-
Hiyama et al <sup>24</sup>	2023	Computer-assisted navigation	728	1.9%	Grade II: 35.7% Grade III: 50% Grade IV: 14.3%	-	-
Present study	2024	Computer-assisted navigation	220	5%	Grade II: 90% Grade III: 0% Grade IV: 10%	Medial: 0% Lateral: 100%	None

<sup>a</sup>Grade II breaches were not reported in this study.

<sup>b</sup>Only screws in the lumbar spine were considered.



biomechanical point of view, we believe that the decision to use an in-out-in trajectory was better than instrumenting pedicles unilaterally in this construct. While this was graded as an inaccuracy, given the surgeon's intention to treat, the authors believe that this inaccuracy should not be considered a result of the navigation technology.

Overall, the accuracy rate of the PPS technique in L-SPS is consistent with the existing literature, but the precision of the technique described here appears to be higher. The authors believe that wire placement, and the sequence of doing so, is the reason for better precision due to reducing intersegmental motion and providing a safe "rail-road" for the tap and screw later in the procedure where inaccuracies may be magnified.

There are several potential limitations to this study resulting from its retrospective, single-cohort design and constrained duration of postoperative follow-up. The study assumes accuracy purely by the amount of pedicle breach; however, given anatomical constraints, surgeons may choose a trajectory with a small breach to account for hypertrophic facets, to avoid facet joint violation, or to optimize screw length. The only true way to truly assess accuracy would be to assess the final screw position compared with the planned screw orientation, which was beyond the scope of this study. Owing to the study's design focusing on a single cohort and a single-surgeon practice external validity is not necessarily implied. However, it does allow for a standardized technique to reference.

## CONCLUSION

PPS placement utilizing computer-assisted navigation in L-SPS is both safe and accurate. An overall breach rate of 5% was found; considering a safe zone of 2 mm, only 1 screw (0.5%) demonstrated a clinically relevant pedicle breach.

## REFERENCES

1. Verma R, Krishan S, Haendlmayer K, Mohsen A. Functional outcome of computer-assisted spinal pedicle screw placement: a systematic review and meta-analysis of 23 studies including 5,992 pedicle screws. *Eur Spine J*. 2010;19(3):370–375. doi:10.1007/s00586-009-1258-4
2. Ouchida J, Kanemura T, Satake K, et al. True accuracy of percutaneous pedicle screw placement in thoracic and lumbar spinal fixation with a CT-based navigation system: intraoperative and postoperative assessment of 763 percutaneous pedicle screws. *J Clin Neurosci*. 2020;79:S0967-5868(20)31349-7:1–6. doi:10.1016/j.jocn.2020.07.012
3. Shillingford JN, Laratta JL, Sarpong NO, et al. Instrumentation complication rates following spine surgery: a report from the scoliosis research society (SRS) morbidity and mortality database. *J Spine Surg*. 2019;5(1):110–115. doi:10.21037/jss.2018.12.09
4. Ikeuchi H, Ikuta K. Accuracy of pedicle screw insertion in the thoracic and lumbar spine: a comparative study between percutaneous screw insertion and conventional open technique. *Arch Orthop Trauma Surg*. 2016;136(9):1195–1202. doi:10.1007/s00402-016-2502-0
5. Wiesner L, Kothe R, Schulitz KP, Rütther W. Clinical evaluation and computed tomography scan analysis of screw tracts after percutaneous insertion of pedicle screws in the lumbar spine. *Spine*. 2000;25(5):615–621. doi:10.1097/00007632-200003010-00013
6. Blizzard DJ, Thomas JA. MIS single-position lateral and oblique lateral lumbar interbody fusion and bilateral pedicle screw fixation. *Spine (Phila Pa 1976)*. 2018;43(6):440–446. doi:10.1097/BRS.0000000000002330
7. Spitz SM, Sandhu FA, Voyadzis JM. Percutaneous "K-Wireless" pedicle screw fixation technique: an evaluation of the initial experience of 100 screws with assessment of accuracy, radiation exposure, and procedure time. *J Neurosurg Spine*. 2015;22(4):422–431. doi:10.3171/2014.11.SPINE14181
8. Buckland AJ, Braly BA, O'Malley NA, et al. Lateral decubitus single position anterior posterior surgery improves operative efficiency, improves perioperative outcomes, and maintains radiological outcomes comparable with traditional anterior posterior fusion at minimum 2-year follow-up. *Spine J*. 2023;23(5):S1529-9430(23)00004-9:685–694. doi:10.1016/j.spinee.2023.01.001
9. Buckland AJ, Ashayeri K, Leon C, et al. Single position circumferential fusion improves operative efficiency, reduces complications and length of stay compared with traditional circumferential fusion. *Spine J*. 2021;21(5):S1529-9430(20)31217-1:810–820. doi:10.1016/j.spinee.2020.11.002
10. Mobbs RJ, Loganathan A, Yeung V, Rao PJ. Indications for ALIF. *Orthop Surg*. 2013;5(3):153–163. doi:10.1111/os.12048
11. Ravi B, Zahrai A, Rampersaud R. Clinical accuracy of computer-assisted two-dimensional fluoroscopy for the percutaneous placement of lumbosacral pedicle screws. *Spine (Phila Pa 1976)*. 2011;36(1):84–91. doi:10.1097/BRS.0b013e3181cbfd09
12. Weishaupt D, Zanetti M, Boos N, Hodler J. MR imaging and CT in osteoarthritis of the lumbar facet joints. *Skeletal Radiol*. 1999;28(4):215–219. doi:10.1007/s002560050503
13. Ozgur BM, Aryan HE, Pimenta L, Taylor WR. Extreme lateral interbody fusion (XLIF): a novel surgical technique for anterior lumbar interbody fusion. *Spine J*. 2006;6(4):435–443. doi:10.1016/j.spinee.2005.08.012
14. Farshad M, Spirig JM, Winkler E, et al. Template guided cervical pedicle screw instrumentation. *N Am Spine Soc J*. 2022;10:100120. doi:10.1016/j.xnsj.2022.100120
15. Aoude AA, Fortin M, Figueiredo R, Jarzem P, Ouellet J, Weber MH. Methods to determine pedicle screw placement accuracy in spine surgery: a systematic review. *Eur Spine J*. 2015;24(5):990–1004. doi:10.1007/s00586-015-3853-x
16. Ouchida J, Kanemura T, Satake K, Nakashima H, Ishikawa Y, Imagama S. Simultaneous single-position lateral Interbody fusion and percutaneous pedicle screw fixation using O-arm-based navigation reduces the occupancy time of the operating room. *Eur Spine J*. 2020;29(6):1277–1286. doi:10.1007/s00586-020-06388-6
17. Okuda R, Ikuma H, Inoue T, et al. Accuracy of percutaneous pedicle screw placement with 3-dimensional fluoroscopy-based navigation: lateral decubitus position versus prone

position. *Medicine (Baltimore)*. 2023;102(14):e33451. doi:10.1097/MD.00000000000033451

18. Lieberman IH, Hardenbrook MA, Wang JC, Guyer RD. Assessment of pedicle screw placement accuracy, procedure time, and radiation exposure using a miniature robotic guidance system. *J Spinal Disord Tech*. 2012;25(5):241–248. doi:10.1097/BSD.0b013e318218a5ef

19. Gu G, Zhang H, He S, et al. Percutaneous pedicle screw placement in the lumbar spine: a comparison study between the novel guidance system and the conventional fluoroscopy method. *J Spinal Disord Tech*. 2013;28(9):E522–7. doi:10.1097/BSD.0b013e3182aab222

20. Smith ZA, Sugimoto K, Lawton CD, Fessler RG. Incidence of lumbar spine pedicle breach after percutaneous screw fixation: a radiographic evaluation of 601 screws in 151 patients. *J Spinal Disord Tech*. 2012;27(7):358–363. doi:10.1097/BSD.0b013e31826226cb

21. Chapman TM, Blizzard DJ, Brown CR. CT accuracy of percutaneous versus open pedicle screw techniques: a series of 1609 screws. *Eur Spine J*. 2016;25(6):1781–1786. doi:10.1007/s00586-015-4163-z

22. Nakahara M, Yasuhara T, Inoue T, et al. Accuracy of percutaneous pedicle screw insertion technique with conventional dual fluoroscopy units and a retrospective comparative study based on surgeon experience. *Global Spine J*. 2016;6(4):322–328. doi:10.1055/s-0035-1563405

23. Oh HS, Kim JS, Lee SH, Liu WC, Hong SW. Comparison between the accuracy of percutaneous and open pedicle screw fixations in lumbosacral fusion. *Spine J*. 2013;13(12):S1529–9430(13)00374-4:1751–1757. doi:10.1016/j.spinee.2013.03.042

24. Hiyama A, Sakai D, Katoh H, Nomura S, Watanabe M. Assessing procedural accuracy in lateral spine surgery: a retrospective analysis of percutaneous pedicle screw placement with intraoperative CT navigation. *J Clin Med*. 2023;12(21):6914. doi:10.3390/jcm12216914

25. Söyüncü Y, Yildirim FB, Sekban H, Ozdemir H, Akyildiz F, Sindel M. Anatomic evaluation and relationship between the lumbar

pedicle and adjacent neural structures: an anatomic study. *J Spinal Disord Tech*. 2005;18(3):243–246.

26. Ashayeri K, Leon C, Tigchelaar S, et al. Single position lateral decubitus anterior lumbar interbody fusion (ALIF) and posterior fusion reduces complications and improves perioperative outcomes compared with traditional anterior-posterior lumbar fusion. *Spine J*. 2022;22(3):419–428. doi:10.1016/j.spinee.2021.09.009

**Funding:** No funding was received for the present study.

**Disclosures:** Aaron James Buckland has received royalties or licenses from NuVasive, Evolution Spine, and Altus Spine and consulting fees from NuVasive. The remaining authors have nothing to disclose.

**Disclaimer:** The authors, their immediate families, and any research foundations with which they are affiliated have not received any financial payments or other benefits from any commercial entity related to the subject of this article.

**Corresponding Author:** Anna-Katharina Calek, Department of Orthopedics, Balgrist University Hospital, University of Zurich, Forchstrasse 340, CH-8008, Zurich, Switzerland; anna-katharina.calek@balgrist.ch

Published 03 July 2024

This manuscript is generously published free of charge by ISASS, the International Society for the Advancement of Spine Surgery. Copyright © 2024 ISASS. To see more or order reprints or permissions, see <http://ijssurgery.com>.