



OPEN ACCESS

Clinical science

Incidence and analysis of intraoperative complications in femtosecond laser-assisted cataract surgery: a large-scale cohort study to establish the learning curve

Xiaobo Zhang, Wen Xu , Xingchao Shentu , Peiqing Chen, Yibo Yu, Kairan Lai, Jiayong Li , Wei Wang, Xinyi Chen, Ke Yao

Eye Center, Second Affiliated Hospital, School of Medicine, Zhejiang University, Hangzhou, Zhejiang, China

Correspondence to

Professor Ke Yao, Eye Center, Second Affiliated Hospital, School of Medicine, Zhejiang University, Hangzhou, Zhejiang, China; xlren@zju.edu.cn

Received 9 May 2023

Accepted 10 March 2024

ABSTRACT

Aims To assess the safety of femtosecond laser-assisted cataract surgery (FLACS) based on surgical parameters and intraoperative complications analysis and to determine the length of the learning curve for FLACS.

Methods A prospective consecutive cohort study was conducted on Chinese patients who underwent either FLACS (3289 cases) or contemporaneous conventional phacoemulsification cataract surgery (2130 cases). The laser group was divided into four subgroups in chronological order. We recorded intraoperative complication incidences and compared with surgical parameters between groups. Subgroup analysis was conducted to explore the learning curve of FLACS.

Results The laser group had a 4.93% incidence of incomplete capsulotomies and a 1.22% incidence of anterior capsule tears. Subgroup analysis showed significant differences in 8 aspects between the first 250 cases (50 cases per surgeon) and the last 2539 cases, but only 2 aspects differed between the second 250 cases (50 cases per surgeon) and the last 2539 cases. There were no significant differences between the third 250 cases (50 cases per surgeon) and the last 2539 cases.

Conclusions The intraoperative complications of FLACS were reported, and the learning curve is associated with a significant reduction in the incidence of intraoperative complications. The length of the basic learning curve of FLACS is 100 cases, and the length of the advanced learning curve was 150 cases. This study demonstrated that FLACS is characterised by a relatively straightforward and secure operative technique.

WHAT IS ALREADY KNOWN ON THIS TOPIC

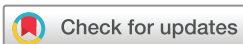⇒ The femtosecond laser-assisted cataract surgery (FLACS) can provide precise, clear corneal incisions, accurate anterior capsulotomy and efficient nuclear fragmentation, and it can better control corneal damage during cataract surgery. FLACS has greater accuracy and reproducibility in surgery.

WHAT THIS STUDY ADDS

⇒ This study evaluated the safety of FLACS by systematically and comprehensively analysing its intraoperative complications and determined its learning curve. The learning curve of FLACS is associated with a significant reduction in the incidence of intraoperative complications. The length of the basic learning curve of FLACS is about 100 cases, and the length of the advanced learning curve was 150 cases.

HOW THIS STUDY MIGHT AFFECT RESEARCH, PRACTICE OR POLICY

⇒ Our findings provide compelling evidence to support the safety of FLACS and offer training recommendations based on the identified learning curve. It is suggested that surgeons are required to undergo at least 100 FLACS procedures before they can be considered to be professionally competent in the technique, and surgeons-in-training should perform FLACS with extreme caution during the first 150 procedures.



© Author(s) (or their employer(s)) 2024. Re-use permitted under CC BY-NC. No commercial re-use. See rights and permissions. Published by BMJ.

To cite: Zhang X, Xu W, Shentu X, et al. *Br J Ophthalmol* Epub ahead of print: [please include Day Month Year]. doi:10.1136/bjo-2023-323897

INTRODUCTION

During the last several years, patients' expectations for cataract surgery have changed, with an increasing emphasis not only on precise refractive and visual outcomes but the speed of recovery as well. The application of femtosecond laser-assisted cataract surgery (FLACS) provides precise, clear corneal incisions (CCIs), accurate anterior capsulotomy, efficient nuclear fragmentation and reduction of corneal endothelial cell loss.¹⁻³ This technique has the potential to improve surgical outcomes and enable inexperienced surgeons to perform more predictable and reproducible cataract surgery.⁴⁻⁶

Several studies have shown the notable benefits of this technology, including the increased precision of anterior capsulotomies, less intraocular lens (IOL) tilt and decentration, and substantial reductions in ultrasound power and effective phacoemulsification time (EPT).⁷⁻¹⁰ FLACS alleviates endothelial cell damage and early postoperative corneal swelling, which leads to a faster visual recovery.¹¹⁻¹³ Several randomised controlled trials demonstrated that FLACS and conventional phacoemulsification cataract surgery (CPCS) could achieve the same outcomes in terms of vision, refraction and patient-reported health.^{5 14-18}

Despite FLACS's potential to reduce the incidence of post-operative complications,¹⁹ it is still not a complication-free procedure. The occurrence of complications associated with the learning curve has often been reported, such as suction break,²⁰ anterior capsule tear,^{4,21} intraoperative miosis, posterior capsule rupture²² and intraoperative vertical gas breakthrough when making CCIs.²³

Recently, there are several kinds of literature published on the study of FLACS's learning curve; however, the length of the learning curve is still uncertain.²⁴ Also, a prospective cohort study with a large sample that provides a comprehensive and systematic analysis of all possible intraoperative complications of FLACS has not been conducted yet, especially in Asian patients. In this study, we conducted a comprehensive and in-depth investigation of the incidence of all possible intraoperative complications using the LenSx laser system (Alcon LenSx, Inc, Aliso Viejo, California, USA) in a large cohort of Chinese patients undergoing FLACS. Through this comprehensive evaluation, we identified the learning curve of this technology. In addition, this study compared intraoperative surgical parameters, including the ultrasound power, absolute phacoemulsification time (APT) and EPT, between FLACS and CPCS in a large sample to evaluate the efficacy and safety of this femtosecond (FS) laser technique.

PATIENTS AND METHODS

We conducted this prospective cohort study at a single centre and evaluated 3289 consecutive cases that underwent FLACS (the laser group) and 2130 consecutive cases that underwent CPCS (the manual group) during the same period. The study was approved by the medical ethics committee of the Second Affiliated Hospital of the School of Medicine, Zhejiang University, Hangzhou, China. All procedures were performed at the Eye Center of the Second Affiliated Hospital, Medical College of Zhejiang University, Hangzhou, China, between February 2015 and August 2018.

All patients involved in the study underwent a complete preoperative ophthalmic evaluation, including slit-lamp examinations, uncorrected and corrected distance visual acuity, tonometry using a non-contact tonometer (NT-510, Nidek Co, Ltd), axial length and biometry with an A-scan ultrasound (Cinescan, Quantel Medical) or IOLMaster (Carl Zeiss Meditec Inc, Germany). The nuclear scleroses of the lenses were graded according to the Emery-Little classification.²⁵ Patients with advanced glaucoma, uveitis, poorly dilated pupils (<5.0 mm), trauma, small hyperopic eyes with steep corneas, severe conjunctivochalasis and nystagmus or who were uncooperative were excluded from the study.

All surgeries were performed by five senior cataract surgeons (KY, WX, XS, PC and YY) with experience from conducting more than 5000 cases in CPCS. According to the requirements of the institutional review board, all five surgeons must be confirmed to have performed 50 cases of FLACS each before participating in this study. To characterise the learning curve of FLACS, the 3289 cases in the laser group were divided into four subgroups in chronological order: subgroup A consisted of the first 50 cases by each surgeon (a total of 250 cases); subgroup B consisted of the next 50 cases by each surgeon (a total of 250 cases); subgroup C consisted of the third 50 cases by each surgeon (a total of 250 cases); subgroup D consisted of the subsequent 2539 cases. The incidences of intraoperative complications and surgical parameters were compared between subgroups. We also compared the intraoperative surgical parameters, including the

ultrasound power, APT and EPT, between the laser group and the manual group.

Surgical technique

All patients received four doses of levofloxacin on the day prior to the surgery. Pupillary dilation was achieved by administering one drop of 0.5% tropicamide every 15 min, three times before the surgical procedure. Furthermore, all patients were administered topical anaesthesia with 0.5% proparacaine hydrochloride before the surgery. In addition, patients in the laser group received non-steroidal anti-inflammatory drug instillation (pranoprofen; Senju Pharmaceutical Co, Ltd) four times a day prior to the surgery.

The LenSx laser system was used in the laser group. During the surgery, a 5.0 mm diameter capsulotomy was created by the LenSx, and the lens was fragmented into six pieces. Two CCIs including a 2.0 mm primary incision and a 1.0 mm secondary incision were created with the FS laser in appropriate cases. In the manual group, all the CCIs were created with the same keratomes, and the continuous curvilinear capsulorhexis was performed using capsular forceps. The phacoemulsification was performed using a Stellaris system (Bausch+Lomb) in both groups. After the removal of the lens cortex, all cases underwent IOL implantation. The characteristics of all the procedures between the two groups were consistent.

We recorded all intraoperative complications that occurred in the laser group for analysis. These complications included suction breaks, incomplete capsulotomies, radial anterior capsule tears, incomplete corneal incisions, incomplete lens prefragmentation, posterior capsule ruptures, posterior lens dislocations and subconjunctival haemorrhages, including the number of quadrants involved. The intraoperative surgical parameters, including the ultrasound power, APT and EPT, were recorded during the procedure. The standard postoperative regimen included one drop for each eye of topical dexamethasone-tobramycin four times a day for 2 weeks and pranoprofen four times a day for 1 month.

Statistical analysis

Categorical data were expressed as number and percentage, and the differences in the incidence of intraoperative complications between groups were assessed using χ^2 analysis, continuity-corrected χ^2 analysis or Fisher's exact test. The continuous variables were described as means \pm SD, and the independent sample t-test or the Mann-Whitney U test was used to compare the preoperative and intraoperative surgical parameters between groups. All statistical analyses were performed with the SPSS software (V.23.0, IBM SPSS, Inc, Chicago, Illinois). $P < 0.05$ was considered a statistically significant difference.

RESULTS

A total of 5419 eyes were involved in this prospective study, which comprised 3289 eyes that underwent FLACS (the laser group) and 2130 eyes that underwent CPCS (the manual group) during the same period. The preoperative demographic data are shown in [table 1](#). The mean nuclear sclerosis grade (according to Emery-Little classification) of the lenses was 2.36 ± 0.88 in the laser group and 2.36 ± 0.90 in the manual group.

The intraoperative complications of FLACS are shown in [table 2](#). In the laser group, a total of 2341 eyes underwent complete femtosecond laser-assisted procedures, including capsulotomy, lens prefragmentation and CCI creation. However, 948 eyes only underwent capsulotomy and lens prefragmentation

Table 1 Comparison of preoperative demographic data between groups

	Laser group (n=3289)					Manual group (n=2130)
	Subgroup A (n=250)	Subgroup B (n=250)	Subgroup C (n=250)	Subgroup D (n=2539)	Total laser group (n=3289)	
Mean age (y)±SD (range)	65.63±14.68 (18-93)	65.77±12.80 (33-99)	65.49±13.17 (14-89)	66.63±12.91 (8-95)	66.40±13.07 (8-99)	66.96±12.52 (15-98)
Female sex, no. (%)	150 (60.00)	136 (54.40)	126 (50.40)	1530 (60.30)	1942 (59.05)	1204 (56.53)
Mean nuclear sclerosis±SD	2.39±0.92	2.38±0.89	2.34±0.87	2.36±0.88	2.36±0.88	2.36±0.90
Grade 1, no. (%)	42 (16.80)	37 (14.80)	35 (14.00)	380 (14.97)	494 (15.02)	365 (17.14)
Grade 2, no. (%)	97 (38.80)	110 (44.00)	121 (48.40)	1131 (44.55)	1459 (44.36)	861 (40.42)
Grade 3, no. (%)	88 (35.20)	79 (31.60)	73 (29.20)	796 (31.35)	1036 (31.50)	712 (33.43)
Grades 4 and 5, no. (%)	23 (9.20)	24 (9.60)	21 (8.40)	232 (9.14)	300 (9.12)	192 (9.01)

due to severe cornea arcus senilis, peripheral cornea opacity or other conditions unsuitable for laser-assisted CCI creation. Of the total 3289 cases, FS laser procedures were completed in 3284 cases (99.85%). After undergoing FS laser procedures, a total of 193 eyes (5.87%) still required a surgeon to manually recreate the CCI using a keratome. Specifically, imperfections were more likely to occur in secondary incisions compared with primary incisions, with 152 cases (4.62%) versus 117 cases (3.56%), respectively ($p=0.029$, as determined by a χ^2 analysis).

Incomplete capsulotomies, including anterior tags and bridges, were observed in 4.93% of the cases, indicating that in these cases, surgeons had to perform manual supplementary capsulorhexis using capsular forceps. Out of the total 3289 cases, 40 cases (1.22%) were observed to have radial anterior capsule tears. Of these, 72.50% (29/40) cases were found to have resulted from incomplete capsulotomy.

Among the 3289 laser cases, the overall incidence of posterior capsule rupture was 0.82%. There was no significant difference in the incidence rate between subgroups. It is noteworthy that none of the posterior capsule ruptures were directly caused by the FS laser, including cases with capsular block syndrome.

Intraoperative miosis was observed in 232 cases (7.05%). Although these cases were treated with ophthalmic viscoelastic device or 1:10000–1:50000 epinephrine, 1.98% (65/3,289) of the cases still experienced interference with the subsequent surgical procedure due to miosis.

In the patients who underwent FLACS, subconjunctival haemorrhage was the most frequently observed complication, with an incidence of 25.93%. A Spearman correlation analysis revealed a statistically significant positive correlation between the presence and extent of subconjunctival haemorrhage (indicated by

the number of quadrants affected) and the age of the patients ($\rho=0.195$, $p<0.001$, Spearman correlation analysis; [figure 1](#)).

Notably, subgroup analysis was performed to investigate the learning curve of FLACS in the laser group, and significant differences were found between subgroup A and subgroup D in eight aspects ([table 2](#)). These aspects include the rate of incomplete capsulotomies, radial anterior capsule tears, incomplete corneal incisions, incomplete lens prefragmentation, intraoperative miosis, suction breaks, repeated docking and subconjunctival haemorrhages. However, only two aspects, including the rate of incomplete lens prefragmentation and subconjunctival haemorrhages, showed significant differences between subgroup B and subgroup D. Moreover, no significant differences were observed between subgroup C and subgroup D regarding the occurrence of all complications.

Additionally, [table 3](#) demonstrates that the intraoperative surgical efficiency parameters, including ultrasound power, APT and EPT, were significantly lower in the laser group than in the manual group ($p<0.001$ for all comparisons, independent t-test). Notably, subgroup analysis in the laser group revealed that surgical parameters in subgroup A were higher than those in subgroup D ($p<0.001$ for all comparisons, independent t-test). However, no significant differences in surgical parameters were observed between subgroups B and C compared with group D, respectively.

DISCUSSION

Overall, it can be posited that FLACS is characterised by a relatively straightforward and secure operative technique. Nevertheless, it is noteworthy that an inadequate level of proficiency

Table 2 Comparison of intraoperative complications between subgroups in the laser group

	Total laser group (n=3289)	Subgroup A (n=250)	Subgroup B (n=250)	Subgroup C (n=250)	Subgroup D (n=2539)
Suction break, no. (%)	5 (0.15)	2 (0.80)*	0 (0.00)	1 (0.40)	2 (0.08)
Incomplete capsulotomy, no. (%)	162 (4.93)	23 (9.20)***	15 (6.00)	16 (6.40)	108 (4.25)
Radial anterior capsule tear, no. (%)	40 (1.22)	9 (3.60)***	3 (1.20)	4 (1.60)	24 (0.95)
Incomplete corneal incisions, no. (%)	193 (5.87)	34 (13.60)***	17 (6.80)	18 (7.20)	124 (4.88)
Incomplete lens prefragmentation, no. (%)	60 (1.82)	14 (5.60)***	11 (4.40)***	1 (0.40)	34 (1.34)
Intraoperative miosis, no. (%)	232 (7.05)	45 (18.00)***	17 (6.80)	18 (7.20)	152 (5.99)
Intraoperative miosis interfered, no. (%)	65 (1.98)	16 (6.40)***	3 (1.20)	2 (0.80)	44 (1.73)
Posterior capsule rupture, no. (%)	27 (0.82)	2 (0.80)	3 (1.20)	2 (0.80)	20 (0.79)
Posterior lens dislocation, no. (%)	3 (0.09)	1 (0.40)	0 (0.00)	0 (0.00)	2 (0.08)
Repeated docking, no. (%)	297 (9.03)	32 (12.80)*	25 (10.00)	21 (8.40)	219 (8.63)
Number of docking attempt, mean±SD	1.15±0.51	1.22±0.69**	1.14±0.48	1.14±0.51	1.14±0.49
Subconjunctival haemorrhage, no. (%)	853 (25.93)	109 (43.60)***	84 (33.60)***	69 (27.60)	591 (23.28)

* $p<0.05$, ** $p<0.01$, *** $p<0.001$, versus subgroup D.

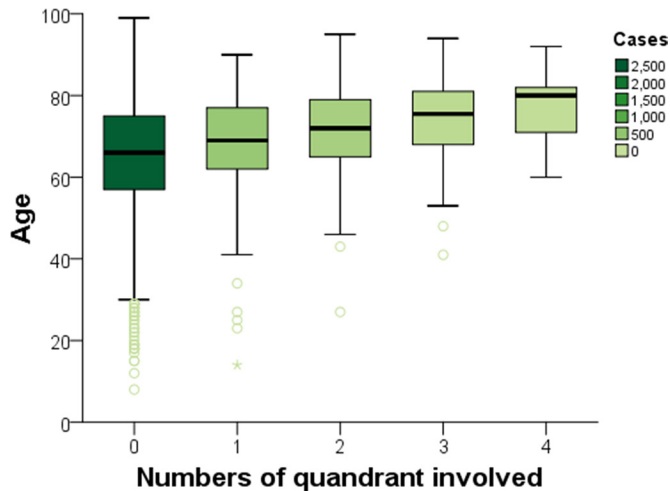


Figure 1 Relationship between age and subconjunctival haemorrhage. A Spearman correlation analysis shows a positive correlation between the presence of subconjunctival haemorrhage and the age of patients ($\rho=0.195$, $p<0.001$).

during the initial stages of the procedure may give rise to a range of concurrent complications.

The learning curve of this technology has been mentioned in several studies, and it is believed that the surgeon’s experience improves the safety of FLACS.^{4 24 26} However, the length of the learning curve of FLACS is still controversial. Therefore, we believe it is imperative to conduct a large-scale study encompassing a prolonged observation period of the FLACS learning process, in order to fully comprehend the nuances of this technique. To investigate the trajectory of the learning curve, we employed a categorisation strategy based on distinct phases of the surgeon’s experience with FLACS cases.

In the present study, it was shown that surgeons were not able to perfectly prevent the occurrence of most intraoperative complications immediately after the initial training period of 50 cases (before this study), but after another 50 cases of FLACS (subgroup A), the incidences of major intraoperative complications decreased significantly. Moreover, after the next 50 cases of FLACS (subgroup B), the surgery could achieve reproducible and almost perfect results. Based on our statistical evaluation, we argue that at least 100 FLACS procedures, including 50 cases in the initial training period before the study and the first 50 cases of this study, are required to achieve qualified relatively professional competence, and further, each surgeon can avoid almost all intraoperative complications of FLACS after completing the 150th case in their own career. It should be noted that the five surgeons involved in this study were the initial users of the LenSx laser system in our centre, and it is believed that resident

surgeons-in-training would sooner be proficient in this skill as long as under the guidance of surgeons who are very experienced in FLACS.

FS laser provides a more regularly shaped and consistent capsulotomy, and several studies reported that the capsulotomies created by FS laser had a stronger capsular margin than those treated with capsular forceps.^{27 28} However, incomplete capsulotomies and radial anterior capsule tears are still common and crucial complications in the laser procedure, the incidences of which are 4.93% and 1.22%, respectively, which are relatively low compared with the incidences of 1.6%–20% and 0.31%–5.3% identified in previous literature.^{4 21 26 29 30}

In our previous study, potential causes and characteristic features of capsulotomy-related complications during FLACS were summarised through the analysis of surgical videos.³¹ Therefore, for incomplete capsulotomy cases, it is recommended that surgeons follow the principle of ‘better outward than inward’ and tear carefully during the secondary capsulorhexis. Although this will make the capsulotomy a little larger than the preset one, it can avoid causing an anterior capsule tear. Furthermore, to our knowledge, the position of the patient’s head and eye and the proper patient interface docking also play important roles in capsulotomy creation; thus, effective communication with the patients before surgery is imperative.

Additionally, our recent study reported that lower ultrasound power and shorter EPT could reduce the rate of corneal endothelial injuries in patients with hard nuclear cataracts.³² In this large-scale comprehensive study comparing FLACS and CPCS, we have confirmed that the use of FS laser technology significantly reduces ultrasound power by 25.59%, APT by 23.46% and EPT by 41.92%. None of the 27 posterior capsule ruptures in the laser group were caused by the laser directly. Five cases were due to an extension of an anterior capsule tear, and the other 22 cases occurred during phacoemulsification or the IOL implantation procedure, including 1 case caused by sudden coughing during phacoemulsification, 1 case of posterior polar cataract and 2 cases of traumatic cataract. Therefore, repeatedly checking the integrity of the capsulotomy to avoid radial anterior capsule tear can never be overemphasised. For all-white cortical cataracts, although trypan blue staining was able to increase the visualisation of the anterior capsule, it could reduce the elasticity of the anterior capsule and make it more rigid, which might lead to further radial anterior capsule tear.²¹ However, FS laser can provide a safe and stable capsulotomy in these challenging cases. Therefore, although all-white cataracts prevent FS lasers from completely prefragmenting the lenses, using the laser is still recommended in these troublesome cases.

The FS laser was also able to create corneal incisions in various patterns, which may be more stable.⁴ In the early stage of the current study, the surgeons for most of the cases in the

Table 3 Comparison of intraoperative parameters between groups

	Laser group (n=3289)					Manual group (n=2130)
	Subgroup A (n=250)	Subgroup B (n=250)	Subgroup C (n=250)	Subgroup D (n=2539)	Total laser group (n=3289)	
Mean ultrasonic power (%) ± SD	15.55±6.84***	12.02±5.71	11.51±5.44	11.74±5.74	12.03±5.89###	16.17±6.13
Mean APT (s)±SD	42.88±26.82***	35.81±23.03	32.99±20.96	34.24±21.88	34.92±22.43###	45.62±26.62
Mean EPT (s)±SD	7.20±5.49***	4.74±3.67	4.33±3.21	4.45±3.41	4.69±3.69###	8.07±6.53

*** p<0.001, versus subgroup D.
p<0.001, versus manual group.
APT, absolute phacoemulsification time; EPT, effective phacoemulsification time.

laser group chose to make primary and secondary incisions with FS laser as long as there was no surgical contraindication, such as corneal pannus and arcus senilis. The 193 cases of incomplete laser corneal incisions were related to the mild opacity of the peripheral cornea and the improper location of the incision. Our recent study found that FS laser incisions were more likely to result in surgery-induced astigmatism compared with manual incisions due to the challenge of accurately positioning the incision with the laser, while the direct visualisation was possible with manual incisions.³³ In addition, it is not recommended that the incisions be made too close to the centre, which will cause more severe astigmatism.

This study conducted a comprehensive analysis of a large cohort of patients undergoing FLACS to evaluate its safety profile and to explore the learning curve associated with this procedure. Our findings provide compelling evidence to support the safety of FLACS and offer training recommendations based on the identified learning curve. This is particularly instructive for young surgeons, enabling them to quickly master this new technology and avoid many unnecessary adverse outcomes, which benefit a wider audience of medical professionals and their patients. However, this study still has certain limitations. Because FLACS requires an out-of-pocket cost, it is difficult to conduct a random clinical trial in the present study, and surgeons have to respect the patients' choices. Moreover, the operating surgeons in this study were all experienced cataract specialists. However, FLACS may be of greater benefit to younger residents, and future research should focus on this group to further explore the potential advantages of this technique.

In conclusion, FLACS is a safe and efficient technology with lower required ultrasound power, APT and EPT compared with CPCS and an acceptable rate of complications. The learning curve of FLACS is associated with a significant reduction in the incidence of intraoperative complications. The length of the basic learning curve of FLACS is about 100 cases, and the length of the advanced learning curve is 150 cases. It is suggested that surgeons are required to undergo at least 100 FLACS procedures before they can be considered to be professionally competent in the technique, and surgeons-in-training should perform FLACS with extreme caution during the first 150 procedures.

Acknowledgements The authors would like to extend their gratitude to Professor Mona Harissi-Dagher at Centre Hospitalier de l'Université de Montréal for her support and invaluable feedback on this research.

Contributors All authors conceived and designed the study. XZ analysed data and drafted the article. KY, WX, XS, PC and YY performed the FLACS and collected data. KL and JL collected and interpreted data. WW and XC analysed data. KY is guarantor.

Funding This study is supported by the Zhejiang Province Key Research and Development Program (grant No. 2020C03035).

Competing interests None declared.

Patient consent for publication Not applicable.

Ethics approval This study involves human participants and was approved by the Medical Ethics Committee of the Second Affiliated Hospital of the School of Medicine, Zhejiang University, Hangzhou, China (2016-044). Participants gave informed consent to participate in the study before taking part.

Provenance and peer review Not commissioned; externally peer reviewed.

Data availability statement Data are available upon reasonable request.

Open access This is an open access article distributed in accordance with the Creative Commons Attribution Non Commercial (CC BY-NC 4.0) license, which permits others to distribute, remix, adapt, build upon this work non-commercially, and license their derivative works on different terms, provided the original work is properly cited, appropriate credit is given, any changes made indicated, and the use is non-commercial. See: <http://creativecommons.org/licenses/by-nc/4.0/>.

ORCID iDs

Wen Xu <http://orcid.org/0000-0002-6277-7136>
Xingchao Shentu <http://orcid.org/0000-0002-8563-7419>
Jiayong Li <http://orcid.org/0000-0002-6154-762X>
Ke Yao <http://orcid.org/0000-0002-6764-7365>

REFERENCES

- Popovic M, Campos-Möller X, Schlenker MB, *et al*. Efficacy and safety of Femtosecond laser-assisted cataract surgery compared with manual cataract surgery: A meta-analysis of 14 567 eyes. *Ophthalmology* 2016;123:2113–26.
- Chen X, Chen K, He J, *et al*. Comparing the curative effects between Femtosecond laser-assisted cataract surgery and conventional Phacoemulsification surgery: A meta-analysis. *PLoS ONE* 2016;11:e0152088.
- Bu JJ, Chung J, Afshari NA. Efficient use of ultrasound in cataract surgery. *Curr Opin Ophthalmol* 2022;33:41–6.
- Roberts TV, Lawless M, Bali SJ, *et al*. Surgical outcomes and safety of Femtosecond laser cataract surgery: a prospective study of 1500 consecutive cases. *Ophthalmology* 2013;120:227–33.
- Day AC, Burr JM, Bennett K, *et al*. Femtosecond laser-assisted cataract surgery versus Phacoemulsification cataract surgery (FACT): A randomized Noninferiority trial. *Ophthalmology* 2020;127:1012–9.
- Chen X, Xu J, Chen X, *et al*. Cataract: advances in surgery and whether surgery remains the only treatment in future. *Adv Ophthalmol Pract Res* 2021;1:100008.
- Miháltz K, Knorz MC, Alió JL, *et al*. Internal aberrations and optical quality after Femtosecond laser anterior Capsulotomy in cataract surgery. *J Refract Surg* 2011;27:711–6.
- Friedman NJ, Palanker DV, Schuele G, *et al*. Femtosecond laser Capsulotomy. *J Cataract Refract Surg* 2011;37:1189–98.
- Hatch KM, Schultz T, Talamo JH, *et al*. Femtosecond laser-assisted compared with standard cataract surgery for removal of advanced cataracts. *J Cataract Refract Surg* 2015;41:1833–8.
- Xu J, Chen X, Wang H, *et al*. Safety of Femtosecond laser-assisted cataract surgery versus conventional Phacoemulsification for cataract: A meta-analysis and systematic review. *Adv Ophthalmol Pract Res* 2022;2:100027.
- Conrad-Hengerer I, Al Sheikh M, Hengerer FH, *et al*. Comparison of visual recovery and refractive stability between Femtosecond laser-assisted cataract surgery and standard Phacoemulsification: six-month follow-up. *J Cataract Refract Surg* 2015;41:1356–64.
- Abell RG, Kerr NM, Howie AR, *et al*. Effect of Femtosecond laser-assisted cataract surgery on the corneal Endothelium. *J Cataract Refract Surg* 2014;40:1777–83.
- Zhang X, Yu Y, Zhang G, *et al*. Performance of Femtosecond laser-assisted cataract surgery in Chinese patients with cataract: a prospective, multicenter, Registry study. *BMC Ophthalmol* 2019;19:77.
- Roberts HW, Wagh VK, Sullivan DL, *et al*. A randomized controlled trial comparing Femtosecond laser-assisted cataract surgery versus conventional Phacoemulsification surgery. *J Cataract Refract Surg* 2019;45:11–20.
- Dzhaber D, Mustafa OM, Alsaleh F, *et al*. Visual and refractive outcomes and complications in Femtosecond laser-assisted versus conventional Phacoemulsification cataract surgery: findings from a randomised, controlled clinical trial. *Br J Ophthalmol* 2020;104:1596–600.
- Stanojic N, Roberts HW, Wagh VK, *et al*. A randomised controlled trial comparing Femtosecond laser-assisted cataract surgery versus conventional Phacoemulsification surgery: 12-month results. *Br J Ophthalmol* 2021;105:631–8.
- Lin CC, Rose-Nussbaumer JR, Al-Mohtaseb ZN, *et al*. Femtosecond laser-assisted cataract surgery: A report by the American Academy of Ophthalmology. *Ophthalmology* 2022;129:946–54.
- Schweitzer C, Brezin A, Cochener B, *et al*. Femtosecond laser-assisted versus Phacoemulsification cataract surgery (FEMCAT): a Multicentre participant-masked randomised superiority and cost-effectiveness trial. *Lancet* 2020;395:212–24.
- Abell RG, Kerr NM, Vote BJ. Femtosecond laser-assisted cataract surgery compared with conventional cataract surgery. *Clin Exp Ophthalmol* 2013;41:455–62.
- Schultz T, Dick HB. Suction loss during Femtosecond laser-assisted cataract surgery. *J Cataract Refract Surg* 2014;40:493–5.
- Nagy ZZ, Takacs AI, Filkorn T, *et al*. Complications of Femtosecond laser-assisted cataract surgery. *J Cataract Refract Surg* 2014;40:20–8.
- Yeoh R. Intraoperative Miosis in Femtosecond laser-assisted cataract surgery. *J Cataract Refract Surg* 2014;40:852–3.
- Grewal DS, Basti S. Intraoperative vertical gas breakthrough during clear corneal Incision creation with the Femtosecond cataract laser. *J Cataract Refract Surg* 2014;40:666–70.
- Roberts HW, Wagh VB, Sung J, *et al*. Risk-adjusted CUSUM analysis of the learning curve of Femtosecond laser assisted cataract surgery. *Curr Eye Res* 2019;44:887–95.
- Emery JM, Little JH. *Phacoemulsification and aspiration of cataracts: surgical techniques, complications and results*. Mosby, 1979.
- Bali SJ, Hodge C, Lawless M, *et al*. Early experience with the Femtosecond laser for cataract surgery. *Ophthalmology* 2012;119:891–9.

- 27 Nagy Z, Takacs A, Filkorn T, *et al.* Initial clinical evaluation of an Intraocular Femtosecond laser in cataract surgery. *J Refract Surg* 2009;25:1053–60.
- 28 Kránitz K, Takacs A, Miháltz K, *et al.* Femtosecond laser Capsulotomy and manual continuous curvilinear Capsulorrhexis parameters and their effects on Intraocular lens Centration. *J Refract Surg* 2011;27:558–63.
- 29 Abell RG, Darian-Smith E, Kan JB, *et al.* Femtosecond laser-assisted cataract surgery versus standard Phacoemulsification cataract surgery: outcomes and safety in more than 4000 cases at a single center. *J Cataract Refract Surg* 2015;41:47–52.
- 30 Chang JSM, Chen IN, Chan W-M, *et al.* Initial evaluation of a Femtosecond laser system in cataract surgery. *J Cataract Refract Surg* 2014;40:29–36.
- 31 Wang W, Chen X, Liu X, *et al.* Lens capsule-related complications in Femtosecond laser-assisted cataract surgery: a study based on Video analysis. *Br J Ophthalmol* 2023;107:906–11.
- 32 Chen X, Yu Y, Song X, *et al.* Clinical outcomes of Femtosecond laser-assisted cataract surgery versus conventional Phacoemulsification surgery for hard nuclear cataracts. *J Cataract Refract Surg* 2017;43:486–91.
- 33 Zhu S, Qu N, Wang W, *et al.* Morphologic features and surgically induced Astigmatism of Femtosecond laser versus manual clear corneal incisions. *J Cataract Refract Surg* 2017;43:1430–5.