

A Single-center Experience of *Coccidioides* Meningitis in Immunocompetent Patients: Case Series and Literature Review

Ravi Rajmohan,^{1,✉} Jacob Deyell,^{2,a} Mark Harris,^{2,a} Kevin Gramajo-Aponte,² Gianna Fote,³ Jordan Davies,³ Nita Chen,¹ Catherine Diamond,⁴ and Xiaoying Lu⁵

¹Department of Neurology, University of California, Irvine, California, USA, ²School of Medicine, University of California, Irvine, California, USA, ³Department of Neurosurgery, University of California, Irvine, California, USA, ⁴Department of Infectious Diseases, University of California, Irvine, California, USA, and ⁵Department of Neurology, Loma Linda University, Loma Linda, California, USA

Recently, the California Department of Public Health issued an advisory related to the substantial rise in *Coccidioidomycosis* in California, which has been attributed in part to climate change and rapid housing development. Most cases are self-limiting, but some may spread to the meninges, resulting in coccidioidal meningitis (CM). Many providers mistakenly presume that CM is limited to patients who are immunocompromised. In this case series and literature review, we present 12 cases of CM in immunocompetent individuals seen at a single tertiary academic center between 1 January 2019 and 31 December 2023. All 12 cases developed complications, with 10 requiring ventriculoperitoneal shunting, 6 having spinal cord involvement (5 with cervical spine involvement), 4 having strokes, and 3 dying from complications related to CM. It is important to recognize CM as it may be life-threatening if not promptly diagnosed.

Keywords. climate change; coccidioidal meningitis; *coccidioides*; fungal meningitis; immunocompetence.

Epidemiology

Coccidioidomycosis is a fungal infection caused by *Coccidioides*, a fungus found in soil endemic to areas in the southwestern

United States, northern Mexico, and parts of Central and South America [1, 2]. Rapid housing development has led to an increase in the incidence of cases. From 1998 to 2011 in Arizona and California, incident cases rose from 5.3 per 100 000 to 42.6 per 100 000 [3]. Earlier this year, the California Department of Public Health issued a health advisory regarding the substantial increase in *Coccidioidomycosis*, citing 9280 cases, suspected to be due in part to “heavy rainfall in the winter of 2022–2023 following years of drought” [4]. Global warming has been further implicated in the expansion of *Coccidioides* spores into new territories such as Washington state because of warmer and drier climates [5].

Although a review of *coccidioidomycosis* in immunocompetent patients is presented elsewhere [6], we review the existing literature specific to coccidioidal meningitis (CM), present a chart review of our single-center demographics of 33 CM cases, and provide a case series of 12 immunocompetent individuals (9 males, 3 females) to help guide recognition and management of this potentially life-threatening condition.

METHODS

Literature Review

We conducted a search of the PUBMED database for articles published in English, available as full text, involving human participants, up until 1 June 2024, using the MESH terms “meningitis” AND “*coccidioides*,” excluding preprints. The entries were screened by 3 authors (R.R., J.D., and M.H.) for potential relevance.

Participant Identification

Our institution is an academic tertiary referral center located in Orange County, California, USA. A chart review tool (Slicer Dicer, Epic, Verona, USA) was used to search the electronic medical record for cases of CM using the International Classification of Diseases, revision 10, code for CM (ICD-10-CM: B38.4) between 1 January 2019 and 31 December 2023. Thirty-three cases were identified and 12 cases were directly seen by at least 1 of the physician coauthors and were determined to be immunocompetent at time of initial infection. Institutional review board approval was obtained for this study from the University of California, Irvine institutional review board (protocol # 3352).

Statistical Analyses

Fisher exact test analyses were used to determine if CM prevalence occurred at a greater-than-chance rate based on self-identified race or ethnicity compared to 2021 US census data for racial

Received 24 July 2024; editorial decision 23 September 2024; accepted 03 October 2024; published online 5 October 2024

^aThese authors contributed equally.

Correspondence: Ravi Rajmohan, MD, PhD, Department of Neurology, University of California, 19200 Jamboree Rd, Irvine, CA 92612 (rrajmoha@hs.uci.edu); Xiaoying Lu, MD, PhD, Department of Neurology, Loma Linda University, 11234 Anderson St, Loma Linda, CA 92354.

Open Forum Infectious Diseases®

© The Author(s) 2024. Published by Oxford University Press on behalf of Infectious Diseases Society of America. This is an Open Access article distributed under the terms of the Creative Commons Attribution-NonCommercial-NoDerivs licence (<https://creativecommons.org/licenses/by-nc-nd/4.0/>), which permits non-commercial reproduction and distribution of the work, in any medium, provided the original work is not altered or transformed in any way, and that the work is properly cited. For commercial re-use, please contact reprints@oup.com for reprints and translation rights for reprints. All other permissions can be obtained through our RightsLink service via the Permissions link on the article page on our site—for further information please contact journals.permissions@oup.com. <https://doi.org/10.1093/ofid/ofae590>

and ethnic demographics in Orange County, California, USA, from the American Community Survey [7].

RESULTS

Literature Review

A total of 59 entries were identified (Figure 1). Forty articles were deemed to be relevant original articles; 18 articles reported at least 1 immunocompetent CM case, 15 did not report on immune status, and 7 had only immunocompromised cases. Supplementary Table 1 contains the complete study list. No studies directly compared immunocompetent cases to immunocompromised cases of CM. Twelve additional review articles are incorporated into the literature review to broaden the discussion of coccidiomycosis for context.

Literature Review: Epidemiology

A total of 89 immunocompetent CM cases were identified. The youngest case was age 23 days [8], most were between age 30 and 60 years, whereas the oldest was age 80 years [9]. A retrospective analysis from southern Arizona revealed that the demographics most affected were men (2:1 male: female ratio) of Asian, African, and Hispanic descent [10].

Literature Review: Clinical Presentations

It is estimated that 95% of pulmonary infections self-resolve, but if the fungus spreads to the central nervous system, it is universally fatal without treatment [1, 11]. Patients can present with symptoms as minor as a mild headache. More serious symptoms include global headaches lasting from weeks to months, cognitive decline, gait disturbances, diplopia, disorientation, lethargy, and/or stupor [1]. On physical examination,

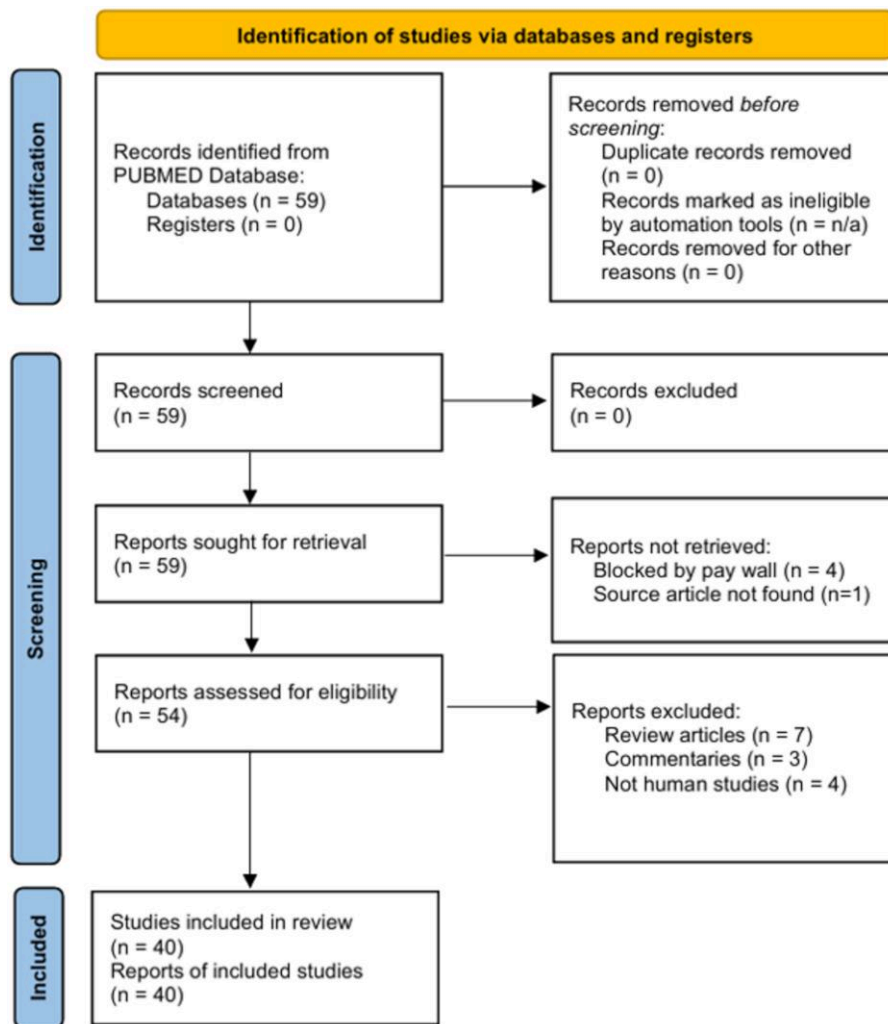


Figure 1. Diagram of literature review search. This literature search does not meet all of the requirements of the Preferred Reporting Items for Systematic reviews and Meta-Analyses (PRISMA) guidelines. This format of this diagram is provided for the viewer's convenience. Source: Page MJ, et al. BMJ 2021;372:n71. doi: 10.1136/bmj.n71. This work is licensed under CC BY 4.0. To view a copy of this license, visit <https://creativecommons.org/licenses/by/4.0/>.

nuchal rigidity is uncommon [1]. Signs of pulmonary or extrapulmonary infection occur in only 1/3 to 2/3 of patients with CM and clinical presentations will depend on these additional sites of infection [1].

Literature Review: Diagnostic Work Up

CM diagnosis relies on cerebral spinal fluid (CSF) or biopsy [12]. In immunocompetent patients, detectable serum immunoglobulin M (IgM) antibody is typically seen within 1 to 3 weeks of symptom onset, followed shortly thereafter by IgG production [13]. Immunodiffusion (ID) and complement fixation (CF) remain the benchmarks, with the former test being more sensitive. A positive CF test for IgG antibody in CSF is considered diagnostic for CM in the setting of a compatible clinical syndrome [14]. High

serum titers may “spill over” into CSF, resulting in false-positive ID results for CSF samples. Therefore, CF is the recommended diagnostic modality for CM diagnosis. A serum CF titer greater than 1:32 is concerning for dissemination of the disease [13, 14]. A CSF culture confirms a diagnosis of CM but is typically positive in only 25% of patients [15]. A cellular profile of CSF that would be suggestive of CM may include a lymphocytic, polymorphonuclear neutrophilic, or characteristically eosinophilic pleocytosis [12] with elevated protein, low glucose [1, 11, 12, 16], and elevated opening pressure. Diagnostic techniques that have not been thoroughly validated should be avoided, including measuring (1,3)- β -glucan in serum, antibody enzyme immunoassays, lateral flow tests [1, 11], and polymerase chain reaction for presence of fungal nucleic acid [17]. Hydrocephalus may be seen on noncontrast head computed tomography [18], whereas magnetic resonance imaging may show leptomeningeal enhancement and nodularity [1, 16].

Table 1. Demographics of Coccidioides Meningitis Cases

	Total CM Cases (n = 33) (%)	Immunocompetent Subset (n = 12) (%)
Age in y: mean (range)	53 (24–86)	34 (21–67)
Female	8 (24)	3 (25)
Male	25 (76)	9 (75)
Asian	6 (19)	2 (17)
Black	3 (9)	2 (17)
Native Hawaiian or Other Pacific Islander	1 (3)	1 (8)
Other Race or Mixed Race	6 (19)	2 (17)
Not stated	1 (3)	0 (0)
White	17 (52)	5 (42)
Hispanic	16 (48)	4 (33)
Non-Hispanic	17 (52)	8 (66)

Abbreviation: CM, coccidioides meningitis.

Literature Review: Effective Treatments

Treatment was revolutionized in the 1990s when third-generation azoles were proven to be effective in managing CM [12]. Nonetheless, azoles are fungistatic agents and lifelong treatment is required. The most common primary treatment for CM is fluconazole at 400–1200 mg daily, but there is no consensus for the starting dose [12]. Azoles should also be avoided in patients in the first trimester of pregnancy because of teratogenicity [11, 12]. Adjunctive treatments include corticosteroids, which were associated with a significant reduction in secondary cerebrovascular events in a multicenter retrospective cohort [19]. A coccidioides vaccine remains elusive [20, 21].

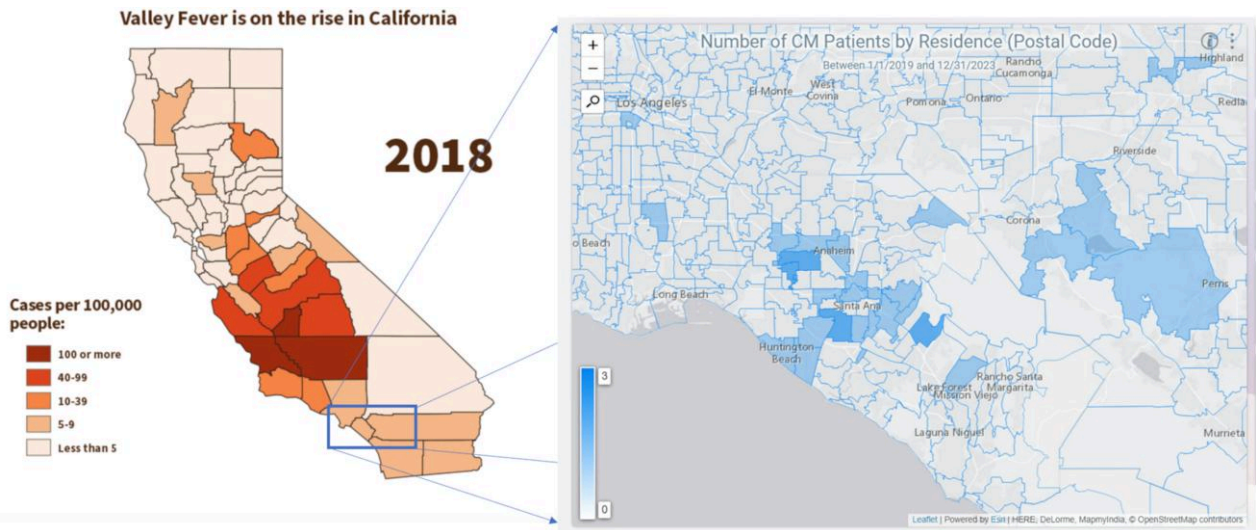


Figure 2. Incidence of coccidioidomycosis reported by the California Department of Public Health in 2018 (left) compared to the geographic distribution of Coccidioides meningitis (CM) cases by postal code of residence in this case series (right). Shaded represent the postal codes in which CM reside. The deeper intensity of shading represents a higher number of cases, ranging from 0 to 3. Source: Sondermeyer Cooksey GL, Nguyen A, Vugia D, Jain S. Regional analysis of coccidioidomycosis incidence—California, 2000–2018. *MMWR Morb Mortal Wkly Rep.* 2020;69(48):1817–1821. Published 2020 Dec 4. doi:10.15585/mmwr.mm6948a4.

Table 2. Summary of Case Series

	Case 1	Case 2	Case 3
Legal sex	M	M	F
Age of onset (y)	21	25	25
Time of onset before review (y)	3	2	6
Self-identified race	African American	Asian American	White
Self-identified ethnicity	Non-Hispanic	Non-Hispanic	Hispanic
Predisposing condition	None known	None known	None known
Possible source	Inland Empire, CA	Oregon	Fountain Valley, CA
Presenting symptoms	Headaches, progressive weakness	Headaches, diplopia, and left-sided weakness	Headaches, confusion, and vomiting
Classic hydrocephalus triad on presentation?	Yes	Yes	Yes
Initial examination findings	Diffuse, symmetric weakness affecting upper extremities > lower extremities, hyperreflexia with bilateral Hoffman and Babinski signs	Left-sided distal > proximal weakness, hyperreflexia, and ataxia	Unknown
Evidence of hydrocephalus on first scan?	Yes	Yes	Unknown
Time from symptom onset to first evidence of hydrocephalus on imaging (wk)	6	3	Unknown
HIV status	Negative	Negative	Negative
Method of establishing diagnosis	CSF and serum complement fixation	CSF antibody Serum complement fixation	CSF fungal culture Serum complement fixation
Complications	Syringomyelia in C-spine with lumbar drain, superimposed bacterial infection of VPS	Hydrocephalus	Intradural lumbar spinal abscess, blurry vision, craniectomy, hydrocephalus, BLE weakness
C-spine involvement	Yes	Yes	No
Needed VPS?	Yes	Yes	Yes
Treatment	Fluconazole	Fluconazole	Fluconazole
Time to treatment (wk)	6	12	Unknown
Outcome	Return to full strength, near-total resolution of symptoms	Improved to near-baseline	Improved to near-baseline
Modified Rankin scale	2	0	4
Deceased?	No	No	No
Time from symptom onset to death	N/A	N/A	N/A

	Case 4	Case 5	Case 6
Legal sex	M	M	F
Age of onset	27	27	31
Time of onset before review (y)	2	22	8
Self-identified race	Asian American	Other Race or Mixed Race	Native Hawaiian or Other Pacific Islander
Self-identified ethnicity	Non-Hispanic	Hispanic	Non-Hispanic
Predisposing condition	None known	None known	None known
Possible source	California central valley	Santa Ana, CA	Fountain Valley, CA
Presenting symptoms	Headaches, confusion, and vomiting	Neck pain, mild headache	Headaches, confusion, and vomiting
Classic hydrocephalus triad on presentation?	Yes	No	Yes
Initial examination findings	Right upper extremity weakness, blurred disc margins on funduscopy	+ Brudzinski sign, decreased breath sounds in RUL	Nonfocal headache
Evidence of hydrocephalus on first scan?	No	No	No
Time from symptom onset to first evidence of hydrocephalus on imaging (wk)	5	Unknown	4
HIV status	Negative	Negative	Negative
Method of establishing diagnosis	CSF fungal culture Serum immunodiffusion	Serum complement fixation	CSF fungal culture Serum complement fixation

Table 2. Continued

	Case 4	Case 5	Case 6
Complications	Hydrocephalus, strokes	Gait imbalance, hydrocephalus c/b tonsillar herniation with medulla compression, c-spine epidural abscess, propionibacterium acnes meningitis, ataxia, blurry vision, muscle atrophy, stroke c/b left hemiparesis	Bilateral retroorbital pain, diplopia, Parinaud syndrome, superior hemifield visual defects
C-spine involvement	No	Yes	No
Needed VPS?	No	Yes	Yes
Treatment	Fluconazole	Fluconazole, amphotericin	Amphotericin, fluconazole, voriconazole
Time to treatment (wk)	3	Recurrent across many years (nonadherent to fluconazole because of price)	Unknown
Outcome	Improved to near-baseline	New baseline of spasticity in BLEs, atrophic muscle bulk, and wide-based gait (patient now uses cane for ambulation)	Improved to near-baseline
Modified Rankin scale	1	3	1
Deceased?	No	No	No
Time from symptom onset to death	N/A	N/A	N/A

	Case 7	Case 8	Case 9
Legal sex	M	M	M
Age of onset	37	44	47
Time of onset prior to review (y)	7	8	6
Self-identified race	Other Race or Mixed Race	African American	White
Self-identified ethnicity	Hispanic	Non-Hispanic	Hispanic
Predisposing condition	Exposure to excavation site	Exposure to excavation site	None known
Possible source	Lake Forest, CA	Sacramento, CA	Santa Ana, CA
Presenting symptoms	Headaches, dizziness, double vision	Intermittent headaches and left eye deficits	Headache, confusion, and seizures
Classic hydrocephalus triad on presentation?	No	No	Yes
Initial examination findings	Unknown	Left-sided vision loss and headache	Photosensitivity, headache, imbalance, speech difficulty, upper left maxillary abscess
Evidence of hydrocephalus on first scan?	Unknown	No	Unknown
Time from symptom onset to first evidence of hydrocephalus on imaging (wk)	Unknown	Unknown	Unknown
HIV status	neg	neg	neg
Method of establishing diagnosis	CSF fungal culture	Serum complement fixation	CSF and serum complement fixation
Complications	Abdominal pseudocyst adjacent to VPS catheter tip	Left optic nerve atrophy, possible left lacrimal neoplasm, left lower lobe scarring from inoculation pneumonia	Thalamic stroke, seizure disorder, communicating hydrocephalus, cerebritis, ptosis and diplopia of left eye, cranial nerve III palsy
C-spine involvement	No	No	No
Needed VPS?	Yes	No	Yes
Treatment	Voriconazole to fluconazole because of elevated LFTs	Voriconazole	Fluconazole (failed, transitioned to voriconazole now)
Time to treatment (wk)	Unknown	Unknown	Unknown
Outcome	Improved to near-baseline	unknown	Improved to near-baseline
Modified Rankin scale	1	2	4
Deceased?	No	No	No
Time from symptom onset to death	N/A	N/A	N/A

	Case 10	Case 11	Case 12
Legal sex	M	M	F
Age of onset	55	56	67
Time of onset prior to review (y)	11	4	3
Self-identified race	White	White	White
Self-identified ethnicity	Non-Hispanic	Hispanic	Non-Hispanic

Table 2. Continued

	Case 10	Case 11	Case 12
Predisposing condition	None known	None known	Celiac disease
Possible source	Tustin, CA	Bakersfield, CA	Arizona
Presenting symptoms	Progressive weakness involving all 4 limbs starting from the left side	Headaches, confusion, and vomiting	Headaches, fever, and confusion
Classic hydrocephalus triad on presentation?	No	Yes	Yes
Initial examination findings	Unknown	Encephalopathic without other pertinent findings	Obtunded, multidirectional nystagmus, localizing to noxious stimuli, bilateral Hoffman and Babinski signs
Evidence of hydrocephalus on first scan?	Unknown	Unknown	No
Time from symptom onset to first evidence of hydrocephalus on imaging (wk)	Unknown	Unknown	7
HIV Status	Negative	Negative	Negative
Method of establishing diagnosis	CSF and serum complement fixation	CSF immunodiffusion Serum complement fixation	CSF complement fixation and immunodiffusion Brain biopsy
complications	Myelomalacia, Quadripareisis resulting in tracheostomy and ventilator dependency, arachnoid cyst (syrinx) formation (C3), bilateral blurry vision	Hydrocephalus, strokes, leptomenigeal spread	Hydrocephalus, strokes
C-spine involvement	Yes	Yes	No
Needed VPS?	Yes	Yes	Yes
Treatment	fluconazole	fluconazole	fluconazole
Time to treatment (wk)	Unknown	20	12
Outcome	Passed from complications of secondary infections in setting of quadripareisis	Passed from complications of basilar meningitis (recurrent strokes and hydrocephalus)	Passed from complications of basilar meningitis (recurrent strokes and hydrocephalus)
Modified Rankin scale	6	6	6
Deceased?	Yes	Yes	Yes
Time from symptom onset to death	11 y	18 mo	5 mo

Abbreviations: BLE, bilateral lower extremities; c/b, complicated by; C-spine, cervical spine; F, female; M, male; N/A, not applicable; RUL, right upper lung lobe; VPS, ventriculoperitoneal shunt; classic triad of hydrocephalus, headache, vomiting, fluctuating mental status.

Chart Review Demographics

Demographic comparisons of the 33 cases identified through chart review and the 12 immunocompetent cases is provided in [Table 1](#). The number of new cases remained stable across the 5-year period with an average of roughly 3 new cases/year (± 2) ([Supplementary Figure 1](#)). Fifteen cases (45%) occurred in patients who were between age 18 and 50 years and 18 were >50 (55%) with a median age of 53 (± 16) years. However, this represents the patients’ current age and the age of infection onset could not be determined from this method. Twenty-five patients were male and 8 were female (roughly 3:1). A total of 52% of patients self-identified as White, 19% as Other/Mixed race, 19% as Asian, 9% as Black, and 3% as Native Hawaiian or Pacific Islander ([Supplementary Figure 2](#)). Forty-eight percent identified as Hispanic and 52% as non-Hispanic (not pictured). Geographic distribution by postal code of residence for cases is presented in [Figure 2](#).

Immunocompetent Cases

Twelve participants directly assessed by the physician authors were determined to be immunocompetent. All 12 had nonreactive HIV serum studies. A summary of these cases is provided in [Table 2](#). The median age of symptom onset was 34 (± 15 years; range, 21–67) years. There were 9 males and 3 females. Two cases endorsed exposure to a construction site where excavation was ongoing. One had known celiac disease with no evidence of immunocompromise on diagnostic studies or history of treatment with immunomodulatory therapies. The 9 remaining cases had no clear predisposing condition or exposure risk.

Eight of 12 (67%) presented with the classic triad of hydrocephalus (headaches, confusion, and vomiting). Of the 4 without the classic triad, 2 presented with headache and oculomotor nerve deficits, 1 with neck pain, and 1 with progressive asymmetric weakness. Three of 7 had evidence of hydrocephalus on the first head computed tomography acquired. Two of 5 who underwent noncontrast head computed tomography scan at the time of having the classic triad did not show evidence of hydrocephalus. All 12 cases developed complications,

Table 3. Fisher Exact Test Analyses of Prevalence of *Coccidioides* Meningitis (CM) by Racial and Ethnic Demographics for the Total Number of CM Cases (top) Compared to Census Data of Orange County (OC)

White	Observed	Expected
White	15	18
Others	18	15
Fisher exact test <i>P</i> -value = .6075		
Asian	Observed	Expected
Asian	6	7
Others	27	26
Fisher exact test <i>P</i> -value = 1.0000		
Black	Observed	Expected
Black	3	1
Others	30	32
Fisher exact test <i>P</i> -value = .3545		
Other/Mixed race	Observed	Expected
Other	6	3
Others	27	30
Fisher exact test <i>P</i> -value = .3184		
Native Hawaiian or Pacific Islander	Observed	Expected
Native Hawaiian or Pacific Islander	1	0
Others	32	33
Fisher exact test <i>P</i> -value = .4848		
Hispanic	Observed	Expected
Hispanic	16	11
Others	17	22
Fisher exact test <i>P</i> -value = .2433		
Non-Hispanic	Observed	Expected
Non-Hispanic	17	22
Hispanic	16	11
Fisher exact test <i>P</i> -value = .2433		

To correct for multiple comparisons, a *P*-value <.025 with adjustment of 6 degrees of freedom was considered significant. No comparisons were considered significant.

with 10 requiring ventriculoperitoneal shunting, 6 having spinal cord involvement (5 with cervical spine involvement), 4 having strokes, and 3 dying from complications related to CM. All patients were treated with antifungal agents. Information on treatment initiation was available for 5 cases. The median time to treatment initiation was 12 weeks (\pm 6) but was 16 weeks for those with an age of symptom onset >50 compared to 6 weeks for those <50. The 3 cases with an age of symptom onset >50 passed away, whereas all others have survived. Two of these patients died in the subacute setting because of recurrent strokes secondary to basilar meningitis, whereas the third died from recurrent infections and medical complications secondary to quadriplegia from *coccoides* myelitis 11 years after the initial infection.

Table 3 provides a comparison of racial and ethnic demographics from US census data of Orange County to our total CM cases. Self-identified race or Hispanic ethnicity was not associated with a higher than chance probability of infection.

DISCUSSION

We note that immunocompetent cases had similar demographics to the total number of CM cases. In both groups, there was a 3:1 male: female ratio, with a majority of cases occurring in males between ages 20 and 70 years, similar to the male:female ratio of CM cases observed by others [10]. Unlike prior reports, we did not see a greater-than-chance prevalence of CM cases for those who identified as Asian or Hispanic [10]. The majority of patients presented with classic symptoms of hydrocephalus. Among our immunocompetent group, neuroimaging demonstrated signs of hydrocephalus 12 weeks after symptom onset on average. The nonspecific nature of initial presentation is unfortunate because CM has a number of serious complications, including quadriparesis from syringomyelia, refractory hydrocephalus, recurrent strokes, and death.

The time between symptom onset to initiation of treatment was largely dependent on timing of diagnosis. Although advanced age may be associated with poorer prognosis, it is important to note that the median time to initiation of treatment for those age <50 years was 6 weeks versus 16 weeks for those age >50 years. This highlights the importance of improving physician awareness of hydrocephalus and CM in elderly patients who present with nonfocal complaints because this 10-week delay may be a critical period in preventing the formation of life-threatening basilar meningitis. Fungal infections of immunocompetent individuals are not limited to *Coccidioides*. A large prospective cohort study has looked at cryptococcal infection of HIV-negative patients and noted significant sequelae of infection [22].

A strength of this investigation is that it is, to our knowledge, the first case series to review CM infections specifically in immunocompetent individuals. Three other case series were identified that had sizeable immunocompetent CM populations (\geq 10 cases) [10, 23, 24]. Demographic information on these subgroups was not reported, prohibiting comparisons to immunocompromised groups or to our data. Limitations include that this is a single-center study and the lack of an immunocompromised comparison group. Our institutional review board protocol restricted our review of cases not directly assessed by the physician authors to anonymized data. We cannot determine if the patients contracted the infection in the same place as their residence (Figure 2). Other healthcare networks exist in our county, and this may bias the demographics of the patients seen. Several cases presented for acute management and lacked sufficient records to determine their initial examination findings.

We exercise caution in interpreting our findings with regard to demographics. It remains possible that immunocompetent patients may have predisposing genetic conditions that were not identified. We emphasize that epidemiological investigations to understand differences in risk factors, pathogenesis,

presenting symptoms, and response to treatment across diverse populations should remain a priority to ensure equitable care in the face of a growing prevalence of the disease. Future studies should assess for differences in clinical findings and disease progression between immunocompetent and immunocompromised patients with CM.

CONCLUSION

It is a common misconception that CM is an opportunistic infection. We discuss our single-center experience within the context of the existing literature to improve early diagnosis and management for common complications of this life-threatening disease. This is of particular importance as large-scale construction projects for housing development throughout the southwestern United States may lead to the release of *Cocci* spores from the soil and to further infections with compounding concerns of more severe weather extremes brought on by global warming expanding the endemic territory of *Coccidioides*.

Supplementary Data

Supplementary materials are available at *Open Forum Infectious Diseases* online. Consisting of data provided by the authors to benefit the reader, the posted materials are not copyedited and are the sole responsibility of the authors, so questions or comments should be addressed to the corresponding author.

Notes

Acknowledgments. Not applicable.

Author Contributions. R.R. provided conceptual framework for the manuscript, contributed to manuscript text and figure design, and critically revised the article. M.H. and J.S.D. drafted the article along with figure design. K.G.A., G.F., and J.D. obtained patient information and contributed to the text. N.C., C.D., and X.L. contributed to the conceptual framework and critically revised the manuscript. Neither chatbots nor artificial intelligence was used for any portion of this work.

Disclaimer. Ethics, approval, and consent to participate: The University of California, Irvine institutional review board approved this study (approval #3352). Written informed consent was obtained from all cases described within following reasonable attempts to contact the patient or next of kin as per the institutional review board's determination. Consent was waived by the institutional review board for circumstances in which the patient or next of kin could not be contacted despite all reasonable attempts.

Availability of data and materials. Anonymized data and materials will be made available upon reasonable request to the corresponding author within the stipulations of the institutional review board approval and applicable privacy laws.

Financial support. None.

Potential conflicts of interest. The authors: No reported conflicts of interest.

All authors have submitted the ICMJE Form for Disclosure of Potential Conflicts of Interest. Conflicts that the editors consider relevant to the content of the manuscript have been disclosed.

References

1. Jackson NR, Blair JE, Ampel NM. Central nervous system infections due to coccidioidomycosis. *J Fungi (Basel)* **2019**; 5:54.
2. Stockamp NW, Thompson GR III. Coccidioidomycosis. *Infect Dis Clin North Am* **2016**; 30:229–46.
3. Krogstad P, Johnson R, Garcia-Lloret MI, Heidari A, Butte MJ. Host-pathogen interactions in coccidioidomycosis: prognostic clues and opportunities for novel therapies. *Clin Ther* **2019**; 41:1939–1954.e1.
4. California Department of Public Health (CDPH). Substantial Rise in Coccidioidomycosis in California: Recommendations for California Healthcare Providers. 1/18/2024. Available at: <https://www.cdph.ca.gov/Programs/OPA/Pages/CAHAN/Substantial-Rise-in-Coccidioidomycosis-in-California-Recommendations-for-California-Healthcare-Providers.aspx>. Accessed 5 January 2024.
5. Litvintseva AP, Marsden-Haug N, Hurst S, et al. Valley fever: finding new places for an old disease: *Coccidioides immitis* found in Washington State soil associated with recent human infection. *Clin Infect Dis* **2015**; 60:e1–3.
6. Galgiani JN, Kauffman CA. Coccidioidomycosis and histoplasmosis in immunocompetent persons. *N Engl J Med* **2024**; 390:536–47.
7. American Community Survey. ACS 5-year data estimates profiles ACS Demographic and Housing Estimates. **2021**. Available at: <https://data.census.gov/table/ACSDP5Y2021.DP05?q=DP05>. Accessed 1 June 2024.
8. Nolt JD, Geertsma FR. Deep solitary brain mass in a four-month-old male with disseminated coccidioidomycosis: case report. *Ann N Y Acad Sci* **2007**; 1111: 385–94.
9. Cárdenas G, Aristizábal S, Salinas C, et al. Coccidioidal meningitis in non-AIDS patients. A case series at a Mexican neurological referral center. *Clin Neurol Neurosurg* **2020**; 196:106011.
10. Drake KW, Adam RD. Coccidioidal meningitis and brain abscesses: analysis of 71 cases at a referral center. *Neurology* **2009**; 73:1780–6.
11. Bays DJ, Thompson GR III. Coccidioidomycosis. *Infect Dis Clin North Am* **2021**; 35:453–69.
12. Johnson R, Ho J, Fowler P, Heidari A. Coccidioidal meningitis: a review on diagnosis, treatment, and management of complications. *Curr Neurol Neurosci Rep* **2018**; 18:19.
13. McHardy IH, Barker B, Thompson GR III. Review of clinical and laboratory diagnostics for coccidioidomycosis. *J Clin Microbiol* **2023**; 61:e0158122.
14. McHardy IH, Dinh BN, Waldman S, et al. Coccidioidomycosis complement fixation titer trends in the age of antifungals. *J Clin Microbiol* **2018**; 56:e01318–18.
15. Crum NF. Coccidioidomycosis: a contemporary review. *Infect Dis Ther* **2022**; 11: 713–42.
16. Singhi P, Saini AG. Fungal and parasitic CNS infections. *Indian J Pediatr* **2019**; 86: 83–90.
17. Vucicevic D, Blair JE, Binnicker MJ, et al. The utility of *Coccidioides* polymerase chain reaction testing in the clinical setting. *Mycopathologia* **2010**; 170:345–51.
18. Orłowski HLP, McWilliams S, Mellnick VM, et al. Imaging spectrum of invasive fungal and fungal-like infections. *Radiographics* **2017**; 37:1119–34.
19. Thompson GR III, Blair JE, Wang S, et al. Adjunctive corticosteroid therapy in the treatment of coccidioidal meningitis. *Clin Infect Dis* **2017**; 65:338–41.
20. Pappagianis D. Evaluation of the protective efficacy of the killed *Coccidioides immitis* spherule vaccine in humans. The Valley Fever Vaccine Study Group. *Am Rev Respir Dis* **1993**; 148:656–60.
21. Kirkland TN. The quest for a vaccine against coccidioidomycosis: a neglected disease of the Americas. *J Fungi (Basel)* **2016**; 2:34.
22. Marr KA, Sun Y, Spec A, et al. A multicenter, longitudinal cohort study of cryptococcosis in human immunodeficiency virus-negative people in the United States. *Clin Infect Dis* **2020**; 70:252–61.
23. Mathisen G, Shelub A, Truong J, Wigen C. Coccidioidal meningitis: clinical presentation and management in the fluconazole era. *Medicine (Baltimore)* **2010**; 89: 251–84.
24. Kassis C, Zaidi S, Kuberski T, et al. Role of coccidioides antigen testing in the cerebrospinal fluid for the diagnosis of coccidioidal meningitis. *Clin Infect Dis* **2015**; 61:1521–6.