

Effectiveness and safety of the combination therapy of micro-needling and minoxidil in androgenetic alopecia of Indonesian men: a randomized controlled trial

Kara Adistri,^{1,2} Sondang P. Sirait,^{1,2} Rahadi Rihatmadja,^{1,2} Lili Legiawati,^{1,2} Wresti Indriatmi,^{1,2} Siti R.F. Saldi^{2,3}

¹Department of Dermatology and Venereology, Faculty of Medicine, Universitas Indonesia, Jakarta; ²Dr. Cipto Mangunkusumo Hospital, Jakarta; ³Clinical Epidemiology and Evidence-Based Medicine Unit, Faculty of Medicine, Universitas Indonesia, Jakarta, Indonesia

Abstract

Androgenetic alopecia (AGA) is the most common type of hair loss. Treatment options are limited. Microneedling, a minimally invasive technique can enhance hair growth by releasing

Correspondence: Sondang P. Sirait, Department of Dermatology and Venereology Faculty of Medicine Universitas Indonesia - Dr. Cipto Mangunkusumo Hospital, Jakarta, Indonesia.
E-mail: sondangdr@yahoo.com

Key words: androgenetic alopecia; micro-needling; minoxidil.

Contributions: KA, SPS, RR, LL, WI, drafting, writing; KA, SRFS, analysis; KA, data collection; SPS, RR, LL, WI, SRFS, review. All the authors approved the final version to be published.

Conflict of interest: the authors declare no potential conflicts of interest.

Funding: this study was supported by Universitas Indonesia (Hibah Publikasi Terindeks Internasional Pascasarjana 2022). Grant number: NKB-214/UN2.RST/HKP.05.00/2022.

Ethical approval and consent to participate: the study has obtained ethical approval under the reference number KET-375/UN2.F1/ETIK/PPM.00.02/2023 issued by the Research Ethics Committee of RSCM, Faculty of Medicine, University of Indonesia.

Availability of data and material: data and materials are available by the authors.

Informed consent: the subjects included in this research signed an informed consent form to participate in the study.

Received: 21 January 2024.

Accepted: 4 February 2024.

This work is licensed under a Creative Commons Attribution-NonCommercial 4.0 International License (CC BY-NC 4.0).

©Copyright: the Author(s), 2024

Licensee PAGEPress, Italy

Dermatology Reports 2024; 16:9945

doi:10.4081/dr.2024.9945

Publisher's note: all claims expressed in this article are solely those of the authors and do not necessarily represent those of their affiliated organizations, or those of the publisher, the editors and the reviewers. Any product that may be evaluated in this article or claim that may be made by its manufacturer is not guaranteed or endorsed by the publisher.

growth factors. However, no standardized protocol for frequency, depth and duration is available. This study aimed to determine the effectiveness and safety of the combination therapy of microneedling and minoxidil in AGA. This study was a randomized controlled clinical trial conducted over 12 weeks. The intervention group received a 4-weekly combination therapy of microneedling + 5% minoxidil, while the control group got only topical 5% minoxidil. Hair density and diameter were assessed using FotoFinder® trichoscale (Fotofinder Systems GmbH, Bad Birnbach, Germany) every 4 weeks. A total of 36 male participants, between 26-51 years old, with Hamilton-Norwood type III-VI AGA were included. At the end of the study, the intervention group had significantly higher hair density (95.6 vs 52.4 hair/cm², p<0.001) and diameter (18 vs 6 μm, p=0.004) than the control group. Side effects, included itching and transient erythema, were well tolerated. The combination of 4-weekly microneedling and topical 5% minoxidil is effective in increasing both hair density and hair diameter, and safe to use in AGA patients.

Introduction

Androgenetic alopecia (AGA) is the most common form of hair loss, affecting both men and women worldwide, with varying prevalence rates based on gender and ethnicity. In men, around 50-60% experience AGA by age 50, rising to 80% by age 70, while women have lower rates (29-42% by age 70). Alopecia androgenetic is also influenced by ethnicity, with different patterns seen in Asian populations compared to others.¹⁻³

Androgenetic alopecia accounts for 31.2% of hair loss cases at our institution between 2017-2019. It primarily affects men, often with a family history of the condition.⁴ Genetic and environmental factors play a role in AGA, primarily driven by androgen in men. This condition often leads to a gradual reduction in hair density in specific regions of the scalp.^{5,6} Androgenetic alopecia significantly impacts patients' quality of life, causing concerns about aging and attractiveness. Most patients experience moderate to severe impacts on their quality of life, with a strong desire for effective treatment to prevent further hair loss.^{7,8}

Treatment options for AGA are limited and include medications like minoxidil and finasteride, as well as procedures such as microneedling (MN). While minoxidil is a common treatment, its mechanism is not entirely understood but is believed to improve blood flow and hair growth factors.⁹ Microneedling is a newer technique that uses tiny needles to stimulate hair growth and enhance the absorption of topical medications.¹⁰ Nevertheless, universal protocol has not yet been established. The aim of this study is to determine the effectiveness and safety of the combination therapy of 4-weekly MN and topical 5% minoxidil in AGA.

Materials and Methods

Study design and population

This study is a controlled randomized clinical trial. The sample collection for this study was conducted at the Dermatology and Venereology Outpatient Clinic at Dr. Cipto Mangunkusumo Hospital (RSCM) from May to August 2023. The study has obtained ethical approval under the reference number KET-375/UN2.F1/ETIK/PPM.00.02/2023 issued by the Research Ethics Committee of RSCM, Faculty of Medicine, University of Indonesia, and has been registered on *clintrials.gov* with ID NCT05989165. The subjects include all Indonesian male diagnosed with AGA who were selected based on inclusion and exclusion criteria and were willing to sign the informed consent form to participate in the study. The inclusion criteria for the subjects are Indonesian male, age 18-59 years, diagnosed with AGA type III-VI based on Hamilton-Norwood scale. The exclusion criteria include: the use of topical minoxidil or finasteride in the last 1 month; the use of oral minoxidil or finasteride in the last 2 months; has skin infection in the balding area; underwent AGA therapy procedures such as PRP injection, laser treatment, or MN within the last 3 months before the study; and a history of keloid.

Study procedures

Thirty-six subjects who met the inclusion and exclusion criteria, and signed the informed consent form, were randomized to receive either combined MN and topical minoxidil 5% therapy (intervention group) or topical 5% minoxidil therapy (control group). The randomization was conducted using a combination block randomization method. The patient's randomization number was matched with their arrival order. Based on the randomization results, 18 subjects were assigned to the intervention group, while 18 subjects were assigned to the control group. All subjects were instructed to apply 5% minoxidil twice daily for 12 weeks. Subjects in the intervention group received MN therapy every 4 weeks (weeks 0, 4, and 8). The treatment area encompasses the frontal region, measuring 20×5 cm. Prior to the procedure, a topical anesthetic cream (2.5% lidocaine and 2.5% prilocaine) is applied to the target area and left in place for a duration of 15-45 minutes. The area is then cleansed with physiologic saline solution and an alcohol swab. A needle depth of 0.6 mm is selected, this depth was selected based on previous study. The desired endpoint

is the presence of pinpoint bleeding or mild erythema. At the end of procedure, the area is cleansed using physiologic saline solution, and a 2% fusidic acid cream is applied. Minoxidil is given 24 hours after the procedure.

Outcome measure

Evaluations were performed at weeks 0, 4, 8, and 12. Upon each visit, patients undergo physical examination, and trichoscale examination. The trichoscale examination is performed at the same designated points, in both right and left frontal regions. This examination is conducted using the FotoFinder® Medicam HD 800 device, which is equipped with TrichoScan® software (Fotofinder Systems GmbH, Germany). This examination will give measures of hair density, hair diameter, percentage of terminal and vellus hairs.

Statistical measures

All subjects completed the study. Intention-to-treat analysis was conducted on the data using SPSS® version 20. Characteristics with categorical data are presented in the form of frequency and percentage. The results of the examination of terminal and vellus hair percentages will be presented as descriptive data in percentage form. Numeric data were analyzed for normality using the Kolmogorov-Smirnov test. The comparison of mean hair density and hair diameter between the two study groups was analyzed using unpaired T-tests. If the data were not normally distributed, an alternative test, the Mann-Whitney test, was used. The significance level used in this study is set at alpha equal to 5%.

Results

Sociodemographic characteristics

All subjects were males aged between 26-51 years old. The overall mean age of the subjects was 34 (6.75) years. The difference mean age between the two groups was statistically significant. A total of 91.7% of the subjects had a family history of AGA. In the control group, there was one subject with a history of hypertension and one subject with a history of dyspepsia. None of the subjects were regularly taking medication. Approximately 47.2% of the subjects were smokers. The characteristics of the study participants are shown in Table 1.

Table 1. Sociodemographic characteristics of the intervention and control group.

Characteristics	Microneedling + topical 5% minoxidil (n=18)	Topical 5% minoxidil (n=18)	p
Age (year) ^a	37.6±7.14	33.3±4.14	0.019*
Family history of AGA; n (%)			
Yes	17 (94.4)	16 (88.9)	0.546 [†]
No	1 (5.6)	2 (11.1)	
Past medical history			
None	18 (100)	16 (88.9)	0.486**
Dyspepsia	0	1 (5.6)	
Hypertension	0	1 (5.6)	
Medication history			
Yes	0	0	1**
No	18 (100)	18 (100)	
Smoking history			
Yes	8 (44.4)	9 (50)	1**
No	10 (55.6)	9 (50)	

^aData presented as mean and standard deviation; *Independent t-test; **Fischer's test; [†]Chi-square test.

Clinical characteristics

The mean duration of AGA overall was 66 (80.5) months, or approximately 5.5 years. Most of the subjects had AGA severity of III (41.6%), followed by III vertex (19.4%), IV (16.7%), VI (13.8%), and V (8.3%). The mean hair density varied from 70.3 ± 24.1 to 96.8 ± 18.9 hair/cm², whereas the mean diameter was 30.2 ± 3 μ m. Hair pull test was negative in all subjects.

Changes in hair density

The comparison of the differences in hair density at each visit

compared to baseline between the intervention and control groups is presented in Figure 1a. Hair density appeared to increase in both groups at each follow-up. After 12 weeks, the mean hair density in the intervention group was 175.8 (47.43) hairs/cm², while in the control group was 156.3 (28.8) hairs/cm². The mean increase of hair density in the intervention group was 95.6 (40.6) hairs/cm² whereas 52.4 (34.2) hairs/cm² in the control group. The difference in mean hair density between the two groups was statistically significant ($p < 0.001$). Clinical comparison at each visit is presented in Figures 2 and 3.

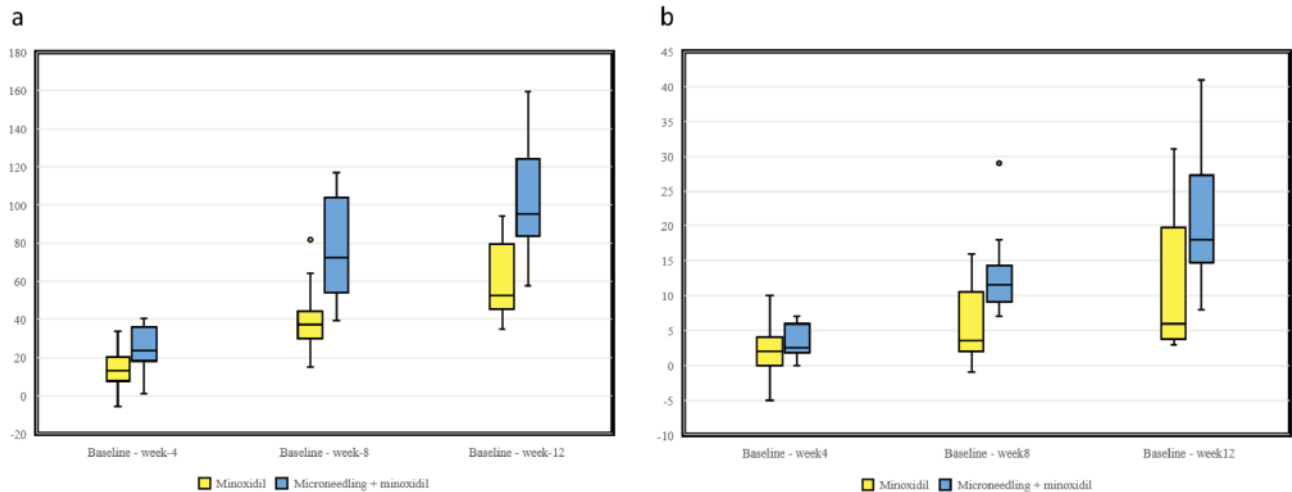


Figure 1. Comparison of the mean difference at each visit between the two groups. **a)** Mean difference in hair density at each visit between the two groups; **b)** mean difference in hair diameter at each visit between the two groups.

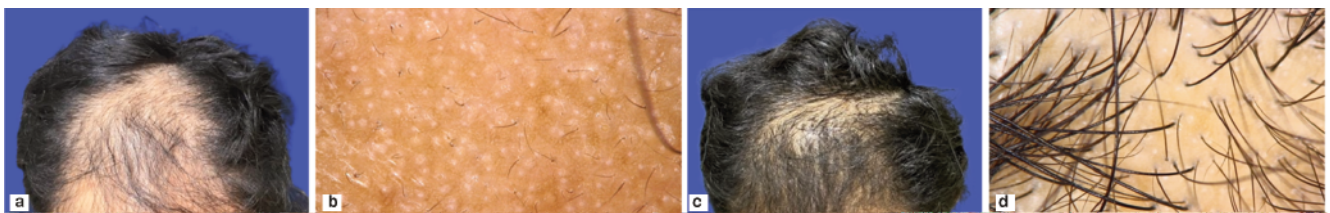


Figure 2. Clinical comparison of combined therapy of micro-needling and minoxidil. **a)** Week 0; **b)** trichoscale at week 0; **c)** week 12; **d)** trichoscale at week 12.

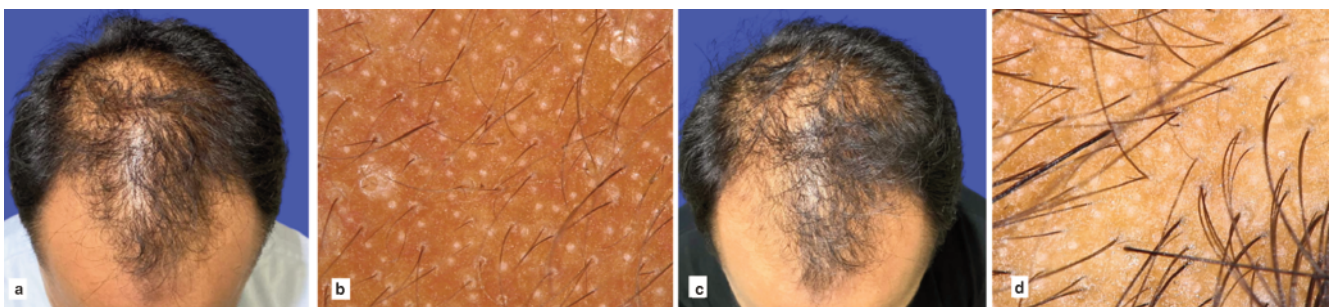

Figure 3. Clinical comparison of minoxidil therapy. **a)** Week 0; **b)** trichoscale at week 0; **c)** week 12; **d)** trichoscale at week 12.

Changes in hair diameter

The comparison of the differences in hair diameter at each visit compared to baseline between the intervention and control groups is presented in Figure 1b. After 12 weeks, there was a higher increase in hair diameter in the intervention group compared to the control group (18 μm vs 6 μm). The mean difference in hair diameter between the two groups was statistically significant at the end of the study ($p=0.004$).

Changes in terminal and vellus hair

After 12 weeks, the mean percentage of terminal hair in the intervention group became 73.2%, while in the control group, the median percentage of terminal hair became 58.8%. Meanwhile, the mean percentage of vellus hair in the intervention group became 26.8%, while in the control group, the median percentage of vellus hair became 41.1% (*data not shown*).

Side effects and adverse events assessment

Side effects and adverse events were assessed at weeks 4, 8, 12. Overall, 25% of the subjects experienced side effects, with six

subjects in the intervention group and three subjects in the control group. The most common reported side effect was itching (22.2%) after using minoxidil. Itching was mainly felt at the beginning of minoxidil use and did not interfere with daily activities. One subject in the intervention group reported transient erythema after the MN procedure. All side effects were well tolerated, and no subject withdrew from the study.

Characteristics of hair based on androgenetic alopecia grade

Subjects were divided into two groups based on AGA grade. The moderate AGA group included individuals with AGA of degree III, III vertex, and IV. The severe AGA group comprised individuals with AGA of degree V and VI. Baseline hair characteristics, categorized by the AGA degree group, are presented in Table 2. Hair density, hair diameter, and the percentage of terminal hair in the moderate AGA group were higher than those in the severe AGA group. Conversely, the percentage of vellus hair was higher in the severe AGA group compared to the moderate AGA group. Hair density at each visit based on AGA grade and overall

Table 2. Baseline hair characteristics based on androgenetic alopecia grade.

Characteristics	Grade III, III vertex and IV (n=28)	Grade V dan VI (n=8)
Hair density (hair/cm ²)	87.8±19.4	68.9±37.7
Hair diameter (μm)	30.5±2	29.2±2
Terminal hair rate (%)	13.2±7.5	11.3±5
Velus hair rate (%)	86.9±7.8	89.2±4.5

Data presented as mean and standard deviation.

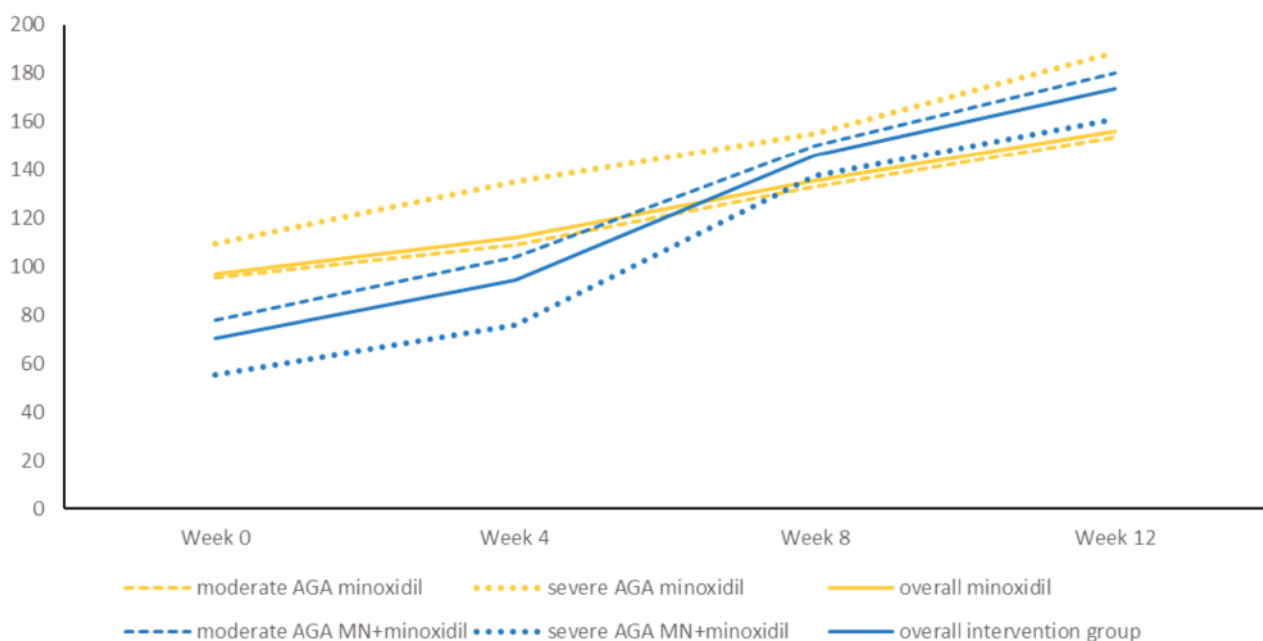


Figure 4. Hair density based on androgenetic alopecia grade and overall.

is presented in Figure 4. In all groups, an increase in hair density compared to baseline was observed. Furthermore, it is evident that there is an increased hair density observed in the intervention groups, both in moderate AGA and severe AGA group, as compared to the control group.

Discussion

The age of the study participants ranged from 26 to 51 years, with a mean age of 34 years. Approximately 50-60% of men experience AGA around the age of 50, increasing to 80% at around 70 years old.¹ In RSCM within the years 2017-2019, the mean age of AGA patients was 29.45 years.⁴ Therefore, the mean age of patients in this study is consistent with AGA research in Indonesia. In this study, the difference mean age between the two groups was statistically significant. Subjects in the control group were younger (33.3±4.14 years old) compared to the intervention group (37.6±7.14 years old). Early intervention may affect treatment outcomes.² About 91.7% of the study participants had a family history of AGA. Data from RSCM shows that 50% of patients have a family history of AGA.⁴ A study in China reported that 55.8% of male AGA patients had a family history of AGA,¹¹ while a study in India reported 87% of AGA patients had a family history.¹²

The baseline mean hair density in this study was 70.3-96.8 hairs/cm². Kumar *et al.* reported a baseline hair density for AGA of 80.37-82.35 hairs/cm²,¹³ while in the study by Sohng *et al.*, the initial hair density ranged from 97.64 to 105.44 hairs/cm².¹⁴ Thus, the baseline mean hair density in this study is similar to other AGA studies in Asia. The baseline mean hair diameter in this study was 30.2 µm. In the study by Bao *et al.*, the baseline hair diameter ranged from 64.4 to 65.3 µm,¹⁵ whereas Faghihi *et al.* reported an initial hair diameter of approximately 47.9-50.6 µm in AGA patients.¹⁶ Thus, the hair diameter in this study is smaller compared to other AGA management studies in Asia. Currently, there is no data available regarding the characteristics of hair density and diameter of AGA in Indonesia.

Both the control and intervention groups showed an increase in hair density over time. After 12 weeks, the mean difference in hair density compared to baseline in the control group was 52.4 hairs/cm², while in the intervention group, it was 103.4 hairs/cm². Despite the lower baseline hair density in the intervention group, the hair density exhibited a substantial increase compared to the control group at the end of the study. There was a significant difference in the mean difference in hair density between the two groups ($p < 0.001$). Significant differences were observed from week 4 onwards. This indicates that the combination therapy of MN and 5% minoxidil is more effective in increasing hair density compared to the control therapy.

The results of studies on the effectiveness of combination therapy with MN and minoxidil 5% vary. The study by Faghihi *et al.* compared the two different depths of MN, a group with 0.6 mm and the other one with 1.2 mm depth.¹⁶ After 12 weeks, the group with the depth of 0.6 mm tended to be more effective than that of 1.2 mm. A shorter depth may induce minimal trauma to the hair bulge compared to a longer depth of microneedle. The type of MN device and needle depth are believed to affect treatment effectiveness.

In this study, the mean hair diameter in both groups increased over time. There was a significant difference in the mean difference in hair diameter between the two groups ($p = 0.004$). The significant difference was observed from week 8 onwards. This study

suggests that the combination therapy of MN and minoxidil 5% is more effective in increasing hair diameter than single therapy with minoxidil 5%. Studies on MN therapy in AGA that assess hair diameter are limited. The study by Faghihi *et al.* reported a significant difference increase of hair diameter in the combination therapy group of 0.6 mm dermapen and minoxidil 5% compared to the control group after 12 weeks ($p = 0.007$).¹⁶ Bao *et al.* compared the effectiveness of AGA therapy in three different groups: minoxidil 5%, MN (depth 1-2 mm), and combination therapy of MN and minoxidil 5%.¹⁷ After 24 weeks, there was no significant difference between the intervention and control group.

Both the control and intervention groups showed a significant increase in the percentage of terminal hair and a decrease in vellus hair compared to baseline. A similar finding was observed in the study by Bao *et al.*, where terminal hair density increased compared to baseline at the end of the study.¹⁷ In AGA, pigmented terminal hair is transformed into non-pigmented vellus hair through the process of follicle miniaturization and repeated shortening of the anagen phase.¹⁸ Therefore, the percentage of vellus hair in AGA is higher than in the normal population. The percentage of vellus hair in the normal population is usually less than 10%, while the percentage of terminal hair ranges from 70% to 90%.¹⁹ The decrease in the percentage of vellus hair and the increase in the percentage of terminal hair indicate improvement of the clinical condition.

In this study, side effects such as itching and transient erythema were reported. The majority reported side effects were itching (8 participants). Complaints of itching were also reported in the studies by Sohng *et al.* and Bao *et al.*^{14,17} One participant experienced transient erythema after the MN procedure. Side effects of MN procedures are rarely found and are usually temporary. Erythema and irritation are the most common reported post-procedure side effects. Other side effects of MN procedures that have been reported include post-inflammatory hyperpigmentation, exacerbation of acne, reactivation of herpes, and local infections.²⁰⁻²² These side effects in this study were tolerable and transient for the participants, allowing all participants to continue the study until the end. The side effects between those two groups did not differ significantly. Thus, MN can be considered a safe adjuvant therapy with minimal side effects.

The mean hair density was found to be lower in patients with more severe grades (grades V and VI) in the initial study data. The increase in hair density was better observed in the intervention group, both in the moderate or severe AGA group. In the study by Bao *et al.*, inclusion criteria included AGA patients with Hamilton Norwood grades III-VI.¹⁷ After 24 weeks, overall hair density was found to increase more in the combination therapy group of MN and minoxidil 5%. Therefore, MN procedures can also be an adjuvant therapy option for AGA patients with more severe grades.

Conclusions

The increase in hair density in participants who received the combination therapy of MN and topical 5% minoxidil was higher compared to 5% minoxidil alone after 12 weeks. Similarly, the increase in hair diameter was higher in the intervention group. Conducting the procedure every 4 weeks increase the compliance of the subjects. Minimal side effects were also observed. The procedure MN with 0.6 mm depth and 4 weeks interval can be greatly considered as an effective and safe adjuvant therapy of AGA.

References

1. Blume-Peytavi U, Kanti V. Androgenetic alopecia. In: Kang S, Amagai M, Bruckner AL, Enk AH, Margolis DJ, McMichael AJ, et al., editors. *Fitzpatrick's dermatology*. 9th edition. New York: McGraw-Hill Company; 2019. p. 1495-506.
2. He F, Shen M, Zhao Z, et al. Epidemiology and disease burden of androgenetic alopecia in college freshmen in China: a population-based study. *PLoS One* 2022;17:e0263912.
3. Wang TL, Zhou C, Shen YW, et al. Prevalence of androgenetic alopecia in China: a community-based study in six cities. *Br J Dermatol* 2010;162:843-7.
4. Legiawati L, Suseno LS, Sitohang IBS, Pratama AI. Hair disorder in dr. Cipto Mangunkusumo cosmetic dermatology and venereology outpatient clinic of Jakarta, Indonesia: a socio-demographic and clinical evaluation. *Dermatol Rep* 2022;14:9341.
5. Lee WS, Lee HJ. Characteristics of androgenetic alopecia in asian. *Ann Dermatol* 2012;24:243-52.
6. Lolli F, Pallotti F, Rossi A, et al. Androgenetic alopecia: a review. *Endocrine* 2017;57:9-17.
7. Nasution K, Pradigo R, Chandra R. The type of androgenetic alopecia and quality of life (QoL) in male patients. *J Med Sci* 2022;54:40-50.
8. Yamazaki M, Miyakura T, Uchiyama M, et al. Oral finasteride improved the quality of life of androgenetic alopecia patients. *J Dermatol* 2011;38:773-7.
9. Kelly Y, Blanco A, Tosti A. Androgenetic alopecia: an update of treatment options. *Drugs* 2016;76:1349-64.
10. Ocampo-Garza SS, Fabbrocini G, Ocampo-Candiani J, et al. Micro needling: a novel therapeutic approach for androgenetic alopecia, a review of literature. *Dermatol Ther* 2020;33:e14267.
11. Xu F, Sheng YY, Mu ZL, et al. Prevalence and types of androgenetic alopecia in Shanghai, China: a community-based study. *Br J Dermatol* 2009;160:629-32.
12. Sehgal VN, Kak R, Aggarwal A, et al. Male pattern androgenetic alopecia in an Indian context: a perspective study. *J Eur Acad Dermatol Venereol* 2007;21:473-9.
13. Kumar MK, Inamadar AC, Palit A. A randomized controlled, single-observer blinded study to determine the efficacy of topical minoxidil plus microneedling versus topical minoxidil alone in the treatment of androgenetic alopecia. *J Cutan Aesthet Surg* 2018;11:211-6.
14. Sohng C, Lee EH, Woo SK, et al. Usefulness of home-use microneedle devices in the treatment of pattern hair loss. *J Cosmet Dermatol* 2021;20:591-6.
15. Bao L, Gong L, Guo M, et al. Randomized trial of electrodynamic microneedle combined with 5% minoxidil topical solution for the treatment of Chinese male androgenetic alopecia. *J Cosmet Laser Ther* 2020;22:1-7.
16. Faghihi G, Nabavinejad S, Mokhtari F, et al. Microneedling in androgenetic alopecia; comparing two different depths of microneedles. *J Cosmet Dermatol* 2021;20:1241-7.
17. Bao L, Zong H, Fang S, Zheng L, Li Y. Randomized trial of electrodynamic microneedling combined with 5% minoxidil topical solution for treating androgenetic alopecia in Chinese males and molecular mechanistic study of the involvement of the Wnt/beta-catenin signaling pathway. *J Dermatolog Treat* 2022;33:483-93.
18. Premanand A, Reena Rajkumari B. Androgen modulation of Wnt/beta-catenin signaling in androgenetic alopecia. *Arch Dermatol Res* 2018;310:391-9.
19. Rakowska A. Trichoscopy (hair and scalp videodermoscopy) in the healthy female. Method standardization and norms for measurable parameters. *J Dermatol Case Rep* 2009;3:14-9.
20. Cohen BE, Elbuluk N. Microneedling in skin of color: a review of uses and efficacy. *J Am Acad Dermatol* 2016;74:348-55.
21. Singh A, Yadav S. Microneedling: advances and widening horizons. *Indian Dermatol Online J* 2016;7:244-54.
22. Bonati LM, Epstein GK, Strugar TL. Microneedling in all skin types: a review. *J Drugs Dermatol* 2017;16:308-13.