



Acute Appendicitis Secondary to the Ingestion of a Toothpick

Marco Antonio Alves Braun¹, Isabella Alves Braun², Márcio Luís Duarte³,
 Bruno Fernandes Barros Brehme de Abreu⁴

¹Department of General Surgery, Centro Universitário São Camilo, São Paulo, SP, Brazil

²Department of Internal Medicine, Faculdade de Ciências Médicas da Santa Casa de São Paulo, São Paulo, SP, Brazil

³Department of Radiology, Universidade de Ribeirão Preto - Campus Guarujá, São Paulo, SP, Brazil

⁴Department of Radiology, WEBIMAGEM Telerradiologia, São Paulo, SP, Brazil

A 17-year-old female presented with a 3-day history of abdominal pain following physical exertion, which was subsequently localized to her right iliac region. She experienced severe pain in her right iliac region, exacerbated by coughing, sneezing, or any physical activity, accompanied by nausea and chills. With rest, the symptoms abated. She denied vomiting, reported regular bowel habits and urination, and had no previous surgeries or allergies.

A physical examination revealed a distended abdomen with normal bowel sounds and no rebound tenderness. Palpation elicited pain in the hypogastrium, right and left iliac regions. Although the Blumberg and Rovsing test results were negative, she displayed positive Lapinski, Psoas, Dunphy, and Obturator signs. Computed tomography (CT) revealed appendicitis with an associated foreign body (Figure 1).

Upon performing a videolaparoscopic appendectomy, a toothpick perforating the patient's appendix was detected (Figure 2). On the first postoperative day, she reported no complaints, and there were no signs of active bleeding from the surgical site. She was discharged subsequently and scheduled for outpatient follow-up.

Acute appendicitis secondary to foreign body ingestion is rare (0.0005-3% of all cases of acute appendicitis),¹ and there are no established guidelines for its management.² The accidental ingestion of foreign objects with food or intentional ingestion is more prevalent in children, adults with psychiatric disorders, alcoholics, prison populations, or individuals who are careless, eat hurriedly, have decreased visual acuity, or have dental implants.^{3,4}

Once inside the gastrointestinal tract, these objects typically do not cause adverse outcomes, with complications such as perforation, obstruction, hemorrhage, and fistula documented in < 1% of all cases.¹⁻⁵ Perforation occurs more frequently with pointed and sharp objects.^{3,4} Once the intestinal wall has been perforated, the foreign body can persist in the intestinal lumen near the damaged area, enter

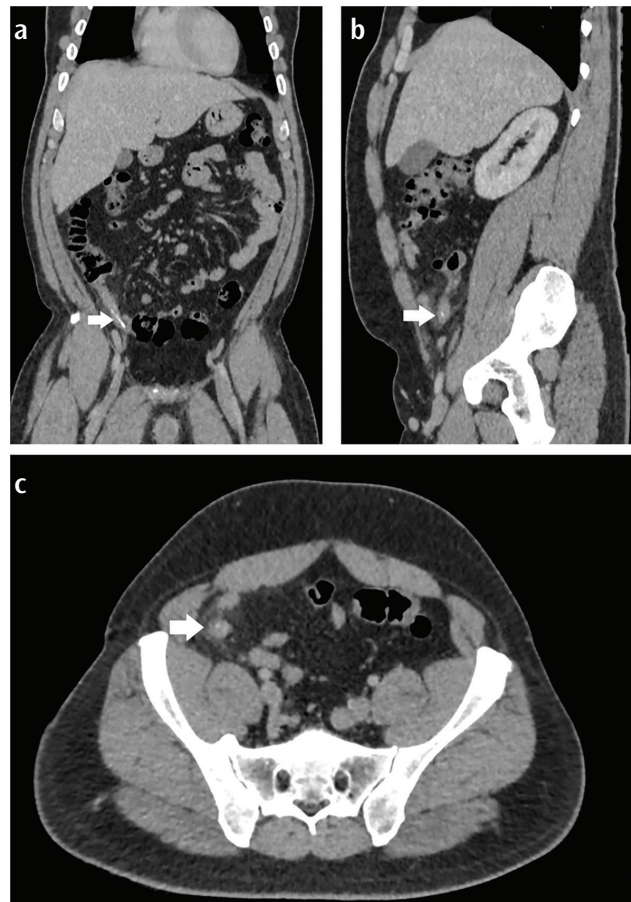

FIG. 1. Coronal (a), sagittal (b), and axial (c) computed tomography planes demonstrating a foreign body in the cecal appendix (white arrow).



Corresponding author: Márcio Luís Duarte, Department of Radiology, Universidade de Ribeirão Preto - Campus Guarujá, São Paulo, SP, Brazil

e-mail: marcioluisduarte@gmail.com

Received: May 08, 2024 **Accepted:** May 27, 2024 **Available Online Date:** October 31, 2024 • **DOI:** 10.4274/balkanmedj.galenos.2024.2024-5-34

Available at www.balkanmedicaljournal.org

ORCID iDs of the authors: M.A.A.B. 0000-0002-2469-7311; I.A.B. 0009-0003-0634-5253; M.L.D. 0000-0002-7874-9332; B.F.B.A. 0000-0003-4882-8299.

Cite this article as: Braun MAA, Braun IA, Duarte ML, de Abreu BFBB. Acute Appendicitis Secondary to the Ingestion of a Toothpick. *Balkan Med J.*; 2024; 41(6):505-6.

Copyright@Author(s) - Available online at <http://balkanmedicaljournal.org/>

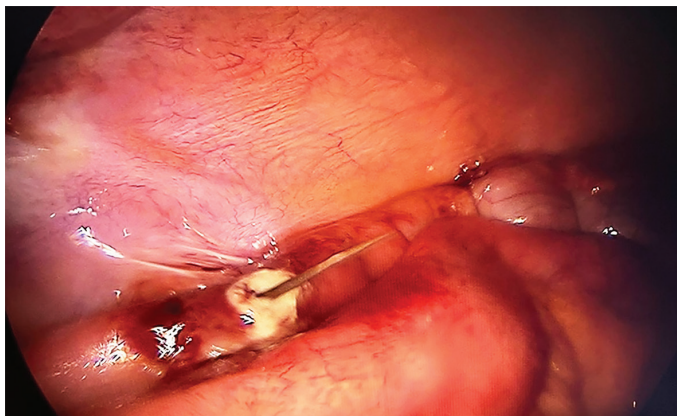


FIG. 2. Videolaparoscopy depicting cecal appendix perforated by a toothpick.

the peritoneal cavity, or even migrate distally, either perforating again or following the gastrointestinal tract's path without new lesions.⁵

When appendicitis is triggered by a foreign body, the onset of symptoms may vary from hours to years since the inflammatory process and the organism's reaction do not always commence immediately.¹ This timeframe is influenced by the size and shape of the object, as well as the position of the appendix.^{1,2} It is considered that the onset of symptoms may be accelerated by sharp or pointed foreign bodies.¹

X-ray, ultrasound, and CT are notable among the imaging methods employed,^{1,3} with CT being considered superior for diagnosing suspected cases.³ However, imaging modalities may not always detect an ingested foreign body.⁵ Only 14% of ingested toothpicks are detectable through imaging examinations.⁶ Toothpicks, being made of wood and thus radiolucent, are often not visible on plain radiographs or CT scans.⁵ However, toothpicks that have been ingested can appear hyperdense on CT scans, similar to the findings in our case.⁷ In a case series by Yang et al.,⁸ the rate of diagnostic accuracy of CT scans for wooden or bamboo toothpicks was determined to be 100%.

In patients developing appendicitis secondary to an ingested foreign body, surgery should be performed to remove the foreign body and treat any perforations if present.^{1,2,5} Videolaparoscopy facilitates the removal of foreign bodies and enables a more thorough assessment of adjacent abdominal organs when exploring for injuries.⁴

Informed Consent: Informed consent was obtained from the patient described in this report.

Authorship Contributions: Concept- M.A.A.B., I.A.B., M.L.D., B.F.B.B.A.; Design- M.A.A.B., I.A.B., M.L.D., B.F.B.B.A.; Supervision- M.A.A.B., I.A.B., M.L.D., B.F.B.B.A.; Fundings- M.A.A.B., I.A.B., M.L.D., B.F.B.B.A.; Materials- M.A.A.B., I.A.B., M.L.D., B.F.B.B.A.; Data Collection and/or Processing- M.A.A.B., I.A.B., M.L.D., B.F.B.B.A.; Analysis and/or Interpretation- M.A.A.B., I.A.B., M.L.D., B.F.B.B.A.; Literature Search- M.A.A.B., I.A.B., M.L.D., B.F.B.B.A.; Writing- M.A.A.B., I.A.B., M.L.D., B.F.B.B.A.; Critical Review- M.A.A.B., I.A.B., M.L.D., B.F.B.B.A.

Conflict of Interest: No conflict of interest was declared by the authors.

REFERENCES

1. Elmansi Abdalla HE, Nour HM, Qasim M, Magsi AM, Sajid MS. Appendiceal foreign bodies in adults: a systematic review of case reports. *Cureus*. 2023;15:e40133. [\[CrossRef\]](#)
2. Grassi V, Desiderio J, Cacurri A, et al. A rare case of perforation of the subhepatic appendix by a toothpick in a patient with intestinal malrotation: laparoscopic approach. *G Chir*. 2016;37:158-161. [\[CrossRef\]](#)
3. Lloyd AJ, Abd Elwahab SM, Boland MR, Elfadul A, Hill ADK, Power C. Acute complicated appendicitis caused by an ingested toothpick - A case report. *Int J Surg Case Rep*. 2022;92:106872. [\[CrossRef\]](#)
4. Pogorelić Z, Čohadžić T. A Bizarre Cause of Acute Appendicitis in a Pediatric Patient: An Ingested Tooth. *Children (Basel)*. 2023;10:108. [\[CrossRef\]](#)
5. Aguilar Ayala BE, Cazares Cadena BR, Molina GA, Constante Ruiz JE, Salazar Parada JF, Solórzano García OJ. Cecum and appendix perforation due to inadvertent ingestion of two toothpicks. *J Surg Case Rep*. 2019;2019:rjz106. [\[CrossRef\]](#)
6. Di Migueli R, De La Roca R, Korkes F. Mysterious ureteral migration of a wooden toothpick from the digestive tract: case report and diagnostic considerations. *Einstein (Sao Paulo)*. 2022;20:eRC5743. [\[CrossRef\]](#)
7. Reginelli A, Liguori P, Perrotta V, Annunziata G, Pinto A. Computed Tomographic Detection of Toothpick Perforation of the Jejunum: Case Report and Review of the Literature. *Radiol Case Rep*. 2016;2:17-21. [\[CrossRef\]](#)
8. Yang Z, Wu D, Xiong D, Li Y. Gastrointestinal perforation secondary to accidental ingestion of toothpicks: A series case report. *Medicine (Baltimore)*. 2017;96:e9066. [\[CrossRef\]](#)