

Spontaneous umbilical cord entwinement in 1-day-old kittens

Aida Glavinić , Nermina Spahija, Soraja Kučlar Muftić, Amila Šunje-Rizvan , Benjamin Čengić, Tarik Mutevelić and Alan Maksimović

Journal of Feline Medicine and Surgery Open Reports
1–4

© The Author(s) 2024

Article reuse guidelines:

sagepub.com/journals-permissions

DOI: 10.1177/20551169241289407

journals.sagepub.com/home/jfmsopenreports

This paper was handled and processed by the European Editorial Office (ISFM) for publication in *JFMS Open Reports*



Abstract

Case summary A 1-year-old domestic shorthair queen with five neonates was referred for umbilical cord entwinement in three kittens 24h after parturition. The owner noticed the kittens were stuck to each other 3h before admission. Despite a conservative treatment approach, prolonged ischaemia led to dry gangrenous changes in one of the kitten's metatarsi.

Relevance and novel information This and other neonatal complications in cats are rarely reported. Primiparity is a known factor contributing to postpartum complications. Furthermore, inexperienced owners require more assistance in mitigating these challenges. Therefore, further research and collaboration among breeders, owners and veterinary professionals are imperative in order to accurately determine the prevalence of this condition in kittens and develop effective strategies to address it.

Keywords: Domestic shorthair; ischaemia; neonatal complications; umbilicus

Accepted: 19 September 2024

Introduction

Parturition problems occur infrequently in cats, and most queens deliver kittens without the need for assistance.¹ The frequency of dystocia is 3–6%, with an increasing tendency in bred cats due to selective breeding.² The neonatal period in cats poses a significant challenge for veterinarians and breeders owing to its high morbidity and mortality rates, which is typically in the range of 14–16%.³ It is estimated that 91% of deaths occur in the first 3 days after parturition.⁴ Identified risk factors for kitten mortality, in research and breeding colonies, were increased litter size, low birth weight and breed.^{4–6} Differences in mortality between birth and weaning differed between breeds in breeding colonies, being lowest in Norwegian Forest Cats (6%) and highest in Persian cats (20%).⁵ Information on mortality of rescue and shelter kittens is limited.⁶

Veterinarians, breeders and owners must be aware of normal physiological behaviour and conduct daily monitoring in order to assist newborns when necessary.^{3,7,8} Cat breeders typically possess substantial expertise in these domains of feline reproduction, unlike inexperienced owners.⁹ Thus, it is essential for veterinarians to

have the most up-to-date knowledge about maternal, prenatal and neonatal care of this species, enabling them to facilitate neonatal care by instructing everyone involved.³ During delivery, the queen typically engages in behaviours such as biting through the amniotic membrane and the umbilical cord, while simultaneously licking the kittens to stimulate respiration. This may not be the case with primiparous queens or during rapid deliveries.⁹ As a result, kittens may asphyxiate inside the intact amniotic sac or become entwined in their umbilical cords, potentially leading to significant injury of the distal limbs, thus affecting their quality of life.⁹ This emphasises the importance of timely and accurate recognition of potential complications during the neonatal period by owners, breeders and veterinarians.

Department of Clinical Sciences in Veterinary Medicine, University of Sarajevo, Veterinary Faculty, Sarajevo, Bosnia and Herzegovina

Corresponding author:

Aida Glavinić DVM, Department of Clinical Sciences in Veterinary Medicine, University of Sarajevo, Veterinary Faculty, Zmaja od Bosne 90, Sarajevo, Bosnia and Herzegovina
Email: aida.glavinic@vfs.unsa.ba



Creative Commons Non Commercial CC BY-NC: This article is distributed under the terms of the Creative Commons

Attribution-NonCommercial 4.0 License (<https://creativecommons.org/licenses/by-nc/4.0/>) which permits non-commercial use, reproduction and distribution of the work without further permission provided the original work is attributed as specified on the SAGE and Open Access pages (<https://us.sagepub.com/en-us/nam/open-access-at-sage>).

This case report describes a spontaneous entwinement of umbilical cords in 1-day-old kittens delivered by a primiparous queen.

Case description

A 1-year-old primiparous domestic shorthair (DSH) queen with five neonates was referred to the Clinic of Surgery, Anesthesia and Resuscitation of the University of Sarajevo – Veterinary Faculty 24h after parturition. The queen initially delivered six kittens. One of the kittens was found dead inside the amniotic sac. Otherwise, the parturition went undisturbed. According to the owner's statements, the queen cut the umbilical cords and detached the placenta without assistance. Three hours before admission, the owner noticed that three of the kittens were stuck to each other. Furthermore, the kittens were vocalising atypically. The owner did not interfere owing to a lack of experience and knowledge, as well as a cultural belief that the queen would not accept kittens back after manipulation if human scent was present on their fur. According to the owner, the queen was an indoor/outdoor cat. During examination, the cat was responsive, with normal clinical parameters and a body condition score of 4/9. The owner declined a more detailed clinical examination due to financial constraints. The neonates exhibited atypical behaviour and discomfort, accompanied by an abnormal positioning. Inspection of the umbilical cords revealed that the cords of three kittens were intertwined, with the metatarsus of one kitten caught inside the umbilical knot (Figure 1). The spontaneous entwinement led to difficulty in feeding and movement for the neonates, resulting in ischaemia-induced tissue damage.

Immediate sharp resection of the formed umbilical knot was performed. Two kittens had unremarkable clinical signs afterwards. The third kitten's right metatarsus had a deep circular soft tissue depression due to prolonged ischaemia. The left metatarsus was swollen due to contusions (Figure 2). The entwined leftover dried umbilical cord was approximately 3cm long.

After resection of the umbilical entwinement, conservative treatment involved daily massages and the administration of an alternating hot/cold compress for 7 days. The conservative treatment approach was chosen due to the patient's age. The owner was advised to monitor the kitten's behaviour and appetite. Four days later, the kitten exhibited signs of necrosis of the right metatarsus and was presented with dry gangrene (Figure 3). Seven days after the initial examination, the gangrenous tissue detached, leaving unremarkable skin over the right tarsal joint. Sloughing due to bacterial infection was ruled out based on the patient's overall health status. At the last follow-up examination 6 months later, the kitten was leading an active and normal life.

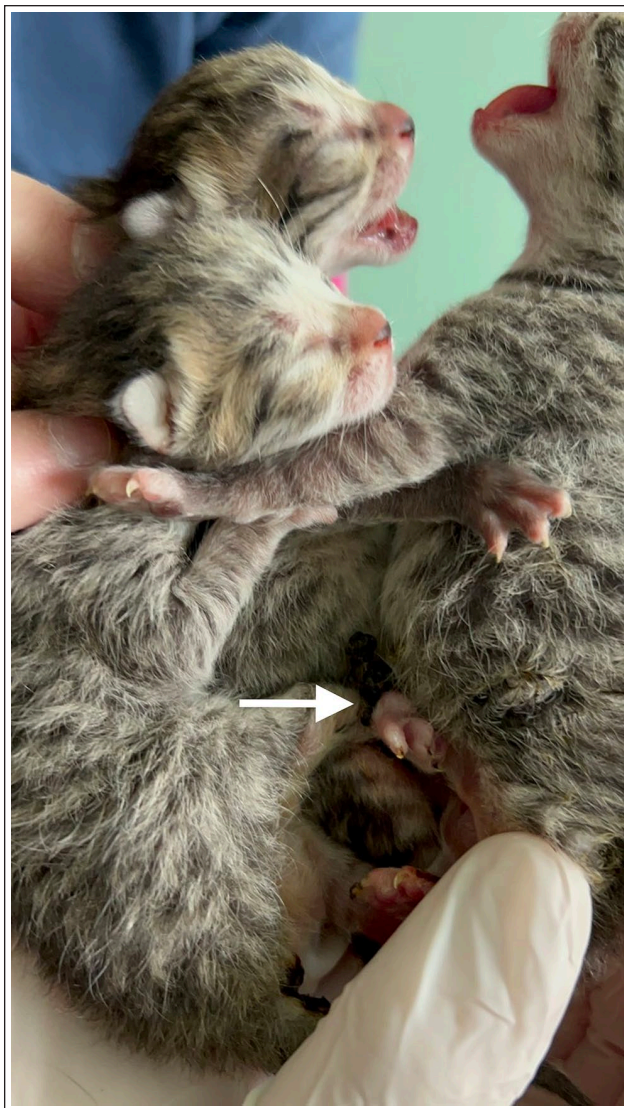

Figure 1 The cords of three kitten entwined with the metatarsus of one kitten (white arrow)

Discussion

Neonatal umbilical cord complications in veterinary medicine are predominantly reported in farm animals.¹⁰ To our knowledge, there has only been one case report published in kittens.¹ Nevertheless, it is considered a condition that can lead to serious consequences if not promptly addressed.⁹

Primiparity in the queen, as observed in our case, is a known factor contributing to umbilical cord entwinement. This is because primiparous queens exhibit different behaviours compared with experienced mothers, potentially posing a risk for this condition.^{11–13} Umbilical cord entwinement can result from increased neonatal activity and variations in cord length. The movement of neonates can lead to twisting, while longer cords increase the risk of entwinement.^{2,11,12} Furthermore, the

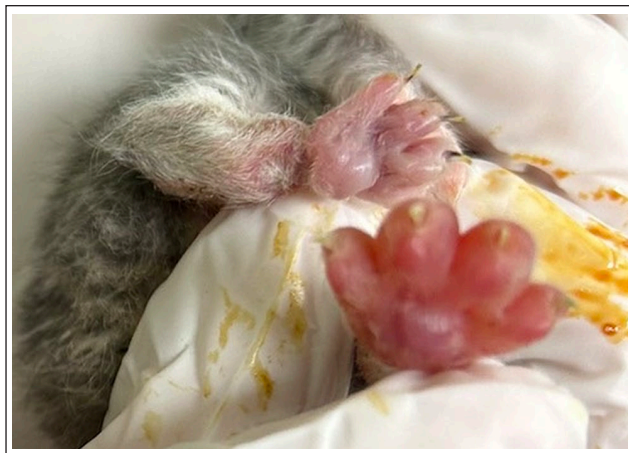

Figure 2 Circular soft tissue depression in the right metatarsus. Marked swelling of the left metatarsus

queen's inexperience, stress and additional factors, such as the owner's lack of experience, might exacerbate the condition.

Management of umbilical cord entwinement requires a tailored approach based on the severity of the condition and its associated complications. In mild cases, manual manipulation to untangle the cord and supportive care may be sufficient. However, severe entwinement with evidence of compromised tissue, such as in this case, may necessitate medical intervention to restore blood flow and prevent limb damage. This condition can have long-term consequences or be life-threatening, underscoring the importance of prompt recognition for optimal outcomes.¹⁴

In this case, conservative management, involving multiple daily massages and hot/cold compresses, was selected as the most appropriate. Drug therapy was avoided owing to concerns about the kitten's immature metabolic and excretory systems, dynamically modulated blood–brain barrier¹⁵ and sensitive gastrointestinal tract.¹⁶ The literature suggests a lack of specific clinical data on drug safety and efficacy in neonatal kittens.¹⁷ Considering human reports that opioids, such as buprenorphine, are appropriate for pain management in neonates,¹⁸ yet there is a lack of reciprocal studies in kittens, we chose not to use any analgesic drugs.

Conclusions

Umbilical cord entwinement in neonatal kittens, although rare, is clinically significant and can lead to complications. Timely observation can help resolve these complications. Through enhanced awareness, early detection and prompt intervention, veterinarians can mitigate the impacts of this condition. Further research and collaboration among

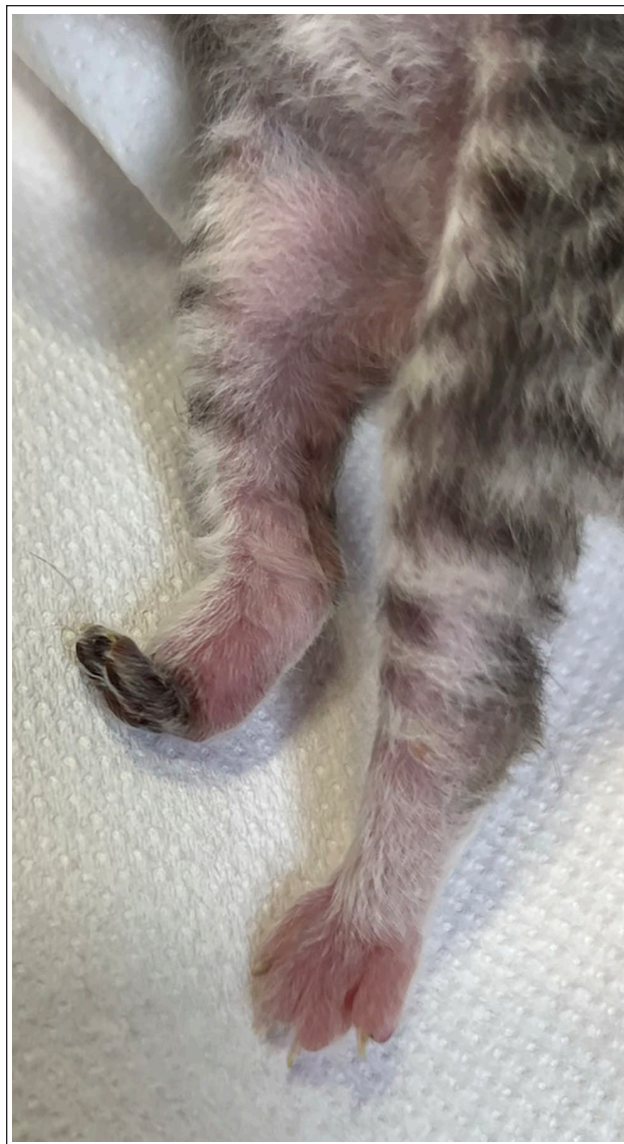

Figure 3 Dry gangrene 4 days after initial presentation

breeders, owners and veterinary professionals are crucial to accurately determine the frequency of this condition in kittens and effectively address it.

Conflict of interest The authors declared no potential conflicts of interest with respect to the research, authorship, and/or publication of this article.

Funding The authors received no financial support for the research, authorship, and/or publication of this article.


Ethical approval The work described in this manuscript involved the use of non-experimental (owned or unowned) animals. Established internationally recognised high standards ('best practice') of veterinary clinical care for the individual patient were always followed and/or this work involved the

use of cadavers. Ethical approval from a committee was therefore not specifically required for publication in *JFMS Open Reports*. Although not required, where ethical approval was still obtained, it is stated in the manuscript.

Informed consent Informed consent (verbal or written) was obtained from the owner or legal custodian of all animal(s) described in this work (experimental or non-experimental animals, including cadavers, tissues and samples) for all procedure(s) undertaken (prospective or retrospective studies). For any animals or people individually identifiable within this publication, informed consent (verbal or written) for their use in the publication was obtained from the people involved.

ORCID iD Aida Glavinić  <https://orcid.org/0000-0001-8661-7180>

Amila Šunje-Rizvan  <https://orcid.org/0000-0002-6141-5723>

Alan Maksimović  <https://orcid.org/0000-0002-4127-9445>

References

- Azari O and Akhtardanesh B. **A clinical report of entangled neonates' umbilical cord with queen's fur in Persian cat.** *Asian Pac J Trop Biomed* 2011; 1: 502–504.
- England G and von Heimendahl A. **Manual of canine and feline reproduction and neonatology.** 2nd ed. Gloucester: BSAVA, 2010.
- Pereira KHNP, Fuchs K da M, Corrêa JV, et al. **Neonatology: topics on puppies and kittens neonatal management to improve neonatal outcome.** *Animals (Basel)* 2022; 12. DOI: 10.3390/ani12233426.
- Lawler DF and Monti KL. **Morbidity and mortality in neonatal kittens.** *Am J Vet Res* 1984; 45: 1455–1459.
- Romagnoli S, Bensaia C, Ferré-Dolcet L, et al. **Fertility parameters and reproductive management of Norwegian Forest Cats, Maine Coon, Persian and Bengal cats raised in Italy: a questionnaire-based study.** *J Feline Med Surg* 2019; 21: 1188–1197.
- Dolan ED, Doyle E, Tran HR, et al. **Pre-mortem risk factors for mortality in kittens less than 8 weeks old at a dedicated kitten nursery.** *J Feline Med Surg* 2021; 23: 730–737.
- Hibaru VY, Pereira KHNP, Fuchs K, da M, et al. **Topics in the routine assessment of newborn kitten vitality: Apgar score, reflexes and complementary assessments.** *J Feline Med Surg* 2022; 24: e34–e42.
- Lawler DF. **Neonatal and pediatric care of the puppy and kitten.** *Theriogenology* 2008; 70: 384–392.
- Little SE. **Female reproduction.** In: Little SE (ed). *The cat: clinical medicine and management.* St Louis, MO: Elsevier Saunders, 2011, pp 1195–1227.
- Zachary JF. *Pathologic basis of veterinary disease.* 7th ed. St Louis, MO: Mosby Elsevier, 2022.
- Kustritz MVR. **Reproductive behavior of small animals.** *Theriogenology* 2005; 64: 734–746.
- Kustritz MVR. *Clinical canine and feline reproduction: evidence-based answers.* Ames, IA: Wiley-Blackwell, 2010.
- Lyons LA. **Feline genetics: clinical applications and genetic testing.** *Top Companion Anim Med* 2010; 25: 203–212.
- O'Neill DG, Church DB, McGreevy PD, et al. **Longevity and mortality of cats attending primary care veterinary practices in England.** *J Feline Med Surg* 2015; 17: 125–133.
- Schmitt G, Parrott N, Prinssen E, et al. **The great barrier belief: the blood–brain barrier and considerations for juvenile toxicity studies.** *Reprod Toxicol* 2017; 72: 129–135.
- Morreale C, Giaroni C, Baj A, et al. **Effects of perinatal antibiotic exposure and neonatal gut microbiota.** *Antibiotics* 2023; 12. DOI: 10.3390/antibiotics12020258.
- Seguin MA, Papich MG, Sigle KJ, et al. **Pharmacokinetics of enrofloxacin in neonatal kittens.** *Am J Vet Res* 2004; 65: 350–356.
- Lindemalm S, Nydert P, Svensson JO, et al. **Transfer of buprenorphine into breast milk and calculation of infant drug dose.** *J Hum Lac* 2009; 25: 199–205.