

## Role of joint receptors in modulation of inspiratory intercostal activity by rib motion in dogs

André De Troyer

*Laboratory of Cardiorespiratory Physiology, Brussels School of Medicine  
and the \*Chest Service, Erasme University Hospital, 1070 Brussels, Belgium*

1. Inspiratory activity in the canine external intercostal muscles is exquisitely sensitive to the direction and amplitude of the inspiratory displacement of the ribs. This study was designed to investigate the role of muscle receptors, in particular the muscle spindles, in mediating this phenomenon.
2. External intercostal inspiratory activity showed a reflex increase when the normal cranial motion of the ribs and the normal shortening of the muscles was reduced, and showed a reflex decrease when the cranial motion of the ribs and the shortening of the muscles was augmented. However, clamping the two ribs making up the interspace and maintaining muscle length constant only moderately attenuated these responses.
3. These persistent responses remained unchanged after section of the levator costae muscles.
4. The responses were attenuated but still present after section of the external intercostals in the contiguous segments and denervation of the internal intercostals.
5. These reflex responses are therefore mediated in part by non-muscular receptors, which most likely lie within the costovertebral joints. These joint receptors might be a primary determinant of the load-compensating reflex.

It is well known that alterations in inspiratory airflow resistance alter the magnitude of motor discharges to the inspiratory intercostal muscles. Specifically, when airflow resistance is suddenly increased in anaesthetized cats (Corda, Eklund & von Euler, 1965; Shannon & Zechman, 1972), rabbits (Sant'Ambrogio & Widdicombe, 1965) and dogs (De Troyer, 1991, 1992), or when the airway is occluded at end-expiration for a single breath, the external intercostal and levator costae muscles in the rostral portion of the ribcage show a reflex increase in inspiratory activity. This response disappears after sectioning of the thoracic dorsal roots (Sant'Ambrogio & Widdicombe, 1965; Shannon & Zechman, 1972; De Troyer, 1991), thus indicating that it results from a spinal mechanism, and several observations have led to the traditional belief that it is, in fact, an expression of the stretch reflex. Firstly, the external intercostal and levator costae muscles are abundantly supplied with muscle spindles (Duron, Jung-Caillol & Marlot, 1978; Hilaire, Nicholls & Sears, 1983). By contrast, the internal intercostal muscles of the parasternal area (the so-called parasternal intercostals), which contain few muscle spindles, do not show any increased inspiratory activity in response to an increase in inspiratory airflow resistance or a single-breath airway occlusion (De Troyer, 1991, 1992). Secondly, electrical recordings from intercostal nerves in cats have

established that the fusimotor neurones innervating the external intercostal muscle spindles, and the corresponding  $\alpha$ -motoneurones, receive similar descending signals from the respiratory neurones in the medulla (Sears, 1963, 1964a). During spontaneous inspiration, the external intercostal  $\alpha$ -motoneurones are thus subjected to a periodic depolarization caused by the summation of direct central respiratory drive potentials and spindle afferent discharges (through the  $\gamma$ -loop), and hence any misalignment between the rate of intrafusal and extrafusal muscle shortening, due to a sudden increase in inspiratory mechanical load, can induce an increase in spindle afferent activity and an augmentation in  $\alpha$ -motoneurone efferent activity. Finally, measurements of the respiratory changes in muscle length in dogs have established that with step increases in inspiratory airflow resistance, the external intercostal and levator costae muscles in the rostral interspaces show a true reduction in the amount of inspiratory shortening or even an inspiratory lengthening, rather than a simple decrease in the rate of shortening (De Troyer, 1992; Romaniuk, Supinski & Di Marco, 1992). Such changes in length should trigger muscle spindles, and indeed recordings from thoracic dorsal roots in cats have shown increased afferent discharges from intercostal muscle spindles during airway occlusion (Critchlow & von Euler, 1963; Corda *et al.* 1965).

\* Address to which correspondence should be sent.

Alterations in inspiratory rib displacement in dogs also elicit reflex alterations in external intercostal and levator costae inspiratory activity without inducing any changes in parasternal intercostal activity (De Troyer & Yuehua, 1994; De Troyer, 1996). Thus, when the normal inspiratory elevation of the ribs is reduced by external manipulation, external intercostal and levator costae activity is increased. Conversely, inspiratory activity decreases when the elevation of the ribs is manually augmented. Since these alterations in inspiratory rib elevation modify the inspiratory shortening of the muscles, increasing it when elevation is augmented and decreasing or reversing it when elevation is reduced, we initially postulated that these reflex changes in external intercostal activity were also determined primarily by alterations in spindle afferent activity (De Troyer, 1996). However, the increased activity produced in a particular external intercostal muscle by a reduction in rib elevation was found to persist after the changes in length of the muscle were suppressed or reversed (De Troyer, 1996). The response to an augmented rib elevation was also maintained, thus indicating that the muscle's own spindles are not essential to these responses. In the present study, therefore, we have investigated the role played by the other intercostal muscles, in particular the levator costae and the external and internal intercostal muscles in the contiguous segments of the ribcage.

## METHODS

The experiments were performed on twenty adult mongrel dogs (15–24 kg) anaesthetized with pentobarbitone sodium (initial dose, 20–25 mg kg<sup>-1</sup> i.v.). The animals were placed in the supine posture, intubated with a cuffed endotracheal tube, and a catheter was inserted in a femoral artery to monitor blood pressure and sample arterial blood periodically for blood gas analysis. The ribcage and intercostal muscles between the first and the eighth rib were then exposed on the right side of the chest from the sternum to the costovertebral articulations. Satisfactory ribcage exposure was usually achieved by a ventrolateral approach. In six animals of the study, however, the ribcage had a more circular cross-section, so that a ventral approach did not provide good enough access to the dorsal aspect of the intercostal spaces. In these animals, therefore, the ribcage was also exposed via a mid-line incision of the skin dorsally and removal of the extensor muscles of the upper and middle thoracic region. The level of anaesthesia in each animal was regulated to abolish the response to nociceptive stimuli during surgery but to keep the corneal reflex present throughout the measurements. Rectal temperature was also maintained constant at  $37 \pm 1$  °C with infrared lamps.

The measurements and apparatus were essentially similar to those described in our previous communication (De Troyer, 1996). Airflow at the endotracheal tube was measured with a heated Fleisch pneumotachograph connected to a differential pressure transducer (Validyne, Northridge, CA, USA), and lung volume was obtained by electronic integration of the flow signal. Electromyographic (EMG) activity was recorded from the parasternal intercostal and external intercostal muscles in the third interspace with pairs of silver hook electrodes spaced 3–4 mm apart. Each pair was placed in parallel fibres. The parasternal intercostal

electrodes were implanted in the portion of the muscle close to the sternum, whereas the external intercostal electrodes were implanted midway between the angle of the rib dorsally and the costochondral junction ventrally. The two EMG signals were processed using amplifiers (CWE, model 830/1, Ardmore, PA, USA), bandpass filtered below 100 and above 2000 Hz, and rectified prior to their passage through leaky integrators with a time constant of 0.2 s. In addition, the craniocaudal (axial) displacement of the fourth rib was measured with a linear displacement transducer (Schaevitz Eng., Pennsauken, NJ, USA), and the changes in external intercostal muscle length were measured with a pair of piezoelectric crystals (2 mm diameter) implanted 6–12 mm apart in a well-identified muscle bundle and connected to a sonomicrometer (Triton Technology, San Diego, CA, USA). Detailed descriptions of these two techniques are given in previous reports (De Troyer & Kelly, 1982; Newman, Road, Bellemare, Clozel, Lavigne & Grassino, 1984; De Troyer, 1992). It is important to stress, however, that the piezoelectric crystals were placed within 10 mm of the EMG electrodes; electrical activity and changes in muscle length were therefore recorded from the same portion of the muscle.

The animal was allowed to recover for 30 min after instrumentation, after which measurements of lung volume, EMG activity, rib motion and muscle length were obtained. The animal was spontaneously breathing throughout. Every fifteen to twenty breaths, however, the normal inspiratory cranial displacement of the rib was manually altered for a single breath in the caudal or cranial direction, as previously described (De Troyer, 1996). At least thirty trials covering a wide range of rib motion were obtained in each animal. Three experimental protocols were then followed.

### Experiment 1

Eight animals were first studied to evaluate the role played by the levator costae muscle in causing the influence of rib motion on external intercostal EMG activity. After the baseline measurements were completed, two clamps were attached firmly to the third and fourth ribs; one clamp was placed in the ventral part of the interspace, 1–2 cm dorsal to the chondrocostal junction, and the other was placed in the dorsal part, 2–3 cm ventral to the rib angle. The two clamps were locked at the muscle resting length, after which manipulation of the rib during inspiration was repeated. As during the baseline evaluation, at least thirty trials covering a wide range of rib motion were performed. The levator costae muscle in the third interspace was then sectioned along its caudal insertions, and rib manipulation was performed again. At the end of the experiment, the animal was given a lethal overdose of anaesthetic (30–40 mg kg<sup>-1</sup> i.v.).

### Experiment 2

Eight animals were next studied to assess the role of the external intercostal muscles in the contiguous interspaces. The third and fourth ribs were locked as in Experiment (Expt) 1, and after the rib was manipulated, the external intercostal muscles situated in the rostral (interspaces 1 and 2) and caudal (interspaces 4–6) interspaces were sectioned midway between their rostral and caudal insertions from the costochondral junction to the angle of the rib. The levator costae muscles situated in interspaces 1–6 were also severed. A 30 min period was allowed to elapse for recovery, and manipulation of the rib during inspiration was repeated.

In three animals we also examined the role of the internal intercostal muscles. In each animal, the caudal border of the second, third and fourth ribs was cleared of periosteum over 1–2 cm at the rib angle, and a curved chisel-edged instrument was passed under the rib to separate the periosteum from the bone. The periosteum

was then incised, and the caudal end of the severed piece of periosteum was gripped and gently drawn caudally. The internal intercostal nerves in interspaces 2–4 could therefore be easily exposed and sectioned with minimal bleeding and without any damage to the external intercostal nerve in the third interspace. A final set of rib manipulation was then obtained.

Post-mortem examination of the ribcage confirmed that the external intercostal muscles in the rostral and caudal interspaces were sectioned entirely in each animal. The levator costae were also completely sectioned in the third to the sixth interspaces. Small portions of levator costae muscle tissue were left in place in the first two interspaces in three animals, but this was limited to a few bundles in the deepest muscle layer. Similarly, since in the dog the internal intercostal muscles in the rostral interspaces extend only a few millimetres dorsal to the rib angle and are extremely thin there, these muscles were essentially eliminated from the act of breathing by the denervation procedure.

### Experiment 3

Lastly, to examine further the role played by the external intercostal muscles in the contiguous interspaces, we studied in four animals the response of the external intercostal in the third interspace to separate manipulation of the third and fourth ribs. With the animal intact, inspiratory lengthening of the muscle was thus produced by alternately pulling the fourth rib in the caudal direction and the third rib in the cranial direction. Inspiratory muscle shortening was also produced by pulling the third rib caudally and the fourth rib cranially. At least thirty manipulated breaths were obtained with either rib. The external intercostal muscles situated in the rostral and caudal interspaces and the levator costae muscles were subsequently severed as in Expt 2, and the procedure was repeated.

### Data analysis

Data analysis was made in two stages, as previously described (De Troyer, 1996). First, phasic inspiratory EMG activity in the parasternal intercostal and external intercostal during the manipulated and non-manipulated ('control') breaths was quantified by measuring the peak height of the integrated signal in arbitrary units. To allow comparison between the different animals studied, the inspiratory EMG activity recorded during each manipulated breath was then expressed as a percentage of the activity recorded during the immediately preceding control breath. The inspiratory axial motion of the fourth rib in the corresponding breaths was measured relative to a known displacement of the core of the transducer and expressed in millimetres, and the inspiratory change in external intercostal muscle length was expressed as a percentage change relative to the muscle resting length ( $L_r$ ), as determined during hyperventilation-induced apnoea. By convention, negative changes in muscle length represent inspiratory muscle shortening below  $L_r$ , and negative rib displacements represent inspiratory caudal motion.

In the second stage, the effects of axial rib displacement on inspiratory EMG activity were quantified by using modified least-squares exponential regressions. Thus, in each animal in each condition, the relationship between axial rib motion and parasternal or external intercostal EMG activity was fitted by a regression equation of the type  $y = ae^{bx}$ , where  $y$  was the peak EMG activity and  $x$  was the axial rib motion, and from this equation we calculated the change in inspiratory EMG activity between a 5 mm decrease and a 5 mm increase in inspiratory cranial rib motion. Manipulating the third rib in Expt 3 did not achieve such a wide range of fourth rib motion in two of the four

animals studied. Comparison between the effects of third *vs.* fourth rib manipulation was therefore made for 2.5 mm decreases and increases in inspiratory cranial displacement and for 2.5%  $L_r$  decreases and increases in inspiratory muscle shortening.

Statistical assessments of the effects of rib clamping, levator costae section (Expt 1), external intercostal section (Expt 2), internal intercostal denervation (Expt 2), and third rib manipulation (Expt 3) on these relationships were made with Student's paired  $t$  tests. The criterion for statistical significance was taken as  $P < 0.05$ . All data are given as means  $\pm$  s.e.m.

## RESULTS

### Baseline response to lower rib manipulation

The twenty animals of the study had a mean arterial  $P_{CO_2}$  of  $38.3 \pm 0.9$  mmHg and a mean arterial  $P_{O_2}$  of  $92.7 \pm 3.0$  mmHg, and all showed phasic inspiratory EMG activity in the parasternal and external intercostal muscles of the third interspace associated with an inspiratory cranial displacement of the fourth rib. Pulling this rib in the caudal or cranial direction during inspiration did not affect the parasternal intercostal EMG activity. As shown by the records of a representative animal in Fig. 1A, however, the external intercostal EMG activity was markedly altered. When the rib was pulled in the caudal direction, so that its normal inspiratory cranial motion was reduced or reversed into an inspiratory caudal motion, the external intercostal inspiratory EMG activity was increased; the inspiratory shortening of the muscle was simultaneously reduced or reversed into an inspiratory lengthening. Conversely, when the fourth rib was pulled in the cranial direction so that the inspiratory cranial motion of the rib was augmented, there was a reduction in external intercostal EMG activity associated with an increased inspiratory muscle shortening.

External intercostal EMG activity was similarly related to axial rib motion in all animals in the study. In each case, the relationship between rib motion and EMG activity was curvilinear and could be fitted by an exponential function with a negative slope, as shown in Fig. 2A. The correlation coefficient ( $r$ ) of this function ranged between 0.86 and 0.98 (mean  $\pm$  s.e.m. =  $0.95 \pm 0.01$ ), and its slope (i.e. the change in inspiratory EMG activity produced by 5 mm decreases and increases in cranial rib motion) varied between  $-30$  and  $-411\%$  (mean  $\pm$  s.e.m. =  $-156.0 \pm 22.1\%$ ). The relationship between the inspiratory change in muscle length and inspiratory EMG activity was also curvilinear, although it had a positive slope (Fig. 2B).

### Effect of rib clamping

When the third and fourth ribs were locked, the external intercostal muscle essentially remained constant in length both during resting breathing and during manipulation of the ribs. However, the external intercostal inspiratory EMG activity continued to increase when the normal cranial motion of the ribs was reduced or reversed into a caudal motion (Fig. 1B), and it continued to decrease when the cranial rib motion was augmented. In each animal, the

**Table 1. Slopes and correlation coefficients of the relationships between axial rib motion and external intercostal inspiratory EMG activity**

	Control	After rib clamping	After section of levator costae
Dog 1	-137.3 (0.90)	-89.6 (0.93)	-94.6 (0.99)
2	-39.1 (0.92)	-40.4 (0.92)	-29.2 (0.93)
3	-70.1 (0.94)	-65.6 (0.93)	-107.8 (0.96)
4	-55.5 (0.97)	-41.1 (0.98)	-43.6 (0.97)
5	-330.0 (0.98)	-280.1 (0.97)	-108.7 (0.96)
6	-114.3 (0.96)	-94.7 (0.96)	-94.0 (0.98)
7	-143.9 (0.98)	-147.9 (0.92)	-49.5 (0.89)
8	-148.7 (0.98)	-68.5 (0.92)	-98.1 (0.96)
Mean	-129.9	-103.5	-78.1
S.E.M.	32.2	28.0	11.2

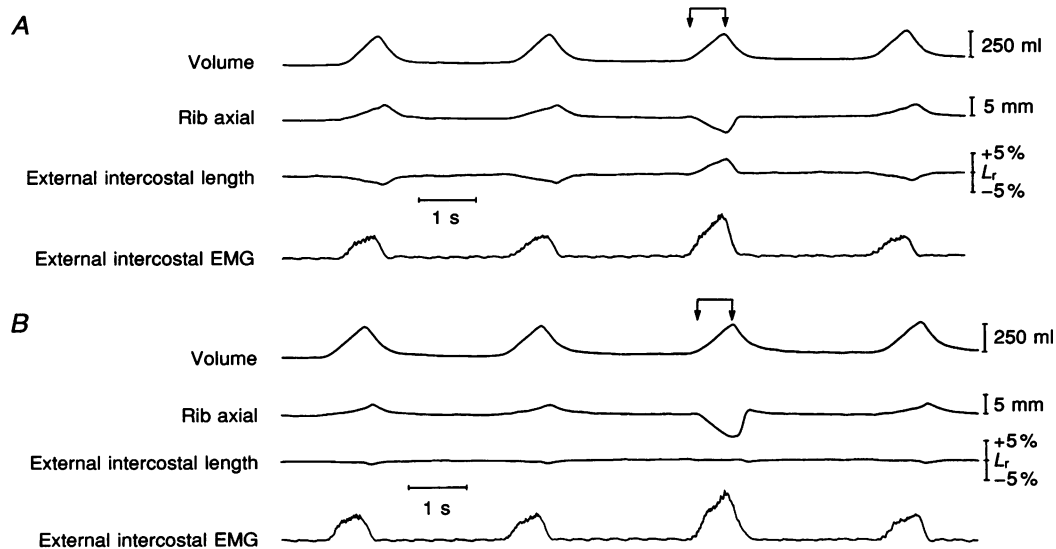
The relationships were fitted by regression equations of the type  $y = ae^{bx}$ , where  $y$  is the peak EMG activity expressed as a percentage of control, and  $x$  is the axial rib motion expressed in millimetres. The values thus shown are the changes in  $y$  produced by 5 mm decreases and increases in  $x$ , and the numbers in parentheses are the correlation coefficients of the regression equations. All values are significant at  $P < 0.001$ .

relationship between axial rib motion and external intercostal EMG activity could still be fitted by an exponential function with a negative slope. Although this relationship was slightly steeper than before rib clamping in three of the sixteen animals in which the procedure was performed, it was flatter in the other thirteen animals, as shown in Fig. 2. As

a result, the slope over the whole animal group was reduced from  $-148.6 \pm 20.8$  to  $-122.3 \pm 19.0\%$  ( $P < 0.005$ ).

#### Effect of levator costae section (Expt 1)

The effects of sectioning the levator costae in the third interspace on the relationship between axial rib motion and



**Figure 1. Response of the external intercostal muscle to a caudal displacement of the ribs during inspiration**

Traces obtained in a representative animal before (A) and after (B) clamping the 2 ribs making up the intercostal space. During control (A), the external intercostal muscle (third interspace) is electrically active and shortens during the inspiratory phase of the breathing cycle, and the fourth rib moves cranially (upward deflection). When the rib is manipulated so that its normal inspiratory cranial motion is reversed into an inspiratory caudal motion (arrows), the external intercostal muscle lengthens during inspiration and the inspiratory EMG activity is increased. After rib clamping (B), a caudal displacement of the ribs (arrows) still elicits an increased external intercostal inspiratory EMG activity, yet the muscle is constant in length.

**Table 2. Slopes and correlation coefficients of the relationships between axial rib motion and external intercostal inspiratory EMG activity**

	Control	After rib clamping	After section of contiguous external intercostals	After denervation of internal intercostals
Dog 9	-319.9 (0.98)	-271.1 (0.97)	-44.6 (0.95)	—
10	-197.1 (0.96)	-170.3 (0.95)	-78.2 (0.95)	—
11	-124.3 (0.96)	-97.7 (0.96)	-62.3 (0.95)	—
12	-87.3 (0.96)	-76.9 (0.97)	-50.8 (0.93)	—
13	-158.7 (0.97)	-78.5 (0.95)	-81.3 (0.96)	—
14	-211.9 (0.86)	-210.8 (0.94)	-74.6 (0.97)	-78.8 (0.97)
15	-92.0 (0.95)	-72.1 (0.95)	-114.5 (0.95)	-95.3 (0.93)
16	-147.9 (0.98)	-151.3 (0.92)	-67.8 (0.87)	-68.7 (0.87)
Mean	-167.4	-141.1	-71.8	-80.9
S.E.M.	26.9	25.8	7.6	7.7

Same conventions as in Table 1.

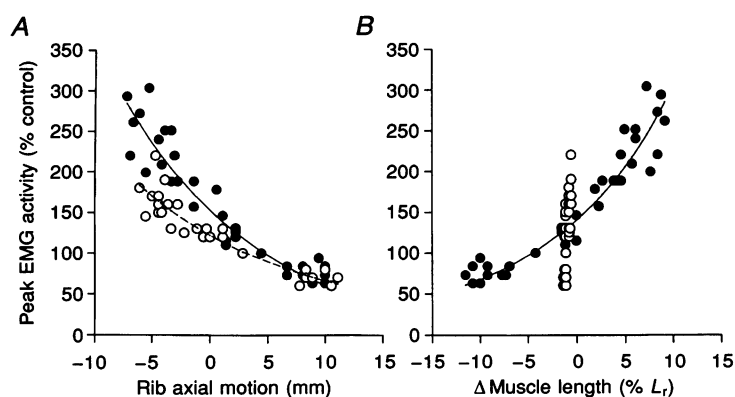
external intercostal EMG activity are summarized in Table 1 for the eight animals studied. Section of the levator costae did not alter the shape of the relationship. Furthermore, although the slope of the relationship was reduced in three animals, it was unchanged in three and increased in two. Consequently, the slope for the animal group was not statistically different from that measured before section.

**Effect of external intercostal section (Expt 2)**

The effects of severing the external intercostals in the rostral and caudal interspaces and the levator costae in all interspaces are shown for two representative animals in

Fig. 3, and the results obtained in the eight animals studied are summarized in Table 2. An exponential relationship with a negative slope was still observed between axial rib motion and external intercostal EMG activity in all animals, and in two the slope of the relationship was slightly greater (Fig. 3A). However, in the other six animals, the slope of the relationship was clearly decreased (Fig. 3B). For the whole animal group, therefore, the slope was reduced from  $-141.1 \pm 25.8$  to  $-71.8 \pm 7.6\%$  ( $P < 0.10$ ).

The relationship between axial rib motion and external intercostal EMG activity was unaltered by subsequent denervation of the internal intercostal muscles (Table 2).



**Figure 2. Effect of rib clamping on the external intercostal muscle response to rib motion**

Data obtained in a representative animal (Dog 3 in Table 1). A, relationships between the inspiratory axial motion of the rib and the peak EMG activity before (● and continuous curve) and after (○ and dashed curve) clamping the 2 ribs making up the intercostal space. B, corresponding relationships between the inspiratory change in length of the external intercostal muscle and peak EMG activity. Peak EMG activity is expressed as a percentage relative to the activity recorded during resting, unmanipulated breathing, rib axial motion is expressed in millimetres, and change in muscle length is expressed as percentage change relative to the muscle relaxation length ( $L_r$ ). Positive values of rib motion and length changes indicate inspiratory cranial motion and muscle lengthening, respectively. Each data point corresponds to a single manipulated breath.

**Table 3.** Slopes and correlation coefficients of the relationships between the change in external intercostal length or axial rib motion and external intercostal inspiratory EMG activity during manipulation of the lower and upper ribs

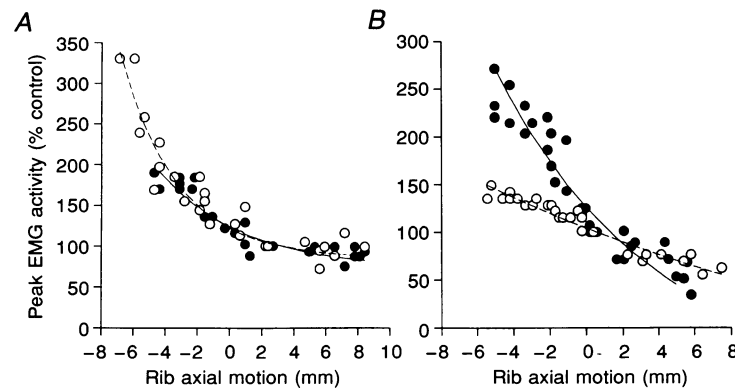
	$\Delta$ Muscle length (% $L_r$ )		Axial rib motion (mm)	
	Lower rib	Upper rib	Lower rib	Upper rib
A. Control				
Dog 17	+114.1 (0.93)	-125.2 (0.79)	-75.8 (0.96)	-45.5 (0.80)
18	+30.9 (0.98)	-20.9 (0.95)	-70.6 (0.97)	-93.7 (0.95)
19	+131.9 (0.95)	-43.6 (0.91)	-186.7 (0.96)	-118.5 (0.87)
20	+9.9 (0.95)	-9.5 (0.84)	-14.9 (0.95)	-18.4 (0.82)
Mean	+71.7	-49.8	-87.0	-69.0
S.E.M.	30.1	26.1	36.0	45.4
B. After section of contiguous external intercostals				
Dog 17	+143.2 (0.93)	-55.1 (0.97)	-101.0 (0.96)	-21.2 (0.97)
18	+25.2 (0.99)	-16.7 (0.92)	-63.0 (0.98)	-59.4 (0.90)
19	+99.3 (0.93)	-19.0 (0.77)	-136.9 (0.93)	-36.2 (0.71)
20	+4.5 (0.94)	-2.9 (0.84)	-12.2 (0.93)	-3.7 (0.85)
Mean	+68.1	-23.4	-78.3	-30.1
S.E.M.	32.3	11.1	26.7	11.8

The relationships were fitted by regression equations of the type  $y = ae^{bx}$ , where  $y$  is the peak EMG activity expressed as a percentage of control, and  $x$  is the inspiratory change in muscle length expressed as a percentage of muscle resting length (%  $L_r$ ) or the axial rib motion in millimetres. The values thus shown are the changes in EMG activity produced by 2.5%  $L_r$  decreases and increases in inspiratory shortening or 2.5 mm decreases and increases in cranial rib motion. Numbers in parentheses are the correlation coefficients of the regression equations. All values are significant at  $P < 0.001$ .

### Response to upper vs. lower rib manipulation (Expt 3)

When the third rib was pulled in the cranial direction in the intact animal, the increased inspiratory cranial motion of the ribs was associated with a reduction in external intercostal EMG activity. Yet the normal inspiratory shortening of this muscle was reduced or reversed into an inspiratory muscle lengthening. Conversely, when the third rib was pulled in the caudal direction, the external

intercostal EMG activity was increased although the inspiratory shortening of the muscle was augmented. As a result, the relationship between the axial motion of the fourth rib and the external intercostal EMG activity was maintained (Fig. 4A), but the relationship between the change in muscle length and EMG activity had a negative rather than a positive slope (Fig. 4B). This observation thus confirmed those reported in our previous communication



**Figure 3.** Effect of severing the contiguous segments on the external intercostal muscle response to rib motion

Data obtained in 2 representative animals (A, dog 13 in Table 2; B, dog 14). ● and continuous curves correspond to the relationships between the inspiratory axial motion of the rib and the peak EMG activity after rib clamping; ○ and dashed curves correspond to the relationships obtained after section of the external intercostal muscles in the rostral and caudal interspaces.

(De Troyer, 1996), and the slopes and correlation coefficients of the relationships obtained in the four animals studied are displayed in Table 3.

Sectioning the external intercostals in the contiguous interspaces and the levator costae did not fundamentally alter this pattern, as shown in Fig. 4*C* and *D*. Thus, manipulating the third rib continued to produce an exponential relationship with a negative slope between axial rib motion and external intercostal EMG activity (Fig. 4*C*), and it continued to elicit a paradoxical relationship between the change in muscle length and EMG activity (Fig. 4*D*). However, whereas in the intact animal, the relationship between rib motion and EMG activity had a similar slope no matter which rib was manipulated, after section of the contiguous external intercostals the slope of the relationship obtained during manipulation of the third rib was consistently smaller than that obtained during manipulation of the fourth rib (Table 3).

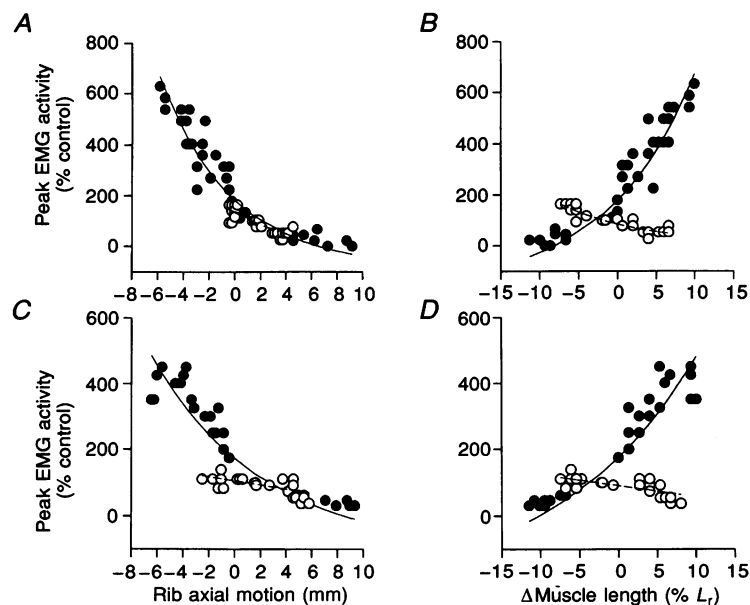
## DISCUSSION

The present studies have confirmed that the inspiratory EMG activity recorded from a particular external intercostal muscle is exquisitely sensitive to the direction and amplitude of the inspiratory displacement of the ribs into which it inserts. They have also confirmed that this phenomenon persists in the absence of altered afferent activity from the muscle's own spindles. Indeed, when the two ribs making up the cranial and caudal boundaries of the muscle were locked,

muscle length was constant and yet the increases and decreases in inspiratory activity induced by the caudal and cranial rib displacements were only moderately attenuated.

The levator costae muscle runs in each interspace from the transverse process of the vertebra cranially to the angle of the rib caudally. This muscle therefore lengthens whenever the rib making up the caudal boundary of the interspace is displaced caudally, and its large content of muscle spindles (Hilaire, Nicholls & Sears, 1983) should lead to an increased spindle afferent activity. A cranial displacement of this rib should conversely reduce spindle afferent activity from the levator costae even when the two ribs making up the interspace are locked. Thus, provided these muscle spindles projected to the  $\alpha$ -motoneurons of the adjacent, ipsi-segmental external intercostal, they would be ideally suited to mediate the relation of external intercostal activity to rib motion. However, when we severed the levator costae at the level of its costal insertions (Expt 1), this relation was found to be unaltered. This result does not necessarily exclude projections from levator costae muscle spindles to the external intercostal  $\alpha$ -motoneurons but indicates that any contribution from these receptors to the modulation of external intercostal activity by rib motion is small.

It is well established from studies in the cat that the external intercostal  $\alpha$ -motoneurons in a given segment of the thoracic spinal cord receive not only monosynaptic excitation from the ipsi-segmental external intercostal muscle spindles but also polysynaptic excitation from the external intercostal muscle spindles in the contiguous



**Figure 4.** Effect of severing the contiguous segments on the external intercostal muscle response to separate manipulation of the upper (O) and lower (●) ribs

Data obtained in a representative animal (Dog 19 in Table 3). The upper panels show the relationships between the axial rib motion (*A*) or inspiratory change in muscle length (*B*) and peak EMG activity during control. The lower panels (*C* and *D*) show the corresponding relationships after section of the external intercostal muscles in the rostral and caudal interspaces. Each data point corresponds to a single manipulated breath.

segments (Eccles, Sears & Shealy, 1963; Aminoff & Sears, 1971). Therefore, when the two ribs making up one interspace are locked and displaced caudally, the expected effect of the lengthening of the external intercostal muscles in the rostral segments would be an excitation of external intercostal activity. This excitatory effect should be particularly pronounced in the presence of rib clamping since for a given caudal displacement of the lower rib, the lengthening of the rostral external intercostal muscles will be larger. The augmented shortening of the external intercostal muscles in the caudal segments should result in a concomitant inhibition of external intercostal activity, but in view of the exponential shape of the relationship between rib motion and muscle activity, this effect should be more than offset by the lengthening of the rostral segments. In addition, there is evidence in the cat that the external intercostal muscles in the rostral interspaces have a greater spindle density than the external intercostal muscles in the caudal interspaces (Duron *et al.* 1978). This difference should also make the changes in muscle length in the rostral interspaces dominate the changes in muscle length in the caudal interspaces.

In agreement with this prediction, the relation of external intercostal activity to rib motion was commonly attenuated when the external intercostal muscles in the rostral and caudal interspaces were eliminated (Expt 2). However, in every animal in which this experiment was performed, a caudal rib displacement continued to induce an increased inspiratory activity and a cranial rib displacement continued to elicit a decreased inspiratory activity, and yet the external intercostal investigated was still constant in length. Previous studies in the cat by Sears (1964*b*) have also suggested that some external intercostal  $\alpha$ -motoneurons may receive excitation from the internal intercostal nerves as well, but the relationship between rib motion and external intercostal activity was still maintained after section of these nerves (Table 2), and this also argued against a significant role of tendon organs. Indeed, it is difficult to see how, in the absence of any change in muscle length and in the absence of any active muscle in the rostral and caudal interspaces, caudal and cranial rib displacements could induce opposite alterations in muscle tension. It appeared, therefore, that although the external intercostal muscle spindles in the rostral interspaces are involved, this relationship is in part mediated by non-muscular receptors.

The observations made in the third experiment of these studies provided further evidence in support of this idea. After section of the muscles in the rostral and caudal segments, the relation of external intercostal activity to rib motion obtained during displacement of the third rib was less steep than in the control condition, thus confirming that muscle spindles in these segments, in particular the rostral segments, are involved. However, this relation persisted in all animals, in spite of the fact that the caudal rib displacements were then associated with an augmented inspiratory muscle shortening while the increased cranial

rib displacements induced a decreased muscle shortening. Thus, rib motion triggers a powerful proprioceptive reflex that actually outweighs the changes in ipsi-segmental spindle afferent activity.

If this powerful reflex does not arise in muscle receptors, then it is most likely to be mediated by receptors within the ribcage joints. To our knowledge, there are no data on the presence or the physiological significance of mechanoreceptors in the costosternal joints. However, as with the synovial joints in the limbs (Andrew & Dodt, 1953; Boyd & Roberts, 1953; Skoglund, 1956), the capsules of the costovertebral joints are known to contain mechanoreceptors (Holmes & Torrance, 1959). Recordings of afferent discharges from these receptors in rabbits and cats have also shown that they do respond to rib displacement (Godwin-Austen, 1969). Specifically, a large majority of these receptors was found to increase their discharge rates when the ribs were displaced in the caudal direction and to decrease their discharge rates when the ribs were displaced in the cranial direction. The magnitude of these variations in afferent activity was directly proportional to the velocity of rib displacement. In addition, such variations were already recorded during quiet, resting breathing, thus indicating that the threshold of activity of these joint receptors is relatively low.

The current observations, combined with these findings, thus lead to the conclusion that the response of external intercostal activity to rib motion results from the interaction between reflex inputs from costovertebral joint receptors and reflex inputs from ipsi-segmental and juxta-segmental (rostral) muscle spindles. Thus, a reduced inspiratory cranial displacement of the ribs would elicit increased afferent discharges from joint receptors and muscle spindles, both of which would lead to an increase in external intercostal efferent  $\alpha$ -motor activity. Conversely, afferent inputs from joint receptors and muscle spindles together would be diminished in the presence of an augmented cranial displacement of the ribs, so reducing external intercostal activity. Although both types of receptors appeared to be involved in most animals, analysis of the individual data in Tables 2 and 3 suggests that their relative contributions may differ. Indeed, some animals (e.g. dogs 9, 10 and 14 in Table 2) showed a large decrease in slope after rib clamping and section of the contiguous external intercostals, thus suggesting a large contribution from muscle spindles, but other animals (e.g. dogs 12 and 15 in Table 2) showed little or no change in slope after these procedures; in these animals, joint receptors would be predominant.

This conclusion is particularly relevant to the understanding of the so-called 'load-compensating' reflex, i.e. the increased external intercostal activity that occurs in response to a sudden increase in inspiratory airflow resistance or an airway occlusion at end-expiration (Corda *et al.* 1965; Sant'Ambrogio & Widdicombe, 1965; Shannon & Zechman, 1972; De Troyer, 1991). As previously emphasized (see Introduction), this response is conventionally attributed to a



spindle reflex, and it is a fact that a step increase in airflow resistance or closure of the trachea induces a reduced shortening or lengthening of the external intercostal muscles during inspiration (De Troyer, 1992; Romaniuk *et al.* 1992) and elicits increased afferent discharges from external intercostal muscle spindles (Critchlow & von Euler, 1963; Corda *et al.* 1965). However, these procedures cause a concomitant reduction in the inspiratory cranial motion, or produce an inspiratory caudal motion, of the ribs (De Troyer, 1992). Based on the present studies, one would therefore suggest that the 'load-compensating' reflex is mediated not only by muscle spindles but also by joint mechanoreceptors, and it is in part the afferent discharge from these receptors whose interruption by cutting the dorsal root abolishes the response of the external intercostals to an increased airflow resistance.

Another implication of the current studies is that rib joint receptors do not project to the parasternal intercostal  $\alpha$ -motoneurons. Indeed, as during airway occlusion (De Troyer, 1991), increases in parasternal intercostal EMG activity during manipulation of the ribs in the caudal direction were never recorded. Inhibition of parasternal intercostal EMG activity during cranial rib displacement was not seen either. This amplifies the idea that in contrast to the external intercostals, activation of these muscles is governed primarily, if not exclusively, by central mechanisms (De Troyer, 1991).

- AMINOFF, M. J. & SEARS, T. A. (1971). Spinal integration of segmental, cortical, and breathing inputs to thoracic respiratory motoneurons. *Journal of Physiology* **215**, 557–575.
- ANDREW, B. L. & DODT, E. (1953). The development of sensory nerve endings at the knee joint of the cat. *Acta Physiologica Scandinavica* **28**, 287–296.
- BOYD, I. A. & ROBERTS, T. D. M. (1953). Proprioceptive discharges from stretch-receptors in the knee joint of the cat. *Journal of Physiology* **122**, 38–58.
- CORDA, M., EKLUND, G. & VON EULER, C. (1965). External intercostal and phrenic  $\alpha$  motor responses to changes in respiratory load. *Acta Physiologica Scandinavica* **63**, 391–400.
- CRITCHLOW, V. & VON EULER, C. (1963). Intercostal muscle spindle activity and its  $\gamma$  motor control. *Journal of Physiology* **168**, 820–847.
- DE TROYER, A. (1991). Differential control of the inspiratory intercostal muscles during airway occlusion in the dog. *Journal of Physiology* **439**, 73–88.
- DE TROYER, A. (1992). The electro-mechanical response of canine inspiratory intercostal muscles to increased resistance: the cranial rib cage. *Journal of Physiology* **451**, 445–461.
- DE TROYER, A. (1996). Rib motion modulates inspiratory intercostal activity in dogs. *Journal of Physiology* **492**, 265–275.
- DE TROYER, A. & KELLY, S. (1982). Chest wall mechanics in dogs with acute diaphragm paralysis. *Journal of Applied Physiology* **53**, 373–379.
- DE TROYER, A. & YUEHUA, C. (1994). Intercostal muscle compensation for parasternal paralysis in the dog: central and proprioceptive mechanisms. *Journal of Physiology* **479**, 149–157.
- DURON, B., JUNG-CAILLOL, M. C. & MARLOT, D. (1978). Myelinated nerve fiber supply and muscle spindles in the respiratory muscles of cat: quantitative study. *Anatomy and Embryology* **152**, 171–192.
- ECCLES, R. M., SEARS, T. A. & SHEALY, C. N. (1963). Intra-cellular recording from respiratory motoneurons of the thoracic spinal cord of the cat. *Nature* **193**, 844–846.
- GODWIN-AUSTEN, R. B. (1969). The mechanoreceptors of the costovertebral joints. *Journal of Physiology* **202**, 737–753.
- HILAIRE, G. G., NICHOLLS, J. G. & SEARS, T. A. (1983). Central and proprioceptive influences on the activity of levator costae motoneurons in the cat. *Journal of Physiology* **342**, 527–548.
- HOLMES, R. & TORRANCE, R. W. (1959). Afferent fibres of the stellate ganglion. *Quarterly Journal of Experimental Physiology* **44**, 271–281.
- NEWMAN, S. L., ROAD, J., BELLEMARE, F., CLOZEL, J. P., LAVIGNE, C. M. & GRASSINO, A. (1984). Respiratory muscle length measured by sonomicrometry. *Journal of Applied Physiology* **56**, 753–764.
- ROMANIUK, J. R., SUPINSKI, G. & DI MARCO, A. F. (1992). Relationship between parasternal and external intercostal muscle length and load compensatory responses in dogs. *Journal of Physiology* **449**, 441–455.
- SANT'AMBROGIO, G. & WIDDICOMBE, J. G. (1965). Respiratory reflexes acting on the diaphragm and inspiratory intercostal muscles of the rabbit. *Journal of Physiology* **180**, 766–779.
- SEARS, T. A. (1963). Activity of fusimotor fibres innervating muscle spindles in the intercostal muscles of the cat. *Nature* **197**, 1013–1014.
- SEARS, T. A. (1964a). Efferent discharges in alpha and fusimotor fibres of intercostal nerves of the cat. *Journal of Physiology* **174**, 295–315.
- SEARS, T. A. (1964b). Investigations on respiratory motoneurons of the thoracic spinal cord. In *Physiology of Spinal Neurons*, ed. ECCLES, J. C. & SCHADE, J. P., *Progress in Brain Research*, vol. 12, pp. 259–272. Elsevier, Amsterdam.
- SHANNON, R. & ZECHMAN, F. W. (1972). The reflex and mechanical response of the respiratory muscles to an increased airflow resistance. *Respiration Physiology* **16**, 51–69.
- SKOGLUND, S. (1956). Anatomical and physiological studies of knee joint innervation in the cat. *Acta Physiologica Scandinavica* **36**, suppl. 124.

#### Acknowledgements

The author gratefully acknowledges A. Van Muylem for his help in the data analysis and the National Heart, Lung and Blood Institute (USA) for its support (grant HL-45545).

Received 4 February 1997; accepted 15 May 1997.