
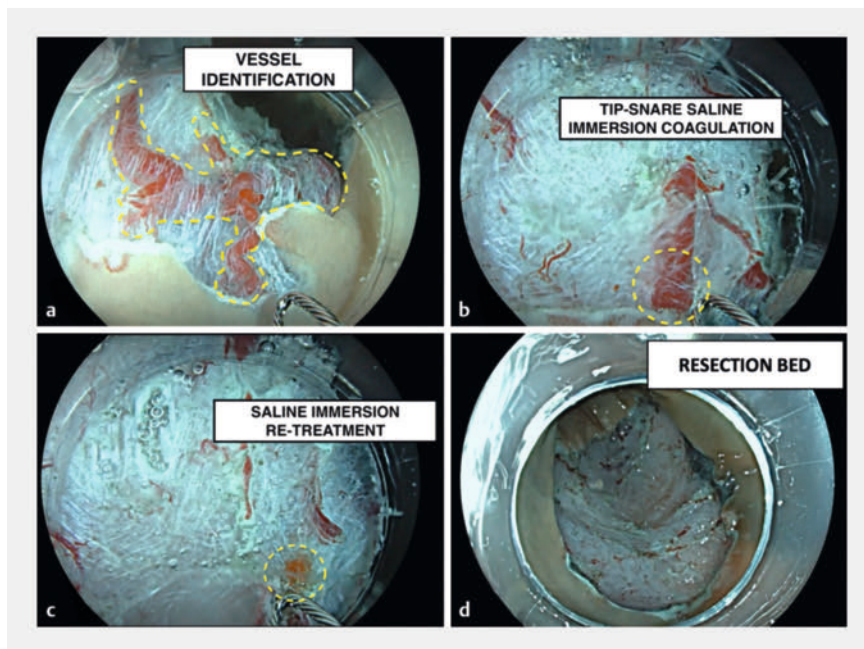


Prophylactic saline-immersion snare-tip vessel coagulation after colorectal endoscopic resection

OPEN
ACCESS



▶ Video 1 Prophylactic saline-immersion coagulation for prevention of delayed bleeding after endoscopic mucosal resection for right colonic laterally spreading tumor.



▶ Fig. 1 Endoscopic images of saline-immersion coagulation. **a** Blood vessel identification (dashed line) after endoscopic mucosal resection. **b** Prophylactic snare-tip coagulation. **c** The vessels appear whitish after application of the high-current voltage under saline immersion. **d** Resection bed after saline-immersion snare-tip vessel coagulation.

Endoscopic mucosal resection (EMR) for large colorectal adenomatous lesions is hampered by a relevant risk of post-EMR delayed bleeding [1,2]. Patients who have proximal lesions and/or are on antithrombotic treatment are at higher risk for such delayed bleeding [3].

Post-EMR prophylactic vessel coagulation has been previously standardized as the application of a low-voltage current using hemostatic forceps [4]. However, this requires a time-consuming device exchange, as well as an additional cost. In addition, the application of a low-voltage current by a relatively large forceps may result in deep thermal injury.

A recent peroral endoscopic myotomy-based series reported that a high-voltage coagulation current delivered through a dedicated knife in a saline-immersion setting maximizes the coagulation effect, preventing unintentional cutting of the vessel wall [5].

We present the case of an 84-year-old woman who underwent an underwater piecemeal EMR (Captivator II, 15 mm; Boston Scientific, Marlborough, Massachusetts, USA) for a large (50 mm) right

colon laterally spreading tumor granular-type without endoscopic features of submucosal invasive cancer. To prevent delayed bleeding, prophylactic saline-immersion coagulation was performed at the end of the procedure (▶ **Video 1**).

The snare tip was gently placed in contact with the visible vessels and a high-voltage coagulation current (ForcedCOAG E4.0, ERBE VIO3; ERBE Elektromedizin GmbH, Tübingen, Germany) was delivered. This resulted in progressive presealing of the vessels without any cutting effect (▶ **Fig. 1**). The patient was discharged 4 hours after the procedure with no relevant post-procedural symptoms. No delayed bleeding or other adverse events were reported up to 30 days after the procedure.

This novel technique aims to reduce the risk of delayed bleeding after endoscopic

resection using a one-device, cost-effective, and time-sparing approach. It also highlights the potential applications of saline-immersion coagulation in the field of endoscopy, which appear to be universal and irrespective of the technique, device, or type of current adopted.

Endoscopy_UCTN_Code_TTT_1AQ_2AZ

Conflict of Interest

A. Capogreco is a consultant for ERBE. R. Masetti is a consultant for ERBE, Fujifilm, 3DMatrix and Boston Scientific. C. Hassan is a consultant for Alpha-Sigma, Fujifilm, Medtronic, Norgine, Olympus and Pentax. A. Repici is a consultant for Medtronic, ERBE, Fujifilm and Olympus.

The authors

Antonio Capogreco¹, Roberto de Sire^{2,3},
Davide Massimi¹, Ludovico Alfarone¹, Roberta
Maselli^{1,4}, Cesare Hassan^{1,4}, Alessandro
Repici^{1,4}

- 1 Digestive Endoscopy Unit, IRCCS Humanitas Research Hospital, Rozzano, Italy
- 2 Gastroenterology, Endoscopy Unit, IRCCS Humanitas Research Hospital, Rozzano, Italy
- 3 Gastroenterology, IBD Unit, Department of Clinical Medicine and Surgery, University Federico II, Napoli, Italy
- 4 Department of Biomedical Sciences, Humanitas University, Pieve Emanuele, Italy

Corresponding author

Antonio Capogreco, MD

Gastroenterology, Endoscopy Unit, IRCCS Humanitas Research Hospital, Via Manzoni 56, 20089 Rozzano, Italy
antonio.capogreco@humanitas.it

Citation Format

Endoscopy 2024; 56: E622–E623.
doi: 10.1055/a-2353-6039.

References

- [1] Ferlitsch M, Moss A, Hassan C et al. Colorectal polypectomy and endoscopic mucosal resection (EMR): European Society of Gastrointestinal Endoscopy (ESGE) Clinical Guideline. *Endoscopy* 2017; 49: 270–297. doi:10.1055/s-0043-102569
- [2] Albéniz E, Montori S, Rodríguez De Santiago E et al. Preventing postendoscopic mucosal resection bleeding of large nonpedunculated colorectal lesions. *Am J Gastroenterol* 2022; 117: 1080–1088
- [3] Spadaccini M, Albéniz E, Pohl H et al. Prophylactic clipping after colorectal endoscopic resection prevents bleeding of large, proximal polyps: meta-analysis of randomized trials. *Gastroenterology* 2020; 159: 148–158. doi:10.1053/j.gastro.2020.03.051
- [4] Bahin FF, Naidoo M, Williams SJ et al. Prophylactic endoscopic coagulation to prevent bleeding after wide-field endoscopic mucosal resection of large sessile colon polyps. *Clin Gastroenterol Hepatology* 2015; 13: 724–730. doi:10.1016/j.cgh.2014.07.063
- [5] Capogreco A, Hassan C, De Blasio F et al. Prophylactic underwater vessel coagulation for submucosal endoscopy. *Gut* 2024; 73: 1049–1051. doi:10.1136/gutjnl-2024-332002

Bibliography

Endoscopy 2024; 56: 978–979

DOI 10.1055/a-2419-2195

ISSN 0013-726X

© 2024. The Author(s).

This is an open access article published by Thieme under the terms of the Creative Commons Attribution License, permitting unrestricted use, distribution, and reproduction so long as the original work is properly cited.

(<https://creativecommons.org/licenses/by/4.0/>)

Georg Thieme Verlag KG, Rüdigerstraße 14,
70469 Stuttgart, Germany



ENDOSCOPY E-VIDEOS

<https://eref.thieme.de/e-videos>



E-Videos is an open access online section of the journal *Endoscopy*, reporting on interesting cases and new techniques in gastroenterological endoscopy. All papers include a high-quality video and are published with a Creative Commons CC-BY license. *Endoscopy E-Videos* qualify for HINARI discounts and waivers and eligibility is automatically checked during the submission process. We grant 100% waivers to articles whose corresponding authors are based in Group A countries and 50% waivers to those who are based in Group B countries as classified by Research4Life (see: <https://www.research4life.org/access/eligibility/>).

This section has its own submission website at

<https://mc.manuscriptcentral.com/e-videos>