

## A Case of Osteitis Fibrosa Cystica of the Mandible: A Rare Presentation during Pregnancy due to *CDC73* Mutation

Pratibha Pawal,<sup>1</sup> Anand Nikalje,<sup>2</sup> Yash Chauhan,<sup>3</sup> Premlata Varthakavi,<sup>3</sup> Nikhil Bhagwat<sup>3</sup>

<sup>1</sup>Spandan Superspecialty Clinic, Maharashtra, India

<sup>2</sup>Mahatma Gandhi Misson Medical College and Hospital, Maharashtra, India

<sup>3</sup>Topiwala National Medical College and Bai Yamunabai Laxman Nair Charitable Hospital, Mumbai, India

### Abstract

Typically, primary hyperparathyroidism (PHPT) develops as a result of multiglandular hyperplasia, parathyroid cancer, or parathyroid adenoma. Patients usually present with skeletal manifestations such as low-trauma fractures. Osteitis fibrosa cystica (OFC) is a classic yet rare skeletal manifestation of advanced PHPT currently reported in less than 2% of patients. We present a case of a 29-year-old Indian female who presented with a femur fracture and mandibular OFC 20 days after delivery. The painless mandibular swelling gradually progressed from the third month of pregnancy. The biochemical and radiological investigations were indicative of PHPT-associated OFC. After the excision of the three-and-a-half parathyroid gland, histology revealed benign cystic adenomas and hyperplasia. Based on the associated clinical manifestations, OFC was suspected. Clinical exome sequencing revealed *CDC73*(+) c.687\_688dupAG heterogenous pathogenic autosomal dominant mutation. Undiagnosed PHPT in mothers during pregnancy led to neonatal hypocalcaemic convulsions. With adequate supplementation, the infant recovered completely from transient congenital hypoparathyroidism. OFC is an important diagnosis to consider in a young patient with swelling of the neck and jaw. Simultaneous high levels of PTH and serum calcium should raise a high index of suspicion for OFC. Parathyroidectomy helps manage the biochemical abnormalities and causes regression of the jaw mass that causes facial disfigurement and attenuates the declining BMD. Children born to mothers with PHPT should be evaluated for neonatal hypoparathyroidism and supplemented appropriately to reduce the risk of hypocalcaemic manifestations that can be life-threatening. If the *CDC73* mutation is detected, the offspring should be monitored for signs of PHPT due to the high probability of inheritance and parathyroid malignancy.

**Key words:** osteitis fibrosa cystica, primary hyperparathyroidism, pathological fracture, skeletal manifestation

### INTRODUCTION

Primary hyperparathyroidism (PHPT) is a common endocrine disorder with a wide range of estimated prevalence (0.4 to 21.6 cases per 100,000 person-years), probably due to variations in screening globally.<sup>1</sup> However, PHPT is rare in pregnancy, with a reported incidence of 1%.<sup>2</sup> The association of PHPT with 'osteitis fibrosa cystica' (OFC), also known as von Recklinghausen disease, was established in 1925.<sup>3</sup> Osteitis fibrosa cystica is a classic yet rare skeletal manifestation of advanced PHPT currently reported in less than 2% of patients.<sup>4,5</sup> Usually, OFC may be found in any part of the skeleton but it is commonly seen in ribs, clavicle, and pelvis.<sup>6</sup> However, OFCs have a very low incidence (0.1%) in jaws.<sup>6,7</sup> Besides, 90% of the reported cases of OFC occur in hyperparathyroidism due to parathyroid carcinoma, with very few cases attributed to benign growths.<sup>8</sup> Osteitis fibrosa cystica largely occurs in females in the fourth or fifth decade of life; therefore, hereditary patterns should be suspected in younger

patients. Hyperparathyroidism has been reported to be an independent feature of the persistent germline tumor suppressor gene (*CDC73*) mutation.<sup>9</sup>

In this case report, we elaborated on the case of a young, pregnant woman who developed PHPT due to parathyroid adenoma associated with *CDC73* mutation, which initially manifested as an OFC of the jaw and subsequently as a femur fracture. The neonate also developed hypoparathyroidism and consequent hypocalcaemia.

### CASE

A 29-year-old female, 20 days after delivery, was referred to our facility for a confirmed femur fracture on radiograph accompanied by painless, progressive anterior neck and lower jaw swelling.

Approximately seven months before referral to our hospital, the patient had noticed painless anterior neck

eISSN 2308-118x (Online)

Printed in the Philippines

Copyright © 2024 by Pawal et al.

Received: March 12, 2024. Accepted: April 19, 2024.

Published online first: September 3, 2024.

<https://doi.org/10.15605/jafes.039.02.17>

Corresponding author: Pratibha S. Pawal, MD, DM

Consultant Endocrinologist, Spandan Superspecialty Clinic

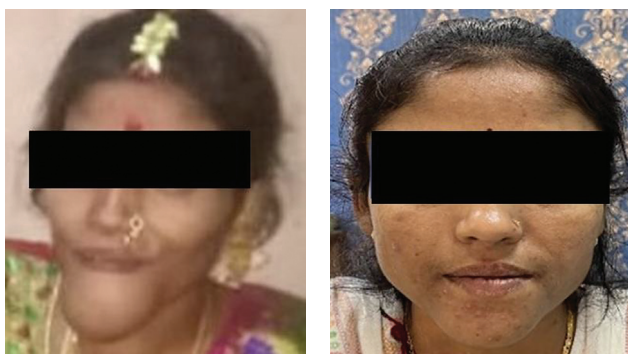Plot No. 63, Pundik Nagar Road, Garkheda,

Aurangabad-Maharashtra - 431009

Tel. No.: 91-9820468315

E-mail: [pratibhapawal@gmail.com](mailto:pratibhapawal@gmail.com)

ORCID: <https://orcid.org/0000-0002-5817-0788>



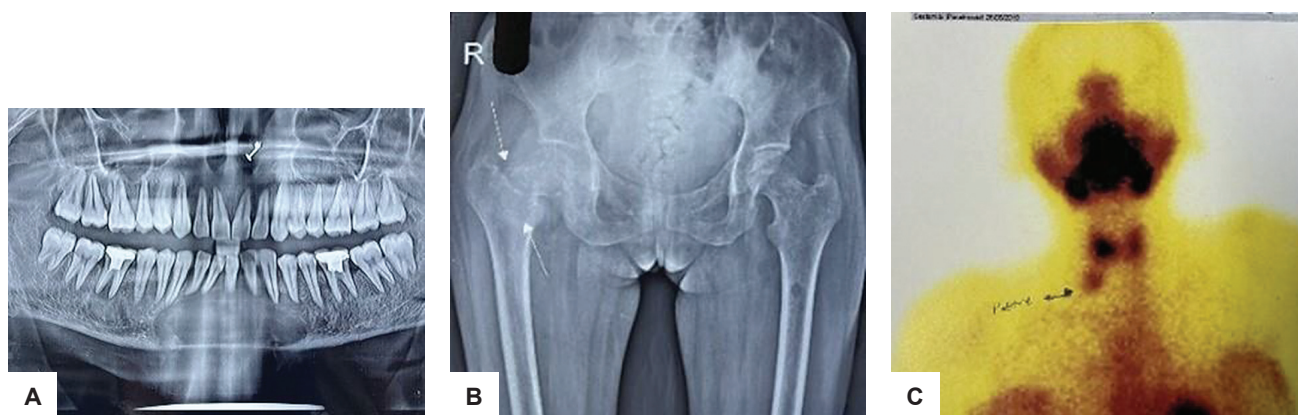**Figure 1. (A)** Pre-operative anterior neck and jaw swelling; **(B)** post-operative resolution of the jaw and neck swelling.

swelling and gradually increasing jaw swelling (Figure 1A), on the third month of gestation. Around the seventh month of gestation, a local dentist evaluated the jaw and neck swelling (Figure 2A). An X-ray revealed a solitary expansile lesion of the central body of the mandible spread across the teeth. It had a distinct sclerotic rim, but no resorption of dental roots was noted. Ultrasonography of the neck revealed a cystic lesion in the right thyroid lobe, 43 x 31 mm, most likely a colloid cyst, and a well-defined mass lesion of 51 x 37 mm of the mandible. There was substantial vascularity in the premental, paramental, and submental regions. Subsequent fine needle aspiration cytology (FNAC) of the mandibular lesion revealed multinucleate giant cells or osteoclastomas. She was advised conservative management until delivery due to risks associated with general anesthesia.<sup>10</sup> She also developed right hip pain, which led to a limping gait. The patient ascribed the pain to the pregnancy; hence, avoided seeking medical advice. She delivered a baby boy at term by lower segment cesarean section (LSCS). The baby's birth weight was 2.2 kg, with an Apgar score of 10/10 and he cried immediately after birth. The cry, tone and activity of the neonate were normal. The neonate was exclusively breastfed successfully and passed stools daily until day 21 of life.

Within 12 hours after delivery, the patient developed an altered sensorium with irrelevant speech and was transferred to the Medicine Intensive Care Unit (MICU).

On examination, her pulse was 112 beats per minute, blood pressure 112/70 mm Hg and blood glucose 86 mg/dL. Fundus examination was normal. Central nervous system examination suggested delirium without focal neurological deficits. Further investigations in the MICU revealed only an abnormal alkaline phosphatase [20.37  $\mu$ kat/L reference range 0.63- 2.10  $\mu$ kat/L] and low serum potassium [3.30 mmol/L (reference range 3.5-5.5 mmol/L)]. Serum calcium was not assessed. Magnetic resonance imaging (MRI) of the brain with MRV showed symmetric hyperintense signals in the bilateral basal ganglia and the midbrain. These findings were considered to be possibly associated with either acute hypoxic insult or metabolic disorder by the treating physician. Metabolic encephalopathy due to hypercalcemia was not suspected by the treating physician. The patient improved with supportive treatment and was discharged after 72 hours.

On day 20 post-partum, she was further evaluated for worsening right hip pain associated with difficulty walking and limping. A hip radiograph revealed a fracture of the right femur (Figure 2B). She was referred to the endocrine service at a tertiary care facility because of a low-trauma fracture at a young age. This prompted laboratory investigations which showed a high serum total calcium at 3.33 mmol/L (reference 2.10-2.55 mmol/L), alkaline phosphatase 5.73  $\mu$ kat/L (reference 0.63-2.10  $\mu$ kat/L), parathyroid hormone 684 ng/L (reference 15-68 ng/L) and low serum 25-hydroxyvitamin D 22.91 nmol/L (reference 74.88-249.60 ng/mL) (Table 1). Thus, after nearly 8 months since symptom onset, PHPT was diagnosed. A subsequent sesta methoxy isobutyl isonitrile (MIBI) scan revealed a parathyroid adenoma at the lower pole of the right thyroid lobe (Figure 2C). Therefore, surgical intervention was sought, and a right inferior parathyroidectomy was performed in a hospital with limited facilities. Intraoperative monitoring of PTH and intraoperative frozen section facilities to predict the postoperative level of PTH were unavailable at the hospital. However, the patient was unwilling to travel to a larger tertiary care centre due to her child's young age. Histopathological examination also revealed benign parathyroid cystic adenoma and hyperplasia. After surgery, there was a decrease in serum



**Figure 2. Radiological imaging of the (A) jaw, (B) femur neck fracture and (C) Sestamibi of the right inferior parathyroid adenoma.**

**Table 1.** Laboratory investigations of the patient (Mother)

Test Reference range Unit	Total Calcium 2.10-2.55 mmol/L	Phosphorus 0.81- 1.45 mmol/L	Alkaline phosphatase 0.63-2.10 µkat/L	25-OH Vitamin D <sub>3</sub> 74.88-249.60 nmol/ml	Intact PTH 15-68 ng/L
<i>Days post-partum (day concerning surgery)</i>					
1 d	not done <sup>†</sup>	not done <sup>†</sup>	20.37	not done <sup>†</sup>	not done <sup>†</sup>
22 d	3.33	0.52	5.73	22.91	684
27 d (One day before surgery)	3.05	0.50	6.1	22.1	NA
28 d (Immediately after surgery)	2.63	0.55	6.23	NA	NA
33 d/1 mo, 2 d	2	0.61	6.4	NA	NA
61 d/ 2 mo	2.5	1.07	6.2	84	184
72 d/2 mo, 11d	2.55	0.81	6.75	50.17	115
105 d/3 mo, 13 d	2.20	0.94	6.30	144.77	225
124 d/4 mo	2.30	1.20	11.16	126	209
142 d/4 mo 20d (One day before second surgery)	2.35	1.55	10.39	156	280
153 d/5 mo (11 days after second surgery)	2.42	0.84	4.91	137.28	120
213 d/7 mo	1.12	1.36	3.22	86.61	94
615 d/1 y, 8mo, 4 d	2.45	1.02	2.9	95	56
704 d/1 y 11 mo 4 d	2.42	0.95	2.3	50.67	37
1184 d/3 y 2 mo 27 d	2.42	0.91	1.9	12.30	45

<sup>†</sup> HPT diagnosis not suspected – hence tests not done; d, day; mo, month; NA, not available; y, year

calcium (from 3.3 to 2.10 mmol/L) and iPTH (from 684 to 184 ng/L), though the latter was not maintained within the normal range. Besides, no significant improvement occurred in the hip pain or mandibular lesion.

Approximately two months after the first solitary parathyroidectomy, a progressive increase in serum calcium (2.55 mmol/L) and PTH (225 ng/L) levels were noted in follow-up investigations. On evaluation for persistent PHPT, she was found to have a low MIBI avidity in proximity to the inferior pole of the left lobe of the thyroid on sestamibi scan and arterially enhancing soft tissue lesion in the left paratracheal region on 4D CT neck suggestive of parathyroid adenoma. A dual-energy X-ray absorptiometry (DXA) scan of the femur, radius ulna, and spine showed a t score of -4.1, -5.3, and -4.8, respectively, which confirmed the diagnosis of osteoporosis.

**Table 2.** Parathyroid levels pre- and post-parathyroidectomy

Event	PTH
Pre-operative Serum PTH	321 pg/ml
First gland removal: Left inferior parathyroid	284 pg/ml
Left superior parathyroid gland removal	213 / 167 pg/ml
Rt superior half parathyroid gland removal	112 / 78 pg/ml

PTH, parathyroid hormone

She underwent a left inferior parathyroid excision at a tertiary care facility equipped for parathyroid surgery. Intraoperative frozen section revealed parathyroid hyperplasia. Nevertheless, no significant decline in intraoperative PTH level was noted; hence, further exploration was conducted (Table 2). Hyperplasia in the left superior and right superior parathyroid glands was confirmed in the frozen section. Therefore, full left superior, full left inferior and half right superior glands were excised, leaving a remnant half-right superior gland. The histopathological analysis was consistent with benign parathyroid hyperplasia. Hungry bone syndrome, commonly occurring as a post-parathyroidectomy complication, was managed with intravenous calcium infusion followed by oral calcitriol, calcium and magnesium supplementation. A year after the three-and-a-half parathyroidectomies, the serum calcium (2.42 mmol/L) and intact PTH (45 ng/L) have been restored to normal levels without calcium and 25-OH vitamin D<sub>3</sub> supplements. She also has completely recovered from bone pain, and the OFC of the jaw has significantly regressed (Figure 1B). The timeline of events is depicted in Figure 3.

Given the young age, presence of parathyroid adenoma and OFC of the jaw, genetic studies were recommended.

**Table 3.** Clinical profile and laboratory investigations of the child

Chronological age	Body Weight kg	Test Reference range Unit	Ionic calcium 1.12-1.37 mmol/dl	Inorganic Phosphorus 1.13-2.13 mmol/L	Alkaline Phosphatase 1-5.35 ukat/L	25-OH vit D <sub>3</sub> 74.88- 249.60 nmol/L	Intact PTH 15-68 ng/L
<i>Clinical presentation</i>							
21 d	2.4	Admission for hypocalcemic seizures	0.62	2.74	11.2	42.43	6.7
2 mo 10 d	3.6	Hypocalcaemic seizures since birth, on calcitriol- irregular medications -seizures persistent till six weeks after birth	1.12	2.36	9.27	12.23	12
2 mo 27 d	3.7	No seizures in the past 15 d	1.36	2.74	10.3	32	15.4
3 mo 12 d	4.9	Neck holding+, social smile+	1.25	2.26	10.47	NA	17.5
5 mo	6.1	Roll over	1.42	1.65	9.47	144.77	2.01
8 mo 15 d	8.6	Calcitriol gradually tapered and stopped					
38 mo 26 d	12.2	No further seizures. Mental, fine motor and language milestones are normal. Walking at 1.5 y, climbing down stairs with support, riding tricycles	1.24	1.9	4.33	26.21	37.8

PTH, parathyroid hormone; d, days; mo, months; NA, not available; y, years

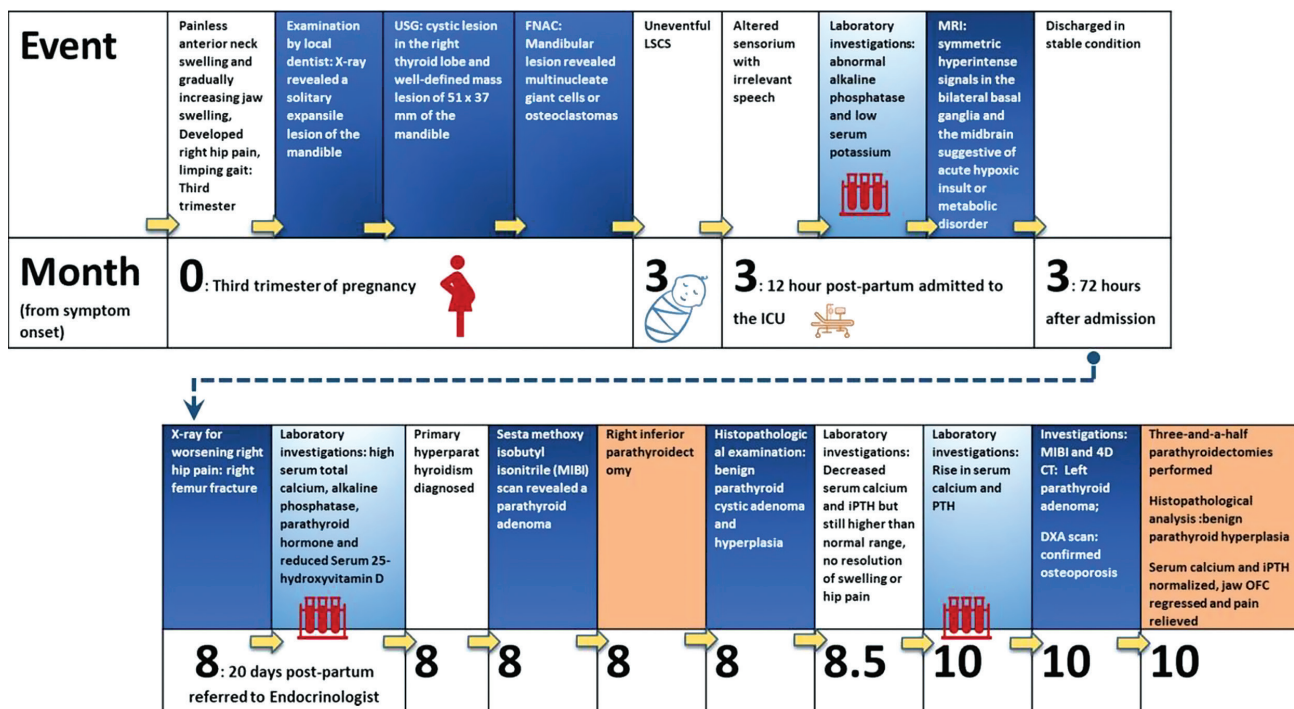


Figure 3. Timeline of events.

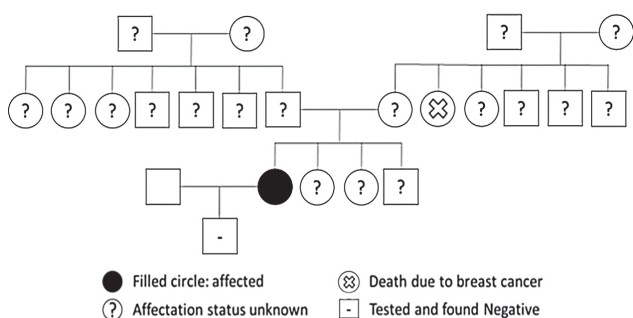


Figure 4. Family tree of the patient with CDC73 mutation.

Clinical exome sequencing revealed CDC73(+) c.687\_688dupAG heterogenous pathogenic autosomal dominant mutation.

None of her family members had a history of similar complaints suggestive of PHPT, except for the maternal aunt, who suffered breast carcinoma at 50 years, to which she succumbed (Figure 4). The CDC73 mutation predisposes the patient to breast cancer and uterine tumors. Given this association, the patient underwent mammography and pelvis USG; however, the reports did not reveal any abnormalities.

The infant was readmitted to the Neonatal Intensive Care Unit (NICU) on day 21 for convulsions. Considering the mother's recent diagnosis of PHPT, the calcium profile was obtained for the neonate, which exhibited low serum ionized calcium of 0.62 mmol/L (1.12-1.37 mmol/L) (Table 3). As per biochemical evaluation, the diagnosis of the neonate was primary hypoparathyroidism leading to hypocalcemic seizures. Calcitriol is used to correct hypocalcaemia in

transient or permanent hypoparathyroidism.<sup>11</sup> The infant required calcitriol ((initial dose, 0.40 µg/Kg/d, tapered to 0.25 µg/Kg/d) until 8 months of age, after which it was gradually tapered and stopped.

At 3 years of age, his weight was 13 kg (25<sup>th</sup> percentile), and his height was 92 cm (25<sup>th</sup> percentile at mid-parental height). He is currently asymptomatic with slight gross motor delay. Mental, fine motor and language milestones were aligned with normal growth parameters. The genetic testing of the baby for the CDC73 mutation was negative.

DISCUSSION

This case depicts a case of PHPT, a rare disease in pregnancy complicated by an expansile mandibular lesion or OFC of the jaw and femur fracture, possibly due to CDC73 mutation. Osteitis fibrosa cystica generally occurs due to severe and long-standing hyperparathyroidism.<sup>12</sup> The most common cause of PHPT in pregnancy is predominantly a single adenoma (85% of all cases), followed by primary parathyroid hyperplasia (10% of all cases), multiple adenomas (3%), and parathyroid carcinoma (2%). In our patient, multiple adenomas and hyperplasia were noted.<sup>13</sup> In western regions, where monitoring of calcium and PTH levels is more widespread, PHPT is detected at milder asymptomatic stages like in the form of osteopenia. However, in developing countries like India, PHPT remains undiagnosed until its severe manifestations, like OFC and pathologic fractures, are evident, as found in the current case. Primary hyperparathyroidism also manifests at a younger age than in Western countries, with higher levels of calcium and PTH with larger adenomas, consistent with vitamin D depletion and skeletal PTH resistance.

A previous case report of a 29-year-old female suggested that increased vitamin D and mineral requirements during pregnancy may trigger accelerated bone resorption followed by the emergence of the jaw OFC which may also be the case in our patient.<sup>12</sup>

As in our patient, the skeletal manifestations attributed to reduced BMD were remarkable in the femoral neck. Female gender has been identified as a risk factor for proximal femoral fractures.<sup>14</sup> The diagnosis of PHPT was confirmed post-partum, with investigations primarily prompted by hip pain and subsequent findings of femur fracture on the radiograph. Three-and-a-half gland parathyroidectomies were performed over 3-4 months, and pharmacological treatment resolved biochemical abnormalities and clinical manifestations. This further confirmed the diagnosis of PHPT-associated OFC since HPT-JT ossifying fibromas do not regress with parathyroidectomies. The hungry bone syndrome commonly occurs post-parathyroidectomy in those with concomitant vitamin D deficiency, as found our patient with severe PHPT and moderate vitamin D deficiency.<sup>15</sup>

Neurologic deterioration in the form of irrelevant talk and disorientation was noted in the patient twelve hours post-partum and was attributed to hypercalcemia. Neurologic deterioration due to metabolic encephalopathy secondary to hypercalcemia is known. A sudden increase in serum calcium levels results in neurological symptoms such as decreased concentration, confusion, and rarely stupor or coma. The hypercalcemic crisis is a condition characterized by decompensation of hypercalcemia and predominantly occurs in PHPT as in our patient.<sup>16</sup>

When the infant was admitted with convulsions, the evaluation suggested low serum calcium with (near normal serum phosphorus) with low 25 OH Vitamin D3 with inappropriately low serum intact PTH for 25 OH vitamin D3 and total calcium. Hence, primary hypoparathyroidism was considered as the cause of hypocalcemia rather than vitamin D deficiency. This was the likelier scenario since the mother had undiagnosed PHPT during pregnancy. Maternal hypercalcemia due to PHPT suppresses foetal PTH synthesis and alters the PTH response to post-partum hypocalcaemia in the newborn. This results in congenital neonatal hypoparathyroidism and consequent hypocalcaemia. Severe PTH suppression, therefore, can cause hypocalcaemic convulsions in the neonatal period and may persist for several weeks. In our case, the infant suffered convulsions on day 21, which persisted for 6 weeks.<sup>17</sup> Undiagnosed PHPT in the mother during pregnancy led to an absence of calcium supplementation, resulting in neonatal hypocalcaemic convulsions.<sup>18</sup> Calcitriol was prescribed to the infant (initial dose, 0.40 µg/Kg/d, tapered to 0.25 µg/Kg/d) to maintain serum calcium level in the normal range and avoid hypocalcaemia-related seizures. Convulsion resolved at 6 weeks of age and the infant completely recovered from transient congenital hypoparathyroidism by the age of eight months.

In a large case series published previously, the average calcium level of mothers at diagnosis and in those who experienced pregnancy loss was 2.85 mmol/L while in our patient, the calcium level was 3.33 mmol/L at diagnosis (post-partum) but she had a successful full-term pregnancy.<sup>19</sup> The serum calcium levels were also higher than all the patients in the case series. Moreover, she had no history of previous miscarriages, in contrast to the patients in the case series. The case series emphasized that full-term pregnancy was unlikely with serum calcium >3.0 mmol/L, but the serum calcium was 3.3 mmol/L in our patient.

Guidelines and best practices suggest parathyroidectomy for asymptomatic non-pregnant patients with calcium elevations >1 mg/dL (0.25 mmol/L) above the upper limits of normal (or >11.5 mg/dL; 2.88 mmol/L) and in pregnant females with calcium levels >11.4 mg/dL (2.85 mmol/L).<sup>19</sup> Surgery is a potential treatment option, but it has potential risks during pregnancy. It is reserved for patients in the second trimester, given the higher risk in the first (incomplete organogenesis) and third trimester (higher risk of preterm labour, >50% fetal mortality).<sup>20,21</sup> Therefore, whenever appropriate, conservative medical therapy is utilized based on the risk-benefit ratio.

Genetic testing revealed the presence of the *CDC73* nonsense mutation, a tumor suppressor gene located on chromosome 1q31. *CDC73* c.687\_688dupAG mutation results in a frameshift mutation that causes a premature translational stop signal (p.Val230Glu) or nonsense-mediated decay. The p.Val230GluTer28 variant has not been reported in the 1000 genomes and the laboratory's internal database and has a minor allele frequency of 0.0008% in the ExAC database. The observed frameshift variant (c.687\_688dupAG, p.Val230GluTer28) is rare (gnomAD-0.002%). Loss-of-function variants in the *CDC73* gene are a known mechanism of this disease. It may result in an absent or disrupted protein product.<sup>22</sup> Possibly, this female has developed PHPT as the result of a *de novo* pathogenic variant of *CDC73* since none of her family members appear to have similar signs or symptoms or may be asymptomatic. Data on the proportion of individuals with a *de novo* pathogenic variant are currently not known but the variant is not novel.<sup>23</sup> This variant has been previously reported in individuals with hyperparathyroidism-jaw-tumor syndrome and/or isolated hyperparathyroidism.<sup>24</sup> It has also been observed to segregate with disease in related individuals. Based on this evidence and according to the ACMG guidelines (PVS1, PM2, PS4, PP5), this variant has been classified as pathogenic.<sup>25</sup> Due to the predisposition to breast and uterine tumors in patients with *CDC73* mutations, the patient was advised on periodic life-long screening. Genetic testing of the child of the index patient was performed as there is a 50% chance of inheriting the pathogenic variant from the mother, but it was negative.<sup>23</sup>

The family has been counselled regarding the screening; however, it is pending. This is most probably due to

difficulties with out-of-pocket expenses owing to a lack of insurance.

## CONCLUSIONS

We present this rare diagnosis of PHPT in a pregnant woman to raise awareness among physicians about this critical differential diagnosis. In patients who exhibit swelling of the neck and jaw, thorough investigations and prompt referral are critical. Simultaneous high levels of PTH and serum calcium should raise a high index of suspicion for PHPT. Parathyroidectomy helps manage the biochemical abnormalities and regresses the jaw's OFC. Parathyroidectomy also helps in attenuating the declining BMD. Children born to mothers with PHPT should be evaluated for neonatal hypoparathyroidism and supplemented appropriately to reduce the risk of hypocalcaemic manifestations that can be life-threatening. Genetic testing in young PHPT would help strategize management for the proband as well as the family early in the disease.

## Learning Points

- In the case of altered sensorium in the peripartum period, serum calcium should be determined for early diagnosis.
- Hyperparathyroidism is a rare diagnosis, and a high index of suspicion is necessary when a patient presents with a jaw lesion. Endocrine evaluation should be performed in addition to a dental examination.
- Long-term follow-up of the child is required to determine whether he completely recovered and did not develop permanent hypoparathyroidism.

## Patient Perspective

The female patient feels satisfied with the regression of her jaw and neck swelling, which significantly altered her appearance. She is completely relieved of her bone pain. The infant is currently asymptomatic and displays normal growth. The patient feels that the correct diagnosis helped obtain appropriate treatment.

## Ethical Consideration

Patient consent was obtained before submission of the manuscript.

## Statement of Authorship

All authors certified fulfillment of ICMJE authorship criteria.

## CRedit Author Statement

**PP:** Conceptualization, Methodology, Investigation, Writing – original draft preparation, Writing – review and editing, Visualization, Project administration; **AN:** Investigation, Resources; **YC:** Formal analysis, Investigation, Data Curation, Writing – original draft preparation, Project administration; **PV:** Investigation, Writing – review and editing, Supervision; **NB:** Investigation, Resources, Supervision.

## Acknowledgment

The authors would like to thank Ms. Seema Kalel for her editorial assistance.

## Author Disclosure

The authors declared no conflict of interest.

## Data Availability Statement

No datasets were generated or analyzed for this study.

## Funding Source

None.

## References

1. Yeh MW, Ituarte PH, Zhou HC, et al. Incidence and prevalence of primary hyperparathyroidism in a racially mixed population. *J Clin Endocrinol Metab.* 2013;98(3):1122-9. PMID: 23418315 PMCID: PMC3590475 DOI: 10.1210/jc.2012-4022
2. McCarthy A, Howarth S, Khoo S, et al. Management of primary hyperparathyroidism in pregnancy: A case series. *Endocrinol Diabetes Metab Case Rep.* 2019;2019:19-0039. PMID: 31096181 PMCID: PMC6528402 DOI: 10.1530/EDM-19-0039
3. Bringham FD, Demay MB, Kronenberg HM. Chapter 28 - Hormones and disorders of mineral metabolism. *Williams textbook of endocrinology (13th ed).* 2016. DOI: 10.1016/B978-0-323-29738-7.00028-9
4. Vanitharoenkul E, Singsampun N, Unnanuntana A, et al. Osteitis fibrosa cystica and pathological fractures-the classic but neglected skeletal manifestation of primary hyperparathyroidism: A case report. *BMC Musculoskelet Disord.* 2021;22(1):443. PMID: 33990191 PMCID: PMC8122575 DOI: 10.1186/s12891-021-04326-1
5. Guerrouani A, Rzin A, El Khatib K. Hyperparathyroidism-jaw tumour syndrome detected by aggressive generalized Osteitis fibrosa cystica. *Clin Cases Miner Bone Metab.* 2013;10(1):65-7. PMID: 23858315 PMCID: PMC3710014 DOI: 10.11138/ccmbm/2013.10.1.065
6. Kalapala L, Keerthi Sai S, Babburi S, et al. An endocrine jaw lesion: Dentist perspective in diagnosis. *Case Rep Dent.* 2016;2016:2582038. PMID: 27974979 PMCID: PMC5126398 DOI: 10.1155/2016/2582038
7. Satpathy AS, Dasgupta A, Dutta C, Mohan NVK, Satpathy S. Osteitis fibrosa cystica of mandible in hyperparathyroidism-jaw tumor syndrome: A rare presentation and review of literature. *Natl J Maxillofac Surg.* 2017;8(2):162-6. PMID: 29386822 PMCID: PMC5773993 DOI: 10.4103/njms.NJMS\_48\_17
8. Naji Rad S, Deluxe L. Osteitis Fibrosa Cystica. In: *StatPearls. Treasure Island (FL): StatPearls Publishing; 2022.* <https://www.ncbi.nlm.nih.gov/books/NBK559097/>
9. Parfitt J, Harris M, Wright JM, Kalamchi S. Tumor suppressor gene mutation in a patient with a history of hyperparathyroidism-jaw tumor syndrome and healed generalized Osteitis fibrosa cystica: A case report and genetic pathophysiology review. *J Oral Maxillofac Surg.* 2015;73(1):194.e1-9. PMID: 25511968 DOI: 10.1016/j.joms.2014.09.008
10. Chapter 3 – Anesthesia. *Clinical Review of Oral and Maxillofacial Surgery (Second Edition), Mosby; 2014.* DOI: 10.1016/B978-0-323-17126-7.00003-0
11. Pillai SS, Foster CA, Ashraf AP. Approach to neonatal hypocalcemia. *Newborn* 2022;1(1):190-6. DOI: 10.5005/jp-journals-11002-0017
12. Casteràs A, Darder L, Zafon C, et al. Brown tumor of the jaw after pregnancy and lactation in a MEN1 patient. *Endocrinol Diabetes Metab Case Rep.* 2016;2016:16-0111. PMID: 27933172 PMCID: PMC5118968 DOI: 10.1530/EDM-16-0111
13. Malekar-Raikar S, Sinnott BP. Primary hyperparathyroidism in pregnancy-A rare cause of life-threatening hypercalcemia: Case report and literature review. *Case Rep Endocrinol.* 2011;2011:520516. PMID: 22937284 PMCID: PMC3420708 DOI: 10.1155/2011/520516
14. Khosla S, Melton LJ 3rd, Wermers RA, Crowson CS, O'Fallon WM, Riggs BI. Primary hyperparathyroidism and the risk of fracture: A population-based study. *J Bone Miner Res.* 1999;14(10):1700-7. PMID: 10491217 DOI: 10.1359/jbmr.1999.14.10.1700
15. Sizar O, Khare S, Goyal A, Givler A. Vitamin D deficiency. In: *StatPearls. Treasure Island (FL): StatPearls Publishing; 2022.* <https://www.ncbi.nlm.nih.gov/books/NBK532266/>
16. Singh DN, Gupta SK, Kumari N, et al. Primary hyperparathyroidism presenting as hypercalcemic crisis: Twenty-year experience. *Indian J Endocrinol Metab.* 2015;19(1):100-5. PMID: 25593835 PMCID: PMC4287752 DOI: 10.4103/2230-8210.131763
17. Mestman JH. Parathyroid disorders of pregnancy. *Semin Perinatol.* 1998;22(6):485-96. PMID: 9880118 DOI: 10.1016/s0146-0005(98)80028-1
18. Vuralli D. Clinical approach to hypocalcemia in newborn period and infancy: Who should be treated? *Int J Pediatr.* 2019;2019:4318075. PMID: 31320908 PMCID: PMC6607701 DOI: 10.1155/2019/4318075
19. Norman J, Politz D, Politz L. Hyperparathyroidism during pregnancy and the effect of rising calcium on pregnancy loss: A call for earlier intervention. *Clin Endocrinol (Oxf).* 2009;71(1):104-9. PMID: 19138316 DOI: 10.1111/j.1365-2265.2008.03495.x
20. Kokrdova Z. Pregnancy and primary hyperparathyroidism. *J Obstet Gynaecol.* 2010;30(1):57-9. PMID: 20121508 DOI: 10.3109/01443610903315611

21. Truong MT, Lalakea ML, Robbins P, et al. Primary hyperparathyroidism in pregnancy: A case series and review. *Laryngoscope*. 2008;118(11):1966-9. PMID: 18758377 DOI: 10.1097/MLG.0b013e318180276f
22. Sun W, Kuang XL, Liu YP, Tian LF, Yan XX, Zu W. Crystal structure of the N-terminal domain of human CDC73 and its implications for the hyperparathyroidism-jaw tumor (HPT-JT) syndrome. *Sci Rep*. 2017;7(1):15638. PMID: 29142233 PMCID: PMC5688130 DOI: 10.1038/s41598-017-15715-9
23. Skefos CM, Waguespak SG, Perrier ND, Hu MI. CDC73-Related Disorders. In: Adam MP, Everman DB, Mirzaa GM, et al., eds. *GeneReviews*®. Seattle (WA): University of Washington, Seattle; 1993-2022. <https://www.ncbi.nlm.nih.gov/books/NBK3789/>
24. NM\_024529.5(CDC73):c.687\_688dup(p.Val230fs). <https://www.ncbi.nlm.nih.gov/clinvar/variation/241496/#new-germline-citation>
25. Richards S, Aziz N, Bale S, et al; ACMG Laboratory Quality Assurance Committee. Standards and guidelines for the interpretation of sequence variants: A joint consensus recommendation of the American College of Medical Genetics and Genomics and the Association for Molecular Pathology. *Genet Med*. 2015;17(5):405-24. PMID: 25741868 PMCID: PMC4544753 DOI: 10.1038/gim.2015.30

Authors are required to accomplish, sign and submit scanned copies of the JAFES Author Form consisting of: (1) Authorship Certification, that authors contributed substantially to the work, that the manuscript has been read and approved by all authors, and that the requirements for authorship have been met by each author; (2) the Author Declaration, that the article represents original material that is not being considered for publication or has not been published or accepted for publication elsewhere, that the article does not infringe or violate any copyrights or intellectual property rights; that no references have been made to predatory/suspected predatory journals; and that use of artificial intelligence (AI) or AI-assisted technologies shall be declared to include the name of the AI tool or service used; (3) the Author Contribution Disclosure, which lists the specific contributions of authors; (4) the Author Publishing Agreement which retains author copyright, grants publishing and distribution rights to JAFES, and allows JAFES to apply and enforce an Attribution-Non-Commercial Creative Commons user license; and (5) the Conversion to Visual Abstracts (\* optional for original articles only) to improve dissemination to practitioners and lay readers. Authors are also required to accomplish, sign, and submit the signed ICMJE form for Disclosure of Potential Conflicts of Interest. For original articles, authors are required to submit a scanned copy of the Ethics Review Approval of their research as well as registration in trial registries as appropriate. For manuscripts reporting data from studies involving animals, authors are required to submit a scanned copy of the Institutional Animal Care and Use Committee approval. For Case Reports or Series, and Images in Endocrinology, consent forms, are required for the publication of information about patients; otherwise, appropriate ethical clearance has been obtained from the institutional review board. Articles and any other material published in the JAFES represent the work of the author(s) and should not be construed to reflect the opinions of the Editors or the Publisher.



**A new venue for publishing your original articles.**  
**Visit [www.ASEAN-endocrinejournal.org](http://www.ASEAN-endocrinejournal.org) for**  
**Instructions to Authors.**