



Case Report

Postoperative left-sided chylothorax following posterior approach in late-onset idiopathic scoliosis surgery

Jack Van-Loo, Nitin Adsul¹, Peter Loughenbury¹, Nigel William Gummerson¹

Department of Spinal Surgery, Leeds General Infirmary, Leeds, United Kingdom.

E-mail: *Jack Van-Loo - jack.van-loo1@nhs.net; Nitin Adsul - nitin.adsul@nhs.net; Peter Loughenbury - p.loughenbury@nhs.net; Nigel William Gummerson - nigel.gummerson@nhs.net



*Corresponding author:

Jack Van-Loo,
Department of Spinal Surgery,
Leeds General Infirmary, Leeds,
United Kingdom.

jack.van-loo1@nhs.net

Received: 01 October 2024

Accepted: 17 October 2024

Published: 08 November 2024

DOI

10.25259/SNI_823_2024

Quick Response Code:



ABSTRACT

Background: Chylothorax is an extremely rare complication of spinal surgery. We were only able to identify 15 previous cases overall, with only 5 involving a posterior approach.

Case Description: A 16-year-old female presented with a chylothorax following a T4–L4 posterior spinal fusion for scoliosis. Postoperatively, the patient developed respiratory distress due to a left-sided pleural effusion. Laboratory tests (i.e., both gross and laboratory analysis) documented the fluid to be chyle. The patient required the placement of a chest drain and a low triglyceride diet to manage and resolve the chylothorax successfully.

Conclusion: Chylothorax is a rare complication of spinal surgery and should be considered among the differential diagnoses involving postoperative respiratory compromise attributed to pleural effusions.

Keywords: Adolescent idiopathic scoliosis, Chylothorax, Complication, Corrective surgery, Scoliosis

INTRODUCTION

Chylothorax is a rare but potentially life-threatening complication more commonly found in anterior versus posterior thoracic spine surgery.

Chylothorax is attributed to the accumulation of chyle from the thoracic duct or its tributaries that drain into the thoracic cavity. Complications of chylothorax may include dyspnea, immune suppression, heart failure, and even death.^[2] Chylothorax is a rare complication of spinal surgery, and few cases are reported in the literature [Table 1].^[9] Here, a 16-year-old female with idiopathic scoliosis following a T4–L4 fusion developed a postoperative chylothorax.

CASE REPORT

A 16-year-old female with idiopathic scoliosis (Lenke 6) underwent a posterior spinal instrumented fusion (T4–L4) [Figure 1]. Three days later, she developed acute respiratory distress. The chest X-ray and chest computed tomography (CT) with contrast (CT pulmonary angiogram) revealed a large left-sided and a smaller right-sided pleural effusion(s) associated with atelectasis [Figure 2].

When a chest tube was placed, it revealed a milky fluid and laboratory studies confirmed that it was a chylothorax (triglycerides 5.0 mmol/L, glucose 6.1 mmol/L, lactate dehydrogenase

This is an open-access article distributed under the terms of the Creative Commons Attribution-Non Commercial-Share Alike 4.0 License, which allows others to remix, transform, and build upon the work non-commercially, as long as the author is credited and the new creations are licensed under the identical terms.

©2024 Published by Scientific Scholar on behalf of Surgical Neurology International

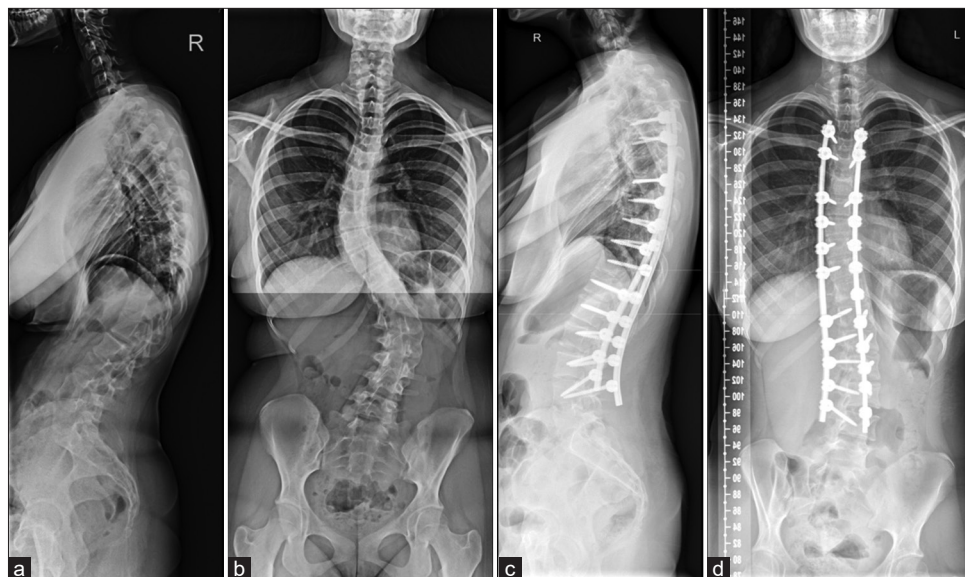


Figure 1: (a) Lateral view of the spine before correction. (b) Anteroposterior view of the spine before correction. (c) Lateral view of the spine after correction. (d) Anteroposterior view of the spine after correction.

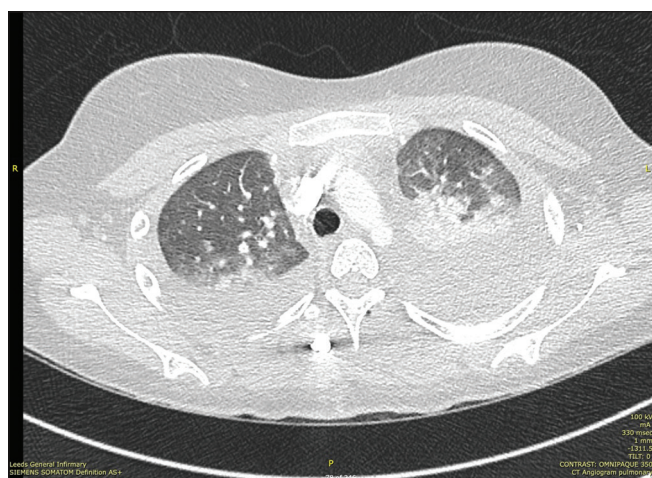

Figure 2: Computed tomography pulmonary angiogram 3-day postprocedure showing left-sided pleural effusion.

204 IU/L, and protein <20 g/L) [Figure 3]. The patient was placed on a low, long-chain triglyceride diet. The drain was later removed, and the patient was discharged without further incident 12 days postprocedure. Six weeks later, she resumed a normal diet, and there were no further adverse events.

DISCUSSION

Incidence and diagnostic confirmation of chylothorax

Chylothorax, usually unilateral, accounts for between 2% and 3% of all pleural effusions. Approximately half of cases are due to trauma versus malignancy [Table 2].^[7] Here, the thoracic duct was likely damaged during the pedicle probe or



Figure 3: Chyle fluid from left-sided chest drain.

screw insertion during the T4–L4 instrumented spinal fusion. The presence of chyle was confirmed both by the typical opaque/milky secretions collected from the chest drain and laboratory analysis of the pleural fluid (i.e., triglyceride >110 mg/dL and cholesterol <200 mg/dL). In addition, the presence of cholesterol crystals and chylomicrons can be used to confirm the diagnosis.^[5]

Conservative management

Early dietary intervention (i.e., to reduce the volume of chyle produced in the lymphatic system) is often sufficient to resolve traumatic chylothorax.^[8] Dietary regimens aim for <3% long-chain triglycerides. It is important to continue

Table 1: Reports of chylothorax after posterior approach spinal surgery.

Case	Age	Sex	Approach	Fusion	Pleural Effusion	Treatment	Reference
1	11	M	Post	T3-L2	R	Drainage	[4]
2	40	F	Post	T3-L2	R	Drainage	[4]
3	16	F	Post	T3-L1	R	Drainage, TPN	[6]
4	18	F	Post	T3-T12	L	Drainage, TPN, Operation	[11]
5	64	F	Post	T8-S2, L3-L5	R	Drainage, Octreotide, TPN	[9]
Present Case	16	F	Post	T4-L4	L	Drainage	

Table 2: Etiologies of chylothorax.

Traumatic	Vertebral fractures, penetrating trauma, sudden spinal hyperextension, increase in thoracic pressure secondary to closed trauma, iatrogenic
Malignancy	Non-Hodgkin's lymphoma, thyroid cancer, Kaposi sarcoma, oesophageal cancer
Congenital Duct Abnormalities	Congenital thoracic duct atresia or absence
Infections	Histoplasmosis, filiaris, tuberculosis
Systemic Disorders	Behcet's disease, systemic lupus erythematosus, amyloidosis, sarcoidosis ^[10]
Miscellaneous	Congestive heart failure, cirrhosis, retrosternal goitre, mediastinal lymph node enlargement
Idiopathic	Approximately 9% of non-traumatic cases

Table 3: Chylothorax management options.

Conservative/Medical	Surgical	Interventional Radiology
Pleural drainage	Thoracic duct ligation (Open/VATS)	Thoracic duct embolization (TDE)
Dietary modifications	Decortication/Debridement of multi-loculated collections	Thoracic duct disruption (TDD)
Somatostatin analogue (Octreotide)	Pleurodesis	
Treatment of underlying condition	Pleurectomy	

drainage of the thoracic chyle and to support a low long-chain triglyceride dietary regimen.

Medical therapy for chylothorax

Medical therapy such as octreotide, a somatostatin analog, has been used both as a continuous infusion and as a bolus to reduce the production of lymph; it reduces the splanchnic circulation and the secretions from the gastrointestinal tract.^[8]

Surgery for chylothorax

Surgery for evacuation of chyle should be considered when drainage exceeds 500 mL/day for 5 days. Surgical options to treat chylothorax include thoracic duct ligation, pleurodesis, and pleurectomy.^[1] Notably, thoracoscopy versus open thoracotomy appears equally effective. Further, operative interventions are more effective for treating traumatic (i.e., resulting in lower rates of recurrence) versus nontraumatic chylothorax [Table 3].^[3]

CONCLUSION

While extremely rare, chylothorax constitutes a serious complication of instrumented typically thoracic or lower cervical/thoracic spinal fusion surgery. To confirm the diagnosis, laboratory analysis should be performed, and conservative medical, and/or surgical management instituted.

Ethical approval

Institutional Review Board approval is not required.

Declaration of patient consent

The authors certify that they have obtained all appropriate patient consent.

Financial support and sponsorship

Nil.

Conflicts of interest

There are no conflicts of interest.

Use of artificial intelligence (AI)-assisted technology for manuscript preparation

The authors confirm that there was no use of artificial intelligence (AI)-assisted technology for assisting in the writing or editing of the manuscript and no images were manipulated using AI.

REFERENCES

1. Browse NL, Allen DR, Wilson NM. Management of chylothorax. *Br J Surg* 1997;84:1711-6.
2. Lai FC, Chen L, Tu YR, Lin M, Li X. Prevention of chylothorax complicating extensive esophageal resection by mass ligation of thoracic duct: A random control study. *Ann Thorac Surg* 2011;91:1770-74.
3. Maldonado F, Cartin-Ceba R, Hawkins FJ, Ryu JH. Medical and surgical management of chylothorax and associated outcomes. *Am J Med Sci* 2010;339:314-8.
4. Nakai S, Zielke K. Chylothorax—a rare complication after anterior and posterior spinal correction. Report on six cases. *Spine* 1986;11:830-3.
5. Pakula AM, Phillips W, Skinner RA. A case of a traumatic chyle leak following an acute thoracic spine injury: Successful resolution with strict dietary manipulation. *World J Emerg Surg* 2011;6:10.
6. Rames RD, Schoenecker PL, Bridwell KH. Chylothorax after posterior spinal instrumentation and fusion. *Clin Orthop Relat Res* 1990;261:229-32.
7. Ryu JH, Tomassetti S, Maldonado F. Update on uncommon pleural effusions. *Respirology* 2011;16:238-43.
8. Schild HH, Strassburg CP, Welz A, Kalf J. Treatment options in patients with chylothorax. *Dtsch Arztebl Int* 2013;110: 819-26.
9. Toriyama K, Kokuho N, Yajima C, Kawagoe J, Togashi Y, Tsuji T, *et al.* Chylothorax after spinal fusion surgery: A case report and literature review. *Respir Med Case Rep* 2019;26:260-64.
10. Ur Rehman K, Sivakumar P. Non-traumatic chylothorax: Diagnostic and therapeutic strategies. *Breathe (Sheff)* 2022;18:210163.
11. Weening AA, Schurink B, Ruurda JP, van Hillegersberg R, Bleys R, Kruyt MC. Chyluria and chylothorax after posterior selective fusion for adolescent idiopathic scoliosis. *Eur Spine J* 2018;27:2088-92.

How to cite this article: Van-Loo J, Adsul N, Loughenbury P, Gummerson NW. Postoperative left-sided chylothorax following posterior approach in late-onset idiopathic scoliosis surgery. *Surg Neurol Int.* 2024;15:408. doi: 10.25259/SNI_823_2024

Disclaimer

The views and opinions expressed in this article are those of the authors and do not necessarily reflect the official policy or position of the Journal or its management. The information contained in this article should not be considered to be medical advice; patients should consult their own physicians for advice as to their specific medical needs.