

ERRATUM

---

# ERRATUM: The role of oestrogen receptor $\alpha$ in human thyroid cancer: contributions from coregulatory proteins and the tyrosine kinase receptor HER2

Dara O Kavanagh<sup>1</sup>, Marie McIlroy<sup>1,2</sup>, Eddie Myers<sup>1</sup>, Fiona Bane<sup>2</sup>, Thomas B Crotty<sup>1</sup>, E McDermott<sup>1</sup>, Arnold D Hill<sup>1,2</sup> and Leonie S Young<sup>1,2</sup>

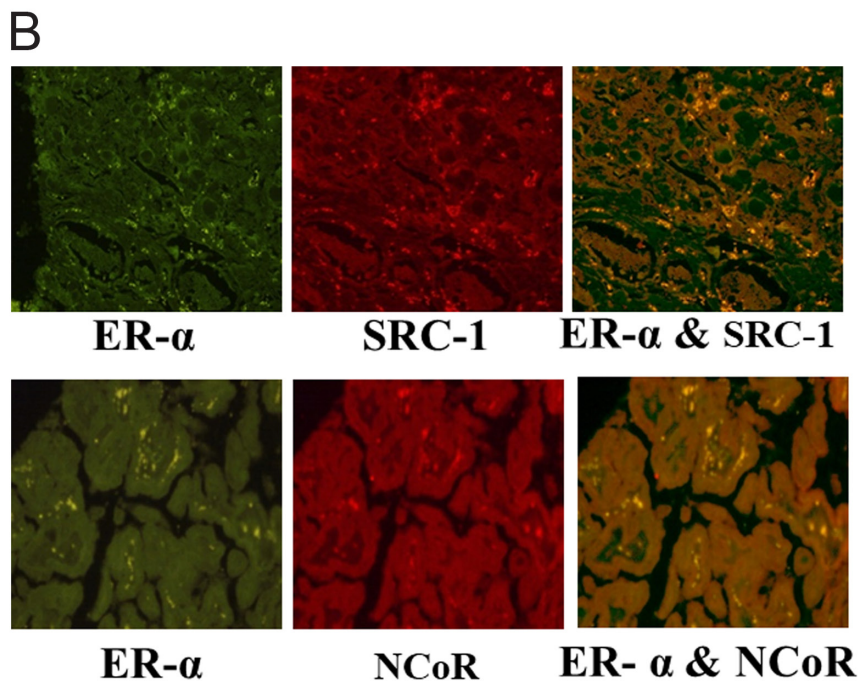
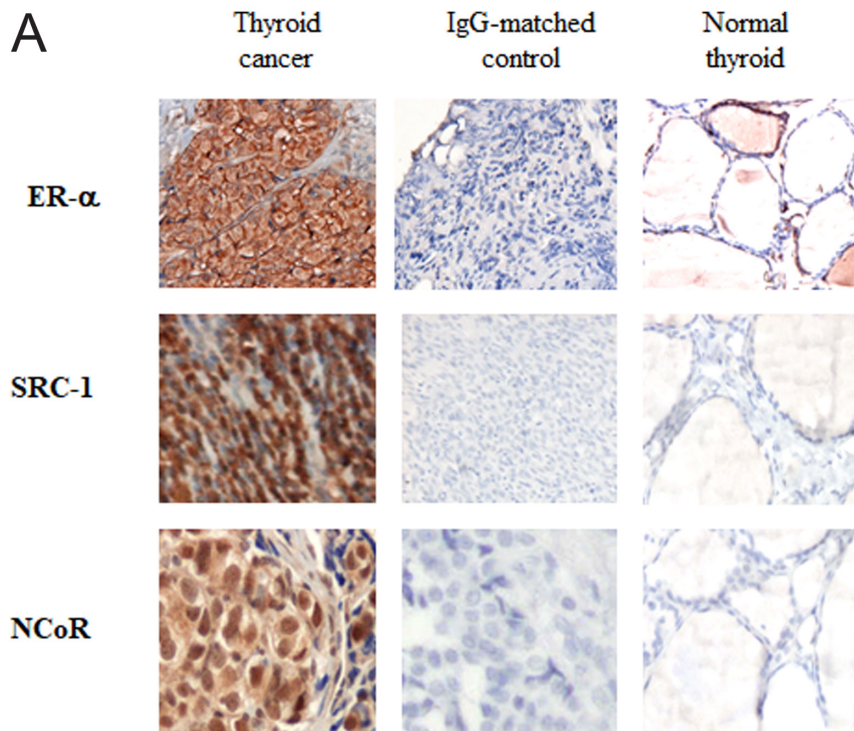
<sup>1</sup>School of Medicine and Medical Science, UCD Conway Institute, St Vincent's University Hospital and University College Dublin, Dublin, Ireland

<sup>2</sup>Endocrine Oncology Research Group, Department of Surgery, Royal College of Surgeons in Ireland, St Stephens Green, Dublin, Ireland

Correspondence should be addressed to L S Young: [lyoung@rcsi.ie](mailto:lyoung@rcsi.ie)

---

The authors and journal apologise for an error in the above paper, which appeared in volume 17 part 1, pages 255–264. The error relates to [Fig. 2B](#) given on page 260, in which incorrect immunofluorescent images of breast tumour histology were submitted in error. The corrected figure artwork, including the correct thyroid cancer images, is given below:



**Figure 2**  
(A) Immunohistochemical localisation of ER $\alpha$ , SRC-1 and NCoR counterstained with haematoxylin and matched IgG-negative controls in human thyroid cancer (200 $\times$ ) and normal thyroid (200 $\times$ ). (B) Immunofluorescent colocalisation of ER $\alpha$  with SRC-1 and NCoR in human thyroid cancer.