

# Resolution of paraneoplastic palmoplantar keratoderma after treating mixed serous neuroendocrine tumor of the pancreas: a case report and literature review

Hend M. Alotaibi, Abdulrahman Alluhaybi, Khalid Nabil Nagshabandi, Maha M. Barakeh

Department of Dermatology, College of Medicine, King Saud University, Riyadh, Saudi Arabia

## Abstract

Palmoplantar keratodermas (PPKs), also known as ‘keratosis palmaris et plantaris’, are a heterogeneous group of disorders characterized by abnormal thickening of the epidermal skin of the palms and soles leading to hyperkeratosis. It could be acquired or hereditary. Acquired PPK often occurs as a paraneoplastic syndrome as well as a stigma of other dermatoses. We report a rare case of paraneoplastic PPK secondary to mixed neuroendocrine tumor of the pancreas with complete remission after surgical excision of the cancer.

Correspondence: Khalid Nabil Nagshabandi, Department of Dermatology, College of Medicine, King Saud University, Riyadh, Saudi Arabia.  
E-mail: khaloed23@gmail.com

Key words: palmoplantar keratodermas; keratosis palmaris et plantaris; tumor.

Conflict of interest: the authors declare no potential conflict of interest.

Availability of data and materials: all data underlying the findings are fully available.

Ethics approval and consent to participate: No ethical committee approval was required for this case report by the Department, because this article does not contain any studies with human participants or animals. Informed consent was obtained from the patient included in this study.

Consent for publication: written consent was obtained from the patients to publish their case details and clinical photographs.

Received: 5 December 2023.

Accepted: 12 January 2024..

This work is licensed under a Creative Commons Attribution-NonCommercial 4.0 International License (CC BY-NC 4.0).

©Copyright: the Author(s), 2024  
Licensee PAGEPress, Italy  
Dermatology Reports 2024; 16:9906  
doi:10.4081/dr.2024.9906

*Publisher's note: all claims expressed in this article are solely those of the authors and do not necessarily represent those of their affiliated organizations, or those of the publisher, the editors and the reviewers. Any product that may be evaluated in this article or claim that may be made by its manufacturer is not guaranteed or endorsed by the publisher.*

## Introduction

Palmoplantar keratodermas (PPKs), also known as ‘keratosis palmaris et plantaris’, are a diverse group of disorders characterized by abnormal thickening of the epidermal skin on the palms of the hands and soles of the feet caused by excessive keratin leading to hyperkeratosis.<sup>1</sup> They can be classified as either acquired or hereditary, and further classified as diffuse (affect most of the palms and soles), focal (affect pressure areas) and punctate type (small round bumps on the palms and soles).<sup>2</sup> Acquired PPK can be linked to a broad list of cutaneous conditions such as lichen planus, psoriasis, contact dermatitis, pityriasis rubra pilaris and internal malignancy. Cancer association may either be a paraneoplastic syndrome or malignancy predisposition.<sup>2,3</sup> Paraneoplastic palmoplantar keratoderma or (PPPK) is an acquired dermatosis that is associated with internal malignancy such as esophageal, bronchial, lung, breast, urinary bladder, gastric, colon, skin cancer and myeloma.<sup>3</sup> PPPK is considered a paraneoplastic syndrome, indicating its close association with an underlying malignancy rather than a direct result of the tumor itself. Tripe palms is a similar clinically unique paraneoplastic type of keratoderma that only affects the palms of the hands. This keratoderma is clinically characterized by excessive dermatoglyphics on the palmar surface of the hands and fingers and has a thickened, moss-like, or velvety texture. It can present with or without acanthosis nigricans, and more than 90% of cases an internal malignancy is found.<sup>4</sup> To the best of our knowledge, only two cases reported tripe palms in association with an underlying pancreatic cancer.<sup>5,6</sup> And only one case in the literature documented plantar keratoderma in a patient with pancreatic adenocarcinoma.<sup>7</sup> We report a rare case of paraneoplastic PPK secondary to mixed neuroendocrine tumor of the pancreas resolved after surgically removing the cancer.

## Case Report

A 60-year old Saudi woman, with no known history of chronic illness, presented to the dermatology outpatient clinic with diffuse thickening of the palms and soles with associated pain, itchiness and dry skin for the past three years. Cutaneous exam revealed hyperkeratosis and fissuring of the palms and soles with mild scaling (Figure 1). Other than her skin complaints the patient was asymptomatic and did not suffer from anything upon systematic review. Punch biopsy of the foot was taken showing mild epidermolytic hyperkeratosis, with minimal lymphocytic infiltrate in the epidermis and perivascular inflammation in the upper dermis with no signs of atypia. Upon immunohistochemical stain, the lymphocytes were positive for CD3 and showed a mixture of CD4 and CD8 phenotype and 50% of the lymphocytes were CD7 positive. Periodic acid–Schiff (PAS) stain was negative for fungal

elements. She was prescribed emollients, topical salicylic acid-urea and topical mometasone cream for the itchy lesions with no improvement. The lesions progressed in severity over the past year and were refractory to multiple courses of therapy.

Due to her advanced age, recalcitrant PPK and positive family history of malignancy, a clinical differential diagnosis of acquired palmoplantar keratoderma (PPK) secondary to internal malignancy or paraneoplastic palmoplantar keratoderma (PPPK) was made. The patient was immediately booked for investigations to rule out cancer. Laboratory investigations were all normal except for high total bilirubin. Abdominal ultrasound, chest x-ray, upper endoscopy and colonoscopy were normal. Tumor marker levels such as cancer antigen 19-9 (CA19-9) and cancer antigen 125 (CA125) were within normal limits, but carcinoembryonic antigen (CEA) was elevated. CT of the abdomen revealed an incidental pancreatic body complex cystic lesion (Figure 2). The image demonstrates homogeneous enhancement with focal cystic lesion seen in the pancreatic body, measuring 2.1 x 3.3 x 3.1 cm in anterior-posterior, transverse and cranio-caudal dimensions

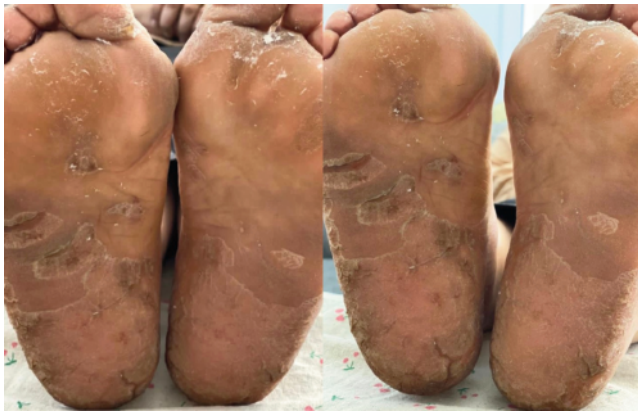

Figure 1. Hyperkeratosis of the soles before cancer excision.

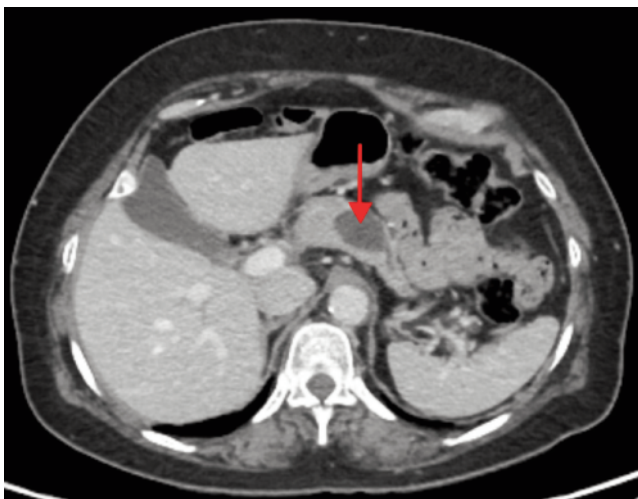

Figure 2. CT scan of abdomen transverse section (red arrow): a cystic pancreatic body mass.

respectively. The cystic lesion demonstrated multiple mildly thickened septations in its superior aspect, with no obvious solid nodules. The mass appeared to be communicating with the main pancreatic duct, with mildly dilated pancreatic duct distal to the lesion. No abdominopelvic metastasis was noted. The differential of side branch intraductal papillary mucinous neoplasm and

Table 1. Cases of keratoderma associated with pancreatic mass.

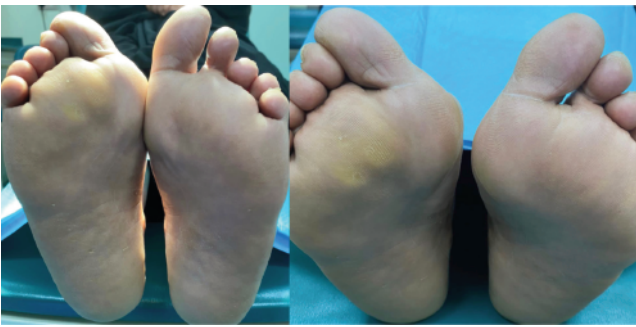
Study name	Year	Age (years)	Gender	Manifestations	Systematic review	Internal malignancies	Treatment
McGinness J et al.	2006	81	Female	Diffuse verrucous papillomatous papules and plaques on her upper and lower vermillion, buccal mucosa, and tongue consistent with oral mucous membrane malignant acanthosis nigricans palms showed accentuation of the dermatoglyphics bilaterally, consistent with tripe palms	Weight loss Gastrointestinal upset	Pancreatic adenocarcinoma	Gemetabine
Ulla JI, et al.	2007	76	Female	Plantar keratotic lesions	Back pain	Pancreatic adenocarcinoma	Distal pancreatectomy
Barman B et al.	2019	50	Male	Hyperpigmentation with thickening of the skin of the face, neck, hands, and feet	Recurrent abdominal pain radiates to back Generalised weakness	Advanced pancreatic adenocarcinoma	Systemic chemotherapy
Alonah HM et al. (our case)	2023	60	Female	Diffuse thickening of the palms and soles with associated pain, itchiness and dry skin	Family history of malignancy	Mixed Neuroendocrine Tumor of the Pancreas	Distal pancreatectomy and splenectomy

mucinous cystic neoplasm was kept. The patient was then referred to general surgery under the hepatobiliary division and underwent an urgent distal pancreatectomy and splenectomy a week after. The mass was excised and was sent to pathology for histologic assessment, the diagnosis of mixed serous cystadenoma and neuroendocrine neoplasm (mixed serous neuroendocrine tumor) of the pancreas was confirmed. Days after undergoing surgery, the skin showed resolution of the palmoplantar keratoderma (Figure 3). Nearly two years after cancer excision, follow-up cutaneous

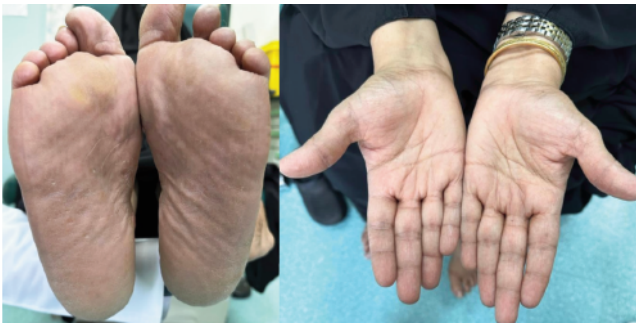examination of the palms and soles showed signs of complete clinical remission (Figure 4). MRI of the abdomen was done, the remaining pancreas revealed normal signal intensity and homogenous enhancement with no suspicious focal lesions and no evidence of any local recurrence (Figure 5).

### Discussion

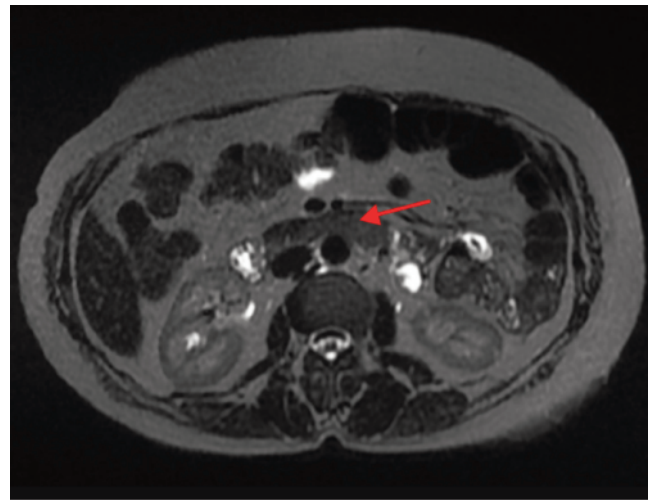
Paraneoplastic palmoplantar keratoderma (PPK) is a rare skin disorder that usually presents with underlying malignant neoplasms. It has been reported to be associated with malignancies of various internal organs. The most common associated neoplasms are pulmonary and gastrointestinal tract.<sup>8</sup> PPK is characterized by thickened, scaly plaques on the palms and soles accompanied by other cutaneous manifestations.<sup>1</sup> In one study, tripe palm was observed to occur with acanthosis nigricans in 77% of the cases, and alone in 23%.<sup>9</sup> Although more than 90%



**Figure 3.** Complete resolution of skin lesions few days after surgical excision of tumor

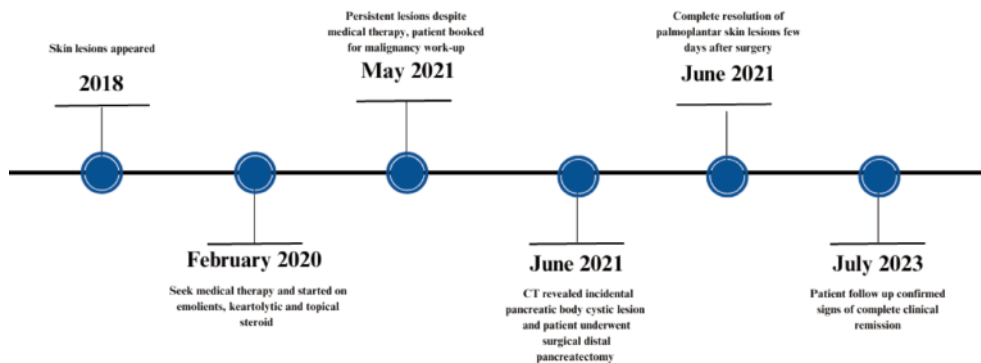


**Figure 4.** Follow-up two years after cancer excision showing complete clinical remission of palmoplantar lesions.



**Figure 5.** MRI of the abdomen transverse section (red arrow): remaining pancreas showing normal signal intensity and homogenous enhancement with no evidence of any local recurrence and no suspicious focal lesions.

#### Case timeline of events



**Figure 6.** Case timeline of events



of tripe palms occurred in patients with cancer, some patients present without cancer, making the diagnosis more challenging.<sup>9</sup> The underlying pathogenesis is unknown, yet it has been hypothesized that PPK is associated with the upregulation of keratinocyte growth factors and cytokines, which are stimulated by tumor-associated antigens.<sup>6,10</sup> The skin manifestations worsen with disease progression, giving an insight into the patient's disease status, and may represent an early sign of cancer before the actual diagnosis.<sup>7</sup> Serous cystic neoplasm (SCN) of the pancreas is a rare benign growth that represents only 1-2% of all pancreatic tumors.<sup>11</sup> One of its subtypes is mixed serous neuroendocrine neoplasm (MSNN), which is a tumor that is composed of 2 distinct components with different pathologies, and has more cancerous potential than SCN alone.<sup>12,13</sup> MSNN is more predominant in females with a female to male ratio 19:3, and patients' ages range between 25-78.<sup>13</sup> Patients can be asymptomatic, nevertheless, clinical features may include abdominal pain most commonly, followed by nausea/vomiting, weight loss, jaundice and melena.<sup>13</sup> Tumors in asymptomatic patients are detected incidentally when imaging is done for other purposes. As it is challenging to differentiate MSNN preoperatively from neuroendocrine neoplasm or adenocarcinomas, pathological evaluation of the specimen is used to establish the diagnosis postoperatively.<sup>14</sup> There is no standardized approach for treatment; therefore, surgical resection is the treatment of choice, and recommended for symptomatic patients with low surgical risks<sup>11</sup> with an overall 5-year survival rate of 40%.<sup>14</sup> The Dermatology Life Quality Index (DLQI) is a questionnaire used to measure the impact of skin diseases on the quality of life of the patient. We have utilized this tool to assess the impact of PPK on the patients quality of life before and after pancreatic cancer excision. The case showed a score of 19 out of 30 (very large effect on patient's quality of life) before surgery, in comparison to a score of 0 out of 30 (no effect at all on patient's life) after the surgery. Surgical management of the pancreatic mass and subsequent cutaneous remission resulted in marked clinical and psychosocial improvement.

Our comprehensive review has meticulously summarized instances of keratoderma linked to internal pancreatic masses, as detailed in (Table 1). In conjunction with our findings, a total of four cases involving keratoderma and pancreatic tumors were identified.<sup>5-7</sup> Two of which were involving tripe palms and associated acanthosis nigricans were documented, with one instance each of isolated plantar keratoderma and palmoplantar keratoderma (PPK). The cases encompassed three females and one male, resulting in a male-to-female ratio of {1:3}, and the age at diagnosis spanned from (50 - 81) years of age. Three cases were associated with pancreatic adenocarcinoma, while our case presented a unique manifestation with the development of a mixed serous neuroendocrine tumor of the pancreas. Surgical intervention, specifically distal pancreatectomy, was employed in two cases, whereas chemotherapy served as the primary management approach in the remaining two instances. Despite the absence of symptoms and other indications of cancer, our patient's advanced age and resistance to treatment raised concerns and necessitated further investigation. Therefore, it is crucial to investigate malignancy and perform a comprehensive cancer evaluation in elderly patients who present with PPK that does not respond to treatment, as it can be the first indicator of the cancer and can occur months before its diagnosis. Timely diagnosis and treatment of the internal tumor not only address the primary disease but also result in the improvement or complete resolution of the associated dermatological symptoms.

## Conclusions

The resolution of paraneoplastic palmoplantar keratoderma after the treatment of an internal tumor highlights the close association between cutaneous manifestations and underlying malignancies. Palmoplantar keratoderma is an uncommon skin condition that can be triggered by an occult malignancy. Its presence should prompt thorough investigation to identify any underlying tumors in suspected patients. This case draws attention to acquired palmoplantar keratodermas that occur in the elderly and do not respond to therapy. As clinicians become more aware of the potential association between cutaneous findings and underlying malignancies, early detection and intervention in paraneoplastic conditions like palmoplantar keratoderma can lead to improved patient outcomes.

## References

1. Arnold HL. "Andrews' diseases of the skin: clinical dermatology". (No Title) (1990).
2. Kelsell DP, Stevens HP. The palmoplantar keratodermas: much more than palms and soles. *Mol Med Today*. 1999;5:107-13.
3. Patel S, Zirwas M, English JC 3rd. Acquired palmoplantar keratoderma. *Am J Clin Dermatol*. 2007;8:1-11.
4. Cohen PR, Grossman ME, Almeida L, Kurzrock R. Tripe palms and malignancy. *J Clin Oncol*. 1989;7:669-78.
5. Barman B, Devi LP, Thakur BK, Raphael V. Tripe Palms and Acanthosis Nigricans: A Clue for Diagnosis of Advanced Pancreatic Adenocarcinoma. *Indian Dermatol Online J*. 2019;10:453-455.
6. McGinness J, Greer K. Malignant acanthosis nigricans and tripe palms associated with pancreatic adenocarcinoma. *Cutis*. 2006;78:37-40.
7. Ulla JL, Garcia-Doval I, Posada C, et al. Plantar keratoderma as a presenting sign of pancreatic adenocarcinoma. *J Clin Ultrasound*. 2008;36:108-9.
8. Pentenero M, Carrozzo M, Pagano M, Gandolfo S. Oral acanthosis nigricans, tripe palms and sign of Leser-trélat in a patient with gastric adenocarcinoma. *Int J Dermatol*. 2004;43:530-2.
9. Cohen PR, Grossman ME, Almeida L, Kurzrock R. Tripe palms and malignancy. *J Clin Oncol*. 1989;7:669-78.
10. Jiang Y, Tsoi LC, Billi AC, et al. Cytokines: the diverse contribution of keratinocytes to immune responses in skin. *JCI Insight*. 2020;5:e142067.
11. Brugge WR, Lauwers GY, Sahani D, et al. Cystic neoplasms of the pancreas. *N Engl J Med*. 2004;351:1218-26.
12. Zhang Z, Liu L, Li Y, et al. Therapeutic experience of a pancreatic mixed serous neuroendocrine neoplasm invading peripancreatic vessels: A case report. *Medicine (Baltimore)*. 2022;101:e30323.
13. Li Y, Dai M, Chang X, et al. Mixed serous neuroendocrine neoplasm of the pancreas: Case report and literature review. *Medicine (Baltimore)*. 2016;95:e4205.
14. Nießen A, Schimmack S, Weber TF, et al. Presentation and outcome of mixed neuroendocrine non-neuroendocrine neoplasms of the pancreas. *Pancreatol*. 2021;21:224-235.