

# Oncoplastic Breast-Conserving Surgery for Upper Inner Quadrant Breast Cancer Using Pedicled Pectoralis Major Myofascial Flap

Jie Jie Hu<sup>1,\*</sup>, Chengdong Qin<sup>1,\*</sup>, Siyuan Liu<sup>1,2</sup>, Meizhen Zhu<sup>1</sup>, Xianghou Xia<sup>1</sup>, Chenlu Liang<sup>1</sup>, Jiefei Mao<sup>1</sup>, Fanrong Zhang<sup>1</sup>, Yang Yu<sup>1</sup>

<sup>1</sup>Breast Cancer Department, Zhejiang Cancer Hospital, Hangzhou Institute of Medicine (HIM), Chinese Academy of Sciences, Hangzhou, Zhejiang, 310022, People's Republic of China; <sup>2</sup>Postgraduate Training Base Alliance of Wenzhou Medical University, Hangzhou, Zhejiang, 310022, People's Republic of China

\*These authors contributed equally to this work

Correspondence: Yang Yu, Breast Cancer Department, Zhejiang Cancer Hospital, Hangzhou Institute of Medicine (HIM), Chinese Academy of Sciences, Hangzhou, Zhejiang, 310022, People's Republic of China, Email yuyangkaiyu@163.com

**Background:** Oncoplastic breast-conserving surgery (OBCS) has emerged as a pivotal approach in the management of breast cancer, ensuring both oncological safety and aesthetic outcomes. However, challenges persist, particularly in upper inner quadrant (UIQ) tumors, where achieving satisfactory cosmetic results while preserving oncological integrity remains intricate.

**Methods:** 15 patients with UIQ breast cancer received OBCS using a pedicled pectoralis major myofascial flap (PMMF). All medical records, preoperative imaging findings, and post-operative data were gathered retrospectively.

**Results:** This study showed good cosmetic outcomes after OBCS of the upper inner pole and the patients were satisfied with the results. There were no recurrences or metastases in any of the patients.

**Conclusion:** PMMF as a technique is reliable blood supply, easy to master, no need for additional incision, and minimal surgical trauma and functional impact.

**Keywords:** breast-conserving surgery, upper inner quadrant, breast cancer, pedicled pectoralis major myofascial flap

## Background

Breast-conserving surgery (BCS) has become a standard procedure for early-stage breast cancer with good local control and satisfying cosmetic results.<sup>1,2</sup> Several randomized studies have demonstrated that BCS has an overall survival rate equivalent to that of mastectomy. The cosmetic outcome of the breast after BCS is associated with several factors, such as the size and location of the tumor, and the ratio of breast volume excised. Poor cosmetic results are not uncommon and occur more frequently with large tumors relative to the size of the breast or unfavorable tumor location, especially in the “no man’s land” UIQ.<sup>3</sup>

Particular caution is needed when considering BCS for lesions in the UIQ of the breast. A wide excision in this location can have a significant impact on the overall quality of the breast shape by distorting the visible breast line.

OBCS combines surgical oncology principles with plastic surgery to achieve a desirable esthetic result while maintaining a low cancer recurrence rate.<sup>4</sup> OBCS has become a growing option for breast cancer treatment and forms a part of breast-conserving therapy (BCT).<sup>5</sup> It is a solution to correct the cosmetic defect from BCS.<sup>6</sup> This surgical technique’s primary advantage is the increased distance of the resection margin and the improved outcome. OBCS incorporated an oncologic partial mastectomy with ipsilateral defect repair using volume displacement or volume replacement techniques with contralateral symmetry surgery as appropriate.<sup>7</sup> Surgeons have proposed many methods, many of which are specific to the tumor’s location within the breast.<sup>8,9</sup> However, tumors located in the UIQ remain a significant challenge for surgeons because there is no insufficient amount of available mammary tissue in this area. The breast’s UIQ plays a crucial role in the upper curve shape and its inner contour. The mobilization of residual mammary tissue cannot provide satisfactory esthetic results.

Even with the help of oncoplastic techniques, it is less effective and provides poor esthetic outcomes. Previous approaches have many disadvantages to prior methods, such as local depression deformities, donor site damage, or noticeable long scars. To overcome these limitations, we seek an effective way to correct the defects.

The pectoralis major muscle is in an ideal position for breast reconstruction. It situates just under the breast, and we can easily access it from the same breast incision. After we carry out a lumpectomy, we can harvest the PMMF to fill the defect using the same incision. Herein we introduce a new volume displacement technique to correct the defect after the UIQ tumor was resected with a pedicled pectoralis major muscle myofascial flap.

## Methods

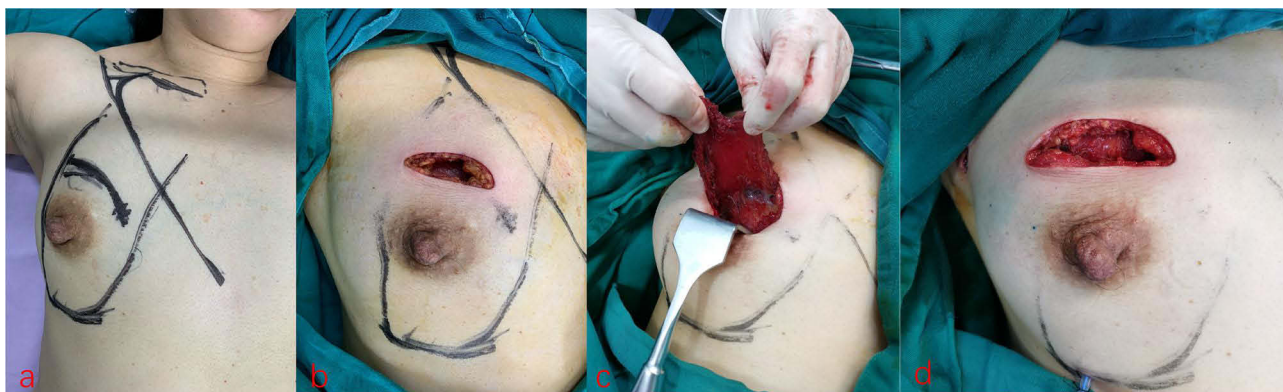### Patients

Between September 2017 and October 2022, 15 patients with UIQ breast cancer received OBCS using PMMF. All medical records, preoperative imaging findings, and post-operative data were gathered retrospectively.

### Technique

All the patients received a thorough evaluation before surgery, which may include imaging tests (mammography, ultrasound, MRI) to identify the size and location of the tumor. When determining if a patient was a good candidate for oncoplastic surgery, considerations such as breast size, tumor size, and patient preferences were taken into account. Under general anesthesia, the patient was placed in a supine position with arms abducted at an angle of 90°. After determining the location of the tumor, a curving skin incision was designed (Figure 1a). The tumor was removed with at least 1cm margins for oncologic safety (Figure 1b). Intraoperative frozen section analyses were performed to verify that the margins were cancer-free. If the results showed positive findings, additional breast tissue was removed. Then titanium pins were inserted into the tumor cavity to delineate the extent of the tumor. After the lumpectomy was carried out, using the same incision, according to the extent of the defect, the PMMF was harvested based on the pectoral branches of thoracocromial pedicle replying on a board pedicle (Figure 1c). In order to avoid muscle atrophy, the pectoralis muscle fascia was retained during the harvest of the muscle to form a myofascial flap. The myofascial flap was folded and sutured to itself to fill the defect (Figure 1d). One drain was placed to remove excess fluid from the surgical site and promote healing. The surgical incision was closed with sutures. A sentinel lymph node biopsy or axillary lymph node dissection was performed through an arc axillary incision, depending on the axillary lymph node status.

All patients received the standard protocols for systemic therapy. All of them received radiotherapy after surgery. And they were followed up regularly for oncological safety and cosmetic results from multiple dimensions such as post-operative appearance, feel, cup size changes, and quality of life.



**Figure 1** Conditions for oncoplastic surgery. (a) curving skin incision and positions of patients; (b) tumor margins for oncologic safety; (c) the detection of thoracic-acromion pedicle; (d) the myofascial flap after folded.

## Results

The mean age of the patients was 45.73 years (range: 36 to 63 years old) (Table 1). Most of the Clinical mean tumor sizes were less than 5 cm. Only one tumor was larger than 5cm. The longest follow-up has been 6 years and the least for 12 months. There was no serious feedback on dissatisfaction with the surgical results. This study showed good cosmetic outcomes after OBCS of the upper inner pole and the patients were satisfied with the results. (Figure 2). There were no recurrences or metastases in any of the patients.

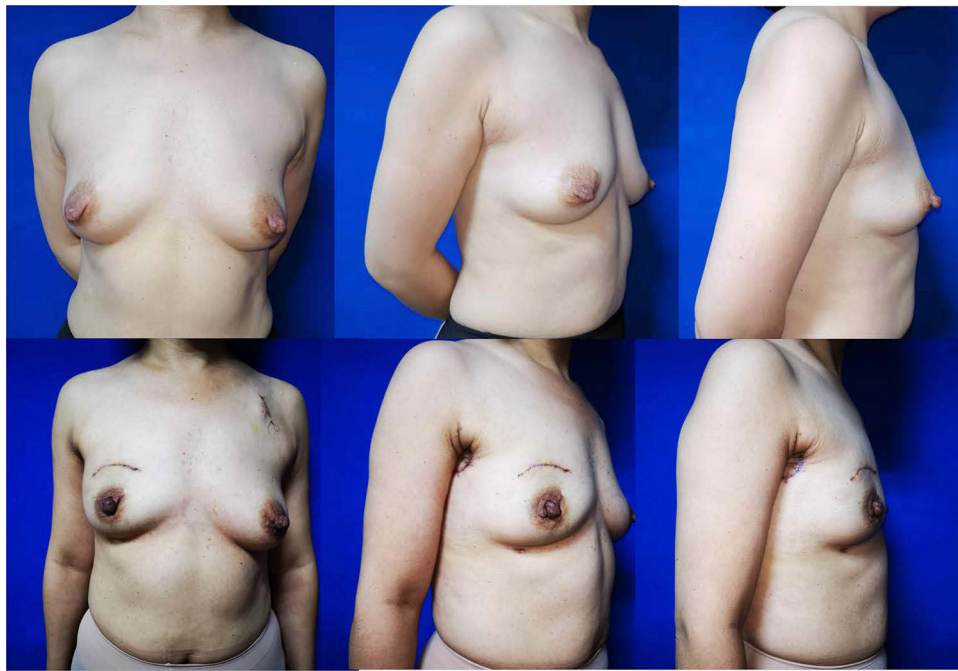
## Discussion

Lesions located in the UIQ of the breast deserve the most attention. A wide excision in this location can significantly impact the breast shape's overall quality by distorting the visible breast line.<sup>10</sup>

Several techniques have been developed for each breast quadrant; however, the UIQ is still a less favorable location. Anderson et al utilize batwing mastopexy to address tumors in the UIQ.<sup>11</sup> It involved two closely similar half-circle incisions with angled wings on each side of the areolar. Although this approach can reconstruct the defects after wide excision, it can cause some lifting of the nipple leading to breast asymmetry. The contralateral breast may need procedures to attain breast symmetry. If the dissection extends too high, it also can lead to nipple necrosis. The modified round block mammoplasty also has a similar problem.<sup>12</sup> Internal mammary artery perforator flap has been used for medial breast defects because it is a reliable fasciocutaneous local flap with good cosmetic outcomes.<sup>13</sup> In this way, the underlying tissue can be moved inwardly to repair the defects caused by tumor resection. Adhesiolysis of the scar and dog-ear correction at the donor site

**Table 1** Clinicopathological Characteristics of Patients

Characteristics (n=15)	
<b>Ages (years)</b>	45.73±9.07
<b>Age, n (%)</b>	
>45	8 (53.3%)
≤45	7 (46.7%)
<b>Pathological tumor (T)stage, n (%)</b>	
T1(≤20 mm)	7 (46.7%)
T2(>20 mm, ≤50 mm)	7 (46.7%)
T3(>50 mm)	1 (6.7%)
<b>Pathological Lymph nodes(N) stage, n (%)</b>	
N0	10 (66.7%)
N1	4 (26.7%)
N2	1 (6.7%)
<b>Pathological stage, n (%)</b>	
IA	6 (40%)
IIA	4 (26.7%)
IIB	4 (26.7%)
IIIA	1 (6.7%)
<b>HR status, n (%)</b>	
Positive	12 (80%)
Negative	3 (20%)
<b>HER2 status, n (%)</b>	
Positive	4 (26.7%)
Negative	11 (73.3%)
<b>Ki67 status, n (%)</b>	
>15%	8 (53.3%)
≤15%	7 (46.7%)



**Figure 2** Postoperative cosmetic effect and patient satisfaction.

were the main reasons for re-operation. Matrix rotation is an easy breast-preserving technique for treating breast cancer located in the upper/upper inner quadrant of the breast that requires a relatively wide excision. With this technique, a larger breast tumor could be removed without compromising the breast appearance.<sup>14</sup> However long scars are caused in the upper outer quadrant. Although it fades away over time, it is much more visible for Asians. In addition to the tissue displacement approach mentioned above, many tissue replacement methods are also used. One novel approach is to harvest an omental flap to fill the local defect laparoscopically.<sup>15</sup> The omental flap is strong against radiation therapy and less atrophic than the muscle flap, it is attractive for partial reconstruction after breast-conserving surgery for the upper inner quadrant. The most important disadvantage of the omental flap is the impossibility of preoperative volume estimation of the flap.<sup>16</sup> The volume of the OF may be too large for partial reconstruction. Since fat is an excellent self-filling material, free dermal fat or lipofilling also can be used to fill the defect after breast-conserving surgery.<sup>17</sup> It can provide a natural appearance quality. However, the fat survival rate is a puzzle, we cannot accurately estimate the amount of fat needed. Tissue acquisition can also lead to additional damage to the donor site. To avoid donor site damage, allogeneic materials have also been tried. An absorbable adhesion barrier Interceed<sup>®</sup> which is an absorbable fabric composed of oxidized, regenerated cellulose has been used for the reconstruction of partial mastectomy defects in the upper quadrant of large ptotic breasts.<sup>18</sup> However, we also do not know the absorption process of the material.

To avoid the limitations of the above approaches, we try to seek an effective tissue displacement or replacement method to fill the defect. The major pectoralis muscle is in an ideal position for breast reconstruction. It situates just under the breast, and we can easily access it from the same breast incision. So a myofascial flap was designed to repair a defect in the upper quadrant. There are a few obvious advantages of this technique: (1) reliable vascular supply, (2) the simple graft technique, (3) good cosmesis, (4) can be approached from the lumpectomy incision hence no additional scarring, and (5) no change of position.

Tissue atrophy is an unavoidable consequence of muscle flaps in general. Notably, to prevent the pectoralis major muscle from atrophying, it is necessary to simultaneously address the pectoralis major fascia. Additionally, the posterior space of the gland must be completely released to prevent local depression of the lower pole of the breast and any subsequent aesthetic disruption. We did not observe any movement abnormalities in our patients as a result of the excision of a portion of the pectoralis major muscle. Finally, it is also critical that the drain does not pass through the area where the pectoralis major muscle is removed to prevent localized depression.

## Conclusion

We strongly believe that the pectoralis major myofascial flap is a reliable volume replacement tool to reconstruct the defects after resecting the tumors located in the UIQ related to OBCS. Its blood supply is reliable, the operation is easy to master, there is no need for an additional incision, and minimal surgical trauma and functional impact.

## Ethical Approval/Informed Consent

This study has been reviewed and approved by the institutional Ethics Committee of Zhejiang Cancer Hospital. The study has been conducted in accordance with the ethical principles laid down in the Declaration of Helsinki. Written informed consent for the use of patient information in this study has been obtained from all patients at the time of admission as a routine practice at Zhejiang Cancer Hospital.

## Author Contributions

All authors have made significant contributions to the work reported. Each author contributed to the conception and design of the study, participated in data collection, analysis, and interpretation, and were involved in drafting, revising, or critically reviewing the article. All authors provided final approval of the version to be published and have agreed on the journal to which the article has been submitted.

## Funding

There is no funding to report.

## Disclosure

The authors report no conflicts of interest in this work.

---

## References

1. Veronesi U, Cascinelli N, Mariani L, et al. Twenty-year follow-up of a randomized study comparing breast-conserving surgery with radical mastectomy for early breast cancer. *N Engl J Med.* 2002;347(16):1227–1232. doi:10.1056/NEJMoa020989
2. Fisher B, Anderson S, Bryant J, et al. Twenty-year follow-up of a randomized trial comparing total mastectomy, lumpectomy, and lumpectomy plus irradiation for the treatment of invasive breast cancer. *N Engl J Med.* 2002;347(16):1233–1241. doi:10.1056/NEJMoa022152
3. Clough KB, Cuminet J, Fitoussi A, et al. Cosmetic sequelae after conservative treatment for breast cancer: classification and results of surgical correction. *Ann Plast Surg.* 1998;41(5):471–481. doi:10.1097/0000637-199811000-00004
4. Lee J, Jung JH, Kim WW, et al. Oncologic outcomes of volume replacement technique after partial mastectomy for breast cancer: a single center analysis. *Surg Oncol.* 2015;24(1):35–40. doi:10.1016/j.suronc.2014.12.001
5. Ho W, Stallard S, Doughty J, et al. Oncological outcomes and complications after volume replacement oncoplastic breast conservations—the glasgow experience. *Breast Cancer.* 2016;10:223–228. doi:10.4137/BCBCR.S41017
6. Noguchi M, Yokoi-Noguchi M, Ohno Y, et al. Oncoplastic breast conserving surgery: volume replacement vs. volume displacement. *Eur J Surg Oncol.* 2016;42(7):926–934. doi:10.1016/j.ejso.2016.02.248
7. Chatterjee A, Gass J, Patel K, et al. A consensus definition and classification system of oncoplastic surgery developed by the American society of breast surgeons. *Ann Surg Oncol.* 2019;26(11):3436–3444. doi:10.1245/s10434-019-07345-4
8. Clough KB, Kaufman GJ, Nos C, et al. Improving breast cancer surgery: a classification and quadrant per quadrant atlas for oncoplastic surgery. *Ann Surg Oncol.* 2010;17(5):1375–1391. doi:10.1245/s10434-009-0792-y
9. Yang JD, Lee JW, Kim WW, et al. Oncoplastic surgical techniques for personalized breast conserving surgery in breast cancer patient with small to moderate sized breast. *J Breast Cancer.* 2011;14(4):253–261. doi:10.4048/jbc.2011.14.4.253
10. Lin J, Chen D-R, Wang Y-F, et al. Oncoplastic surgery for upper/upper inner quadrant breast cancer. *PLoS One.* 2016;11(12):e0168434. doi:10.1371/journal.pone.0168434
11. Anderson BO, Masetti R, Silverstein MJ. Oncoplastic approaches to partial mastectomy: an overview of volume-displacement techniques. *Lancet Oncol.* 2005;6(3):145–157. doi:10.1016/S1470-2045(05)01765-1
12. Nguyen-Sträuli BD, Frauchiger-Heuer H, Talimi-Schnabel J, et al. Single-incision for breast-conserving surgery through round block technique. *Surg Oncol.* 2022;44:101847. doi:10.1016/j.suronc.2022.101847
13. Huizum MAV, Hage JJ, Oldenburg HA, et al. Internal mammary artery perforator flap for immediate volume replacement following wide local excision of breast cancer. *Arch Plast Surg.* 2017;44(6):502–508. doi:10.5999/aps.2016.00458
14. Lee S, Lee J, Jung Y, et al. Oncoplastic surgery for inner quadrant breast cancer: fish-hook incision rotation flap. *ANZ J Surg.* 2017;87(10):E129–e133. doi:10.1111/ans.13336
15. Zaha H. Oncoplastic volume replacement technique for the upper inner quadrant using the omental flap. *Gland Surg.* 2015;4(3):263–269. doi:10.3978/j.issn.2227-684X.2015.01.08
16. Zaha H, Sunagawa H, Kawakami K, et al. Partial breast reconstruction for an inferomedial breast carcinoma using an omental flap. *World J Surg.* 2010;34(8):1782–1787. doi:10.1007/s00268-010-0535-z

17. Kijima Y, Yoshinaka H, Hirata M, et al. Clinical and pathologic evaluation of implanted free dermal fat grafts after breast cancer surgery: a retrospective analysis. *Surgery*. 2012;151(3):444–455. doi:10.1016/j.surg.2011.07.031
18. Lee J, Lee S, Jung Y, et al. Use of an absorbable adhesion barrier for reconstruction of partial mastectomy defects in the upper quadrant of large ptotic breasts. *Surg Oncol*. 2015;24(2):123–127. doi:10.1016/j.suronc.2015.01.002

Cancer Management and Research

Dovepress

**Publish your work in this journal**

Cancer Management and Research is an international, peer-reviewed open access journal focusing on cancer research and the optimal use of preventative and integrated treatment interventions to achieve improved outcomes, enhanced survival and quality of life for the cancer patient. The manuscript management system is completely online and includes a very quick and fair peer-review system, which is all easy to use. Visit <http://www.dovepress.com/testimonials.php> to read real quotes from published authors.

Submit your manuscript here: <https://www.dovepress.com/cancer-management-and-research-journal>