

## Distribution of primary cochlear afferents in the bulbar nuclei of the rat: a horseradish peroxidase (HRP) study in parasagittal sections\*

MIGUEL A. MERCHAN, FRANCISCO P. COLLIA,  
JAIME A. MERCHAN AND MARIA D. LUDEÑA

*Department of Histology, Faculty of Medicine, University of Salamanca and  
Department of Morphology, Faculty of Medicine, University of Alicante, Spain*

*(Accepted 24 April 1985)*

### INTRODUCTION

The bulbar cochlear nuclei constitute a neuronal complex which contains several cell types (Harrison & Irving, 1965, 1966; Brawer, Morest & Kane 1974; Cant & Morest, 1979*a*; Cant, 1981), arranged in two main areas, known as the ventral (VCN) and dorsal (DCN) cochlear nuclei, the latter showing a well defined lamination. The ventral nucleus has been divided into the anterior (AVCN) and posterior (PVCN) regions (Cajal, 1909; Lorente de No, 1933*a, b*) as a result of an almost geometrical bifurcation of the auditory fibres into ascending and descending branches. Subsequent data obtained with different techniques have revealed a more precise division which envisages the central nucleus as composed of three (Powell & Erulkar, 1962; Nissl method), five (Rasmussen, 1967; Nissl method; silver stain), eight (Harrison & Irving 1966; Osen, 1969: silver stain) or fourteen (Brawer *et al.* 1974: Nissl and Golgi micrometry methods) different regions.

The main differences between these classifications are related to cytoarchitecture or to minor aspects of connectivity. However, all of them are linked by the acceptance of the classical V branching pattern of the cochlear axons (Held 1893; Cajal, 1894, 1900, 1909; Lorente de No, 1933*b*). Recent work with peroxidase (Merchan, Collia, Merchan & Saldana, 1985) has shown that the primary afferents exhibit a more complex topological distribution than the classical V shaped pattern. This discrepancy may be due to technical factors. Primary afferent localisation can be more easily established using horseradish peroxidase (HRP) than by means of the Golgi or Bodian impregnation techniques, because with the latter methods it is not possible to follow axons from their origin in the cochlear ganglion.

Nevertheless, the spatial arrangement of the cochlear nuclei should also be taken into account. As is well known, minor variations in the plane of sectioning can furnish different results. It is possible that the differences between previously reported Golgi (Cajal, 1894; Lorente de No, 1933*b*; Feldman & Harrison, 1969) and the present HRP results may be, at least partially, related to this critical orientation of the sectioning plane. The aims of the present paper are to determine the distribution of the primary cochlear fibres by searching for the oblique parasagittal plane which permits the main direction of the fibres to be followed in the brain stem and after

\* Reprint requests to Dr Miguel A. Merchan, Dpto. de Histología, Facultad de Medicina, C/Fonseca, 2, 37007 Salamanca, Spain.

entering the auditory nuclei, and to establish a correlation between this parasagittal plane and the appearances in transverse section.

#### MATERIAL AND METHODS

Twenty five young (150 g) healthy Wistar albino rats were used. All the animals were anaesthetised with chloral hydrate (0.3 g/kg body weight) and the left cochlea surgically exposed after opening the bulla. The bone was drilled and 10  $\mu$ l of 30% aqueous HRP (Type VI, Sigma) were injected over 30 minutes using a glass micropipette connected to a perfusion pump. After the injection, the hole was stoppered with the micropipette tip, which was left *in situ* for 60 minutes. Twenty four hours later, the animals were anaesthetised again with chloral hydrate (0.3 g/kg body weight) and perfused transcadiacally with 40 ml saline solution, followed by 350 ml of Karnovsky fixative containing 2% glutaraldehyde and 1% p-formaldehyde. After washing with 350 ml 5% sucrose in 0.1M phosphate buffer, pH 7.4, the brain stem was excised and left for an additional 24 hours in 15% buffered sucrose. The blocks containing the cochlear nuclei were cut in a Reichert OM-E microtome equipped with a tilting stage and connected to a carbon dioxide freezing device.

The brain stems of five animals were sectioned in the transverse plane, and the remaining ones in parasagittal planes. The blocks for transverse sectioning were fixed to the stage which was tilted until completely symmetrical sections were obtained. This was considered to be the transverse zero plane. The brain stems of two animals were sectioned along plane zero and 5 by inclining the stage 5° more each time.

The inclination planes could not be established with mathematical precision due to different shrinkages of the blocks according to the degree of freezing. This aspect was even more troublesome in the parasagittal planes in which the zero plane could not be established by symmetry and the medial surface obtained after cutting the piece was never completely sagittal. Accordingly, the number of animals needed to observe the whole length of the fibres along the parasagittal plane was necessarily high. The surface fixed to the stage was obtained by sectioning the brain stems along the medial posterior sulcus.

In every case the sections (25  $\mu$ m thick) were developed with 3,3', 5,5'-tetramethylbenzidine (Sigma; Mesulam, 1982) and alternate sections counterstained with neutral red.

#### RESULTS

In the parasagittal plane, HRP labelling was more conspicuous in the ventral than in the dorsal nucleus, which occasionally showed no labelling at all (Fig. 1A). In the ventral complex (Fig. 1A), two heavily stained plexuses were prominent; both of them were composed of such a densely woven network of fibre terminals that the resolution of individual axons was often impossible, although some empty spaces surrounded by nest-like axonal arrangements could be seen. As they were located in the most superficial zones of the anteroventral and posteroventral nuclei, these have been called here the anterior and posterior primary plexuses respectively.

The origin and topography of these plexuses could be readily established by examining different series of parasagittal sections cut at different angles (or tilting planes) to the sagittal reference plane. In the more lateral sections (Figs. 2A, 3A) the axons of the cochlear root followed a straight course towards the centre of the ventral nucleus. However, shortly after their entrance into the root, some of them gave rise to a collateral which ran perpendicularly to the root axis (Figs. 1A, B,

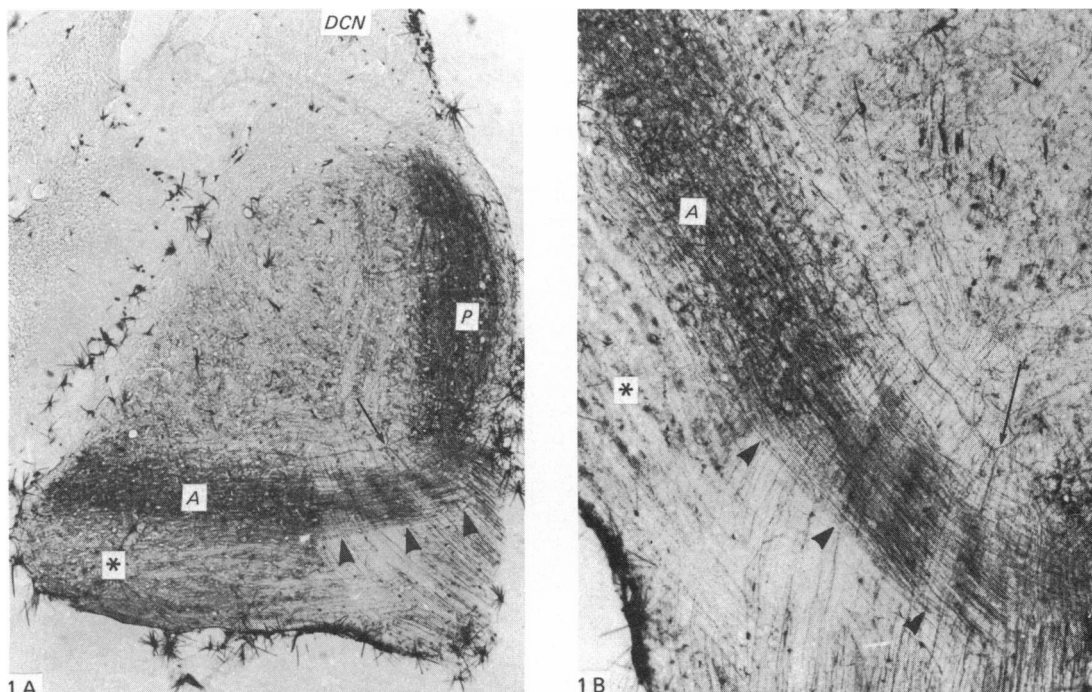


Fig. 1 (A–B). Lateral parasagittal sections. HRP labels are concentrated in the anterior (A) and posterior (P) plexuses, while the dorsal cochlear nucleus (DCN) shows no labelled fibres at this level. The nerve fibres emerging from the bifurcation (arrow) of the root axons are not related to the anterior bundle (arrowheads). The ventral superficial area of the anteroventral cochlear nucleus (\*) is barely labelled. (A)  $\times 90$ ; (B)  $\times 450$ .

2A, 3A), forming a bundle (anterior bundle) which ended in the anterior plexus. Transverse sections clearly showed (Figs. 4A, B) the origin at right angles to these collaterals; the stippled aspect of the anterior bundle due to the spatial arrangement of its fibres was also prominent in this plane. The localisation of this plexus may be established from Figures 2A, B and 3A, B and from Figure 1 which, since it corresponds to a more oblique plane, allows the observation of a complementary perspective. The anterior plexus covered the most anterior and lateral portion of the anterior division of the ventral nucleus and also the central region of the more medial areas of this division (Figs. 1, 2A, B, 3A, B).

In a more medial section it could be easily seen that the bulk of the cochlear root axons fanned out inside the central zone of the ventral nucleus (Figs. 2B, 3B), yielding a homogeneous pattern of straight, scarcely ramified fibres, with a small number of their terminal branches ending near the anterior or posterior plexuses (Figs. 2B, 3B).

The posterior plexus, although present in lateral sections (Figs. 2A, B, 3A, B), is best shown on deeper planes (Figs 1A, 2C, D, 3C, D). This plexus covered the posterior area of the posteroventral cochlear nucleus. As reported elsewhere (Merchan *et al.* 1985), this plexus also covered the deep layers of the dorsal cochlear nucleus, but only in its most medial areas (Figs. 2D, 3D), whereas the lateral ones (Figs. 1A, 2C, 3C) were not strongly labelled. The origin of the posterior plexus could be traced to the root in the medial parasagittal sections. Figures 2C and 3C show

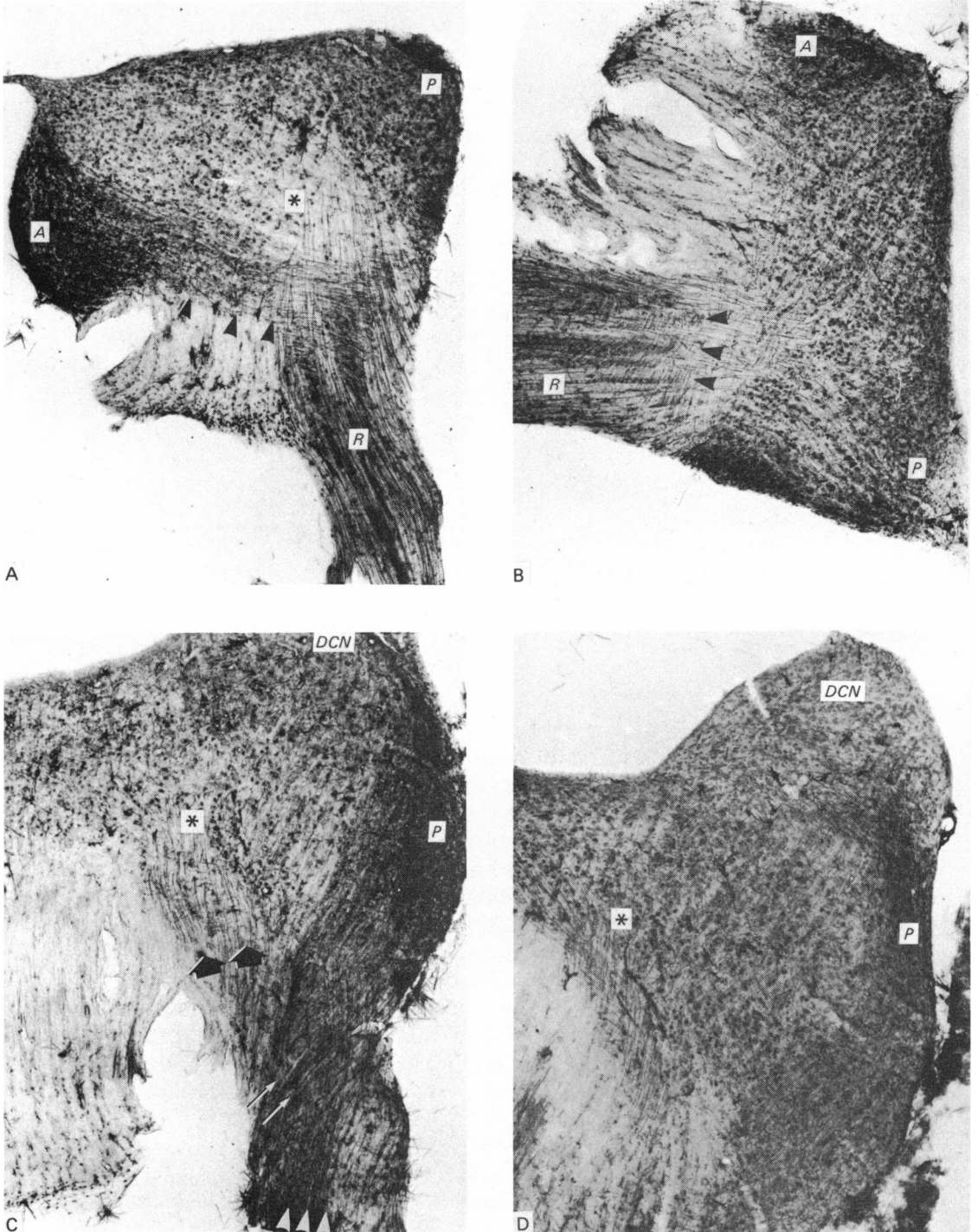


Fig. 2. For legend see page 77.

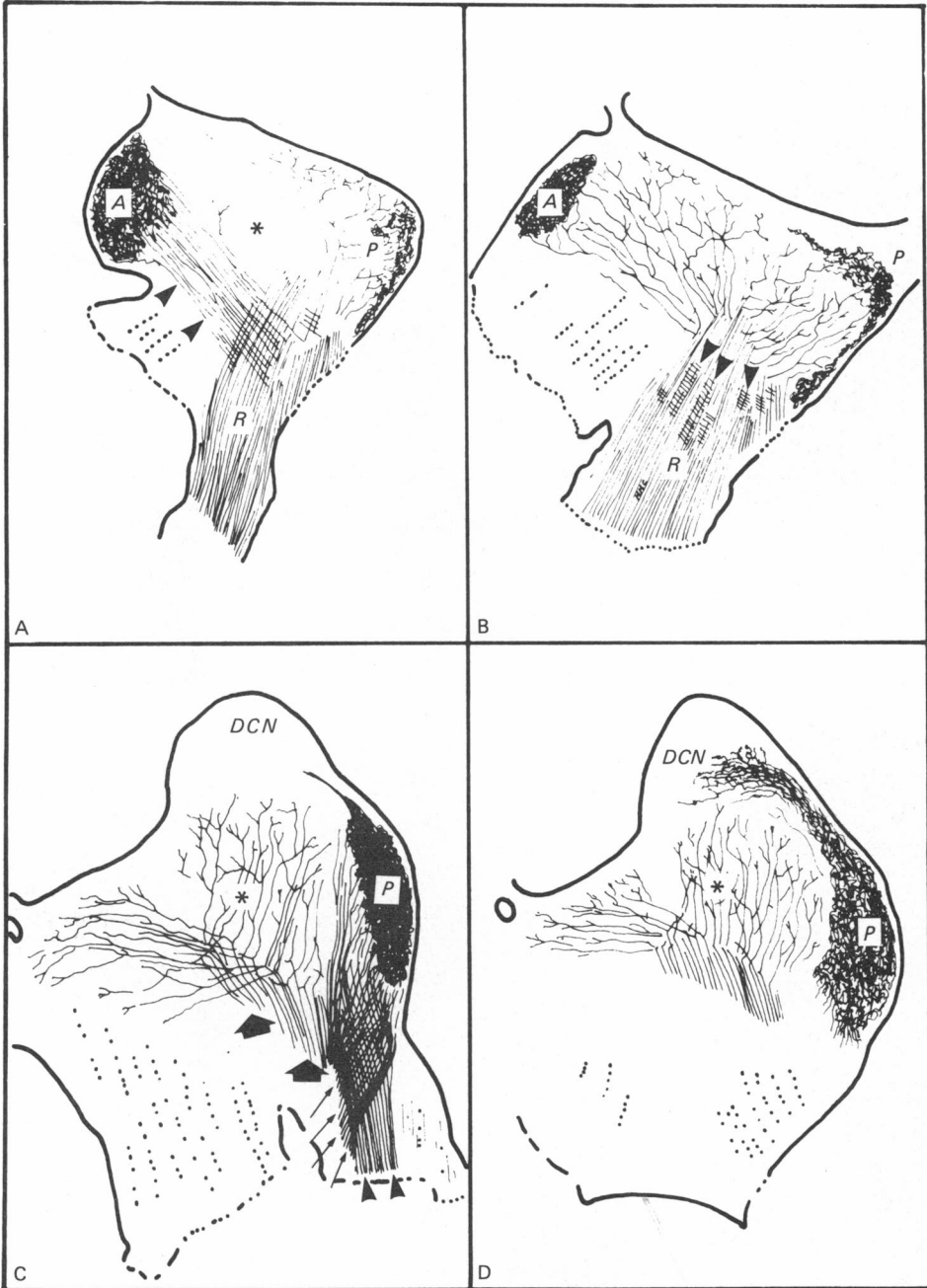


Fig. 3. For legend see page 77.

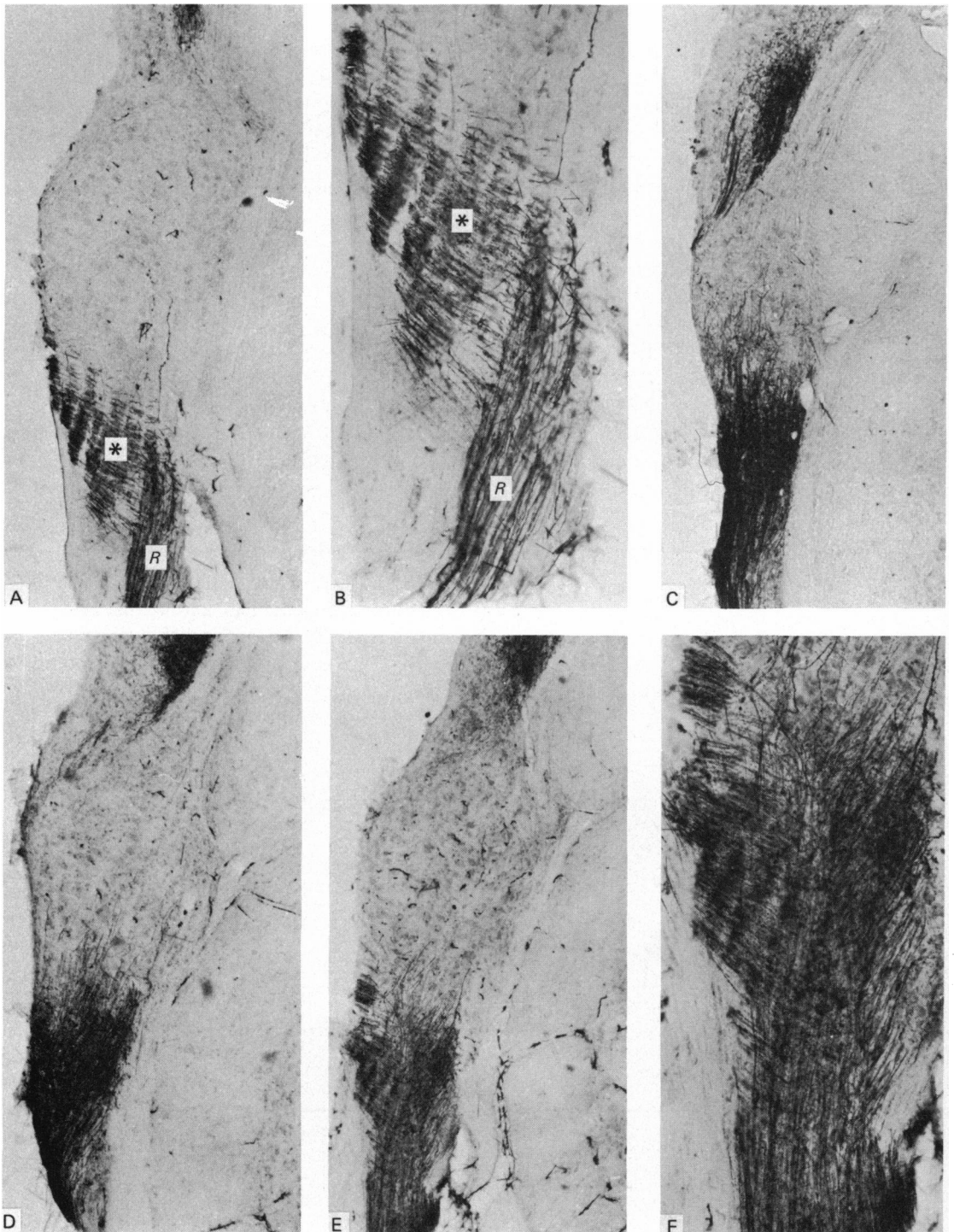


Fig. 4. For legend see opposite.

that, at this level, the cochlear root is composed of groups of fibres crossing each other.

The transverse sections confirm the structural organisation demonstrated in the parasagittal sections. In the most anterior transverse sections, the origin of the fibres of the anterior bundle is seen stemming at right angles from the principal fibres (compare Figs 2A and 3A with 4A and B). The fibres crossing from the posterior bundle (Fig. 3C) were seen in the transverse sections to be formed by two groups of axons with different courses in two successive sections (Figs. 4C, D).

The posterior bundle ended in the posterior plexus (Figs. 2C, 3C: arrowheads) without branching in the cochlear nucleus. The anterior part of the posterior bundle exhibited a dual destination. The posterior ones (Fig. 2C, 3C: thin arrows) also ended in the posterior plexus, while the anterior group (Figs. 2C, 3C; thick arrows) branched throughout the central area of the ventral cochlear nucleus in the V-pattern described by Cajal (1894) and Lorente de No (1933). This pattern, which was not present in the most lateral parasagittal sections, was nonetheless prominent in the more medial planes, even in those where no cochlear root appeared (Figs. 2D, 3D). At this level, the posterior plexus was highly developed, but showed no connection at all with the ascending or descending branches of the cochlear axons.

#### DISCUSSION

The main features of the distribution of primary cochlear afferents in the bulbar nuclei were established by the pioneer work of Held (1893), Cajal (1900) and Lorente de No (1933 *a, b*). According to the latter two authors, the cochlear axons, just after entering the medulla, divide into two branches, usually known as the anterior (ascending) and posterior (descending) branches. They related this division to the localisation of sound perception in the cochlea (Held, 1893; Cajal, 1894, 1900). According to Lorente de No (1933*a, b*) the anterior branches ramify within the

Figs. 2 (A–D)–3 (A–D). Photomicrographs (Fig. 2) and camera lucida drawings (Fig. 3) of tilted parasagittal serial sections (anteroposterior axis). (A) and (B) are more lateral sections than that in Fig. 1; (C) and (D) are progressively deeper planes.

(A) The anterior bundle (arrowheads), formed by collaterals emerging at right angles from the root (*R*) axons, ends in the anterior plexus (*A*), which covers the anterior region of the antero-neutral cochlear nucleus. The posterior plexus (*P*) is smaller. The central area (\*) of the ventral nucleus shows no labelling.

(B) Branching of the cochlear axons on a slightly deeper plane than (A). The anterior bundle has disappeared, though the first segment (arrowheads) of its fibres can be seen intermingled at right angles with the parent axons of the root (*R*). *A*, anterior plexus; *P*, posterior plexus.

(C) Medial section. The fibres of the posterior bundle are arranged in the root in two groups, anterior and posterior. The posterior group (arrowheads) runs directly to the posterior plexus (*P*), where the anterior group of axons (thin arrows) of the posterior bundle also ends. Of the anterior group of fibres of the posterior bundle, the most anterior fibres do not address the posterior plexus but give rise to collaterals in a V-shape (\*), according to the classical pattern (thick arrows). *DCN*, dorsal cochlear nucleus.

(D) The most medial parasagittal sections showing the posterior plexus (*P*) reaching the dorsal cochlear nucleus (*DCN*). The tonotopic pattern (\*) is fully developed. (A) and (B),  $\times 190$ ; (C) and (D),  $\times 240$ .

Fig. 4 (A–F). Transverse sections. (A, B) Fibres for the anterior bundle (\*) commence in the root (*R*) and at right angles to the parent axons. (C) Posterior group of the posterior bundle running parallel to the main axis of the root. Transverse zero plane. (D) Anterior part of the posterior bundle running in a slightly slanting direction to the axis of the root. Transverse zero plane. (E–F) Overlapping of the anterior and posterior bundles of the root. Tilted section (anteroposterior axis) (A), (C), (D) and (E)  $\times 190$ ; (B) and (F)  $\times 250$ .

anteroventral cochlear nucleus, while the posterior branches span the posteroventral cochlear nucleus and the dorsal cochlear nucleus. Short collaterals stem from both branches and form different terminal arborisations, either the classical endbulbs of Held (1893) or more delicate fibrillar meshworks, which may or may not be arranged in a nest-like fashion (Cajal, 1894, 1900, 1909).

The V-branching pattern has been widely confirmed (see Lorente de No, 1981, for references) and, as claimed by Cajal (1900), it is generally accepted to be the structural basis for the tonotopic distribution of response to sound stimuli in the cochlear nuclei (Rose, Galambos & Hughes, 1959).

The only two reports on HRP tracing of primary afferents, performed on fish (Meredith & Butter, 1983) and hens (Parks & Rubel, 1978), have yielded important results, but species differences from the rat make any extrapolation extremely difficult.

The HRP results described in the present paper are basically in agreement with the Golgi data, and the ascending and descending branches observed (Figs. 2C, D, 3C, D) correlate closely with the classical interpretation. However, HRP data provide new features which are worth discussing; these are the anterior and posterior plexuses.

In the light of the present HRP results, careful examination of the papers based on the Golgi technique shows that in one way or another part of these new data was already known, although it was interpreted in a different manner. In fact, Cajal's drawings (Cajal, 1909, Fig. 330) of the cochlear nuclei show an 'anterior marginal plexus' (carefully described in his 1900, although not in his 1909, paper), whose localisation seems to be the same as that of the anterior plexus shown in the present HRP results.

More recently, Feldman & Harrison (1969), working with rats and using the Golgi technique, have reported that towards the posterior end of the posteroventral cochlear nucleus, the fibres of the descending branch converge ventrally to form a compact bundle situated at the boundary between the posteroventral cochlear nucleus and dorsal cochlear nucleus, some axons penetrating the latter nucleus. A certain relationship exists between such data and the present results concerning the posterior bundle and plexus, although Feldman & Harrison (1969) do not describe any kind of disposition of axonal terminals which could be considered as a well defined plexus. On the other hand, this seems easy to understand considering that only some of the axons in their material were impregnated.

Feldman & Harrison (1969) have also reported the existence of a "system of collaterals arising from the dorsalmost fibres of the ascending branch. This collateral system consists of long parallel branches orientated perpendicular to the parent fibres, and extending upward to the area of the ventral cochlear nucleus over the region of the bifurcations".

The HRP results also demonstrate a right angled branching pattern for the anterior bundle (Figs. 1A, 2A, 3A). Though there are certain similarities in structural detail between the illustrations of Feldman & Harrison (1969) and the results obtained using HRP, there is also a basic discrepancy since these latter authors refer to their data on the basis of the classical V-shaped branching pattern, whereas the peroxidase technique reveals that neither the anterior nor the posterior bundles follow this pattern.

The anterior plexus lies (Fig. 2A, B, 3A, B) over the lateral area of region III, the anterocentral area of region II and in the whole of region I, according to Harrison &



Irving in the rat (1965, 1966), and partially over the anterior, anteroposterodorsal, anteroposterior and posterodorsal parts of the anteroventral cochlear nucleus, according to the division by Brawer *et al.* (1974) in the cat. Although species differences should be remembered, it can be assumed that the cytoarchitectonics of these areas can be extrapolated from the cat to the rat (authors' unpublished data); in this case, it could be assumed that the cells occupying the territories reached by the anterior plexus (see above) must also receive the terminal branches of this plexus. Cell population analysis of the anteroventral cochlear nucleus by Cant & Morest (1979*a, b*), have shown that nearly all the neurons in the anterior and anteroposterodorsal parts are bushy cells, while in the anteroposterior part this type accounts for approximately half the total, the remaining neurons being either stellate or small cells. Nonetheless, the anterior plexus does not completely cover the anterior and anteroposterodorsal nuclei, so that bushy cells can receive different inputs depending on their location, as has been previously suggested (Brawer & Morest, 1975). In any case, the anteroventral cochlear nucleus is a synaptic area of paramount importance, as at least six types of non-cochlear axons end here, besides the primary afferents (Cant & Morest, 1978). The distribution of the non-cochlear axons has been settled by Cant & Morest (1978), and in some places it matches the areas innervated by the anterior plexus, thus modelling precise sites for the convergence of inputs in the anteroventral cochlear nucleus.

#### SUMMARY

HRP was injected into the cochleae of 25 young albino rats in order to trace the primary afferents to the bulbar cochlear nuclei. Besides the classic V-shaped pattern and unconnected with it, HRP labelling revealed two plexuses stemming directly from the axons of the cochlear root. The plexuses cover the posterior area of the posteroventral cochlear nucleus (posterior plexus) and the anterolaterodorsal area of the anteroventral cochlear nucleus (anterior plexus). The fibres giving rise to these two plexuses were previously grouped in two bundles which have been called the posterior and anterior bundles, respectively. The origin of the anterior bundle is typically seen with the fibres stemming out at right angles; the origin and course of the posterior bundle, which characteristically cross over, is also a typical feature.

This work was supported by grants 1279/82 and 1822/83 of the Spanish Government (Fondo Nacional para el desarrollo de la Investigación Científica).

#### REFERENCES

- BRAWER, J. R. & MOREST, D. K. (1975). Relations between auditory nerve endings and cell types in the cat's anteroventral cochlear nucleus seen with the Golgi method and Nomarski optics. *Journal of Comparative Neurology* **160**, 491–506.
- BRAWER, J. R., MOREST, O. K. & KANE, E. C. (1974). The neuronal architecture of the cochlear nucleus of the cat. *Journal of Comparative Neurology* **155**, 251–300.
- CAJAL, S. R. Y (1894). Apuntes para el estudio del bulbo raquídeo, cerebelo y origen de los nervios encefálicos. *Anales de la Sociedad española de historia natural* **24**, 74–110.
- CAJAL, S. R. Y (1900). Disposición terminal de las fibras del nervio coclear. *Revista trimestral micrográfica* **5**, 111–127.
- CAJAL, S. R. Y (1909). *Histologie du Système Nerveux de l'Homme et des Vertébrés*, vol. 1. Paris: Maloine.
- CANT, N. B. (1981). The fine structure of two types of stellate cells in the anterior division of the anteroventral cochlear nucleus of the cat. *Neuroscience*, **6**, 2643–2655.
- CANT, N. B. & MOREST, D. K. (1978). Axons from non cochlear sources in the antero-ventral cochlear nucleus of the cat. A study with the rapid Golgi method. *Neuroscience* **3**, 1003–1029.

- CANT, N. B. & MOREST, D. K. (1979*a*). Organization of the neurons in the anterior division of the antero-ventral cochlear nucleus of the cat. Light microscopic observations. *Neuroscience* **4**, 1909–1923.
- CANT, N. B. & MOREST, D. K. (1979*b*). The bushy cells in the antero-ventral cochlear nucleus of the cat. A study with the electron microscope. *Neuroscience* **4**, 1925–1945.
- FELDMAN, M. L. & HARRISON, J. M. (1969). The projection of the acoustic nerve to the ventral cochlear nucleus of the rat. A Golgi study. *Journal of Comparative Neurology* **137**, 267–294.
- HARRISON, J. M. & IRVING, K. (1965). The anterior ventral cochlear nucleus. *Journal of Comparative Neurology* **124**, 15–42.
- HARRISON, J. M. & IRVING, R. (1966). The organization of the posterior ventral cochlear nucleus in the rat. *Journal of Comparative Neurology* **126**, 391–402.
- HELD, H. (1893). Die centrale Gehörleitung. *Archiv für Anatomie und Physiologie, Anatomische Abteilung*, 201–248.
- LORENTE DE NO, R. (1933*a*). Anatomy of the eighth nerve. The central projection of the nerve endings of the internal ear. *Laryngoscope* **43**, 1–38.
- LORENTE DE NO, R. (1933*b*). Anatomy of the eighth nerve. III. General plan of structure of the primary cochlear nuclei. *Laryngoscope* **43**, 327–350.
- LORENTE DE NO, R. (1981). *The Primary Acoustic Nuclei*. New York: Raven Press.
- MERCHAN, M. A., COLLIA, F. P., MERCHAN, J. A. & SALDANA, E. (1985). Distribution of primary afferent fibres in the cochlear nuclei. A silver and horseradish peroxidase (HRP) study. *Journal of Anatomy* **141**, 121–130.
- MEREDITH, G. E. & BUTTER, A. B. (1983). Organization of the eighth nerve afferent projections from individual endorgans of the inner ear in the Teleost *Astronotus ocellatus*. *Journal of Comparative Neurology* **220**, 44–62.
- MESULAM, M. M. (1982). Principles of HRP neurohistochemistry and their applications for tracing neural pathways. Axonal transport, enzyme histochemistry and light microscopic analysis. In *Tracing Neural Connections with Horseradish Peroxidase* (ed. M. M. Mesulam), pp. 127. New York: Wiley.
- OLEN, K. K. (1969). Cytoarchitecture of the cochlear nuclei in the cat. *Journal of Comparative Neurology* **125**, 223–258.
- PARKS, T. N. & RUBEL, E. W. (1978). Organization and development of the brain stem auditory nuclei of the chicken: Primary afferent projections. *Journal of Comparative Neurology* **180**, 439–448.
- POWELL, T. P. S. & ERULKAR, S. D. (1962). Transneuronal cell degeneration in the auditory relay nuclei of the cat. *Journal of Anatomy* **96**, 249–268.
- RASMUSSEN, G. L. (1967). Efferent connections of the cochlear nucleus. In *Sensorineural Hearing Processes and Disorders* (ed. A. B. Graham), pp. 346. Boston: Little Brown.
- ROSE, J. E., GALAMBOS, R. & HUGHES, J. R. (1959). Microelectrode studies of the cochlear nuclei of the cat. *Bulletin of the Johns Hopkins Hospital* **104**, 211–251.