

Observations on the bony bridging of the jugular foramen in man

YUKIO DODO

Department of Anatomy, Sapporo Medical College, Sapporo 060, Japan

(Accepted 23 May 1985)

INTRODUCTION

Many current textbooks of human anatomy describe bony bridging of the jugular foramen (Elze, 1954; Breathnach, 1965; Warwick & Williams, 1973; Staubesand, 1978; Romanes, 1981; Kamijo, 1982). However, these descriptions are not in such detail that the presence or absence of bony bridging of the jugular foramen can be easily defined in actual observations of human skulls. If the bridging of the jugular foramen is clearly present, it can be used effectively as a non-metrical cranial variant, as demonstrated in successful anthropological population studies (Laughlin & Jørgensen, 1956; Brothwell, 1958; Berry & Berry, 1967; Yamaguchi, 1967; Ossenberg, 1969; Pietrusewsky, 1971; Czarnetzki, 1972; Dodo, 1974).

During a preliminary observation on a considerable number of macerated fetal crania, the author has encountered bridge formation of the jugular foramen in several instances. Since the configuration of the region of the jugular foramen in fetuses is simpler than in adults, the bony processes making up the jugular foramen bridging can be easily defined as to their origin and/or direction within the jugular foramen. The definition of jugular foramen bridging so obtained is not new, but was pointed out by Spee (1896) and Hayek (1929).

The purposes of this study are, first, to re-evaluate the definition of jugular foramen bridging on the basis of the examination of fetal skulls; secondly, to present several types of bridging in both fetuses and adults; thirdly, to compare the incidence of the bridging trait in Japanese fetal and adult skulls; and fourthly, to discuss briefly the morphological significance of jugular foramen bridging.

MATERIALS AND METHODS

Fetal specimens consisted of 64 macerated crania of Japanese fetuses, aged nine months to term, in the Department of Anatomy, Tohoku University School of Medicine, collected by the late Professor K. Hasebe between 1920 and 1935. All the crania examined were extremely well preserved and documented by age and sex.

A total of 222 adult skulls examined comprised two cranial series of modern Japanese in Honshu: 87 male and 40 female crania from the Tohoku district in the collection at Tohoku University School of Medicine, and 74 male and 21 female crania from the Kanto district in the collection at Chiba University, now kept at Sapporo Medical College.

The region of the jugular foramen was observed macroscopically; when necessary, a magnifying glass was used. Only the complete type of bridging was considered in the present study. Since partial bridging was indicated in most cases only by a mere

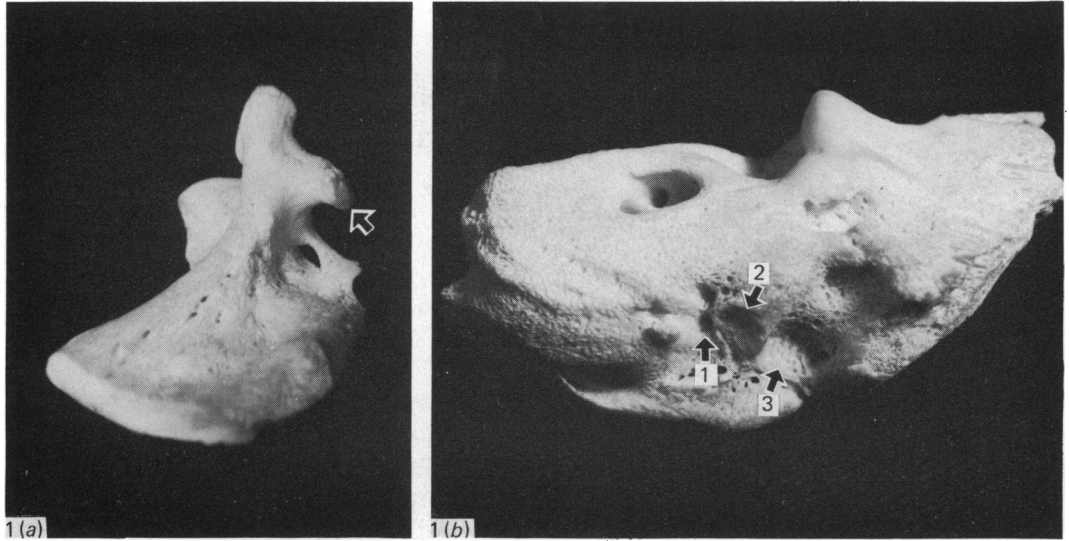


Fig. 1(a-b). (a) The intrajugular process of the occipital bone projecting from the right upper limb of the lateral part in a fetal cranium of nine months (arrow). (b) The right petrous part of the temporal bone of the same fetal cranium. 1, triangular depression; 2, intrajugular process; 3, jugular fossa. Note that the intrajugular process of the temporal bone is situated posterior to the triangular depression.

tubercle, it was not possible to use any definite and consistent criteria for determining its presence or absence.

The area of the jugular foramen in an adult male Japanese cadaver was carefully dissected in order to clarify the relationship between the glossopharyngeal, vagus and accessory nerves, and the intrajugular processes of the jugular foramen.

OBSERVATIONS

Fetal series

During preliminary observations on macerated fetal crania, it was noticed that in a cranium aged nine months a large stout process extended anterolaterally from the right upper limb of the lateral part of the occipital bone (Fig. 1a). Later, it was found to be the intrajugular process in the jugular notch of the occipital bone. On the inferior aspect of the petrous part of the temporal bone of the same individual, a bony process with an articular surface on its tip projected posteromedially. This process was situated anterior to the jugular fossa of the temporal bone, and posterior to the triangular depression (Warwick & Williams, 1973) which lodges the inferior ganglion of the glossopharyngeal nerve. At the apex of the triangular depression, there was a small opening leading into the cochlear canaliculus (Fig. 1b). This process was identified as the intrajugular process of the temporal bone. It is noteworthy that the intrajugular process of the temporal bone was located posterior to the triangular depression of the petrous part. The process of the occipital bone and that of the temporal bone fitted closely together and served to divide the jugular foramen into two parts in the articulated cranium.

A fetal temporal bone in which a stout bony process extended posteromedially from the inferior surface of the petrous part is shown in Figure 2a. The process was again situated posterior to the triangular depression and was identified as the intra-

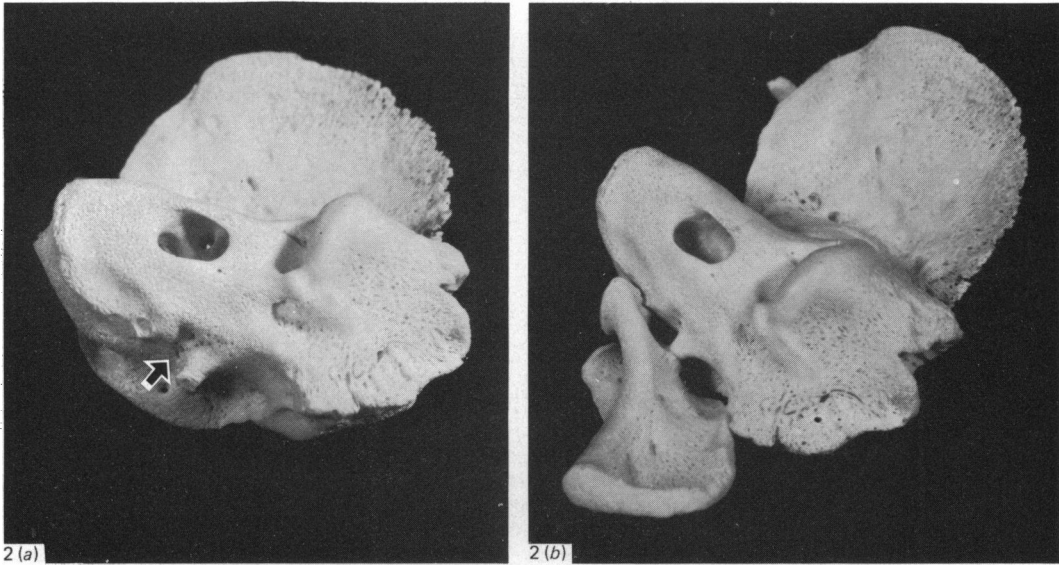


Fig. 2(a-b). (a) The intrajugular process of the temporal bone in a fetal cranium of nine months. An arrow shows the triangular depression. (b) The jugular foramen bridging in the articulated occipital and temporal bones of the same fetal cranium.

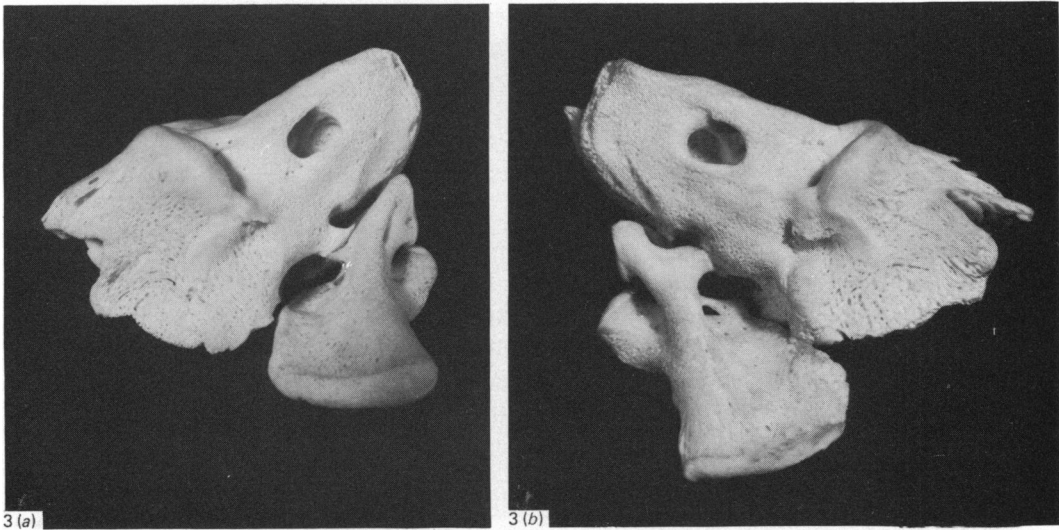


Fig. 3(a-b). (a) The jugular foramen bridging in the articulated occipital and temporal bones in a fetal cranium of nine months. (b) The jugular foramen bridging in the articulated occipital and temporal bones of the same fetal cranium shown in Figure 1.

jugular process of the temporal bone. This process reached a slight projection in the jugular notch of the occipital bone and evidently divided the jugular foramen into two parts in the articulated cranium (Fig. 2b). Such cases of bridging of the jugular foramen in fetal crania are also shown in Figure 3a and b. In Figure 3a, it is seen that the bridging is established mainly by the bony process extending from the temporal bone; in Figure 3b, the bony process projecting from the occipital bone makes a major contribution to the jugular foramen bridging. Again, it should be noted here

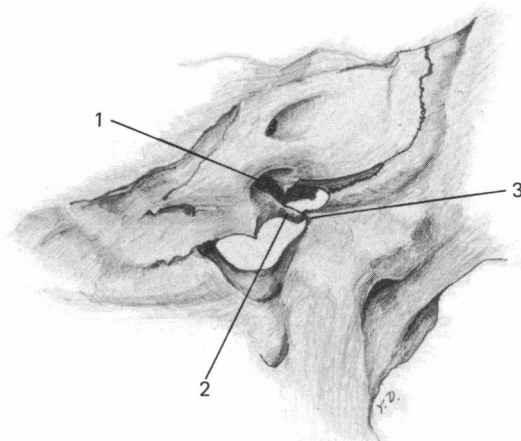


Fig. 4. The internal aspect of the jugular foramen bridging in an adult cranium. 1, triangular depression; 2, intrajugular process of the temporal bone; 3, intrajugular process of the occipital bone. Note that the intrajugular process of the temporal bone is situated posterior to the triangular depression and that the intrajugular process of the occipital bone projects from just above the hypoglossal canal.

that in both cases bridging of the jugular foramen occurred posterior to the triangular depression of the petrous part of the temporal bone.

On the basis of these observations the intrajugular process of the temporal bone may be defined as that located posterior to the triangular depression of the petrous part. On the other hand, the intrajugular process of the occipital bone could not always be defined so easily, although in most cases the process extended immediately superior to the hypoglossal canal.

Adult cranial series

The criterion of jugular foramen bridging obtained from observations of fetal crania was applied to that of adult crania. A typical case of jugular foramen bridging in an adult cranium is illustrated in Figure 4. The intrajugular processes of the temporal and occipital bones, as well as the triangular depression of the petrous part of the temporal bone, are shown in this Figure. The intrajugular process of the temporal bone was located posterior to the triangular depression. The process of the occipital bone, in this case a small protuberance, was situated immediately above the hypoglossal canal.

In Figures 5 and 6 other adult cases of bridging of the jugular foramen are shown. The intrajugular process of the occipital bone was a major contributor in both cases. The bridging occurred posterior to the triangular depression of the petrous part.

In Figures 7 and 8, two additional cases of the jugular foramen bridging are shown. In Figure 7, the triangular depression has been converted into a bony canal which gives passage to the glossopharyngeal nerve. In Figure 8, a case is shown in which jugular foramen bridging was made up exclusively by the intrajugular process of the temporal bone.

The other type of jugular foramen bridging, differing slightly from that described formerly, was observed in the adult cranial series. An indication of a bony process was situated posterior to the hypoglossal canal in the jugular notch of the occipital bone (Fig. 9a). Such a bony process sometimes extended to the intrajugular process

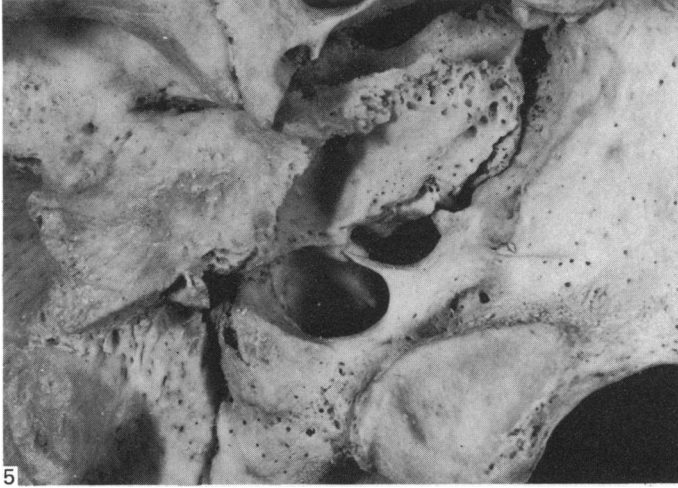


Fig. 5. The external aspect of jugular foramen bridging in an adult cranium. Note that the intrajugular process of the occipital bone makes a major contribution to the bridging of the jugular foramen.

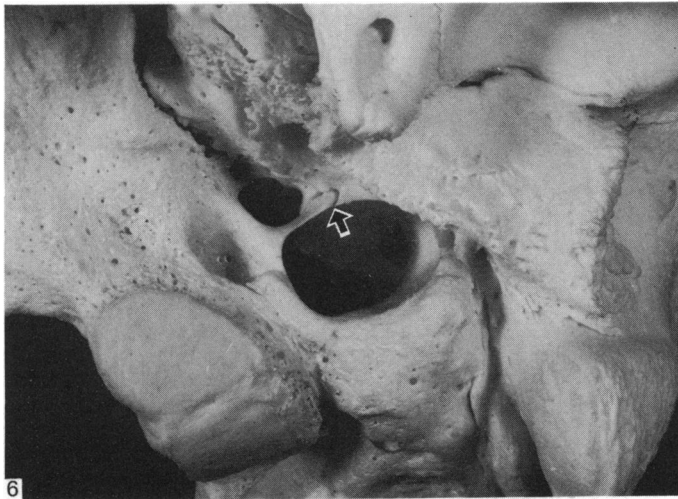


Fig. 6. External aspect of the jugular foramen bridging in an adult cranium. Note that there is a suture-like gap between the intrajugular processes of the temporal and occipital bones (arrow).

of the temporal bone, so completely dividing the jugular foramen into two parts (Fig. 9b).

This type of bridging was designated Type II, while the more frequent type described above was termed Type I. In both cases, it should be emphasised that bony fusion never occurred between the bridging processes. The bridge was made by the contact of the two intrajugular processes, and a suture-like gap was always observed between them.

Incidences of jugular foramen bridging in the Japanese fetal and adult series

The incidence of Type I and Type II bridging in the adult cranial series is shown in Table 1. Since the incidence of Type II bridging was very low (3 out of 222 cases;

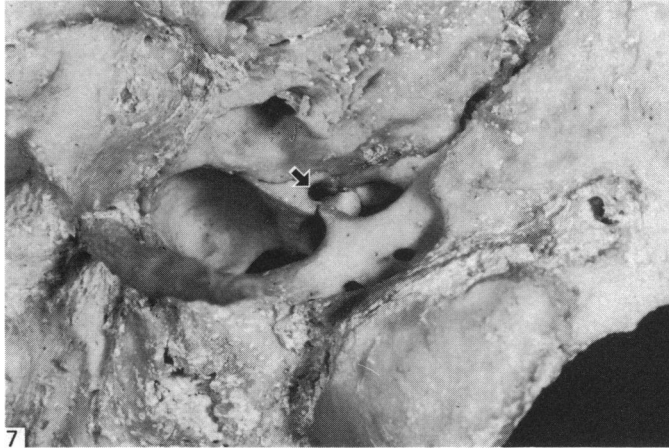

Fig. 7. External aspect of the jugular foramen bridging in an adult cranium. The triangular depression is converted into a bony canal which transmits the glossopharyngeal nerve (arrow).

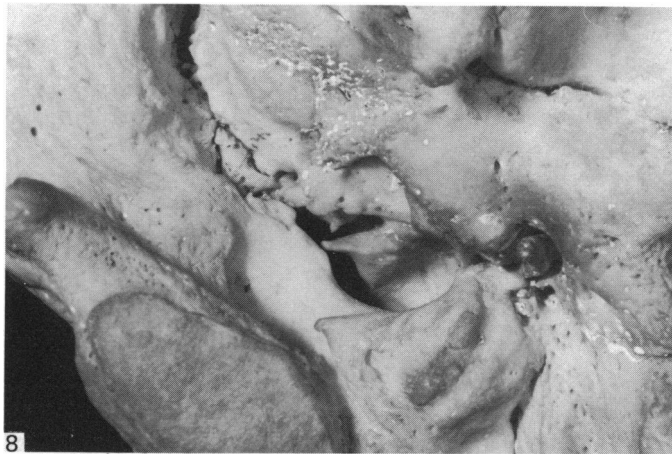


Fig. 8. External aspect of the jugular foramen bridging in an adult cranium. Note that the intra-jugular process of the temporal bone makes a major contribution to the bridging of the jugular foramen.

Table 1. *Incidences of two types of jugular foramen bridging in the Japanese adult series of both sexes*

	RL	RO	OL	OO	Number
Type I	5	12	7	198	222
Type II	0	1	2	219	222
Both types	5	13	9	195	222

RL, bilaterally present; RO, right side only; OL, left side only; OO, absent.

1.4%), both types of bridging were treated as a single group in the statistical analyses.

The sex difference in the incidence of the bridging trait was not statistically significant (Table 2). Nor was the difference between left and right sides statistically significant (Table 3). Conversely, the association of the occurrence of bridging trait on the two sides was highly significant ($P < 0.001$) (Table 4).

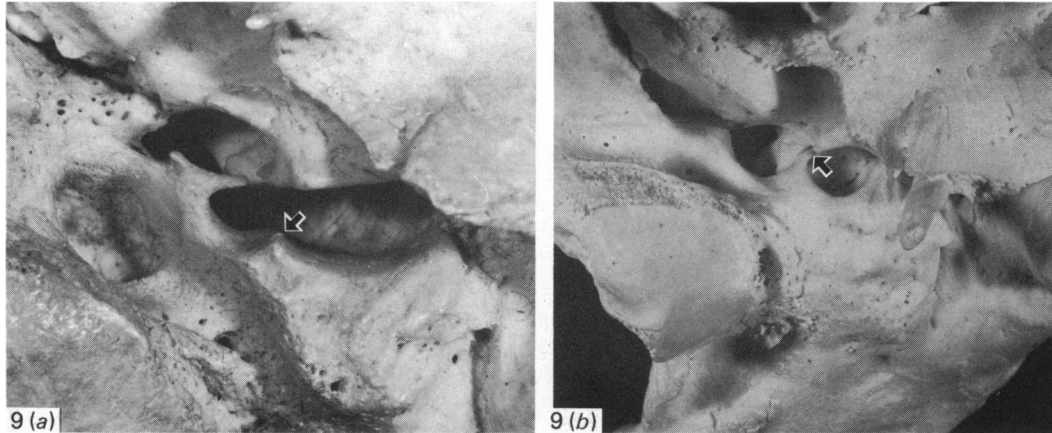


Fig. 9(a-b). (a) An indication of a bony process is situated posterior to the hypoglossal canal in the jugular notch of the occipital bone (arrow). Adult cranium, external aspect. (b) A bony process situated posterior to the hypoglossal canal extends and reaches the intrajugular process of the temporal bone (arrow), thus dividing the jugular foramen into two parts. Adult cranium, external aspect.

Table 2. Sex difference in the incidence of jugular foramen bridging in the Japanese adult series. (Types I and II are combined)

	Number (skulls)	Present	Percentage
Male	161	20	12.4
Female	61	7	11.5
$\chi^2 = 0.0371$, d.f. = 1, n.s.			

Table 3. Difference between left and right sides in the incidence of jugular foramen bridging in the Japanese adult series of both sexes. (Types I and II are combined)

	Number (sides)	Present	Percentage
Right	222	18	8.2
Left	222	14	6.3
$\chi^2 = 0.5388$, d.f. = 1, n.s.			

Table 4. Association of the incidence of jugular foramen bridging between the two sides in the Japanese adult series of both sexes. (Types I and II are combined)

	Right		Number
	Present	Absent	
Left			
Present	5	9	14
Absent	13	195	208
Number	18	204	222
$\chi^2 = 15.2838$, d.f. = 1, $p < 0.001$			

Table 5. Comparison of incidences of jugular foramen bridging between the Japanese fetal and adult cranial series. (Both sexes are pooled)

	Number (skulls)	Present	Percentage
Fetus	64	7	10.9
Adult	222	27	12.2

$\chi^2 = 0.0711$, d.f. = 1, n.s.

In Table 5, incidences of jugular foramen bridging are compared between the Japanese fetal and adult cranial series. Seven out of 64 skulls (10.9%) were bridged in the fetal series and 27 out of 222 skulls (12.2%) in the adult series. The difference in incidence was not statistically significant. It is relevant, however, in this connection that, since the occipital and temporal bones were disarticulated in the macerated fetal cranium, it was difficult to be certain of the presence of complete bridging of the jugular foramen. Observation of the fresh cranium of a ten months fetus showed that a cartilage, from 1 to 2 mm in thickness, intervened between the jugular process of the occipital bone and the jugular surface of the temporal bone. When judging whether the bridging was complete or not in the fetal cranium, this gap should be taken into consideration.

DISCUSSION

In the present study the bony process extending posterior to the triangular depression of the petrous part of the temporal bone is defined as the intrajugular process of the temporal bone. This criterion is not a new one. For example, Spee (1896), on page 174 of Bardeleben's *Handbuch der Anatomie des Menschen*, properly states that "Eine Knochenzacke der hinteren Kante des Petrosum an der Grenze zwischen Fossa jugularis und Apertura externa aqueductus cochleae heisst Processus intrajugularis". Spee's 'Apertura externa aqueductus cochleae' is the same structure as that related to the triangular depression (Warwick & Williams, 1973) at the apex of which a small opening leads into the cochlear canaliculus. Spee's definition of the intrajugular process of the temporal bone is utilised in an excellent article by Hayek (1929). Though their descriptions are not as detailed as those of Spee and Hayek, several textbooks of human anatomy display precise illustrations of the intrajugular process of the temporal bone (Charpy & Nicolas, 1911; Kopsch, 1919; Spanner, 1953; Töndury, 1968; Ferner & Staubesand, 1983).

Figure 10, which shows the relationships of the triangular depression, the intrajugular process of the temporal bone and the intrajugular process of the occipital bone, is redrawn from Figure 94 of Kopsch (1919). It should be noted that the intrajugular process of the temporal bone is located posterior to the triangular depression.

In most textbooks of human anatomy, there is no appropriate description of the intrajugular process of the occipital bone, except to note that it projects from the jugular notch of the occipital bone. Only Breathnach (1965) appears to define the intrajugular process of the occipital bone as a small bony projection from the occipital bone above the hypoglossal canal. The present author has observed two types of bony process projecting from the occipital bone. Type I is situated immediately above the hypoglossal canal and is more frequently present, while Type II

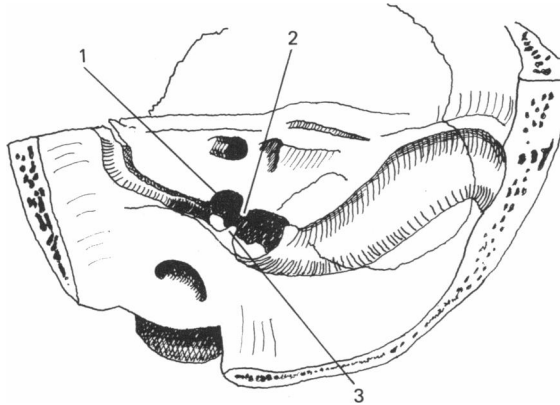


Fig. 10. Internal aspect of the jugular foramen of an adult cranium. 1, triangular depression; 2, intrajugular process of the temporal bone; 3, intrajugular process of the occipital bone. Redrawn from Figure 94 of Kopsch (1919).

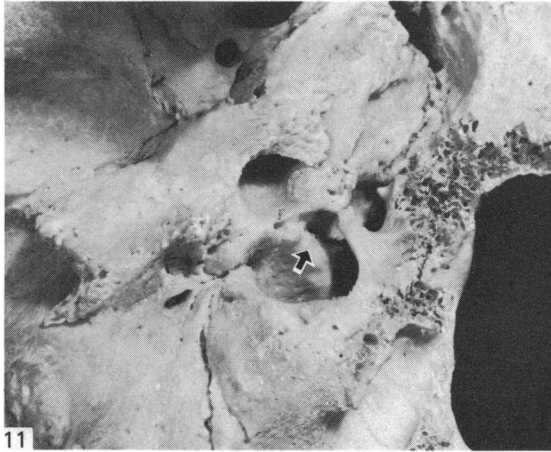

Fig. 11. An ambiguous case of jugular foramen bridging in an adult cranium. External aspect. Though a bony process projects from the occipital bone, it does not reach the intrajugular process of the temporal bone (arrow). Instead it is in contact with the protuberance of the temporal bone located anterior to the triangular depression. This case of bridging was not regarded as true jugular foramen bridging.

is located posterior to the hypoglossal canal and is extremely rare. If these two bony processes were to be prolonged to reach the intrajugular process of the temporal bone together, then the jugular foramen would be divided into three compartments, as described by Charpy & Nicolas (1911), Shima (1941), Warwick & Williams (1973) and Romanes (1981). However, such a tripartite jugular foramen was not encountered in the present cranial series.

In Figure 11, an ambiguous case of jugular foramen bridging is shown. Though a bony process projects from the occipital bone above the hypoglossal canal, it does not reach the protuberance situated posterior to the triangular depression of the petrous part of the temporal bone. Instead, it is in contact with that located anterior to the triangular depression. Probably this structure bears close relation to the inferior petrosal sinus (Lang & Weigel, 1983). This type of bridging is distinct from the jugular foramen bridging discussed in the present paper.

Most textbooks of human anatomy consulted by the present author give similar descriptions of the relationship between the cranial nerves traversing the jugular foramen and the bridging of the foramen. For example, "The jugular foramen is divisible into two parts by the intrajugular process; an anterior for the inferior petrous sinus, the glossopharyngeal, vagus and accessory nerves, and a posterior for the internal jugular vein" (Sharpey, Thomson & Cleland, 1867; Spee, 1896; Kopsch, 1919; Sieglbauer, 1927; Schaeffer, 1953; Breathnach, 1965; Töndury, 1968). Descriptions in the few textbooks of human anatomy which refer to the tripartite division of the jugular foramen may be summarised as follows: "The jugular foramen may be partly or completely divided into three compartments by small spicules of bone. The anteromedial compartment transmits the inferior petrosal sinus, the middle compartment contains the ninth, tenth and eleventh cranial nerves, and the large posterolateral compartment transmits the sigmoid sinus on its way to become the internal jugular vein" (Charpy & Nicolas, 1911; Romanes, 1981).

On the other hand, Hayek (1929), examining cases of bridging of the jugular foramen in a fetal chondrocranium as well as in adult crania, criticised the descriptions in several classic textbooks of human anatomy published at that time. He concluded that in the subdivided jugular foramen, the anteromedial foramen provides passage to the glossopharyngeal nerve, while the posterolateral foramen transmits the vagus and accessory nerves and the internal jugular vein. His conclusion is quoted in *Benninghoff/Goerttler Lehrbuch* (Staubesand, 1978).

In order to examine Hayek's assertion, the region of the jugular foramen of an adult cadaver was dissected very carefully. The result of the dissection is illustrated in Figure 12. As described by Warwick & Williams (1973), in passing through the jugular foramen, the vagus nerve is accompanied by and contained in the same sheath of dura mater as the accessory nerve, a fibrous septum separating them from the glossopharyngeal nerve, which lies anteriorly. Since the glossopharyngeal nerve is contained in the triangular depression which lies anterior to the intrajugular process of the temporal bone, it must be situated anterior to the bony bridging in the bridged jugular foramen. On the other hand, it is apparent that the posterolateral compartment of the bridged jugular foramen transmits the vagus nerve, the accessory nerve and the internal jugular vein. Hayek's assertion is undoubtedly correct.

However, with regard to Type II bridging, no interpretation can be given. Type II bridging is completed by the contact of the intrajugular process of the temporal bone and the bony process of the occipital bone projecting posterior to the hypoglossal canal. Probably this form of bridge develops along the dural sheath between the vagus and accessory nerves, and the internal jugular vein (Fig. 12). Therefore, it is suggested that the posterolateral part of the jugular foramen with a Type II bridging transmits the internal jugular vein alone.

The pattern of incidence of jugular foramen bridging in the Japanese fetal and adult cranial series closely resembles that of bony bridging of the hypoglossal canal studied previously (Dodo, 1980). In the majority of cases, both bridging traits make their appearance during the fetal period. In both cases, neither sex nor left-to-right differences in incidence are found. A high correlation of occurrence is observed between the two sides for both bridging traits.

However, since an interrelation of occurrence of jugular foramen bridging and hypoglossal canal bridging could never be observed, the two bridging traits seem to develop quite independently.

The fact that almost all the cases of bridging of the jugular foramen are already

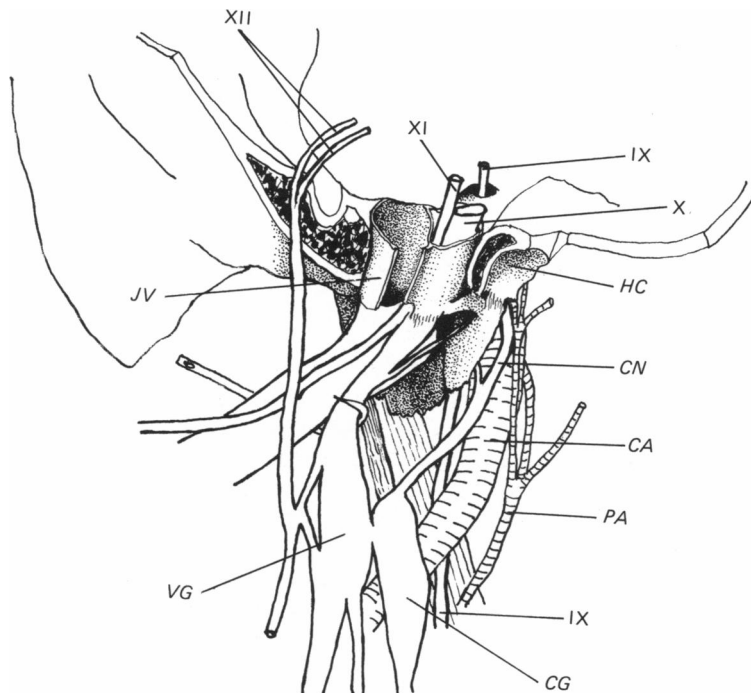


Fig. 12. Nerve-vessel relations in the jugular foramen region of a dissected adult cadaver. IX, glossopharyngeal nerve; X, vagus nerve; XI, accessory nerve; XII, hypoglossal nerve; JV, internal jugular vein; HC, posterosuperior portion of the hypoglossal canal; CN, internal carotid nerve; CA, internal carotid artery; PA, ascending pharyngeal artery; CG, superior cervical ganglion of the sympathetic trunk; VG, inferior ganglion of the vagus nerve. Note that the vagus and accessory nerves are contained in the same sheath of dura mater and separated from the glossopharyngeal nerve by a fibrous septum.

established by the end of fetal development suggests the existence of genetic factors in the expression of the bridging trait and indicates that the trait can be used effectively for anthropological population studies.

SUMMARY

The anatomical nature and pattern of incidence of bony bridging of the jugular foramen was investigated using 64 fetal crania aged nine months to term and 222 adult crania of Japanese. In addition, the region of the jugular foramen of an adult cadaver was carefully dissected in order to clarify the relationship between the cranial nerves passing through the jugular foramen and the intrajugular processes of the jugular foramen.

The general conclusions concerning the anatomical nature of the bony bridging of the jugular foramen were as follows. (1) The intrajugular process of the temporal bone is situated posterior to the triangular depression (as described in *Gray's Anatomy*) of the petrous part. (2) The bony bridging of the jugular foramen is established by the contact of the intrajugular process of the temporal bone with the bony process of the occipital bone projecting either from just above the hypoglossal canal (Type I) or from posterior to the hypoglossal canal (Type II). (3) If both the processes of the occipital bone reach the intrajugular process of the temporal bone

simultaneously, the jugular foramen is divided into three compartments. (4) In the case of Type I bridging, the anteromedial compartment transmits the glossopharyngeal nerve, while the posterolateral compartment gives passage to the vagus nerve, the accessory nerve and the internal jugular vein. (5) In the case of Type II bridging, the anteromedial compartment contains the glossopharyngeal, vagus and accessory nerves, and the posterolateral compartment transmits the internal jugular vein. (6) When tripartite division of the jugular foramen occurs, the anteromedial compartment transmits the glossopharyngeal nerve, the middle compartment contains the vagus and accessory nerves, and the posterolateral compartment transmits the internal jugular vein.

Concerning the pattern of incidence of jugular foramen bridging in the Japanese fetal and adult cranial series, this is similar to that of the bony bridging of the hypoglossal canal. The fact that almost all the cases of bridging of the jugular foramen are already established by the end of fetal development must serve as a strong indication that this trait can be used effectively for anthropological population studies.

REFERENCES

- BERRY, A. C. & BERRY, R. J. (1967). Epigenetic variation in the human cranium. *Journal of Anatomy* **101**, 361-379.
- BREATHNACH, A. S. (ed.) (1965). *Frazer's Anatomy of the Human Skeleton*, 6th ed., p. 189. London: J. & A. Churchill.
- BROTHWELL, D. R. (1958). The use of non-metrical characters of the skull in differentiating populations. *Bericht über die 6. Tagung der Deutschen Gesellschaft für Anthropologie*, 103-109.
- CHARPY, A. & NICOLAS, A. (1911). *Poirier/Charpy Traité d'Anatomie Humaine*, Tome 1, pp. 204-205. Paris: Masson.
- CZARNETZKI, A. (1972). Epigenetische Skelettmerkmale im Populationsvergleich. III. Zur Frage der Korrelation zwischen der Grösse des epigenetischen Abstandes und dem Grad der Allopatrie. *Zeitschrift für Morphologie und Anthropologie* **64**, 145-158.
- DODO, Y. (1974). Non-metrical cranial traits in the Hokkaido Ainu and the Northern Japanese of recent times. *Journal of the Anthropological Society of Nippon* **82**, 31-51.
- DODO, Y. (1980). Appearance of bony bridging of the hypoglossal canal during the fetal period. *Journal of the Anthropological Society of Nippon* **88**, 229-238.
- ELZE, C. (1954). *Hermann Braus Anatomie des Menschen*, Bd. 1, 3. Aufl., p. 642. Berlin: Springer-Verlag.
- FERNER, H. & STAUBESAND, J. (1983). *Sobotta's Atlas of Human Anatomy*, vol. 1, 10th English ed., p. 29. Baltimore: Urban & Schwarzenberg.
- HAYEK, H. (1929). Über Teilung des Foramen jugulare. *Anatomischer Anzeiger* **68**, 65-70.
- KAMUO, Y. (1982). *Oral Anatomy*, vol. 1, 2nd ed., p. 128. Tokyo: Anatom. (In Japanese.)
- KOPFSCH, F. (1919). *Rauber's Lehrbuch der Anatomie des Menschen*, Abt. 2, 11. Aufl., pp. 63-66. Leipzig: Georg Thieme.
- LANG, J. & WEIGEL, M. (1983). Nerve-vessel relations in the region of the jugular foramen. *Anatomia clinica* **5**, 41-56.
- LAUGHLIN, W. S. & JÖRGENSEN, J. B. (1956). Isolate variation in Greenlandic Eskimo crania. *Acta genetica et statistica medica* **6**, 3-12.
- OSSENBERG, N. S. (1969). Discontinuous morphological variation in the human cranium. Doctoral dissertation, University of Toronto.
- PIETRUSEWSKY, M. (1971). Application of distance statistics to anthroposcopic data and a comparison of results with those obtained by using discrete traits of the skull. *Archaeology and Physical Anthropology in Oceania* **6**, 21-33.
- ROMANES, G. J. (1981). *Cunningham's Textbook of Anatomy*, 12th ed., p. 115. Oxford: Oxford University Press.
- SCHAEFFER, J. P. (ed.) (1953). *Morris' Human Anatomy*, 11th ed., pp. 143, 164. New York: McGraw-Hill.
- SHARPEY, W., THOMSON, A. & CLELAND, J. (1867). *Quain's Elements of Anatomy*, Vol. 1, p. 59. London: James Walton.
- SHIMA, G. (1941). Craniology of the Mongol. *Anthropological Paper, Anthropological Society of Nippon* **A 2**, 1-108. (In Japanese, with German summary).
- SIEGLBAUER, F. (1927). *Lehrbuch der normalen Anatomie des Menschen*, p. 201. Berlin: Urban & Schwarzenberg.

- SPANNER, R. (1953). *Spalteholz Handatlas und Lehrbuch der Anatomie des Menschen*, Bd. 1, 15. Aufl., p. 464. Amsterdam: Scheltema & Holkema.
- SPEE, G. (1896). *Bardeleben Handbuch der Anatomie des Menschen*, Bd. 1, pp. 108, 174. Jena: Gustav Fischer.
- STAUBESAND, J. (1978). *Benninghoff/Goerttler Lehrbuch der Anatomie des Menschen*, Bd. 1, 12. Aufl., pp. 495, 510. München: Urban & Schwarzenberg.
- TÖNDURY, G. (1968). *Rauber/Kopsch Lehrbuch und Atlas der Anatomie des Menschen*, Bd. 1, 20. Aufl., pp. 459, 482. Stuttgart: Georg Thieme.
- WARWICK, R. & WILLIAMS, P. L. (ed.) (1973). *Gray's Anatomy*, 35th ed., pp. 287, 294, 1017-1020. Edinburgh: Longman.
- YAMAGUCHI, B. (1967). A comparative osteological study of the Ainu and the Australian Aborigines. *Australian Institute of Aboriginal Studies, Occasional Paper* (10), 1-73.