

A Golgi study of the sixth layer of the cerebral cortex. II. The gyrencephalic brain of Carnivora, Artiodactyla and Primates

I. FERRER, I. FABREGUES AND E. CONDOM

*Unidad de Neuropatología, Departamento de Anatomía Patológica,
Hospital Principes de España, Hospitalet de Llobregat, Barcelona, Spain*

(Accepted 8 August 1985)

INTRODUCTION

Studies of a number of gyrencephalic species have shown that neurons of the sixth layer of the cerebral cortex are the origin of many cortico-subcortical projections (Gilbert & Kelly, 1975; Lund & Hendrickson, 1975; Jones & Wise, 1977; Jones, Coulter, Burton & Porter, 1977; Harvey, 1978; Kosmal, Stepniewska & Markow, 1983) as well as the source of some callosal connections (Keller & Innocenti, 1981; Hornung & Garey, 1981; Wall, Symonds & Kaas, 1982; Jouandet, Garey & Lipp, 1984). Interlaminar long cortico-cortical ipsilateral connections in the sixth layer have also been demonstrated in selected areas of the cerebral cortex (Tigges, Spatz & Tigges, 1974; Spatz, 1977; Seltzer & Pandya, 1978; Rockland & Pandya, 1979; Weller & Kaas, 1978; Lin, Weller & Kaas, 1982; Friedman, 1983). Many observers have demonstrated that neurons of this layer are target sites for distinct thalamic terminations (Rosenquist, Edwards & Palmer, 1974; Jones & Burton, 1976; Wall *et al.* 1982).

These observations have given support to early investigations, based on the Golgi method, which postulated projection functions for a number of neurons located in the sixth layer (Ramon y Cajal, 1911; O'Leary, 1941; Tunturi, 1971; Valverde, 1978; Lund, Henry, McQueen & Harvey, 1979). In addition, recent studies have extended the pioneering work of Ramon y Cajal (1911) on the presence of several types of short axon neurons (local circuit neurons) in the sixth layer in cats and monkeys (Tömböl, 1976, 1978 *a, b*, 1984; Peters & Regidor, 1981). Taken together these data suggest a basic uniformity in the structure of the sixth layer in gyrencephalic species, although many differences may exist in the neuronal morphology of species with lissencephalic brains (Ferrer, Fabregues & Condom, 1986).

Further, cellular orientation varies among gyral, intermediate and fissural regions of gyrencephalic brains (Miodonski, 1974; Tömböl, 1984).

The present study deals with neuronal structural form and cellular distribution in the sixth layer of the cerebral cortex in several species with gyrencephalic brains in the Carnivora (dog and cat), Artiodactyla (cow and sheep) and the Primates (man). Results are then compared with those observed in lissencephalic species.

MATERIAL AND METHODS

The brains of adult cats and 15–20 days old kittens, adult and 15–20 days old dogs, adult cows and adult sheep were used in the present study.

The cats and dogs were killed under pentobarbital anaesthesia and the cows and

sheep under appropriate slaughterhouse conditions (compressed air bolts and beheading) and the brains rapidly removed and processed according to the rapid Golgi method (Ferrer *et al.* 1986), or fixed with glutaraldehyde-paraformaldehyde (1-2.5 %; vol/vol) for current histological methods in paraffin sections.

The regions studied in the cats' brains were the lateral gyrus and sulcus and the middle suprasylvian gyrus and sulcus.

The regions studied in the dogs' brains were the ectolateral gyrus and sulcus, the lateral gyrus and sulcus, and the middle suprasylvian gyrus and sulcus.

Samples from the parietal and frontal cortex were obtained from the brains of the cows and sheep.

In addition tissue samples (temporal and frontal lobes) from human infant brains aged 2, 3, 4, and 6 months and 1 year old were obtained at autopsy. The infants died of different, non-neurological diseases. The tissue samples in these cases were also processed with the rapid Golgi method or stained with cresyl violet in paraffin sections.

RESULTS

Layer VI of the dog

General microscopical findings of the cerebral cortex

In cresyl violet stained sections, marked differences were observed between the gyral, intermediate and fissural (sulcal) regions. The total thickness of the cortex was about 2000, 1600 and 1400 μm in gyral, intermediate and fissural regions of the middle suprasylvian gyrus and sulcus, the sixth layer accounting for 450, 270 and 270 μm respectively. The inner region of the cortex (layer VI) consisted of lamina VIa, in which spindle shaped or triangular cell bodies predominated, and lamina VIb, in which fusiform somas and a lesser number of globular cells were the main neuronal profiles encountered. The cellular bodies in the fissural and the intermediate regions were orientated horizontally but, in the gyral regions, neurons were arranged vertically (Fig. 1).

The fissural and the intermediate cortex in Golgi preparations

The apical processes of pyramidal cells converged on the pial surface in the fissural cortex; the cellular bodies of these neurons were triangular in all layers but in lamina VIa and VIb fusiform, tangentially oriented somas were predominant. Projection neurons of lamina VIa were large and medium sized pyramidal neurons, atypical or asymmetrical pyramidal cells, multiapical pyramidal neurons, spinous multipolar cells with long descending axons penetrating the white matter and medium sized fusiform neurons; small pyramidal cells were stained in lesser numbers.

Projection neurons of lamina VIb were medium sized and small pyramidal neurons with long descending axons, large fusiform neurons, horizontal or tangential pyramidal cells and spinous multipolar neurons with long descending axons (Fig. 2A).

Pyramidal neurons of the sixth layer frequently had the origin of the apical dendrite at one pole of the soma; the apical dendrite then curved towards the pial surface. Basilar dendrites were oriented horizontally and extended within the same layer. The apical dendrite of large pyramidal neurons reached the first layer, thus covering the whole thickness of the cortex. However, medium sized pyramidal cells only reached the middle layers of the cortex, and small pyramidal cells spread their apical dendritic arbor within the sixth layer and the inner level of the fifth.

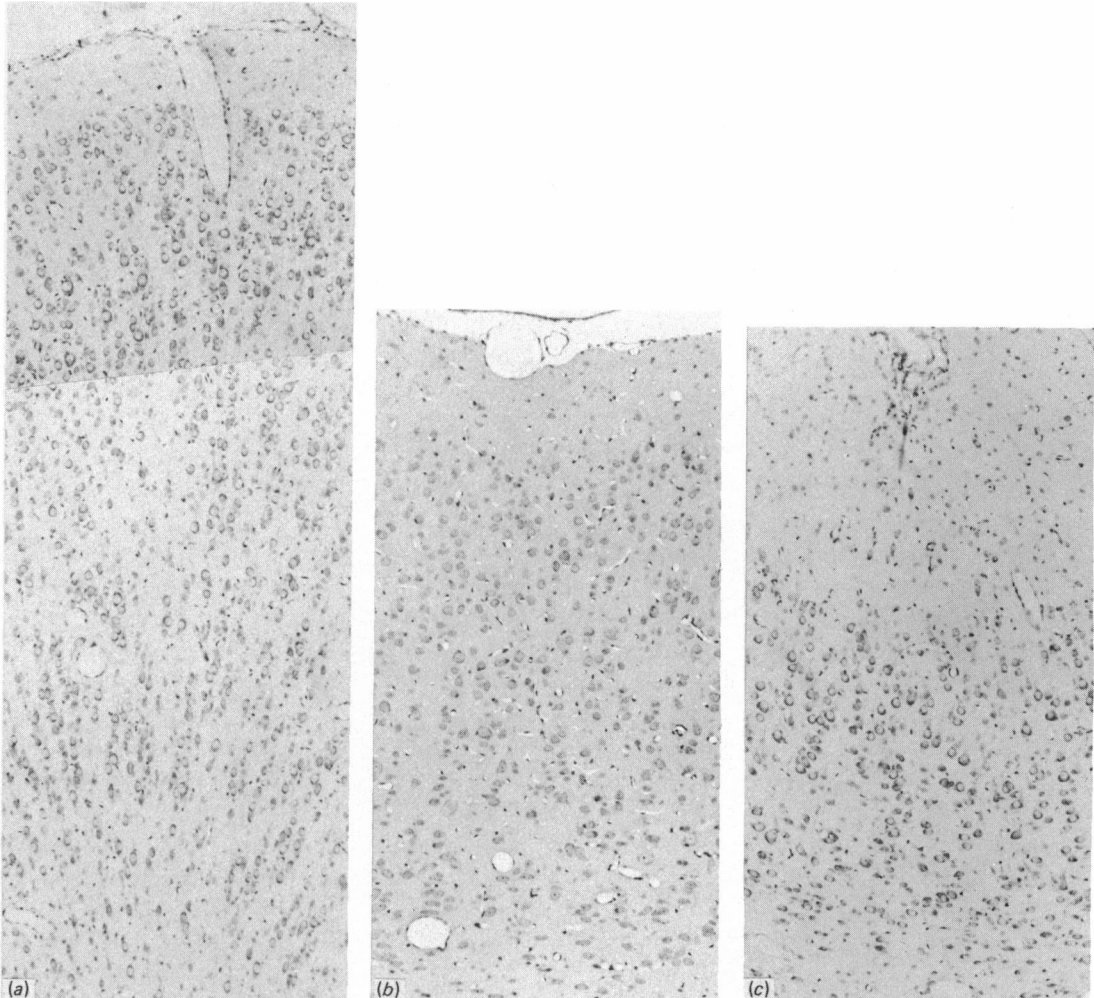


Fig. 1 (a-c). Comparative aspects between gyral (a), intermediate (b), and fissural (c) regions of the lateral gyrus and sulcus of the dog brain. With the exception of the molecular layer, cortical thickness is smaller in the sulcus than in the gyrus. Note the vertical arrangement of layer VI neurons in the gyrus and tangential orientation of these cells in intermediate and fissural regions. Nissl stain. $\times 63$.

Atypical or asymmetrical pyramidal cells had a characteristic, very long, basilar dendrite about $400\ \mu\text{m}$ in length, which emerged from one pole of the soma. In most instances the basilar dendrite was thicker than the apical dendrite.

Multipical pyramidal neurons had a distinctive apical dendritic arbor characterised by several apical dendrites emerging from the upper border and the poles of the soma. Apical dendrites were directed toward the upper layers of the cortex and occupied a width of about $200\text{--}300\ \mu\text{m}$.

Both asymmetrical and multipical pyramidal cells were then considered subtypes of pyramidal neurons with specialised dendritic arbors.

The axon of pyramidal neurons always descended towards the white matter but, before penetrating it, many horizontal collateral branches emerged. Some of them established contacts with basilar dendrites of neighbouring pyramidal cells (Fig. 2B).




Fig. 2(A-B). (A) Camera lucida drawing of the sulcal region (layers I-VI) in the dog cerebral cortex, neurons of the sixth layer in particular being illustrated. (B) Horizontal axonic collateral of a pyramidal neuron in contact with a dendrite of a neighbouring pyramidal cell. *P*, pyramidal neuron; *aP*, atypical pyramidal cell; *maP*, multipolar pyramidal neuron; *hP*, horizontal pyramid; *M*, Martinotti cell; *F*, fusiform neuron. Large arrows indicate the course of the axons; small arrows show the course of horizontal collaterals; the asterisk denotes the ascending collateral of a pyramidal neuron. Rapid Golgi method. $\times 1000$.

An ascending collateral directed to the middle layers of the cortex was also stained in most pyramidal neurons of lamina VIa.

Multipolar spinous neurons with long descending axons penetrating deeply into the white matter had a globular or polygonal cell body from which six to eight poorly ramified spinous dendrites emerged. These dendrites were oriented radially and spread for a length of about 100–150 μm . The axons of these cells descended towards the white matter giving off few collaterals.

Fusiform neurons were medium sized in lamina VIa and large in lamina VIb; fusiform neurons had a horizontal soma, with stout spinous dendrites emerging from

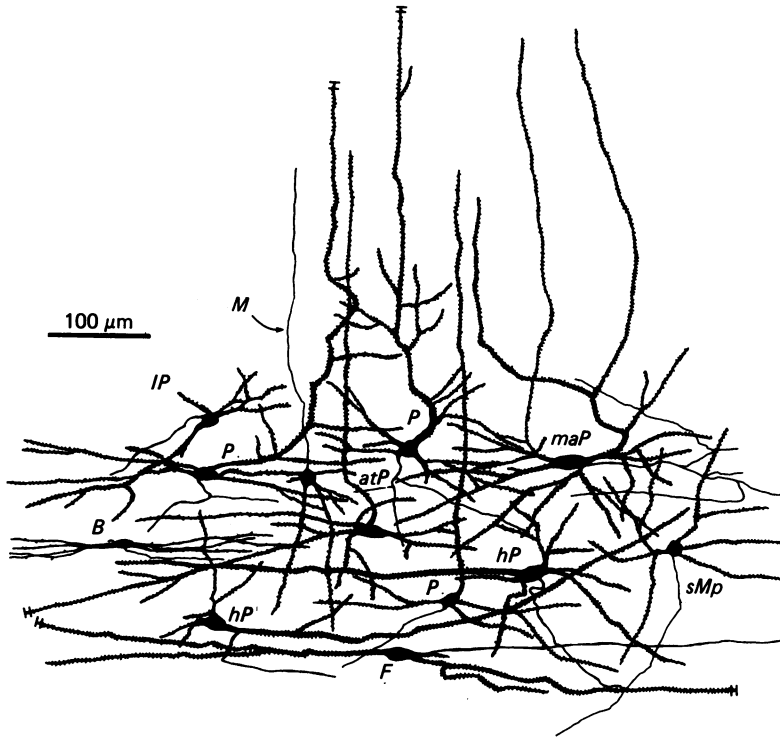


Fig. 3. Neurons of the sixth layer in the intermediate region of the dog cerebral cortex. *P*, pyramidal neuron; *maP*, multiapical pyramidal cell; *atP*, atypical pyramidal neuron; *IP*, inverted pyramid; *M*, Martinotti cell; *B*, bipolar neuron; *hP*, horizontal pyramidal neuron; *sMp*, spinous multipolar cell with long descending axon; *F*, fusiform neuron.

each pole. These dendrites were very long in large fusiform cells, often reaching a length of 700–800 μm . The axon emerged from the soma or from the proximal region of a dendrite and rapidly curved to take a tangential course within the inner region of the cortex or the upper border of the white matter. Axons of large fusiform cells had the trajectory of subcortical U fibres and could be followed for a distance of about 5 mm in some cases.

Horizontal pyramidal neurons were arranged tangentially and had a very long dendrite emerging from one pole of the soma. The basilar dendrites originated at right angles from the soma, dendrites directed upwards being longer than those directed towards the white matter. The axon of horizontal pyramidal neurons originated in the soma or in the proximal region of the long dendrite and passed obliquely toward the white matter, giving off a long horizontal collateral before penetrating it. Similar types of neurons to those described were also observed in the intermediate regions (Fig. 3).

The gyral cortex in Golgi preparations

Main projection neurons of lamina VIa in the gyral regions were large and medium sized pyramidal cells, asymmetrical pyramidal neurons, medium sized fusiform neurons and spinous multipolar neurons with long descending axons. Projection neurons of lamina VIb were medium sized and small pyramidal neurons,

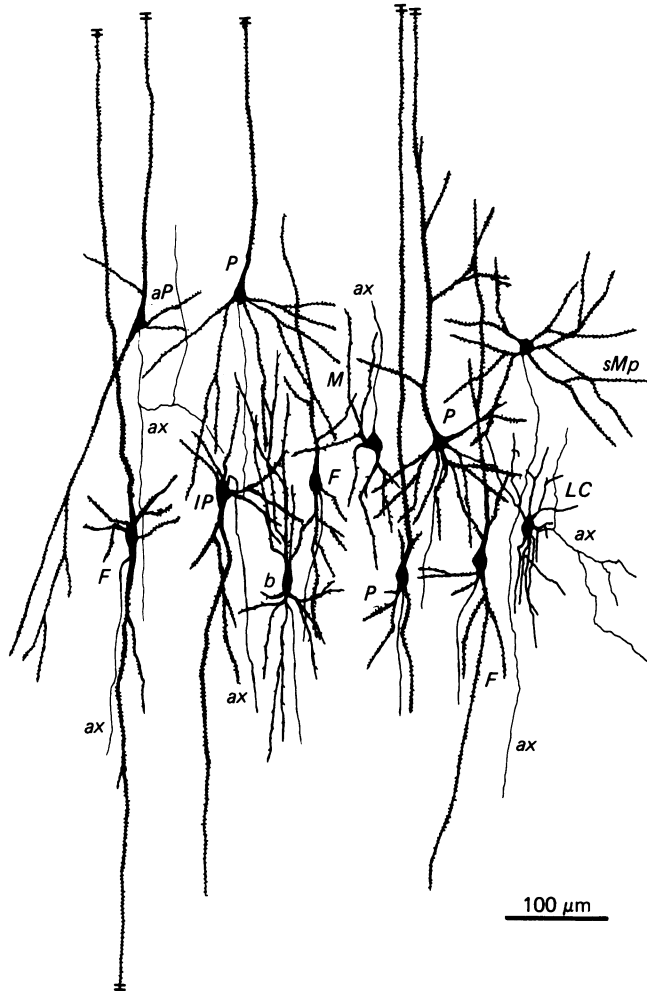


Fig. 4. Neurons of the sixth layer in the gyral region of the dog cerebral cortex. *P*, pyramidal neuron; *IP*, inverted pyramid; *sMp*, spinous multipolar neuron; *M*, Martinotti cell; *F*, fusiform neuron; *b*, bipolar cell; *LC*, local circuit neuron; *ax*, axons.

spinous multipolar neurons with long descending axons, large fusiform cells and inverted pyramidal neurons (Fig. 4).

Pyramidal neurons had a spindle shaped soma and obliquely descending basal dendrites. The apical dendrite was directed upwards in a straight line and reached the upper layers of the cortex in the case of large pyramidal neurons, but only the inner region of the fifth layer in the case of small pyramidal neurons.

Atypical or asymmetrical pyramidal neurons had a long basal dendrite emerging from one of the basal vertices of the triangular soma. This asymmetrical dendrite descended for a distance of about 300–400 μm .

The axons of typical and atypical pyramidal neurons were directed towards the white matter, giving off several collateral branches before penetrating it. Characteristically one of these collaterals had ascended towards the middle layers of the cortex.

Fusiform neurons in the gyral region were vertically arranged and showed very

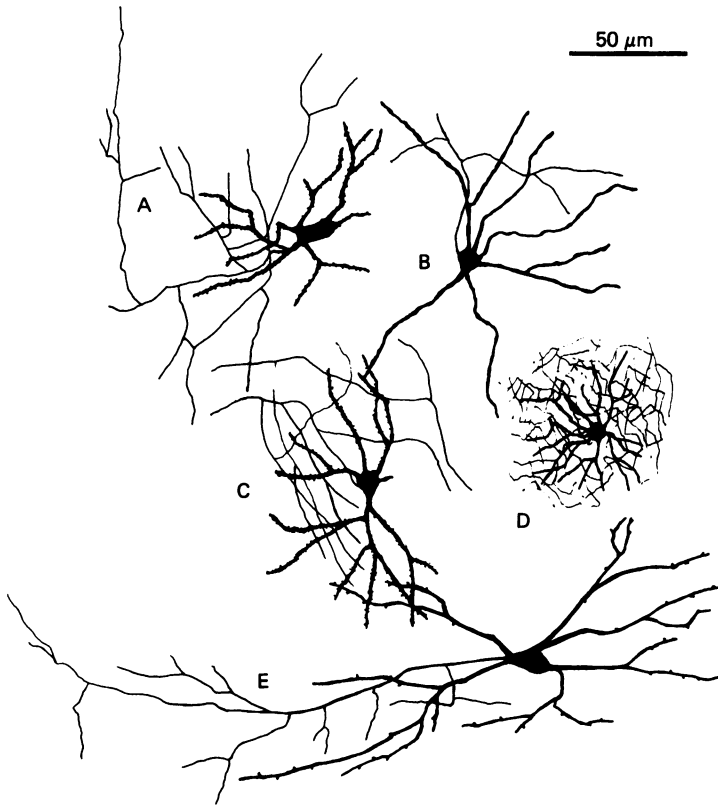


Fig. 5. Local circuit neurons of the sixth layer. A, sparsely spinous multipolar neuron with short axon; B, smooth multipolar neuron; C, small globular neuron with whirled axon; D, neurogliaform neuron; E, basket cell.

long, stout dendrites emerging at each pole of the soma. The axon originated in the soma or in the proximal region of the descending dendrite, and penetrated deeply into the white matter.

Inverted pyramidal neurons were mainly observed in lamina VIb. These cells had a triangular soma from which a stout descending dendrite emerged. The axon originated from one side of the soma or from the proximal segment of the main dendrite and descended towards the white matter.

Local circuit neurons in Golgi preparations

Several types of neuron with a short axon were observed in the sixth layer of the gyral, intermediate and fissural regions. The main neuronal types were Martinotti cells, neurogliaform neurons, basket cells, small neurons with whirled axons, sparsely spinous and spine-free (smooth) multipolar neurons and bipolar cells.

Martinotti cells (Figs. 2-4) had a triangular or polygonal soma with radially oriented asymmetrical dendrites. Although neuronal structure varied from cell to cell, the axon always ascended towards the upper layers of the cortex. In fact, the axons of Martinotti cells, together with the ascending collaterals of pyramidal neurons and subtypes, represented the main source of the ascending intracortical fibrillary subsystem originating in the sixth layer.

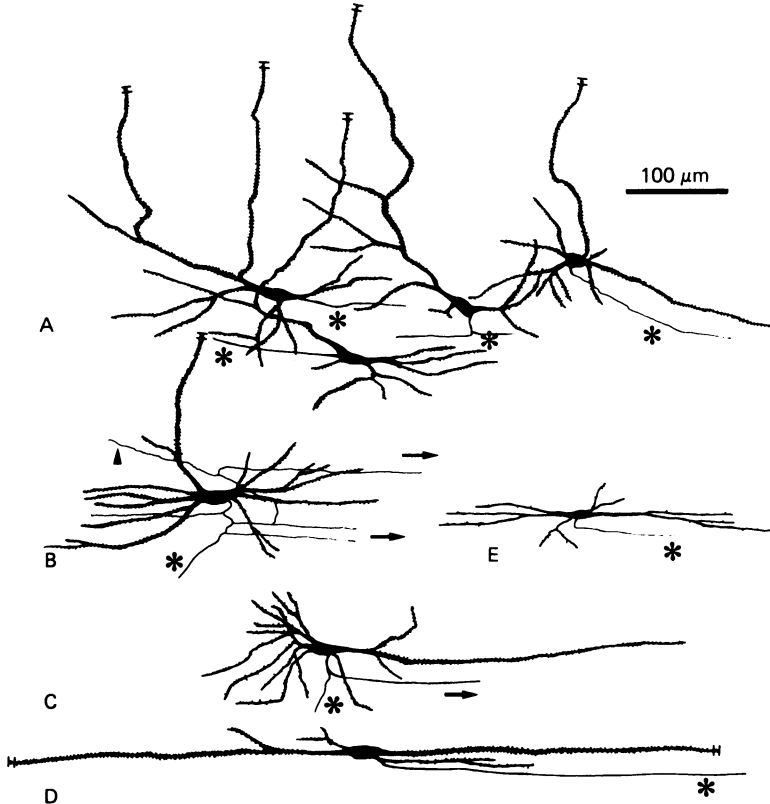


Fig. 6. Horizontal fibrillary system in intermediate and fissural regions of the cerebral cortex. A, pyramidal neurons; B, pyramidal neuron with multiple horizontal collaterals; C, horizontal pyramidal neuron; D, fusiform cell; E, bipolar neuron. Asterisks indicate the course of the axon; arrows show the course of horizontal collaterals.

Neurogliaform neurons (Fig. 5D) had small and round somas from which large numbers of fine and smooth dendrites emerged. The axons of these cells ramified to a considerable extent around the cellular body, thus mimicking the form of a claw.

Basket cells (Fig. 5E) were similar to those observed in other layers of the cortex. Although the cellular morphology was similar to other multipolar neurons, the axon had a horizontal course giving off several perpendicular and short collateral branches.

Small neurons with whirled axons (Fig. 5C) were considered to be a separate type of multipolar neuron because the spread of their axons was characteristic of these cells. The axon emerged from the upper border of the soma and then branched consecutively in several concentric collaterals around the soma.

Sparsely spinous and spine-free multipolar cells (Fig. 5A, B) probably formed a heterogeneous group of neurons. The soma was of a triangular, polygonal or globular shape from which radially oriented dendrites emerged. Some neurons had asymmetrical dendrites sometimes mimicking obliquely oriented or tangential pyramidal neurons; others, however, had six to eight poorly ramified radial dendrites. In any case, neurons were sparsely spinous or spine-free, thus lacking the large number of spines which was considered a typical feature of true pyramidal cells. The axon emerged from any point of the soma or from the proximal segment of a dendrite and ramified rapidly as several local branches distributed at random.

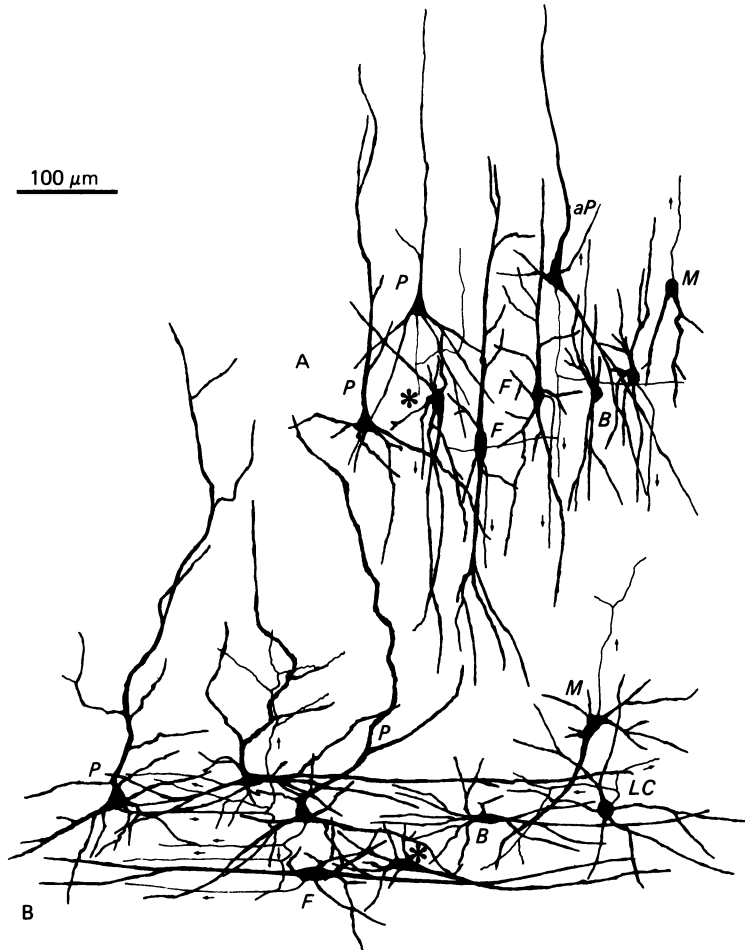


Fig. 7(A-B). Camera lucida drawing of neurons of the sixth layer in the gyral (A) and fissural (B) regions of the cat cerebral cortex. *P*, pyramidal neuron; *aP*, atypical pyramidal cells; *M*, Martinotti cells; *F*, fusiform neurons; *B*, bipolar cells; *LC*, local circuit neuron. Asterisks show an inverted pyramidal cell in the gyrus and a horizontal pyramidal cell in the fissural region. Small arrows point out the course of the axons and collaterals.

Neurogliaform neurons, basket cells, small neurons with whirled axons and sparsely spinous and spine-free multipolar cells were considered the main source of the local intracortical fibrillary subsystem.

Bipolar cells (Figs. 2, 4, 6E) had a fusiform or spindle shaped soma with many sparsely spinous or smooth dendrites emerging at each pole. Some neurons had one or two dendrites emerging at each pole, but a tuft of fine, long dendrites was observed in other cells. The length of the dendrites varied from cell to cell but was about 200 μm in the case of large bipolar cells.

The axon emerged from the soma or frequently from the proximal region of a dendrite and followed the direction of the major axis of the dendritic arbor.

Bipolar cells were distinctly oriented in gyral, fissural and intermediate regions. Thus they had a vertical orientation in the gyral region, but were tangentially arranged in the fissural and intermediate regions.

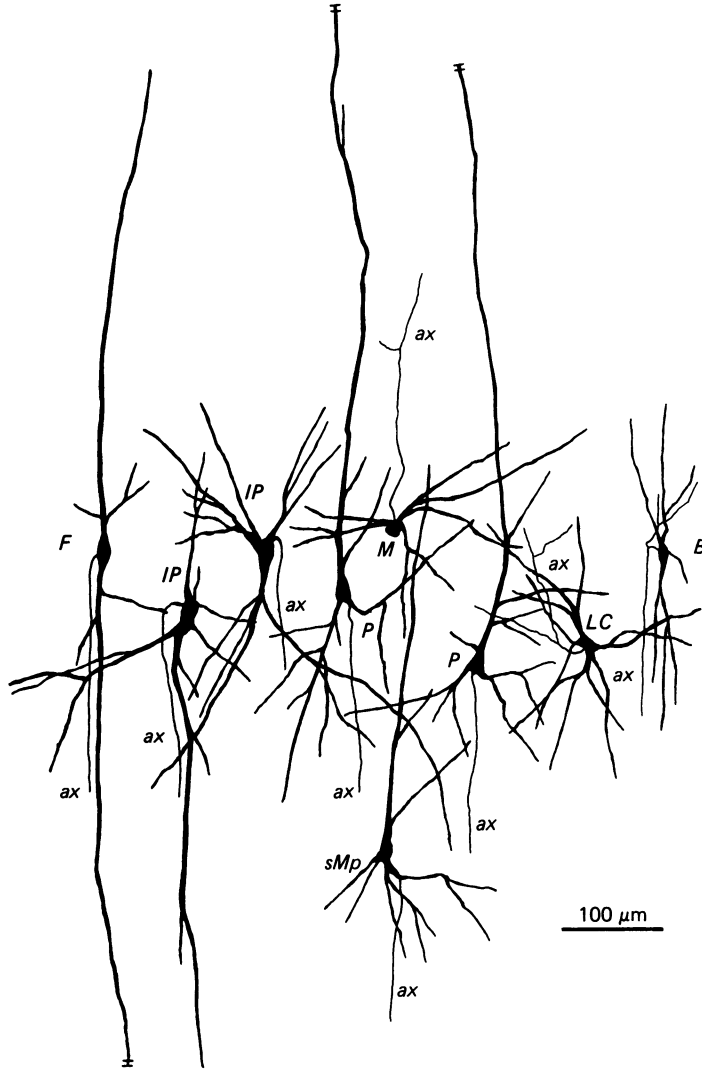


Fig. 8. Neurons of the sixth layer in the gyral region of the sheep cerebral cortex. *P*, pyramidal neuron; *IP*, inverted pyramidal cell; *F*, fusiform neuron; *M*, Martinotti cell; *B*, bipolar neuron; *LC*, local circuit neuron; *ax*, axons.

The horizontal intracortical fibrillary system of layer VI

As shown in Figures 2, 3 and 6, a major characteristic of lamina VIb in fissural and intermediate regions was the great development of the horizontal fibrillary system.

Four neuronal types were the main source of horizontal axons. Pyramidal neurons had horizontal axons and tangential collaterals distributed in the sixth layer. Some of them appeared to make contact with basilar dendrites of neighbouring pyramidal cells, but others were followed for distances of about 500 μm without observing contacts (Figs. 2B; 6A, B).

Horizontal pyramidal cells always had a tangential collateral running in the sixth layer (Fig. 6C). Fusiform neurons had a stout axon which was followed at times for

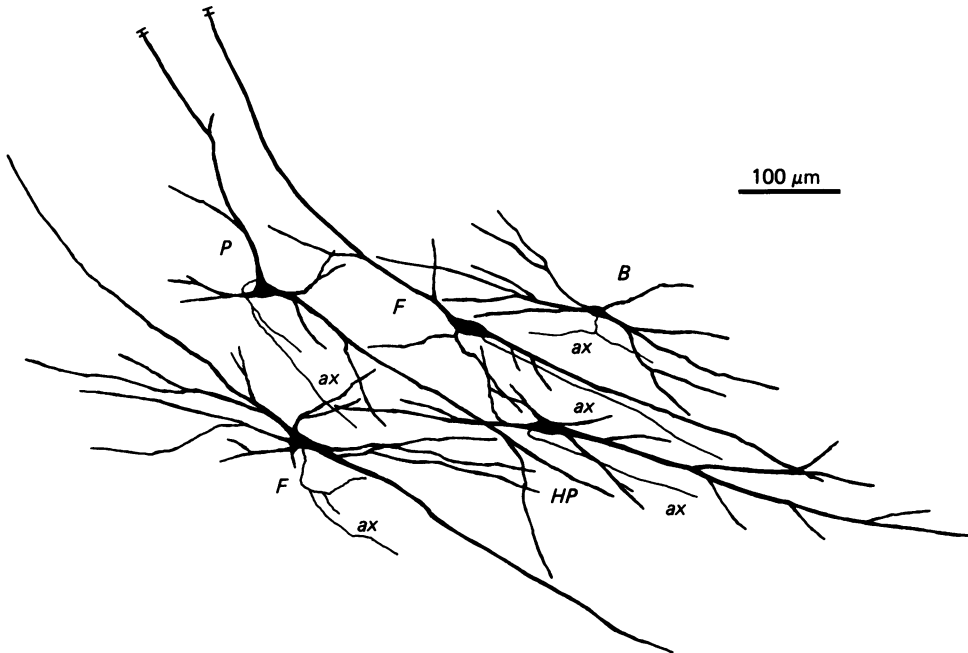


Fig. 9. Neurons of the sixth layer in the transitional zone between the gyrus and the intermediate zone of the sheep cerebral cortex. *P*, pyramidal neuron; *F*, fusiform cell; *HP*, horizontal pyramid; *B*, bipolar neuron; *ax*, axons.

a distance of about 4–5 mm (Fig. 6D). Finally, bipolar cells had short axonal horizontal spreads (Fig. 6E).

Layer VI of the cat, cow and sheep

Similar morphological characteristics to those described in the dog were observed in these species (Figs. 7, 8). Differential patterns in gyral, intermediate and fissural regions were also present in other Carnivora (cat), as well as in Artiodactyla (cow and sheep).

Figure 9 illustrates the boundary between the gyral and the intermediate regions. Fusiform neurons, inverted pyramids and bipolar cells curved to adopt the characteristic tangential pattern of the intermediate region from the vertical pattern characteristic of the gyrus.

Layer VI of the human infant

As shown in Figure 10, the neuronal morphology and the cellular arrangement of neurons in the sixth layer in the gyrus and in the sulcus were similar to those described in other gyrencephalic species.

DISCUSSION

General comments

A basic uniformity in the structure of the sixth layer of the cerebral cortex is observed in several species with gyrencephalic brains. The different neuronal types can be classified, according to the course and distribution of their axons, into projective and associative cells and local circuit neurons. Main projection and long

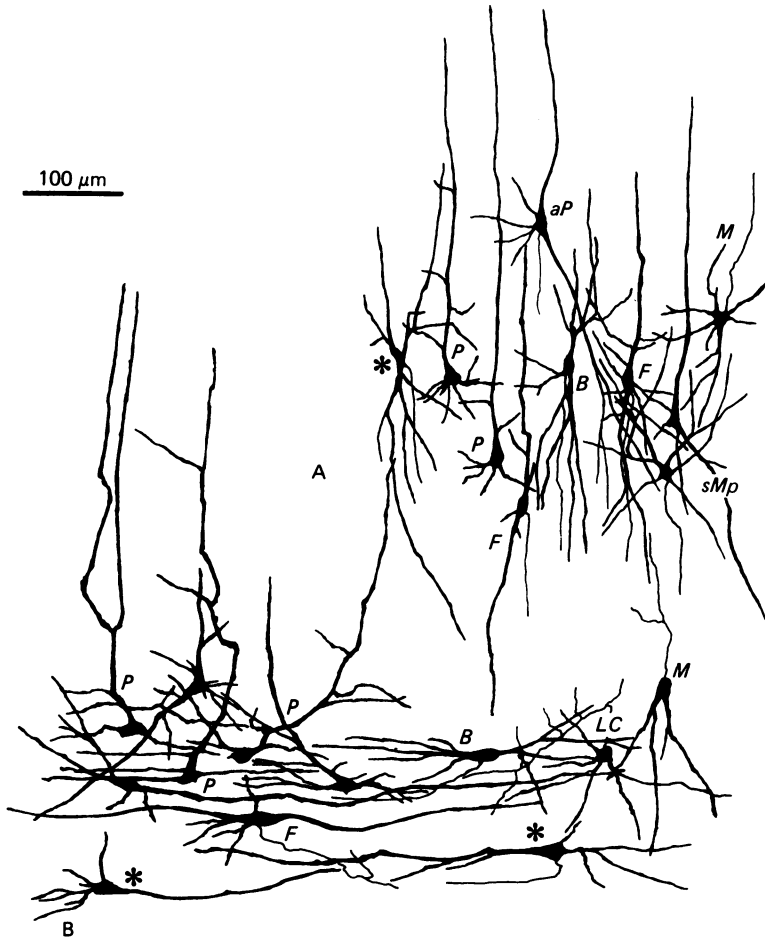


Fig. 10(A-B). Neurons of the sixth layer in the gyrus (A) and sulcus (B) of the cerebral cortex of the human infant. *P*, pyramidal neuron; *aP*, atypical pyramidal cell; *B*, bipolar neuron; *F*, fusiform cell; *M*, Martinotti cell; *LC*, local circuit neuron; *sMp*, spinous multipolar neuron with long descending axon. Asterisks show an inverted pyramidal cell in A, and a tangential (horizontal) pyramidal cell in B.

association neurons comprise pyramidal cells (large, medium sized, small, atypical or triangular and multiapical pyramidal neurons), inverted pyramids, fusiform neurons, horizontal pyramidal cells and spinous multipolar neurons with long descending axons penetrating deeply into the white matter. Main local circuit neurons comprise Martinotti cells, large and small bipolar neurons (called bipolar horizontal neurons when located in the intermediate and fissural regions), sparsely spinous and spine-free multipolar cells, smooth neurogliaform neurons, basket cells and sparsely spinous round neurons with whirled axons.

The distribution of these cells is not homogeneous but varies between the two laminae of the sixth layer. Large, medium sized atypical or triangular pyramidal cells, multiapical pyramidal neurons, Martinotti cells, basket cells and neurogliaform neurons predominate in lamina VIa; medium sized, small pyramids, multipolar neurons with long descending axons, bipolar neurons, large fusiform cells and

horizontal pyramids (in the fissural and intermediate regions) and inverted pyramidal cells (in gyral regions) predominate in lamina VIb; sparsely spinous and spine-free multipolar neurons with short axons are present in the two laminae of the sixth layer.

In the human brain, Ramon y Cajal (1911) reported the presence of medium sized pyramidal cells, triangular pyramidal neurons, small fusiform cells, small neurons with ascending axons, small neurons with short axons and neurogliaform neurons in layer VI (lamina VIa); and pyramidal cells, large fusiform neurons and multipolar neurons with short axons, some of them ascending to the upper layers of the cortex (Martinotti cells) in layer VII (lamina VIb).

In the cerebral cortex of the cat, Peters & Regidor (1981) have described three types of non-pyramidal neurons in the sixth layer: smooth or sparsely spinous horizontal neurons, sparsely spinous multipolar neurons with short axons (basket cells), and sparsely spinous multipolar neurons with descending axons. Horizontal neurons were not mentioned by O'Leary (1941) in the cerebral cortex of the cat, but at least two types of local multipolar neurons were illustrated; one of them with a short axonal spread, the other with an ascending axon directed toward the first layer, with the morphological features of Martinotti cells.

Recently, Tömböl (1984) has fully reviewed the morphology of layer VI cells in rabbits, cats and monkeys. The projection neurons of lamina VIa were named medium sized pyramidal neurons, multipolar cells with descending axons, small pyramidal and ovoid neurons. The projection neurons of lamina VIb consisted of medium sized and small pyramidal neurons, tangential or horizontal pyramidal neurons, medium sized neurons with ovoid cell bodies and tangential fusiform cells. Six types of local circuit neurons were described in lamina VIa: medium sized and small pyramidal cells with short axons, pyramidal neurons with tangential apical dendrites and ascending axons (Martinotti cells), basket cells, small neurons with round cell bodies (in which three subtypes were further considered: neurogliaform neurons, small round cells with sparsely spinous dendrites and medium sized round cells with smooth dendrites), ovoid bipolar horizontal neurons and large fusiform neurons with a short horizontal axon. Finally, four types of local circuit neurons were drawn in lamina VIb: fusiform cells with short axons (bipolar neurons), tangentially oriented smooth dendritic pyramidal neurons, medium sized bipolar neurons and small neurons with ovoid cell bodies with either spinous or smooth dendrites, and small neurons with round cell bodies and smooth dendrites.

A list comparing Tömböl's (1984) and the present nomenclature is given in Table 1. Major differences between the two classifications reside in bipolar cells and multipolar neurons with short axons. Ovoid neurons with bipolar and tangential dendrites, large fusiform neurons with tangential dendrites and short axons, fusiform short axon cells (or bipolar neurons) and medium sized bipolar neurons with spinous and smooth dendrites have been considered here as morphological varieties of bipolar neurons. Smooth round cells, tangentially oriented smooth dendritic pyramidal neurons, small neurons with ovoid cell bodies (spinous or smooth) and small neurons with round cell bodies and smooth dendrites have been included here under the term sparsely spinous and spine-free multipolar cells with short axons.

*Differences in the neuronal orientation between gyral, fissural
and intermediate regions*

A striking characteristic of the gyrencephalic brain is the progressive reduction in thickness (with the exception of the molecular layer) of the intermediate and fissural

Table 1. *Comparative nomenclature in Tömböl's (1984) and the present classification (right hand column) of the neurons in the sixth layer of the cortex in gyrencephalic species*

Lamina VIa	
<i>Projection neurons</i>	
Medium sized pyramidal cells	Large and medium sized pyramidal neurons (including atypical and multiapical)
Small pyramidal and ovoid	Small pyramidal cell
Multipolar	Spinous multipolar neurons with long long descending axons
<i>Local circuit neurons</i>	
Medium sized and small pyramids	
Pyramidal cells with ascending axons and tangential apical dendrites	
Basket neurons	Martinotti cells
Small neurons with round cell bodies	Basket neurons
Neurogliaform neuron	Neurogliaform neuron
Small cells with sparsely spinous dendrites	Sparsely spinous neurons with whirled axons
Smooth round cells	Spine-free multipolar neurons
Ovoid neurons with bipolar and tangential dendrites	} Bipolar neurons
Large fusiform neurons with tangential dendrites and short axons	
Lamina VIb	
<i>Projection neurons</i>	
Medium sized pyramidal neurons	Medium sized pyramidal neurons and small pyramids
Tangential or horizontal pyramidal neurons	Horizontal pyramids
Medium sized neurons with ovoid cell bodies	Inverted pyramids
Tangential fusiform neurons	Spinous multipolar neurons with long descending axons
	Fusiform neurons
<i>Local circuit neurons</i>	
Fusiform short axon cells or bipolar neurons	} Bipolar neurons
Medium sized bipolar neurons with spinous and smooth dendrites	
Tangentially oriented smooth dendritic pyramidal neurons	} Sparsely spinous and spine-free multipolar cells with short axon
Small neurons with ovid cell bodies spinous or smooth	
Small neurons with round cell bodies and smooth dendrites	

regions, and the different orientation of neurons in the sixth layer of the cortex resulting from cortical folding (Miodonski, 1974; Tömböl, 1984).

Pyramidal cells in the gyral region are elongated cells with the basilar dendrites directed downwards, but pyramidal cells in the sulcus have triangular cell bodies and long horizontal basilar dendrites; the apical dendrites in these cells often take an oblique or curved direction towards the upper layers of the cortex (Jones, 1975).

In the gyral region, triangular or atypical pyramidal neurons possess an elongated, descending asymmetrical basilar dendrite directed downwards, although the asymmetrical basilar dendrite becomes almost horizontal in the fissural and intermediate regions. Further multiapical pyramidal cells are fully developed in the latter regions, but the apical dendritic arbor of multiapical pyramidal cells is narrow in the gyral region.

Inverted pyramids are observed mainly in the gyrus, but horizontal pyramidal cells have been considered as a similar type of cell in the intermediate and fissural regions.

Fusiform cells and bipolar neurons are oriented vertically in the gyrus, but are arranged tangentially in the intermediate and fissural regions.

Although not yet proven in developmental studies, these regional differences may be a good example of neuronal plasticity secondary to folding.

Two relevant consequences result from these regional differences. First, the dendritic receptive fields are arranged vertically in the gyrus and horizontally in the fissural and intermediate regions. In the latter region, horizontal dendrites of tangential fusiform cells and horizontal pyramidal neurons may spread for a length of more than 800 μm , thus greatly exceeding the extent of the columnar modules which are considered to be the basic functional unit of the vertical organisation of the cerebral cortex (Szentágothai, 1975, 1978; Eccles, 1984). Fusiform neurons, horizontal pyramidal cells and bipolar neurons in the fissural and intermediate regions are cells which do not seem to participate in a modular concept of cortical organisation.

Second, horizontal axons and collaterals are greatly developed in the fissural regions thus contributing to interlaminar connections. Axons of fusiform neurons, and to a lesser degree axonal collaterals of horizontal pyramidal cells, have been followed in Golgi sections for a distance of more than 5 mm within the trajectory of U fibres, thus reaching the inner boundary of neighbouring cortical areas. Although further studies with adequate tracers will be necessary, fusiform cells have been tentatively considered to be the source of some cortico-cortical ipsilateral connections on the basis of results with the Golgi method.

*Common and specific morphological features in layer VI
of lissencephalic and gyrencephalic species*

In the first part of this study (Ferrer *et al.* 1986), the neuronal morphology and the cellular organisation of the sixth layer was described in several lissencephalic species. When these results were compared with those observed in gyrencephalic species, most of the cellular types were present in both smooth and convoluted cortices, as summarised in Table 2. However, three differences can be observed: (1) the characteristic orientation of particular neuronal types in the fissural, intermediate and gyral regions, which is the result of folding, is obviously not manifested in lissencephalic brains; (2) the local circuit subsystem is formed, in addition to basket cells and sparsely spinous and spine-free multipolar cells, by neurogliaform neurons and sparsely spinous round neurons with whirled axons in gyrencephalic species, but the latter types of neuron were never impregnated in lissencephalic brains; (3) the tangential system (projection and local) is better developed in gyrencephalic species, in which it is represented by the large fusiform neurons of lamina VIb, together with the large horizontal pyramidal neurons and the large bipolar cells. As discussed above, this tangential system (which is arranged vertically in gyral regions) has been tentatively considered as a major source of long and short cortico-cortical fibres of the sixth layer. This assumption may be corroborated by recent findings using horse-radish peroxidase as tracer. This demonstrates that certain neurons of the sixth layer are the origin of a large number of ipsilateral cortico-cortical connections in particular areas of the gyrencephalic brain (Tigges *et al.* 1974; Spatz, 1977; Seltzer & Pandya, 1979; Weller & Kaas, 1978; Lin *et al.* 1982; Friedman, 1983; Symonds & Rosenquist, 1984).

Table 2. *Neuronal types in the sixth layer of the cerebral cortex in lissencephalic and gyrencephalic species*

Lissencephalic	Gyrencephalic
<i>Projection neurons</i>	
Large, medium and small pyramidal neurons	Large, medium and small pyramidal neurons
Multiapical and atypical pyramids	Multiapical and atypical pyramids
Small fusiform (V)	Small fusiform (V: g; T: z. i., f)
	Large fusiform (V: g; T: z. i., f)
Spinous multipolar with long descending axons	Spinous multipolar with long descending axons
Inverted pyramid	Inverted pyramid (g)
Horizontal pyramid	Horizontal pyramid (z.i., f)
Fan shaped neuron	
<i>Local circuit neurons</i>	
Ascending subsystem	
Martinotti cells	Martinotti cells
(Ascending axon collaterals pyramidal cells)	(Ascending axon collaterals pyramidal cells)
Horizontal subsystem	
Bipolar cells	Bipolar cells (z.i., f)
(Axon collaterals of pyramidal and horizontal pyramidal cells)	(Axon collaterals of pyramidal and horizontal pyramidal cells)
Local subsystem	
Sparsely spinous and spine-free multipolar cells	Sparsely spinous and spine-free multipolar cells
Basket cells	Basket cells
Bi-tufted neurons	
	Neurogliaform neurons
	Sparsely spinous neurons with whirled axons

V, vertical; T, tangential; g, gyrus; z.i., intermediate zone; f, fissural region.

The great development of the sixth layer ipsilateral cortico-cortical fibrillary system in gyrencephalic species, then, may be considered a major step in neocortical evolution.

SUMMARY

The sixth layer of the cerebral cortex has been studied by means of the Golgi method in Carnivora (dog and cat), Artiodactyla (cow and sheep), and Primates (human) brains; a basic structural uniformity being observed in all these species.

Projection neurons of lamina VIa were large and medium sized pyramidal neurons (including atypical and multiapical), small pyramidal cells, and spinous multipolar neurons with long descending axons. Projection neurons of lamina VIb were medium sized pyramidal neurons and small pyramids, horizontal pyramids, inverted pyramidal cells, spinous multipolar neurons with long descending axons and large fusiform cells. Local circuit neurons of lamina VIa were Martinotti cells, basket neurons, neurogliaform cells, sparsely spinous neurons with whirled axons, spine-free multipolar cells and bipolar neurons. Local circuit neurons of lamina VIb were sparsely spinous and spine-free multipolar cells with short axons and bipolar neurons.

Marked differences were observed between gyral, intermediate and fissural regions. Fusiform and bipolar neurons were vertically arranged in the former, but were tangentially orientated in intermediate and fissural regions; inverted pyramidal cells were present in the gyrus but horizontal pyramids were the respective cells in the intermediate and fissural zones.

When compared with lissencephalic species, a great horizontal fibrillary system (which is vertically arranged in gyral regions) was observed in convoluted brains.

Cells of origin were fusiform neurons, bipolar cells, horizontal and inverted pyramids and pyramidal neurons (the latter by means of horizontal axonal collaterals). The great development of this cortico-cortical association system in gyrencephalic species is considered to be a major step in neocortical evolution.

The authors wish to thank L. Anzizu, J. Carol, J. Ferrer, A. Prat, J. Roca and R. Savall for the supply of different species used in the present study.

REFERENCES

- ECCLES, J. C. (1984). The cerebral cortex. A theory of its operation. In *Cerebral Cortex*, vol. 2, *Functional Properties of Cortical Cells* (ed. E. G. Jones & A. Peters), pp. 1–36. New York: Plenum Press.
- FERRER, I., FABREGUES, I. & CONDOM, E. (1986). A Golgi study of the sixth layer of the cerebral cortex. I. The lissencephalic brain of Rodentia, Lagomorpha, Insectivora and Chiroptera. *Journal of Anatomy* **145**, 217–234.
- FRIEDMAN, D. P. (1983). Laminar patterns of termination of cortico-cortical afferents in the somato-sensory system. *Brain Research* **273**, 147–151.
- GILBERT, C. D. & KELLY, J. P. (1975). The projections of cells in different layers of the cat's visual cortex. *Journal of Comparative Neurology* **163**, 81–106.
- HARVEY, A. R. (1978). Characteristics of corticothalamic neurons in area 17 of the cat. *Neuroscience Letters* **7**, 177–181.
- HORNUNG, J. P. & GAREY, L. J. (1981). The thalamic projection to cat visual cortex: ultrastructure of neurons identified by Golgi impregnation or retrograde horseradish peroxidase transport. *Neuroscience* **6**, 1053–1068.
- JONES, E. G. (1975). Varieties and distribution of non-pyramidal cells in the somatic sensory cortex of the squirrel monkey. *Journal of Comparative Neurology* **160**, 205–268.
- JONES, E. G. & BURTON, H. (1976). Areal differences in the laminar distribution of thalamic afferents in cortical fields of the insular, parietal and temporal regions of primates. *Journal of Comparative Neurology* **168**, 197–248.
- JONES, E. G., COULTER, J. D., BURTON, H., & PORTER, R. (1977). Cells of origin and terminal distribution of corticostriatal fibres arising in the sensory-motor cortex of monkeys. *Journal of Comparative Neurology* **173**, 53–80.
- JONES, E. G. & WISE, S. P. (1977). Size, laminar and columnar distribution of efferent cells in the sensory-motor cortex of monkeys. *Journal of Comparative Neurology* **175**, 391–438.
- JOUANDET, M. L., GAREY, L. J. & LIPP, H. P. (1984). Distribution of the cells of origin of the corpus callosum and anterior commissure in the marmoset monkey. *Anatomy and Embryology* **169**, 45–59.
- KELLER, G. & INNOCENTI, G. M. (1981). Callosal connections of suprasylvian visual areas in the cat. *Neuroscience* **6** 703–712.
- KOSMAL, A., STEPNIWSKA, I. & MARKOW, G. (1983). Laminar organization of efferent connections of the prefrontal cortex in the dog. *Acta neurobiologicae experimentalis* **43**, 115–127.
- LIN, C. S., WELLER, R. E. & KAAS, J. H. (1982). Cortical connections of striate cortex in the owl monkey. *Journal of Comparative Neurology* **211**, 165–176.
- LUND, J. & HENDRICKSON, A. (1975). The origin of efferent pathways from the primary visual cortex area 17 of the macaque monkey as shown by retrograde transport of HRP. *Journal of Comparative Neurology* **164**, 287–304.
- LUND, J. S., HENRY, G. H., MACQUEEN, C. L. & HARVEY, A. R. (1979). Anatomical organization of the primary visual cortex (area 17) of the cat. A comparison with area 17 of the macaque monkey. *Journal of Comparative Neurology* **184**, 599–618.
- MIODONSKI, A. (1974). The angioarchitectonics and cytoarchitectonics structure of the fissural frontal cortex in dog. *Folia biologica* **22**, 237–279.
- O'LEARY, J. L. (1941). Structure of the area striata of the cat. *Journal of Comparative Neurology* **75**, 131–164.
- PETERS, A. & REGIDOR, J. (1981). A reassessment of the forms of non-pyramidal neurons in area 17 of the cat visual cortex. *Journal of Comparative Neurology* **203**, 685–716.
- RAMON Y CAJAL, S. (1911). *Histologie du Système Nerveux de l'Homme et des Vertébrés*, pp. 571–575. (Reprinted by Consejo Superior de Investigaciones Científicas, Madrid. 1972).
- ROCKLAND, K. S. & PANDYA, D. N. (1979). Laminar origins and terminations of cortical connections of the occipital lobe in the Rhesus monkey. *Brain Research* **179**, 3–20.
- ROSENQUIST, A. C., EDWARDS, S. B. & PALMER, L. A. (1974). An autoradiographic study of the projections of the dorsal lateral geniculate nucleus and the posterior nucleus in the cat. *Brain Research* **80**, 71–93.
- SELTZER, B. & PANDYA, D. N. (1978). Afferent cortical connections and architectonics of the superior temporal sulcus and surrounding cortex in the Rhesus monkey. *Brain Research* **149**, 1–24.

- SPATZ, W. B. (1977). Topographically organized reciprocal connections between areas 17 and MT (visual area of the superior temporal sulcus) in the marmoset *Callithrix jacchus*. *Experimental Brain Research* **27**, 559–572.
- SYMONDS, L. L. & ROSENQUIST, A. C. (1984). Laminar origins of visual corticocortical connections in the cat. *Journal of Comparative Neurology* **229**, 39–47.
- SZENTÁGOTHAJ, J. (1975). The “module-concept” in cerebral cortex architecture. *Brain Research* **95**, 475–496.
- SZENTÁGOTHAJ, J. (1978). The neuron network of the cerebral cortex: a functional interpretation. *Proceedings of the Royal Society of London, B* **201**, 219–248.
- TIGGES, J., SPATZ, W. B. & TIGGES, M. (1974). Efferent cortico-cortical fiber connections of area 18 in the squirrel monkey. *Journal of Comparative Neurology* **158**, 219–236.
- TÖMBÖL, T. (1976). Golgi analysis of the internal layers (V and VI) of the cat visual cortex. *Experimental Brain Research, Suppl. I*, 292–295.
- TÖMBÖL, T. (1978*a*). Comparative data on the Golgi architecture of interneurons of different cortical areas in cat and rabbit. In *Architectonics of the Cerebral Cortex* (ed. M. A. B. Brazier & H. Petsche), pp. 59–76. New York: Raven Press.
- TÖMBÖL, T. (1978*b*). Some Golgi data on visual cortex of the Rhesus monkey. *Acta morphologica Academiae scientiarum hungaricae* **26**, 115–138.
- TÖMBÖL, T. (1984). Layer VI cells. In *Cerebral Cortex*, vol. 1, *Cellular components of the cerebral cortex* (ed. A. Peters & E. G. Jones), pp. 479–519. New York: Plenum Press
- TUNTURI, A. R. (1971). Classification of neurons in the ectosylvian auditory cortex of the dog. *Journal of Comparative Neurology* **142**, 153–166.
- VALVERDE, F. (1978). The organization of area 18 in the monkey *Anatomy and Embryology* **154**, 305–334.
- WALL, J. T., SYMONDS, L. L. & KAAS, J. H. (1982). Cortical and subcortical projections of the middle temporal area (MT) and adjacent cortex in Galagos. *Journal of Comparative Neurology* **211**, 193–214.
- WELLER, R. E. & KAAS, J. H. (1978). Connections of striate cortex with the posterior bank of the superior temporal sulcus in macaque monkeys. *Neuroscience Abstracts* **4**, 650.