

Continuous darkness and continuous light induce structural changes in the rat thymus

I. MAHMOUD, S. S. SALMAN AND A. AL-KHATEEB

Department of Anatomy, College of Medicine, Al-Mustansiriyah University, Baghdad, Iraq

(Accepted 27 January 1994)

ABSTRACT

It is known that neuroendocrine responses to environmental stimuli, such as light, can influence immune responses through the pineal gland. It is also known that periods of constant darkness and constant light cause stimulation and inhibition of melatonin secretion from the pineal gland, successively. In this study, we provide experimental evidence that changes in the rhythm of the photoperiod have considerable effects on thymic structure of the rat. Male albino Wistar rats were divided into 3 groups. Group 1 rats were kept in a dark room, group 2 in a room under a bright artificial light and group 3 (control) animals were exposed to a 12:12 h light:dark cycle. All animals were killed after 4 wk. In group 1, thymus weight increased by 315%, the increase in volume affecting the medulla (cortex 190%, medulla 655%). The absolute number of epithelial cells and lymphocytes increased both in the cortex and medulla. Thymic cortical epithelial cells were hypertrophied and contained numerous large clear vesicles. Perivascular spaces were enlarged. In group 2 thymus weight decreased by 53%, the reduction in volume affecting mainly the cortex (cortex 61%, medulla 27%). The absolute numbers of cortical epithelial cells and lymphocytes were decreased, and pyknotic lymphocyte nuclei were frequent both in the cortex and medulla. It is concluded that constant darkness causes hypertrophy and increased cellularity of the thymus, while constant light causes involution of the thymus and death of lymphocytes. These changes possibly reflect the well known immunostimulatory effects of melatonin acting directly or indirectly, on the thymic lymphocytes and epithelial cells.

Key words: Photoperiodicity; melatonin; neuroendocrine responses.

INTRODUCTION

There is a close relationship between the neuroendocrine responses to environmental stimuli and immune responses. These neuroendocrine responses have been shown to influence liability to infection, autoimmune disease and malignancy (Ader, 1981; Plotnikoff et al. 1986).

Environmental stimuli such as light and temperature are transduced into neuroendocrine signals by the cyclic circadian synthesis and release of melatonin by the pineal gland (Axelrod et al. 1982; Brown & Niles, 1982; Reiter, 1984) and alterations of the circadian rhythm of its release have been associated with anxiety states and other affective disorders, and malignancy (Birau, 1981; Brown & Niles, 1982). Stimulation of synthesis and secretion of melatonin was found to take place during a period of continuous darkness,

while inhibition of synthesis and secretion was shown to occur during a period of continuous light (Wurtman, 1967; Kinson & Peat, 1971; Shirama et al. 1982; for review, see Erlich & Apuzzo, 1985).

In addition to the pineal gland, it has been demonstrated that many of the photoperiodic responses are mediated through the hypophyseal-pituitary-endocrine axis in the hamster (Yellon & Goldman, 1984; Duncan et al. 1985; Vitale et al. 1985) and the rat (Takahashi et al. 1971).

There are relatively few studies on a possible connection between the pineal gland and the lymphopoietic system (Jankovic et al. 1970). Mice kept for 3 generations under constant environmental light do not grow normally and show marked atrophy of the thymolymphatic system (Maestroni & Pierpaoli, 1981) and permanent light causes a significant depression of humoral and cell-mediated immune responses in this

species (Maestroni & Pierpaoli, 1981). When melatonin is administered in a circadian fashion to normal adult mice, it has powerful immuno-augmenting properties (Maestroni et al. 1987a, b).

In this study the effect of permanent darkness and permanent light on thymic histology was tested.

MATERIALS AND METHODS

Male albino Wistar rats, aged 4–5 wk, were maintained in wire-mesh cages, 2 rats per cage, under controlled conditions and were fed a regular diet and water ad libitum. The ambient temperature was kept at 24 ± 2 °C. The rats were divided into 3 experimental groups, each comprising 6 rats. The 1st group was kept in a dark room for a period of 4 wk, the 2nd under a bright artificial light for 4 wk, and the 3rd in the animal house where the photoperiod was day-light:darkness 12:12 h (light 06.00–18.00 h).

Animals were killed by ether anaesthesia between 10.00 and 12.00 h. The thymus was removed, dissected free from adjacent connective tissue, and weighed. Taken randomly, one lobe was fixed in Bouin's fluid and embedded in paraffin wax; serial sections (5 μ m) were stained with haematoxylin and eosin. Three sections were taken from each lobe, 1 from the centre and 2 from the periphery and used for stereological analysis. The other lobe was cut into small fragments, fixed for 2 h in 4% glutaraldehyde, rinsed, and postfixed for 1 h in 1% osmium tetroxide. All solutions were buffered in 0.12 M phosphate buffer at pH 7.4 containing 0.5 M CaCl₂. The pieces were dehydrated in graded solutions of acetone, embedded in Epon-812, and 1 μ m sections cut with an LKB 14800 microtome and stained with toluidine blue (Bancroft & Stevens, 1982). These sections, 2 from each lobe, were used for stereological and morphological analyses.

Thymic volume was obtained by dividing thymic weight by 1.1, the assumed value for the density of thymic tissue (Scheiff et al. 1977). The stereological analysis was performed on a light microscope equipped for point counting with a Zeiss Integrating Micrometer-disk Turret I. The percentage of thymic cortex and medulla was calculated in paraffin sections by counting the number of points overlying each area. Absolute volumes of cortex and medulla were deduced from this percentage (Weibel et al. 1966). No estimation for fixation constants before and after fixation was performed, since tissue pieces were small and all fixatives and solutions were adjusted to isotonicity (Anderson, 1982).

The number of epithelial cells and lymphocytes per

mm² were calculated by counting their nuclei in Epon sections using the following formula:

$$A_i = \pi \frac{\sqrt{3}}{2} Z^2,$$

where A_i represents in mm² the part of total section area belonging to the tissue component i (cortex or medulla), π the number of points overlying this component, and Z the equivalent in mm of the distance between 2 points on the test system. Multinucleate epithelial cells were rare thus they were not considered in the calculations. Cell numbers per mm³ (numerical density) were calculated according to the following equation:

$$N_v = \frac{N_a}{(\bar{D} + t)} \quad (\text{Weibel, 1979}),$$

where N_v represents the number of nuclei per mm³, N_a the number of their profiles per mm², \bar{D} their mean equivalent diameter, and t the section thickness. For both epithelial cells and lymphocytes, the mean equivalent diameter had to be approximated by considering the largest profiles as equatorial sections of nuclei, all of which were assumed to be spherical and of the same size. This approximation was allowed since the size and shape of the nuclei did not change in the light or dark groups in comparison with the controls; the error was thus the same in all groups. The absolute number of each cell type was calculated by multiplying the number of cells per mm³ by the volume of the corresponding thymic region.

The use of an integral test system and sections of thickness less than the diameter of counted nuclei has been shown to provide for unbiased estimates of absolute numbers of cells (Sterio, 1984).

Statistical analysis

The results were evaluated statistically by the analysis of variance. When this was significant, Tukey's test (Honestly Significant Difference test, HSD; Daniel, 1978) was performed to localise the significance between the dark and light groups and the control group.

RESULTS

Stereology

Overall body weight was not affected by the dark or light periods (Table 1).

Continuous dark. The thymus underwent marked enlargement that resulted at the end of the dark

Table 1. The effect of dark and light periods on body and thymus weight in rats (mean \pm S.E.M.)

	Controls	Dark	Light
Body weight (g)	283 \pm 8.7	290 \pm 3.4	284 \pm 3.9
Thymus weight (mg)	365 \pm 26.9	1515 \pm 29.7	172 \pm 28.8*

* $P < 0.01$ vs control; d.f. = 2/15.

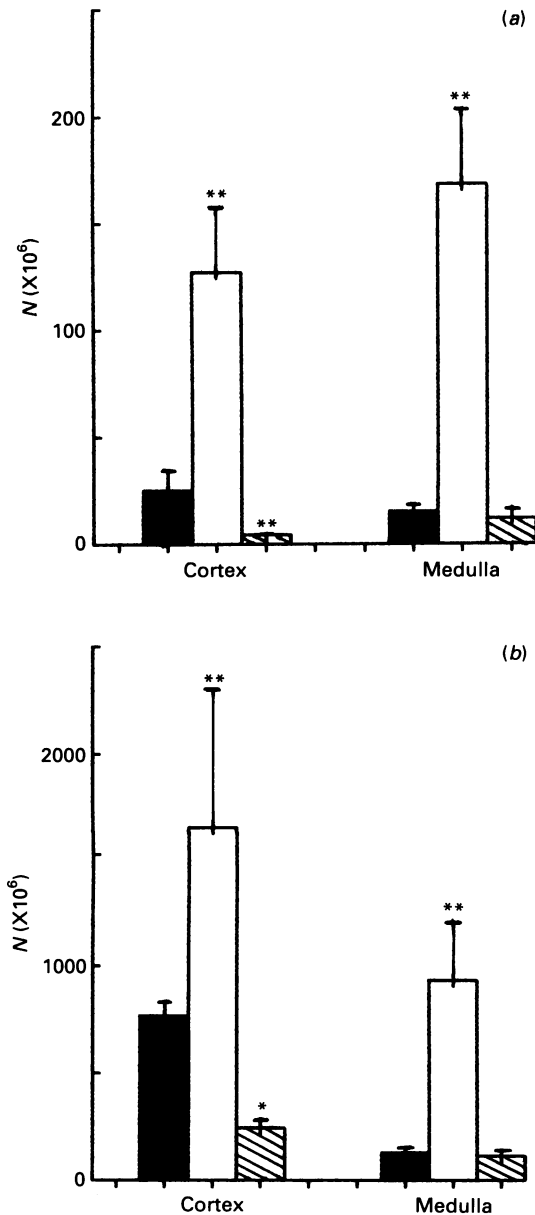


Fig. 1. (a) Absolute number of epithelial cells. (b) Absolute number of lymphocytes. Solid bars, controls; open bars, continuous darkness; hatched bars, continuous light. Values represent means S.D. * $P < 0.05$ vs control; ** $P < 0.01$ vs control; d.f. = 2/39.

period in a weight gain of 315% (Table 1). The 2 regions of the thymus were not affected to the same extent (Table 2), the increase in volume being greater in the medulla (655%) than in the cortex (190%).

The absolute number of epithelial cells increased by

Table 2. The effect of dark and light periods on the percentage and absolute volume of cortical and medullary regions of the rat thymus (mean \pm S.E.M.)

	Controls	Dark	Light
Cortex			
%	72.9 \pm 1.1	50.8 \pm 5.2**	60.0 \pm 2.7**
Volume (mm ³)	242 \pm 25	700 \pm 27**	93.9 \pm 26**
Medulla			
%	27.1 \pm 1.1	49.5 \pm 5.2**	39.9 \pm 2.7**
Volume (mm ³)	89.9 \pm 25	679 \pm 27**	62.5 \pm 26

** $P < 0.01$ vs control; d.f. = 2/15.

401% in the cortex and by 1029% in the medulla; the greater increment in the medulla was related to the higher volume gain (Fig. 1a). Absolute lymphocytes numbers underwent a significant rise ($P < 0.01$ vs control) both in the cortex (114%) and in the medulla (641%) (Fig. 1b).

Continuous light. The thymus underwent involution that resulted at the end of the light period in a weight loss of 53% (Table 1). The reduction in volume was greater in the cortex (61%) than in the medulla (27%) (Table 2). With the reduction in volume the absolute number of epithelial cells decreased by 84% in the cortex and by 19% in the medulla. (Fig. 1a). The absolute numbers of lymphocytes decreased by 69% in the cortex and by 13% in the medulla (Fig. 1b).

Morphology

Stereological analysis demonstrated changes at the histological and ultrastructural levels.

Continuous dark. There was a marked increase in the thickness of the medulla, and epithelial cells were more numerous both in the cortex and the medulla. Cortical epithelial cells were of increased size; clear vesicles which are normally present but difficult to discern with the light microscope were easily seen, filling the cytoplasm (Fig. 2b). No modification was seen in the medullary epithelial cells and, as in control animals, they did not contain clear vesicles (Fig. 3b). Mitotic figures were seen frequently in epithelial cells both in the cortex and the medulla. The perivascular connective tissue spaces were enlarged (Fig. 2b). Pyknotic lymphocyte nuclei, which are normally abundant in the cortex, were rare.

Continuous light. Cortical lymphocytes were less numerous and pyknotic lymphocyte nuclei were more frequent (Fig. 2c). In the medulla, the spaces between the epithelial cells contained more closely arranged

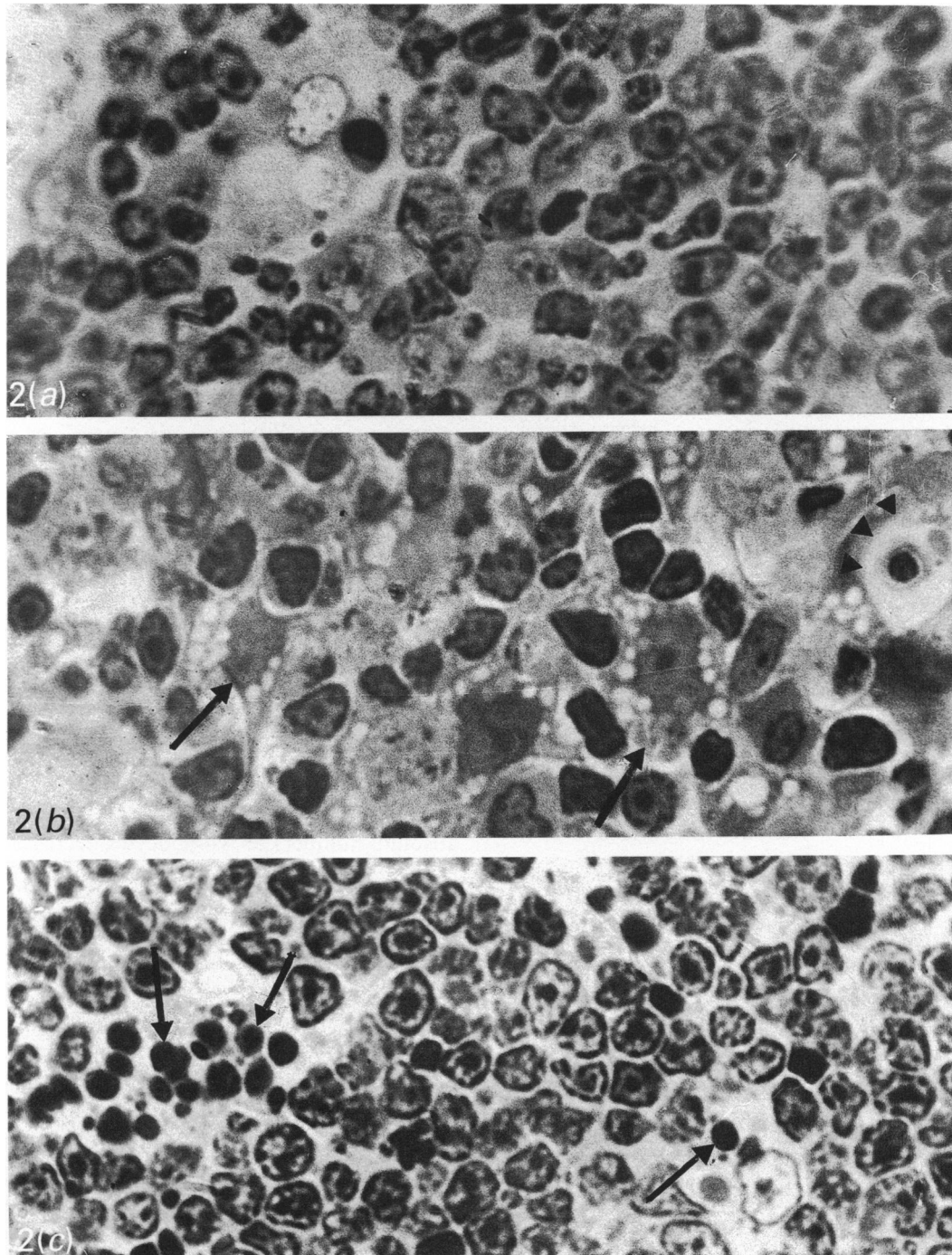


Fig. 2. Thymic cortex, 1 μ m sections, toluidine blue stain, $\times 1000$. (a) Control. (b) Continuous darkness. Arrows, hypertrophied epithelial cells containing enlarged clear vesicles; arrowheads, enlarged perivascular spaces. (c) Continuous light. Arrows, pyknotic lymphocyte nuclei.

lymphocytes and pyknotic lymphocyte nuclei, which are normally absent from the medulla, were frequent (Fig. 3c).

DISCUSSION

It is known that melatonin is continuously synthesised and secreted during a period of continuous darkness, and that its synthesis and secretion are inhibited

during a period of continuous light, provided that the light is a bright artificial light (Wurtman, 1967; Kinson & Peat, 1971; Shirama et al. 1982; for a review, see Erlich & Apuzzo, 1985). The changes in thymic structure observed in the present work may thus be related, directly or indirectly, to changes in melatonin levels during continuous darkness and continuous light.

Only scant experimental findings exist on a possible

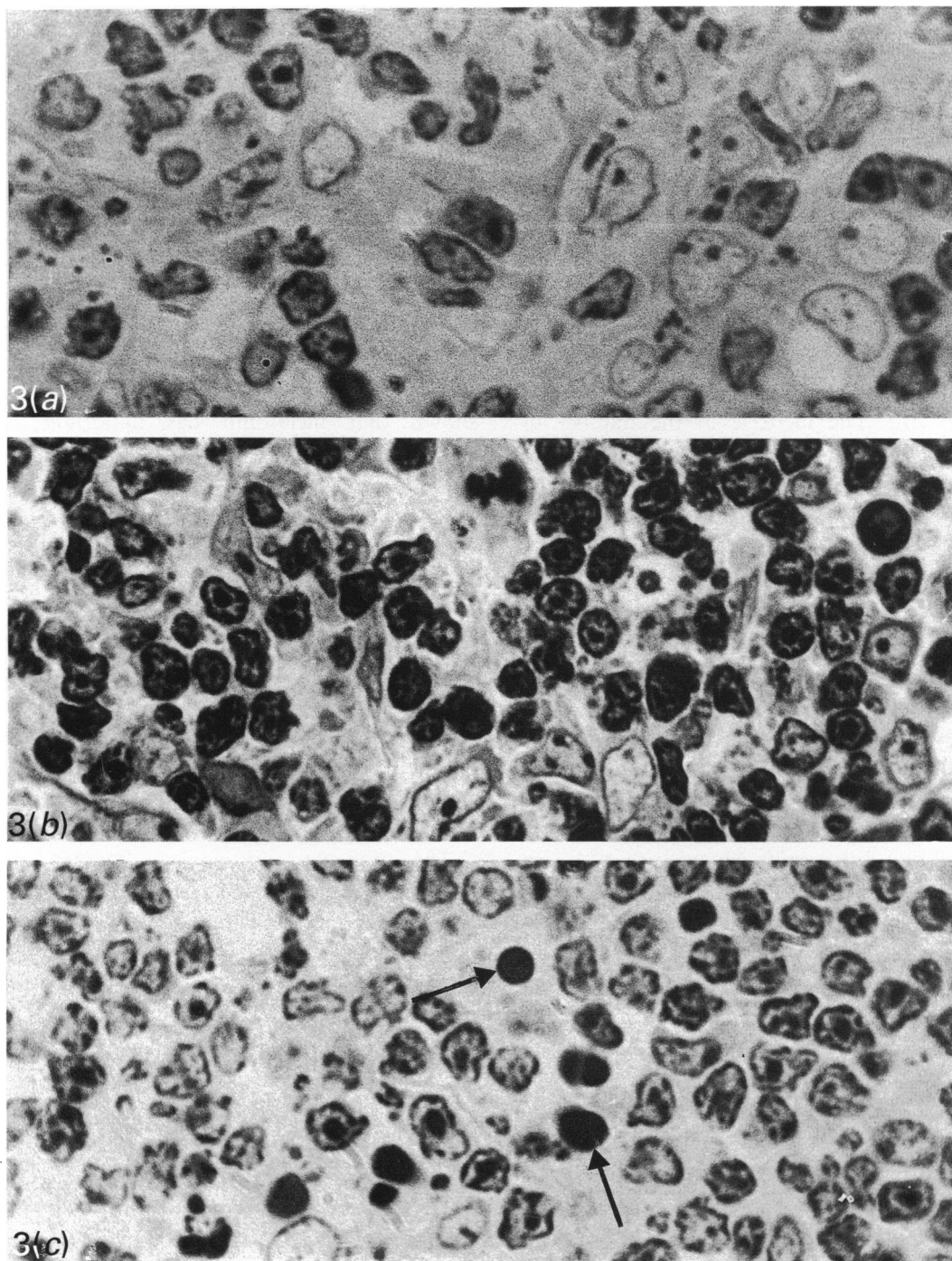


Fig. 3. Thymic medulla, 1 μ m sections, toluidine blue stain, $\times 1000$. (a) Control. (b) Continuous darkness. (c) Continuous light. Arrows, pyknotic lymphocyte nuclei.

relationship between the pineal gland and the lymphopoietic system (Jankovic et al. 1970). It has been demonstrated that exogenous melatonin enhanced antibody production through an increase in spleen cellularity (Maestroni et al. 1987a) and that when normal nonstressed mice were injected with sheep red blood cells, an injection of melatonin led to increase in antibody production without thymic enlargement (Maestroni et al. 1987b). It was also reported that

mice kept for 3 generations under constant environmental light did not grow normally and had marked atrophy of the thymolymphatic system (Maestroni & Pierpaoli, 1981). In addition, the immune reactivity and circulating lymphocytes were shown to fluctuate according to a circadian rhythm (Fernandes et al. 1976; Abo et al. 1981; Kawate et al. 1981).

During continuous darkness, the large thymic weight gain seen in this study can be explained both

by the increase in the number of lymphocytes and epithelial cells and by the hypertrophy of the cortical epithelial cells.

The increase in the absolute number of epithelial cells, both in the cortex and medulla, may be explained by the action of melatonin on these cells. Melatonin may (1) increase mitotic activity, as evidenced by the frequent observation of mitotic figures of epithelial cells in the cortex and medulla, and (2) increase the secretory activity of cortical epithelial cells, since the clear vesicles, which are considered as the morphological expression of the secretory activity of these cells (Clark, 1966, 1968; Bennett, 1978) increased in number and size. The increase in the number of lymphocytes may be due to the action of melatonin either (1) directly on cortical lymphocytes, increasing their mitotic activity and decreasing their death rate, as was evidenced by the rare findings of pyknotic nuclei in the cortex and medulla or (2) indirectly through its action on cortical epithelial cells.

Maestroni et al. (1988) demonstrated that the drastic involution of the thymus induced by acute stress could be countered by exogenous melatonin. However, melatonin produced reconstitution of the thymic medulla and not the cortex, indicating that melatonin exerts its activity on the thymic medulla containing mature T lymphocytes (Maestroni et al. 1988). Similarly, our results showed that during continuous darkness greater weight gain occurred in the medulla. This may indicate that the effect of melatonin on the thymus is mainly exerted on the medulla.

During the period of permanent light, the large thymic weight loss may be attributed to the decrease in number of lymphocytes and epithelial cells. The decrease in the number of lymphocytes may be due to an increased rate of their destruction (as evidenced by increase in the number of pyknotic nuclei) and/or a decreased rate of production.

It is widely known that acute stress and corticosterone or ACTH administration cause a rapid but transient involution of the lymphatic organs, especially the thymus (Dougherty, 1952; Weaver, 1955; Bloodworth et al. 1975; Kalland et al. 1978). Exogenous melatonin, through opioid peptides, has been shown to antagonise the immunosuppressive effect of acute stress, corticosterone and cyclophosphamide (Maestroni et al. 1987a, 1988). It has also been reported that acute stress during day time enhances the nocturnal surge of melatonin (Lynch & Deng, 1985).

Our results show that during continuous light, the greater weight loss was mainly in the cortex. This

involution is similar to that induced by the administration of sex hormones, corticosteroids and by stress, when the weight loss is mainly in the cortex which contains the bulk of lymphocytes (Sobhon & Jirasattham, 1974; Simpson et al. 1975; Kalland et al. 1978).

It is possible that inhibition of melatonin synthesis and release during a period of continuous light removes its antagonising effect on steroids, whether adrenal or gonadal; consequently these hormones, when unopposed, produce destructive actions on the thymus.

A variety of clinical and experimental models have shown that melatonin has important immunoregulatory functions (Blask, 1984; for a review, see Erlich & Apuzzo, 1985). These effects were shown to be exerted through opioid peptides (Maestroni et al. 1987a, b). Furthermore, it was reported that certain endogenous opioid peptides, namely B-endorphin, had direct effects on the cells of the immune system, namely the proliferative activity of lymphocytes (Gilman et al. 1982; McCain et al. 1982; Plotnikoff & Miller 1983; Heijnen et al. 1987).

The cellular targets for the melatonin-opioid action are still unknown. However, it has recently been reported that antigen-activated T cells must be considered as the possible targets (Wybran, 1986).

The previous and present findings allow the following proposal: changes in thymic histology during darkness and light may be attributed to direct effect of melatonin on the thymus, or indirect effects of the neurohormone via opioid peptides. These findings may have important physiological and/or immunotherapeutic implications.

ACKNOWLEDGEMENTS

The authors wish to thank Professor Y. Abbu for his critical reading of the manuscript and Mrs H. Shaheed for her technical help.

REFERENCES

- ABO T, KAWATE T, ITOH K, KUMAGAI K (1981) Studies on the bioperiodicity of the immune response. I. Circadian rhythms of human T, B and K cell traffic in the peripheral blood. *Journal of Immunology* **126**, 1360–1363
- ADER R (ed.) (1981) *Psychoneuroimmunology*, New York: Academic Press.
- ANDERSON JM (1982) Histometry. In *Theory and Practice of Histological Techniques* (ed. J. D. Bancroft & A. Stevens), pp. 548–563. Edinburgh: Churchill Livingstone.
- AXELROD J, FRASCHINI F, VELO GP (1982) The pineal gland and its endocrine role. *Proceeding of the NATO Advisory Study Institute, Erice, Italy*, pp. 227–241. New York: Plenum Press.

- BANCROFT JD, STEVENS A (1982) *Theory and Practice of Histological Techniques*. Edinburgh: Churchill Livingstone.
- BENNETT G (1978) Synthesis and migration of glycoproteins in cells of the rat thymus, as shown by radioautography after 3H-fucose injection. *American Journal of Anatomy* **152**, 223–256.
- BIRAU N (1981) Melatonin in human serum: progress in screening investigation and clinic. In *Melatonin: Current Status and Perspectives* (ed. N. Birau & W. Schloot), pp. 297–327. Oxford: Pergamon Press.
- BLASK DE (1984) The pineal: an oncostatic gland? In *The Pineal Gland* (ed. R. J. Reiter), pp. 253–285. New York: Raven Press.
- BLOODWORTH JMB, HIRATSUKA H, HICKEY RC (1975) Ultrastructure of the human thymus, thymic tumors, and myasthenia gravis. *Pathological Annuals* **10**, 329–391.
- BROWN GM, NILES LP (1982) Studies on melatonin and other pineal factors. In *Clinical Neuroendocrinology*, vol. I (ed. G.M. Besser & L. Martini), pp. 205–253. New York: Academic Press.
- CLARK SL JR (1966) Cytological evidences of secretion in the thymus. In *The Thymus: Experimental and Clinical Studies* (ed. G. E. Wolstenholme & R. Porter), pp. 3–30. London: Churchill.
- CLARK, SL JR (1968) Incorporation of sulfate by the mouse thymus: its relation to secretion by medullary epithelial cells and thymic lymphopoiesis. *Journal of Experimental Medicine* **128**, 927–957.
- DANIEL WW (1978) *Biostatistics: A Foundation for Analysis in the Health Sciences*, 2nd edn (ed. W. W. Daniel). New York: John Wiley.
- DOUGHERTY TF (1952) Effects of hormones on lymphatic tissue. *Physiological Reviews* **32**, 379–401.
- DUNCAN MJ, GOLDMAN BD, DIPINTO MN, STETSON MH (1985) Testicular function and pelage color have different critical daylengths in the Djungarian hamster, *Phodopus sungorus*. *Endocrinology* **116**, 424–430.
- ERLICH SS, APPUZO MLJ (1985) The pineal gland: anatomy, physiology and clinical significance. Review article. *Journal of Neurosurgery* **63**, 321–341.
- FERNANDES G, HALBERG F, YUNIS EJ, GOOD RA (1976) Circadian rhythmic plaque forming cells; response of spleens from mice immunized with SRBC. *Journal of Immunology* **117**, 962–966.
- GILMAN SC, SCHWARTZ JM, MILNER RJ, BLOOM FE, FELDMAN JD (1982) B-endorphin enhances lymphocyte proliferative responses. *Proceedings of the National Academy of Science of the USA* **79**, 4226–4230.
- HEIJNEN CJ, CROISSET G, ZIJLSTRA J, BALLIEUX RE (1987) Modulation of lymphocyte function by endorphins. *Annals of the New York Academy of Sciences* **496**, 161–165.
- JANKOVIC BD, ISAKOVIC K, PETROVIC S (1970) Effect of pinealectomy on immune reactions in the rat. *Immunology* **18**, 1–16.
- KALLAND T, FOSSBERG TM, FORSBERG JG (1978) Effect of estrogen and corticosterone on the lymphoid system in neonatal mice. *Experimental and Molecular Pathology* **28**, 76–95.
- KAWATE T, ABO T, HINUMA S, KUMAGAI K (1981) Studies on the bioperiodicity of the immune response. II. Co-variations of murine T and B cells and a role of corticosteroid. *Journal of Immunology* **126**, 1364–1367.
- KINSON GA, PEAT F (1971) The influences of illumination, melatonin and pinealectomy on testicular function in the rat. *Life Sciences* **10**, 259–269.
- LYNCH HJ, DENG M-H (1985) Pineal responses to stress. In *Melatonin in Humans*. *Proceedings of the First International Conference on Melatonin in Humans, Vienna, Austria*. Cambridge MA: Center for Brain Sciences and Metabolism Charitable Trust, pp. 431–442.
- MCCAIN HW, LAMSTER IB, BOZZONE JM, GRABIC JT (1982) B-endorphin modulates human immune activity via non-opiate receptor mechanisms. *Life Sciences* **31**, 1619–1624.
- MAESTRONI GJM, PIERPAOLI W (1981) Pharmacological control of the normally mediated immune response. In *Psychoneuro-immunology* (ed. R. Ader), pp. 405–425. New York: Academic Press.
- MAESTRONI GJM, CONTI A, PIERPAOLI W (1987a) The pineal gland and the circadian, opiate, immunoregulatory role of melatonin. *Annals of the New York Academy of Sciences* **496**, 67–77.
- MAESTRONI GJM, CONTI A, PIERPAOLI W (1987b) Role of the pineal gland in immunity: II. Melatonin enhances the antibody response via an opiate mechanism. *Clinical and Experimental Immunology* **68**, 384–391.
- MAESTRONI GJM, CONTI A, PIERPAOLI W (1988). Role of the pineal gland in immunity. III. Melatonin antagonizes the immunosuppressive effect of acute stress via an opiate mechanism. *Immunology* **63**, 465–469.
- PLOTNIKOFF NP, MILLER GC (1983) Enkephalins-endorphins: Immunomodulators in mice. *International Journal of Immunopharmacology* **5**, 437–439.
- PLOTNIKOFF NP, FAITH BE, MURGO AJ, GOOD RA (1986) Ying-Yang hypothesis of immunomodulation. In *Enkephalins and Endorphins: Stress and the Immune System* (ed. N. P. Plotnikoff, B. E. Faith, A. J. Murdo & R. A. Good), pp. 1–2. New York: Plenum Press.
- REITER RJ (ed.) (1984) *The Pineal Gland*. New York: Raven Press.
- SCHIEFF JM, CORDIER AC, HAUMONT S (1977) Epithelial cell proliferation in thymic hyperplasia induced by triiodothyronine. *Clinical and Experimental Immunology* **27**, 516–521.
- SHIRAMA K, FURUYA T, TAKEO Y, SHIMIZU K, MAEKAWA K (1982) Direct effect of melatonin on the accessory sexual organs in pinealectomized male rats kept in constant darkness. *Journal of Endocrinology* **95**, 87–94.
- SIMPSON JG, GRAY ES, BECK JS (1975) Age involution in the normal human adult thymus. *Clinical and Experimental Immunology* **19**, 261–265.
- SOBHON P, JIRASATTHAM C (1974) Effect of sex hormones on the thymus and lymphoid tissue of ovariectomized rats. *Acta Anatomica* **89**, 211–225.
- STERIO DC (1984) The unbiased estimation of number and sizes of arbitrary particles using the disector. *Journal of Microscopy* **134**, 127–136.
- TAKAHASHI M, KYO-CHOI CHU, SUZUKI Y (1971) Light activation of gonadal function restoration by continuous dark treatment in male rats. *Endocrinologica Japonica* **18**, 195–203.
- VITALE PM, DARROW JM, DUNCAN MJ, SHUATAK CA, GOLDMAN BD (1985) Effects of photoperiod, pinealectomy and castration on body weight and daily torpor in Djungarian hamsters (*Phodopus sungorus*). *Journal of Endocrinology* **106**, 367–375.
- WEAVER JA (1955) Changes induced in the thymus and lymph nodes of the rat by the administration of cortisone and sex hormones and by other procedures. *Journal of Pathology and Bacteriology* **69**, 133–139.
- WEIBEL ER (1979) *Stereological Methods: Practical Methods for Biological Morphometry*. London: Academic Press.
- WEIBEL ER, KISTLER GS, SCHERLE WR (1966) Practical stereological methods for morphometric cytology. *Journal of Cell Biology* **30**, 23–38.
- WURTMAN RI (1967) Effect of light and visual stimuli on endocrine function. In *Neuroendocrinology*, vol. II (ed. L. Martini & W. F. Ganong), pp. 20–59. New York: Academic Press.
- WYBRAN J (1986) Enkephalins as molecules of lymphocyte activation and modifiers of the biological response. In *Enkephalins and Endorphins: Stress and the Immune System* (ed. N. P. Plotnikoff, R. E. Faith, A. J. Murgo & R. A. Good), pp. 253–262. New York: Plenum Press.
- YELLON SM, GOLDMAN BD (1984) Photoperiod control of reproductive development in the male Djungarian hamster (*Phodopus sungorus*). *Endocrinology* **114**, 664–670.