

# Disposition of collagen fibrils in human tendons

C. STOLINSKI

*Department of Anatomy and Cell Biology, St Mary's Hospital Medical School, Imperial College of Science, Technology and Medicine, London, UK*

*(Accepted 2 December 1994)*

---

## ABSTRACT

Fixed and unfixed human tendons originating from cadavers and postoperation specimens were examined using inclined parallel beams of light in a reflecting mode. Along the tendon, numerous planes, constantly inclined to the axis, were observed edge-on at the surface and within the interior. Their angle of inclination, with respect to the distal end was very nearly  $\pm 50^\circ$ . The planes consisted of individual segments arranged in steps which were on average  $190 \times 50 \mu\text{m}$ . Similar configurations were also observed with the scanning electron microscope. Using this technique, the segments were identified with collagen bundles turning at a sharp angle with respect to the axis of the tendon at the level of the inclined plane. Crimped planes were found to be irregularly distributed along the tendons. On longer flatter tendons the average distance between planes was in the range of 1–12 mm. On stretching, the inclined pattern disappeared and was rapidly re-established in the previously observed position when the strain was released. It is suggested that the observed structure forms a mechanism which is responsible for the appearance of the first part or 'foot' region of the tendon's stress-strain diagram.

*Key words:* Tendon; collagen.

---

## INTRODUCTION

The shimmering bright reflections from moist, freshly dissected tendon have been noticed by a variety of anatomists. For example, Gray (1860) described these as pearly white, glistening and iridescent fibrous cords, while Schäfer (1912) compared the tendon's superficial appearance to a watered ribbon.

Histological study of the fine structure of tendons was initiated by Kölliker (1852) who established the longitudinal arrangement of fibres within its interior. Subsequently, Ranvier (1889) expanded the original observations by describing the specific cell populations associated with dense connective tissues. Arai (1907) and Edwards (1946) traced the vascular network of the newborn and adult human to this organ with rather limited metabolic requirements. Verzár & Huber (1958) applied episcopic illumination in a light microscopic study of rat tail tendons and reported their banded appearance. Similarly banded rat tail tendons with a periodicity of the order of  $100 \mu\text{m}$  were observed in their relaxed state by Rigby et al. (1958). Following these studies, Diamant et al. (1972) and Kastelic et al. (1978) reported a planar zigzag

arrangement of collagen fibrils in the rat tail tendons. The authors also reported that the banding disappeared on the application of tension. Among the studies involving human tendons, crossing and spiralling fibres were reported by Cummins et al. (1946) and Martin (1958). Attachments of the human tendons to bone were studied by Benjamin et al. (1986), while the myotendinous junctions were investigated among others by Hanak & Böck (1971).

The mechanical properties of tendons from various species have been investigated in detail by Hooley et al. (1980), Ker (1981) and Bennett et al. (1986). The assembly of the collagenous matrix into fibrils and bundles has been extensively studied by Birk & Zycband (1994) in the developing tendon of the chick embryo.

In a morphological study, Jozsa et al. (1991) investigated collagen fibril arrangement in a variety of human tendons using transmission and scanning electron microscopy. Both epitendineum and peritendineum were investigated while the interior of the tendon was reported to consist of predominantly longitudinal in addition to some transverse and horizontal fibrils. The general subject of tendon




Fig. 1. Fixed human extensor digitorum tendon surface observed with reflected light, showing segmented inclined pattern. The pattern is inclined at  $130^\circ$  and  $230^\circ$  with respect to the proximal end (top of the micrograph) or  $\pm 50^\circ$  with respect to the distal end. (A) Strongly reflecting segments are seen against black background as illuminated along the axis of the tendon. (B) The same pattern illuminated at  $90^\circ$  to the axis of the tendon shows nonreflecting segments against a bright background of the light reflected from the collagen bundles. Both  $\times 27$ . (C, D) Details of above micrographs showing at higher magnification reflecting and nonreflecting segments. Average dimension of segments is  $190 \times 50 \mu\text{m}$ . Large arrows in this and succeeding micrographs indicate direction of illumination. SF, secondary fascicle; ET, endotendineum.  $\times 87$ .

structure and function has been extensively reviewed by Elliot (1965), Evans & Barbenel (1975) and O'Brien (1992).

For the present study, inclined light illumination in the reflecting mode and scanning electron microscopy were used to observe specific regions of fibrillar arrangement near the surface and within the interior of the tendon. Specific fibrillar configurations were found to form discrete terraced planes, uniformly inclined to the axis of the tendon. The segmented regions were observed to consist of fibrils which change their longitudinal direction at the level of the

plane and then resume their original longitudinal orientation parallel to the axis of the tendon. Under tension the segmented regions disappeared and then reappeared on relaxation. It is suggested that the described structures are responsible for the initial extension of the tendon when under tension.

#### MATERIALS AND METHODS

Human extensor digitorum, palmaris longus, plantaris and flexor carpi ulnaris tendons were obtained from embalmed and postmortem cadavers as well as

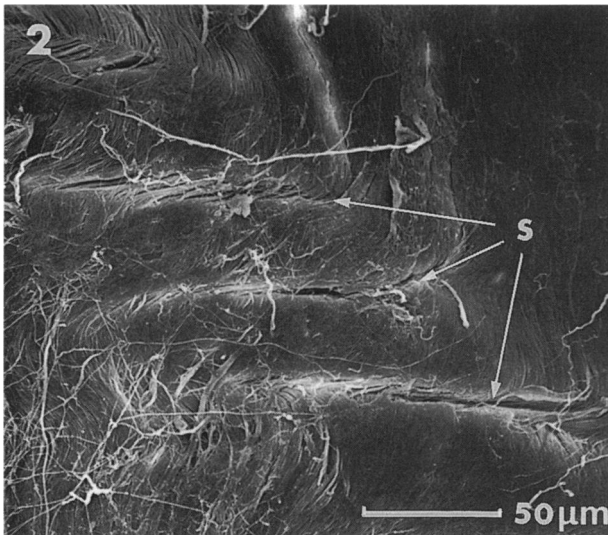
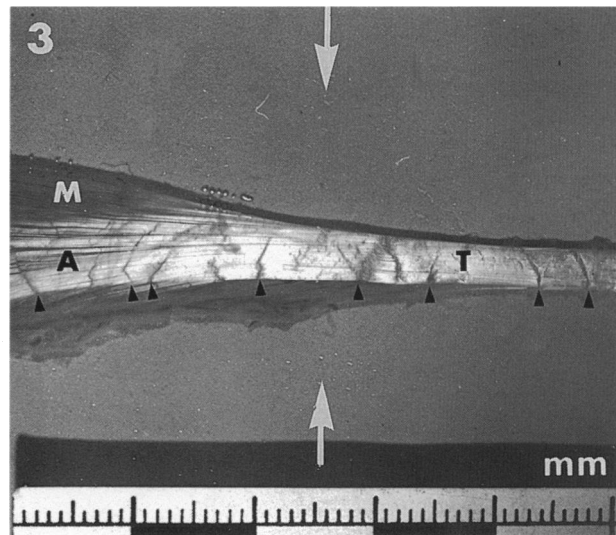


Fig. 2. Scanning electron micrograph of surface of the extensor digitorum tendon, showing an echelon of slits separated by a distance of approximately 40  $\mu\text{m}$ . The length of the slits is of the order of 150–170  $\mu\text{m}$ .  $\times 355$ .

Fig. 3. Photograph of fixed plantaris muscle and tendon, showing disposition of the inclined planes (arrowheads) along the tendon (T) and aponeurosis (A). M, muscle.  $\times 1.6$ .



postoperation fixed specimens (previous consent was obtained in each case). Unfixed tendons were placed in phosphate buffered saline (PBS). Tendons from embalmed cadavers were washed in distilled water and postfixed in 10% formol saline and stored. For scanning electron microscopy procedures, the tendons were cleaned in PBS and the outer epitendineum and peritendineum were removed under the dissecting microscope. For observations by light microscopy, fixed and unfixed tendons were placed on a flat surface, covered by a coverslip and bathed in PBS. The tendons were illuminated by parallel beams of light from a fibreoptic source, directed from 2 opposite sides, at approximately 35° to the plane of the sample. The reflected image was viewed with  $\times 1$  and  $\times 4$  objectives against a black background. The tendons were illuminated along or at right angles to their axis. Fixed, unstained tendons were sliced using a micro-cut vibrating microtome. Approximately 150  $\mu\text{m}$  thick slices were viewed using conventional transmission illumination. A 20 mm length of fixed tendon was also clamped at the cut ends in a device capable of longitudinally straining the tissue. Images of the same region, before and after stretching, were subsequently recorded with a photomicroscope. Percentage strain was measured with a micrometer gauge.

For scanning electron microscopy, tissues were dehydrated in graded acetone solutions up to absolute and critically point dried. Some of the dried tendons were split to reveal the internal aspects of fibrils at the level of the segmental planes. The specimens were

subsequently mounted on planchettes and sputter coated with gold.

## RESULTS

Fixed, unfixed and postoperation human tendons, illuminated by an inclined parallel beam of light, directed along their longitudinal axis, displayed bright, strongly reflecting obliquely arranged segmented arrays viewed against a dark background (Fig. 1A). The same area when illuminated at 90° to the axis, showed the previously observed segments as dark, nonreflecting arrays viewed against a light background (Fig. 1B). So far, in all the examined specimens the great majority of the linear arrays were found to be symmetrically inclined at 130° and 230° to the axis of the tendon, with respect to the proximal, or  $\pm 50^\circ$  with respect to the distal end. The arrays often extended partly or over the entire width of the tendon. The segments within the arrays consisted of discrete regions arranged in steps of approximately 180  $\mu\text{m}$  length and 50  $\mu\text{m}$  width (Fig. 1C, D). In the background of Figure 1B and D alternate light and dark bands of 80  $\mu\text{m}$  periodicity, disposed across the axis of the tendon, were observed.

The surface appearance of the tendons (Fig. 2) as observed in the scanning electron microscope showed a similar region to that on Figure 1C and D. An echelon of slits, disposed at about 130° to the axis of the tendon, of 170  $\mu\text{m}$  length and 40  $\mu\text{m}$  separation can be observed on this micrograph. Longitudinally




Fig. 4 (A, B). Unfixed palmaris longus tendon (T) showing disposition of crimped planes (arrowheads). M, muscle.  $\times 2.6$ .




Fig. 5 (A, B). Postoperation fixed flexor carpi ulnaris tendon showing disposition of inclined crimped planes. A shows aggregations of crimped planes,  $\times 9.6$ . B shows enlarged details from A,  $\times 71$ .

disposed collagen fibrils reach the slits from both directions and then enter the tendon's interior. A photograph of fixed plantaris muscle and tendon (Fig. 3) shows the disposition of the inclined planes (indicated by arrowheads). Their separation along the entire length of the tendon including the aponeurosis is of the order of 3–5 mm.

A nonfixed palmaris longus tendon in Figure 4 shows comparable configurations of crimped planes as observed in Figure 3. Similarly, postoperation flexor carpi ulnaris tendon (Fig. 5) again shows configurations of crimped planes as observed in the unfixed and embalmed specimens. Collagen fibrils within the tendon's interior are shown in Figure 6.

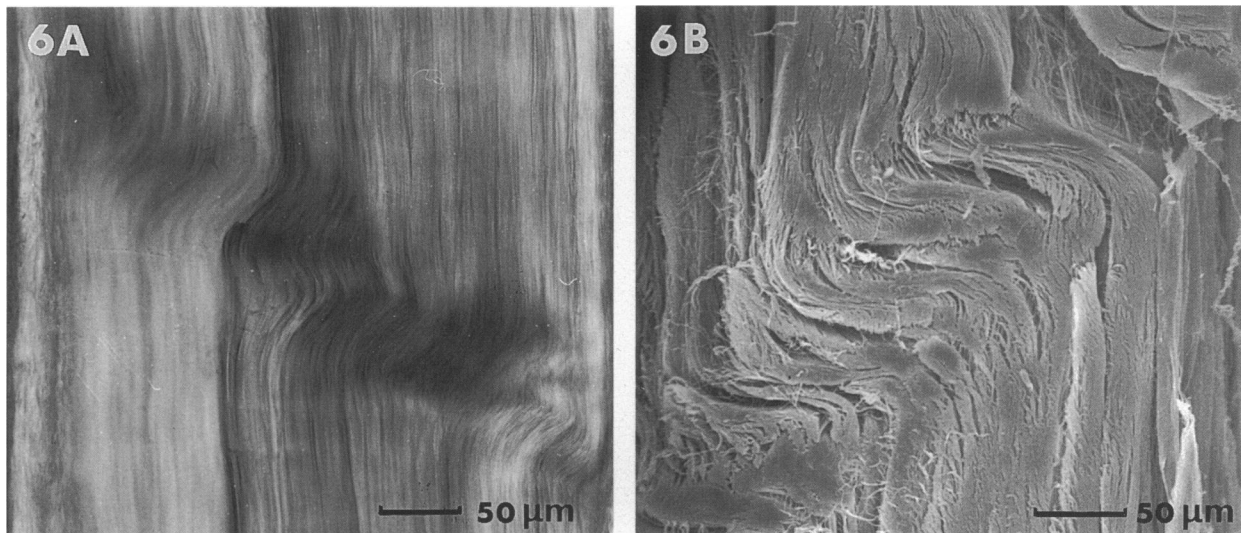


Fig. 6 (A, B). Internal aspect of fibrillar segments by conventional transmission light and scanning electron microscopy. A shows a thick slice of fixed unstained tendon tissue at the region of the segmental plane. Note change of direction of collagen bundles at the segmental level.  $\times 210$ . B shows similar region as observed in a scanning electron microscope.  $\times 240$ .

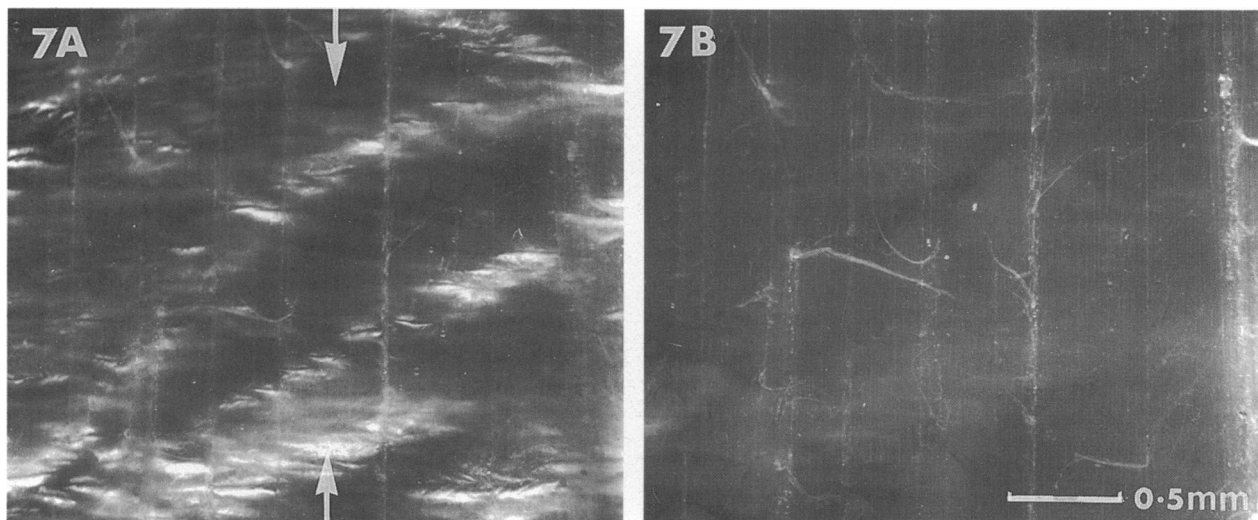


Fig. 7 (A, B). Plantaris tendon in relaxed state (A) showing characteristic inclined segments. The same region under tension (B) shows almost complete absence of the previously observed pattern. On relaxation of tension the pattern seen on A was restored. Both  $\times 30$ .

The micrograph (Fig. 6A) was obtained from the sliced part of the tendon and revealed the internal arrangement of fibrils as viewed by conventional transmitted illumination. Twisted fibrils were observed in the region which was continuous with the inclined arrays near the surface. A similar region observed in the scanning electron microscope (Fig. 6B), shows twisted fibrils arranged in an echelon formation.

Figure 7A and B shows the same areas of the fixed tendon, when relaxed (Fig. 7A) and when under approximately 1% strain (Fig. 7B). The characteristic bright segments observed with reflected light almost

completely disappeared when the tendon was stretched. On relaxation, the pattern was rapidly re-established in the previously observed configuration.

#### DISCUSSION

Tendon collagen fibrils strongly reflect incident light when illuminated at  $90^\circ$  to their general orientation. Conversely, light is very weakly reflected and the tissue becomes semitransparent when the beam of light is directed along the fibrils. From these observations the actual linear disposition of the fibrils can be deduced by their ability to reflect a parallel beam of

light. It can therefore be concluded that the segments shown in Figure 1, by their reversed illumination pattern, indicate a position of an abrupt change of direction of the fibrils, followed by resumption of their original orientation. These observations apply to the segments observed near the surface as well as in the interior of the tendon.

The pattern of slits arranged in an echelon as observed in Figure 2 shows similarities in the overall arrangement of the details to the image shown in Figure 1. The separation of the slits and their length is of the same order as the width and length of the segments. The observed arrangement suggests that the slits represent the sites where fibrils on arriving from the ends of the tendon change their direction and enter the interior of the tendon.

The multisegmented arrangement of the inclined planes occasionally extends over the entire cross-section and spans across the septa of primary and secondary fascicles of the tendon. These structures were found to be located at various intervals over the entire length of the tendon, in some cases aggregated (Fig. 5A), while in longer tendons such as plantaris they were separated on average by 3–12 mm (Figs 3, 4). The internal arrangement of fibrils within the planes, as illustrated on Figure 6, indicates that their twisted configuration is similar to that observed near the surface.

A possibility that the observed patterns could be an artifact resulting from fixation can be discounted since very similar configurations as shown in Figures 1 and 3 originating from embalmed tissues were observed in unfixated tendons (Figure 4). The same tendons after fixation retained the structures in their previously observed configurations. In addition, fixed post-operation tendon (Fig. 5) also showed similar inclined arrays of segments, indicating absence of possible postmortem necrotic artifacts in the embalmed material.

The stretching experiments indicate that a force applied to the tendon can straighten the fibrils and almost completely obliterate previously observed structural details (Fig. 7). It is significant that the inclined pattern of segments can be restored when the tension is removed, indicating that fibrils are permanently set in the normally observed segmented pattern when in a relaxed state. In general, it has been suggested that two different deformation mechanisms are supposed to occur; one in the 'foot' and another in the linear part during the strain–stress tests (Hooley et al. 1980). From the preliminary observations it can be surmised that the 'foot' region of the strain–stress graph is probably caused by unwinding of the twisted

fibrils within the segmental regions of the crimped planes.

Tendons, which are composed of long strands of collagen fibrils, have to transmit substantial forces from muscle to the bone. Longitudinally disposed collagen fibrils which make up most of the tendon tissue are very flexible but are not extensible. It is probable that without any means of damping of the rapidly produced muscular forces the tendon and its attachments would undergo rapid deterioration (Hill, 1951). It is suggested therefore that the reported planes of twisted fibrils are responsible for initial elongation of the entire tendon, hence protecting the tendon's attachments. In addition, when relaxed the entire tendon shows faint dark and light bands in reflected light (Fig. 1B,D) indicating the presence of gentle planar waves of collagen fibrils disposed along the axis of the tendon which also disappear on stretching. A similar planar wavy arrangement has recently been reported in the epineurial sheath of peripheral nerve (Stolinski, 1995).

A different mechanism has been proposed for the damping of forces in the rodent tail tendon. The arrangement of fibrils within these tissues was scrutinised by a number of investigators (Nauck, 1931; Rigby et al. 1958; Verzár & Huber, 1958). The general conclusion was that a helical or wavy disposition of fibrils was responsible for the banded appearance of the tendon when viewed in reflected or polarized light. Diamant et al. (1972) and Kastelic et al. (1978) also suggested that the damping of forces transmitted by the tendon is achieved in the rat tail by the straightening of fibrils which in a relaxed state are composed of individual segments 90 to 120  $\mu\text{m}$  in length arranged in a zigzag pattern over their entire length.

The reason for the specific inclination of symmetrically disposed crimped planes, observed within human tendons, is not obvious and requires further elucidation. The actual twisted arrangement of fibrils within the inclined segmented planes likewise requires further investigation in order to gain understanding of their actual spatial disposition, their ability to straighten under strain and to return to the original form when relaxed.

#### ACKNOWLEDGEMENTS

I am most grateful to Mr J. Buchanan and Mr R. Williams of the Orthopaedics Department, St Mary's Hospital Medical School, for their help in obtaining samples of tendon. I also wish to express my thanks to Drs J. P. Bennett and J. P. Cassella of the Anatomy

and Cell Biology Department for helpful comments and discussion, and to Ms Leonie Mansell for expert production of the manuscript.

## REFERENCES

- ARAI H (1907) *Die Blutgefäße der Sehnen. Anatomische Hefte* **34**, 363–381.
- BENJAMIN M, EVANS EJ, CUPP L (1986) The histology of tendon attachment to bone in man. *Journal of Anatomy* **149**, 89–100.
- BENNETT MB, KER RF, DIMERY NJ, ALEXANDER RMCN (1986) Mechanical properties of various mammalian tendons. *Journal of Zoology* **209**, 537–548.
- BIRK DE, ZYCBAND E (1994) Assembly of the tendon extracellular matrix during development. *Journal of Anatomy* **184**, 457–463.
- CUMMINS EJ, ANSON BJ, CARR BW, WRIGHT RR, HAUSER DW (1946) The structure of calcaneal tendon (of Achilles) in relation to orthopedic surgery. With additional observations on the plantaris muscle. *Surgery, Gynecology and Obstetrics* **83**, 107–116.
- DIAMANT J, KELLER A, BAER E, LITT M, ARRIDGE RGC (1972) Collagen; ultrastructure and its relation to mechanical properties as a function of ageing. *Proceedings of the Royal Society, London B* **180**, 293–315.
- EDWARDS DA (1946) The blood supply and lymphatic drainage of tendons. *Journal of Anatomy* **80**, 147–152.
- ELLIOTT DH (1965) Structure and function of mammalian tendon. *Biological Reviews of the Cambridge Philosophical Society* **40**, 392–421.
- EVANS JH, BARBENEL JC (1975) Structural and mechanical properties of tendon related to function. *Equine Veterinary Journal* **7**, 1–8.
- GRAY H (1860) *Anatomy, Descriptive and Surgical*, 2nd edn, p. 237. London: J. W. Parker.
- HANAK H, BÖCK P (1971) Die Feinstruktur der Muskel-Sehnenverbindung von Skelett und Herzmuskel. *Journal of Ultrastructural Research* **36**, 68–85.
- HILL AV (1951) The mechanics of voluntary muscle. *Lancet* **261**, 947–951.
- HOOLEY CJ, MCCRUM NG, COHEN RE (1980) The viscoelastic deformation of tendon. *Journal of Biomechanics* **13**, 521–528.
- JOZSA L, KANNUS P, BALINT JB, REFFY A (1991) Three-dimensional ultrastructure of human tendons. *Acta Anatomica* **142**, 306–312.
- KASTELIC J, GALESKI A, BAER E (1978) The multicomposite structure of tendon. *Connective Tissue Research* **6**, 11–23.
- KER RF (1981) Dynamic tensile properties of plantaris tendon of sheep (*Ovis aries*). *Journal of Experimental Biology* **93**, 283–302.
- KÖLLIKER RA (1852) *Handbuch der Gewebelehre des Menschen*, p. 173. Leipzig: Engelmann.
- MARTIN BF (1958) The tendons of flexor digitorum profundus. *Journal of Anatomy* **92**, 602–608.
- NAUCK ET (1931) Die Wellung der Sehnenfasern, ihre funktionelle Bedeutung. *Morphologisches Jahrbuch* **68**, 79–96.
- O'BRIEN M (1992) Functional anatomy and physiology of tendons. *Clinics in Sports Medicine* **11**, 505–520.
- RANVIER LA (1889) *Traité Technique d'Histologie*, 2me edn, pp. 285–297. Paris: F. Savy.
- RIGBY BJ, HIRAI N, SPIKES JD, EYRING H (1959) The mechanical properties of rat tail tendon. *Journal of General Physiology* **43**, 265–283.
- SCHÄFER EA (1912) *Text-book of Microscopic Anatomy*, p. 111. London: Longman, Green & Co.
- STOLINSKI C (1995) Structure and composition of the peripheral nerve outer sheath. *Journal of Anatomy* **186**, 123–130.
- VERZÁR F, HUBER K (1958) Die Struktur der Sehnen-Faser. *Acta Anatomica* **33**, 215–229.