

# The vomeronasal organ of the cat

IGNACIO SALAZAR<sup>1</sup>, PABLO SANCHEZ QUINTEIRO<sup>1</sup>, JOSE MANUEL CIFUENTES<sup>1</sup> AND TOMAS GARCIA CABALLERO<sup>2</sup>

<sup>1</sup> Department of Anatomy and Embryology, Faculty of Veterinary Medicine, Lugo, and <sup>2</sup> Department of Morphological Sciences, Faculty of Medicine, University of Santiago de Compostela, Spain

(Accepted 3 October 1995)

---

## ABSTRACT

The vomeronasal organ of the cat was studied macroscopically, by light microscopy and by immunohistochemical techniques. Special attention was paid to the general distribution of the various soft tissue components of this organ (duct, glands, connective tissue, blood vessels and nerves). Examination of series of transverse sections showed that the wall of the vomeronasal duct bears 4 different types of epithelium: simple columnar in the caudal part of the duct, respiratory and receptor respectively on the lateral and medial walls of the middle part of the duct, and stratified squamous rostrally. The pattern of distribution of other soft tissue components was closely associated with that of epithelium types. In areas where the duct wall was lined with receptor epithelium, nerves and connective tissue were present between the epithelium and the medial sheet of the vomeronasal cartilage. Most glands and blood vessels were located lateral to those areas of the duct wall lined with respiratory epithelium. Numerous basal cells were present in the sensory epithelium. Understanding of the distribution of the soft tissue components of this organ may shed light on its function.

*Key words:* Vomeronasal organ; cat; epithelium.

---

## INTRODUCTION

The vomeronasal system (VNS) basically comprises the vomeronasal organ (VNO), the accessory olfactory bulb (AOB) and the 'vomeronasal amygdala'. It is generally agreed that this system constitutes a dual olfactory pathway (Raisman, 1972) which is closely involved in the control of sexual behaviour (Wysocki, 1979). In cats, some parts of the VNS have been extensively studied: important work has been done on the amygdala (Krettek & Price, 1977*a, b*, 1978*a, b*), the accessory olfactory bulb (Sanides-Kohlrausch & Wahle, 1990; Wahle et al. 1990), the innervation of the VNO (Eccles, 1982) and the relationship between the VNO and behaviour (Verberne, 1976; Verberne & De Boer, 1976). However, little information is available on the normal morphology in adult cats of the VNO as a whole. The studies of Seifert (1971) and Kogure et al. (1989) dealt with only one specific part of the epithelium of the vomeronasal duct, while the more complete report of Steinberg (1913) was based on the study of a single 30-d-old fetus. The lack of comprehensive studies is

particularly surprising given the importance of the cat in biomedical research. Here we report a study of the general morphology of the VNO in this species.

## MATERIALS AND METHODS

Eight adult male and female cats were used in this study. All animals were killed humanely with an overdose of barbiturates, in full accordance with US National Institutes of Health ethical guidelines (DHEW, publication NIH 72-23). Two animals were dissected immediately after death. In another 2, the part of the nasal cavity in which the VNO is situated was isolated and immersed in 5% paraformaldehyde in 0.1 M phosphate buffer, pH 7.4; after 48 h the samples were rinsed in tap water, decalcified in 5% EDTA over 48 h at 35 °C, dehydrated in alcohol, embedded in paraffin wax, transversely serially sectioned at 10 µm and stained with haematoxylin-eosin (HE). A classic method (His, 1880) was used for the reconstruction of the material obtained on the basis of 35 sections (i.e. 1 section in every 25). Immediately after death of the remaining 4 animals,

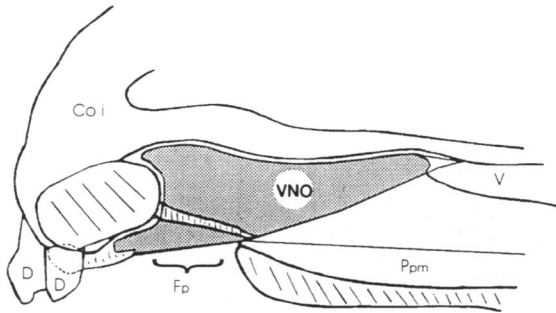


Fig 1. Projection of the vomeronasal organ (VNO) on the anterior part of the skull. Coi, corpus ossis incisivi; D, teeth; Fp, palatine fissure; Ppm, palatine process of maxilla; V, vomer.

the heads were severed and washed via the common carotid artery with 0.8 (w/v) solution of NaCl and then with 5% buffered paraformaldehyde; the whole VNO was then isolated and immersed in the same fixative for several hours. Routine procedures were used for preparing 5 of these VNOs: washing, dehydration in alcohol and embedding in paraffin wax

prior to cutting transverse sections (6–8  $\mu$ m) for staining, alternately with HE, PAS, Alcian blue, Masson's trichrome and Weigert's resorcin fuchsin methods.

Samples of the vomeronasal and nasocaudal nerves were also obtained and fixed in a cacodylate buffered solution containing 2% glutaraldehyde and 3% paraformaldehyde (pH 7.4). The tissues were postfixed in 1% unbuffered osmium tetroxide, dehydrated in graded solutions of ethanol, embedded in Araldite, sectioned (1  $\mu$ m) using glass knives and stained with 1% toluidine blue in an equal volume of 2.5% sodium carbonate.

*Immunohistochemistry*

The avidin–biotin–peroxidase complex (ABC) procedure of Hsu et al. (1981) was employed in the remaining 3 samples. After conventional blocking steps (0.3% hydrogen peroxide for 10 min and normal

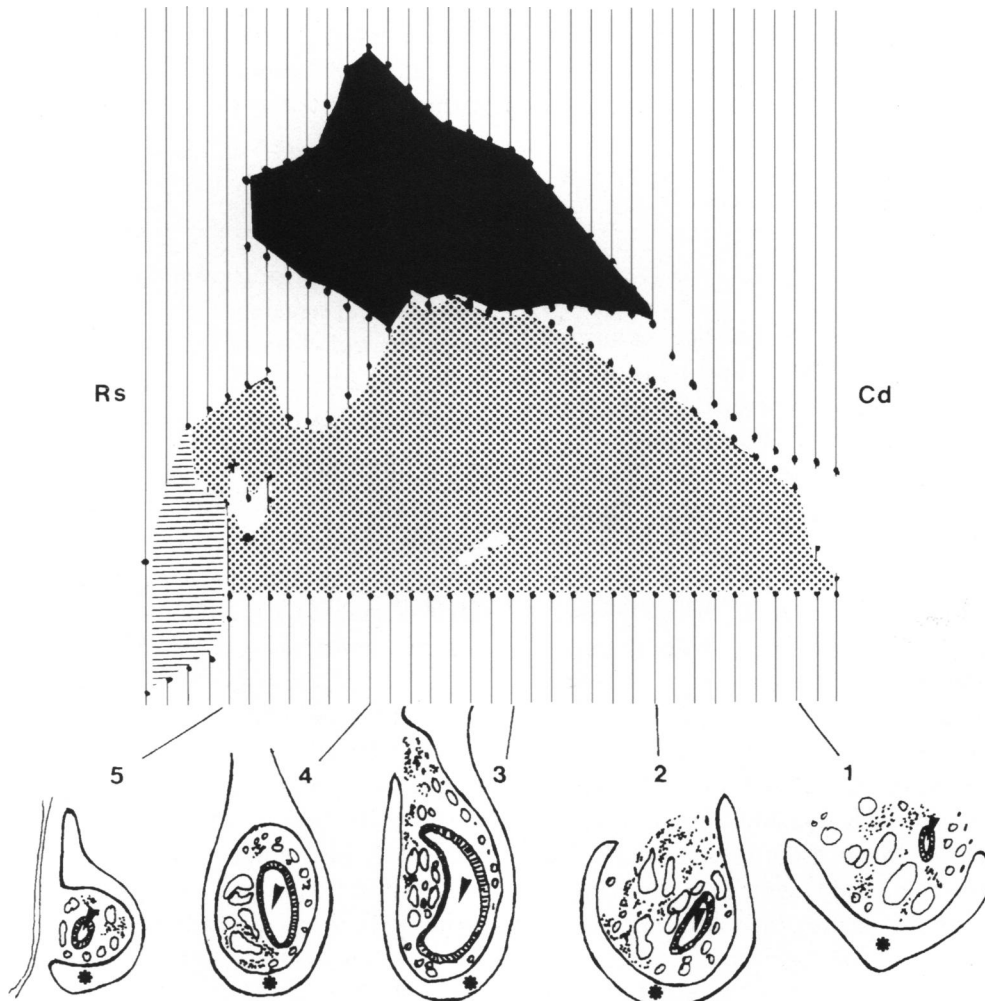


Fig. 2. Top: reconstruction of the vomeronasal cartilage, lateral view. Cd, caudal; Rs, rostral; black, medial sheet of the VNC; dotted, lateral sheet of the VNC; striped, cartilage of the incisive duct. Bottom: camera lucida drawing of transverse sections of levels 1–5. Vomeronasal cartilage (asterisk); vomeronasal duct (arrowheads).

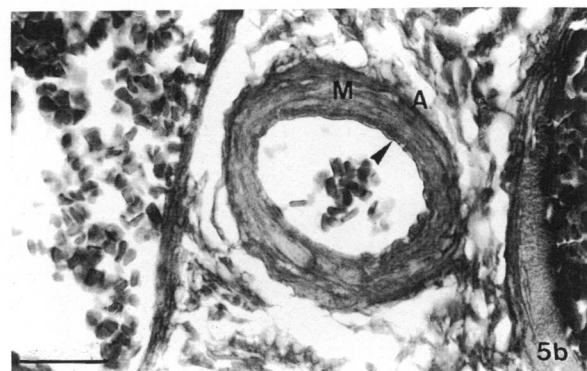
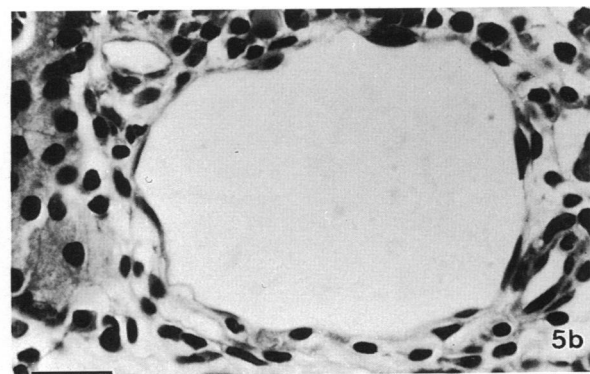
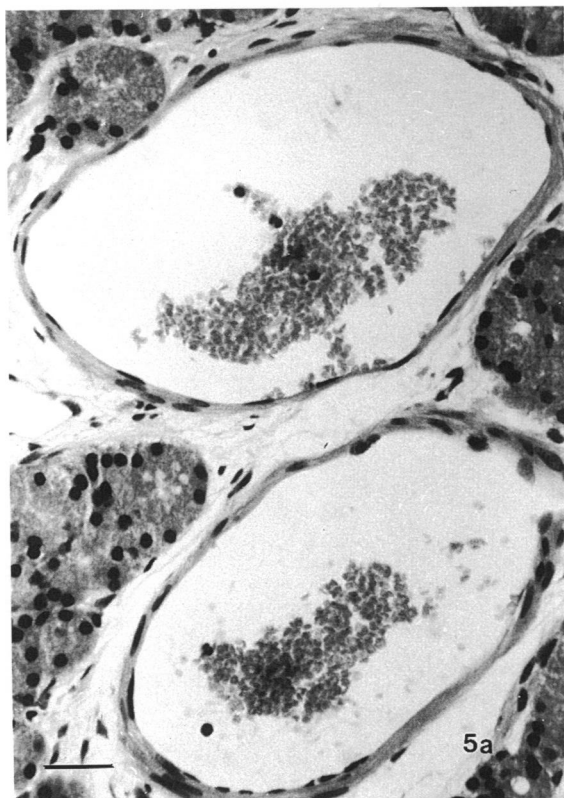
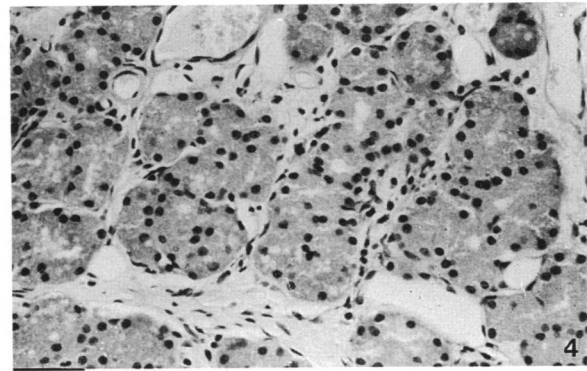
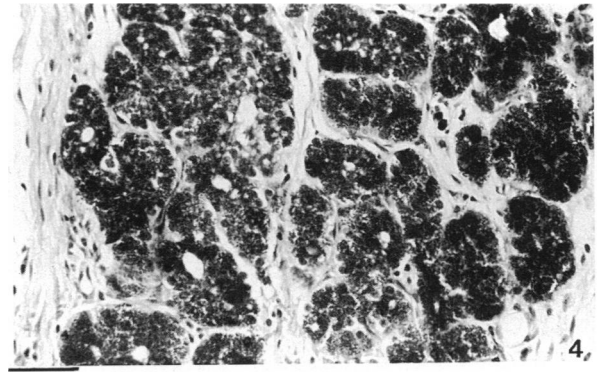
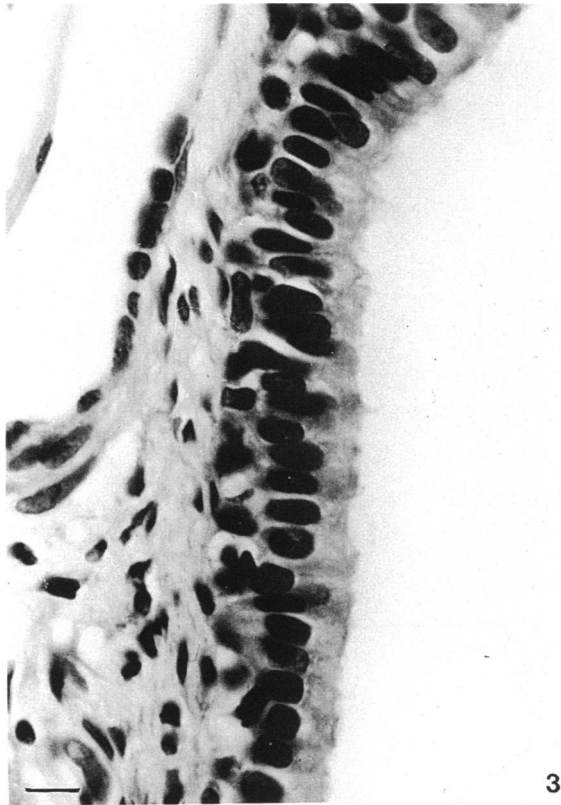


Fig. 3. Simple columnar epithelium which lines the more caudal part of the vomeronasal duct. Haematoxylin and eosin. Bar, 10  $\mu$ m.

Fig. 4. PAS positive (top) and Alcian blue negative (bottom) glands around the vomeronasal duct. Bars, 40  $\mu$ m.

Fig. 5. (a) Typical veins. Haematoxylin and eosin. Bar, 30  $\mu$ m. (b) Venous sinus (top) and an artery (bottom), showing the 3 components of its wall: tunica intima (arrowhead), t. media (M) and t. adventitia (A). Haematoxylin and eosin and Weigert. Bars, 20  $\mu$ m.

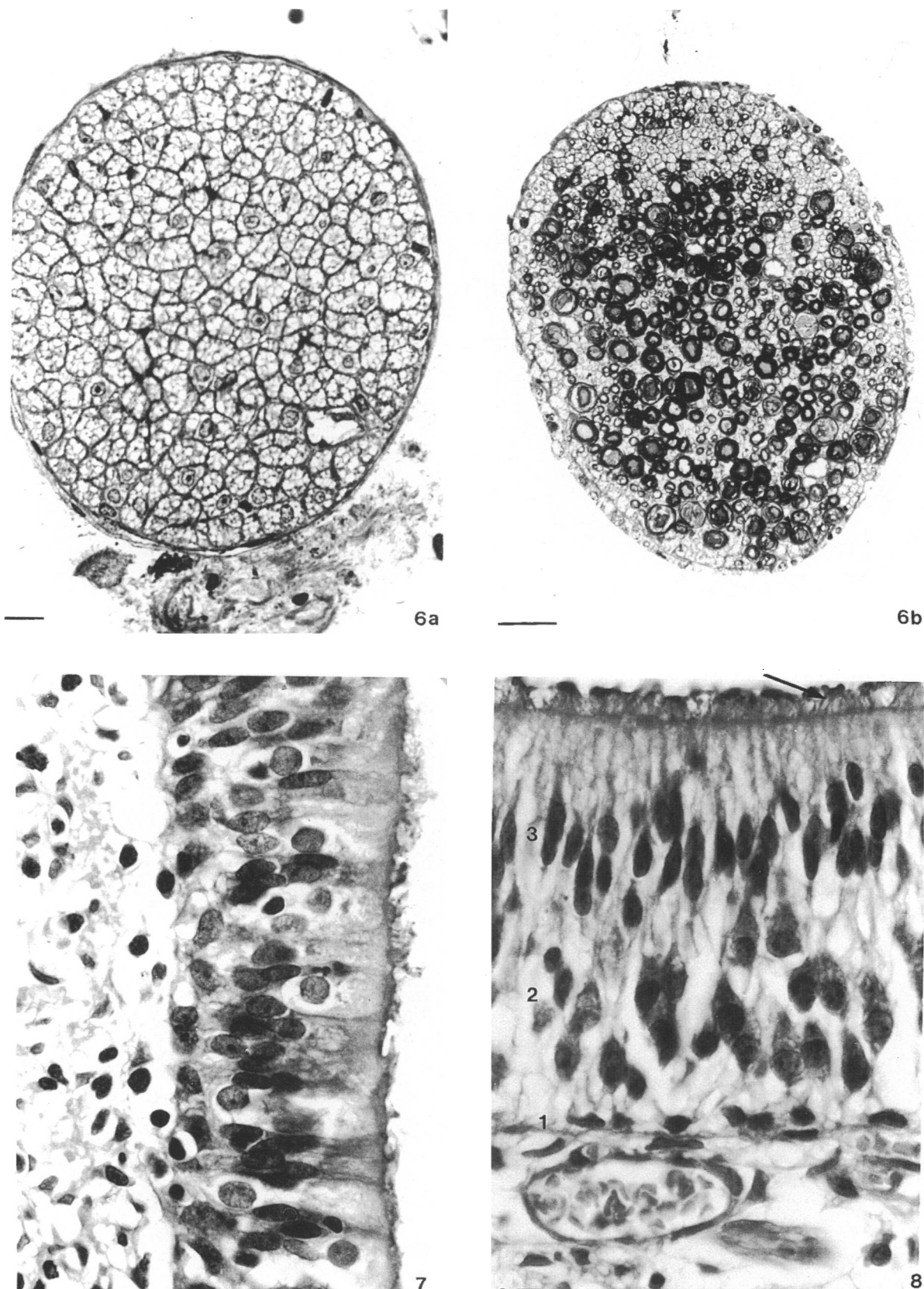


Fig. 6. Semithin transverse sections of the unmyelinated vomeronasal (*a*) and the mixed nasocaudal (*b*) nerves. Methylene blue/azur II. Bars, 10  $\mu$ m and 30  $\mu$ m.

Fig. 7. Ciliated respiratory epithelium characteristic of the lateral wall of the vomeronasal duct. Masson. Bar, 10  $\mu$ m.

Fig. 8. Receptor epithelium showing the basal (1), bipolar (2) and supporting cells (3), and microvilli (arrow). Masson. Bar, 10  $\mu$ m.

rabbit serum obtained from Dakopatts, diluted 1:10, for 30 min) the sections were sequentially incubated at room temperature with (1) mouse monoclonal antibodies to neuron-specific enolase (NSE) (Dakopatts, 1:100) for 1 h; (2) biotinylated rabbit antimouse immunoglobulins (Dakopatts, 1:400) for 30 min; (3) avidin-biotin-peroxidase complex (Vectastin Elite Kit, Vector, prepared following the manufacturer's instructions) for 30 min; and (4) 0.03% (w/v) solution of 3,3'-diaminobenzidine-tetrahydrochloride (Sigma) containing 0.003% (v/v) hydrogen peroxide, for 5 min. Between steps, the sections were washed with 0.001 M phosphate-buffered saline (PBS), pH 7.4, and after step (4) with distilled water. All dilutions were made in PBS. In some cases light counterstaining in haematoxylin was undertaken. Controls were performed either by omitting essential steps of the reaction or by replacing of the primary antibody with nonimmune mouse serum.

## RESULTS

The VNO of the cat is a bilateral formation located in the inferior part of the nasal cavity and, in direct relationship with the vomer, the palatine process of the maxillary bone and the incisive bone (Fig. 1). The VNO passes from the nasal to the oral cavity through the palatine fissure; its mean length, measured from the papilla incisiva to the caudal end of the vomeronasal cartilage, is 15 mm. Laterally the VNO is contained within the nasal mucosa. The spatial arrangement of the components of the VNO (cartilage, duct, glands, blood vessels, nerves and connective tissue) varies with level.

At level 1 (Fig. 2<sub>1</sub>) the vomeronasal duct (VNd) has just formed and is uniformly lined with simple columnar epithelium (Fig. 3). The VNd is surrounded by a small amount of connective tissue, while the most evident soft tissue components are the glands, which are distributed all around the VNd. Morphologically, the glands are of the serous acinar type, with the nucleus in the basal part of the cell and the secretory apparatus in the apical zone; they are PAS-positive and Alcian blue negative (Fig. 4). Several wide veins (Fig. 5a) up to 195 µm in diameter, and a reduced venous sinus (Fig. 5b) are located around the VNd. Two or 3 arteries of moderate size (Fig. 5b), about 55 µm in diameter, are also present in the vomeronasal parenchyma. Close to the medial sheet of the vomeronasal cartilage are the nonmyelinated fibres (Fig. 6a) of the vomeronasal nerves, which extend to the caudodorsomedial part of the VNO and terminate in the receptor epithelium. Ventrolaterally to the

VNd, 1 or 2 nerves with both myelinated and nonmyelinated axons can be observed (Fig. 6b); these are branches of the nasocaudal nerve, which enter caudally to the VNO and terminate in the glandular tissue.

At level 2 (Fig. 2<sub>2</sub>) the VNd is well developed, and its wall differs in several respects from that of the level 1 VNd: a typical respiratory epithelium (i.e. ciliated and pseudostratified) (Fig. 7) lines the lateral and dorsal parts, while the medial and ventral parts of the duct are lined by receptor (or sensory) epithelium (Fig. 8), commonly referred to as the vomeronasal epithelium. This receptor epithelium displays the following characteristics: (1) it has few basal cells with the nucleus oriented parallel to the lumen of the duct, (2) the widest stratum is formed by several layers of bipolar cells with rounded nuclei, (3) there is a layer of flattened supporting cells with prominent nuclei, and (4) the luminal layer is formed by extensions of the underlying cells, with microvilli always present and readily differentiated from the cilia of the respiratory epithelium. Connective tissue is most evident in the proximity of the VNd and the vomeronasal cartilage (VNC) (Fig. 9). Glands are numerous but are mainly distributed laterally and dorsally to the VNd, they are less frequent in ventral position, and very scarce in medial position. The duct system of these glands is poorly developed and opens into the lumen mainly in the lateral wall (Fig. 10). These glands are PAS-positive and Alcian blue-negative. The vascular elements are represented by 3 or 4 typical veins around 1 or 2 small arteries, all of them situated lateral to the lateral wall of the VNd; at this level 2, it is possible to distinguish 2 or 3 veins and 1 or 2 arteries medial to the VNd and smaller in size than the laterally located vessels. Several vessels of varying calibre, between 22 and 45 µm, with very thin walls comprised of very few cells, are distributed around the VNd, though they are more evident in the lateral and medial positions; these vessels form part of the venous sinus. At this level, 10-15 branches of the vomeronasal nerve can be observed close to the medial sheet of the vomeronasal cartilage; some of these are mixed fibres, but the majority comprise solely unmyelinated axons.

At level 3 (Fig. 2<sub>3</sub>), the VNd is crescent-shaped and better developed than at other levels, occupying much of the volume of the parenchyma. As at level 2, the wall of the duct bears respiratory epithelium with a maximum thickness of about 60 µm and receptor epithelium (Fig. 11), which is about 102 µm thick. Moving rostrally through level 3, the receptor epithelium gradually invades the dorsal part of the wall. Capillary blood vessels are more apparent at this level

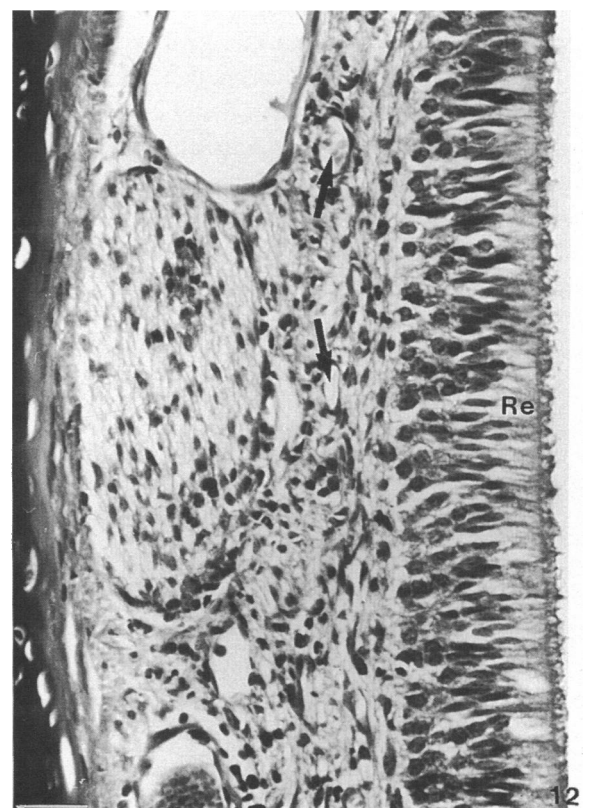
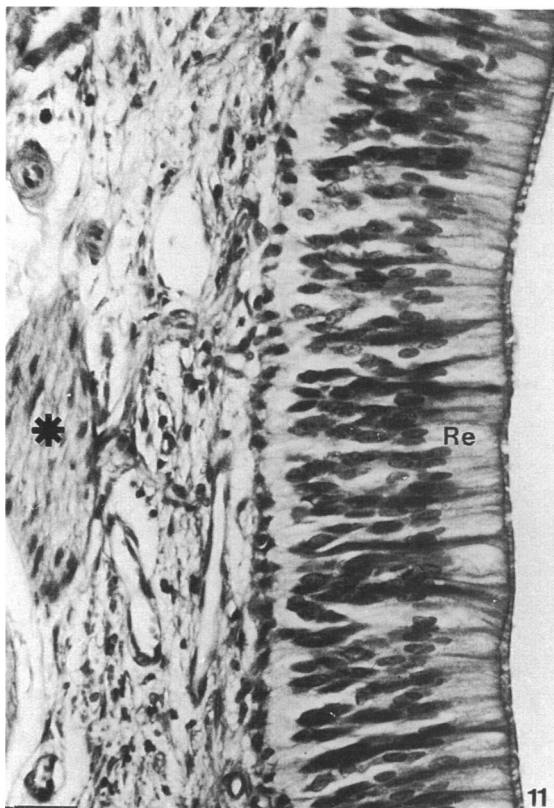
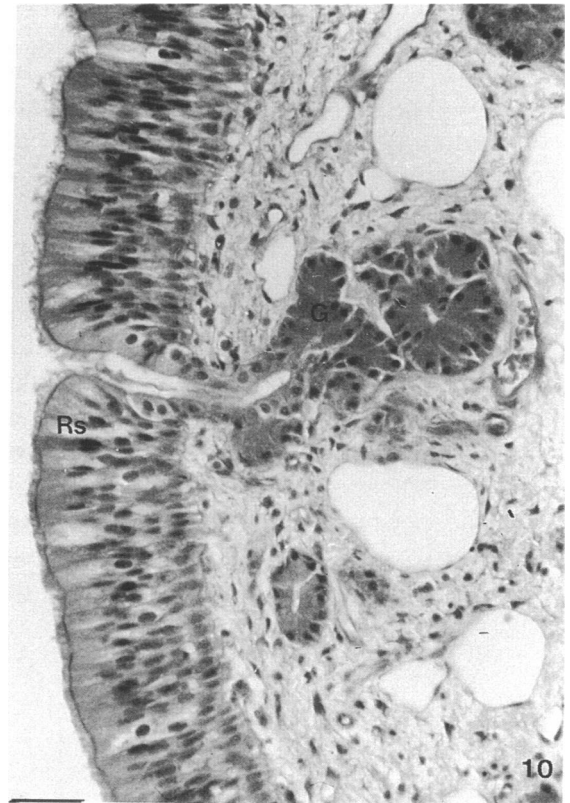
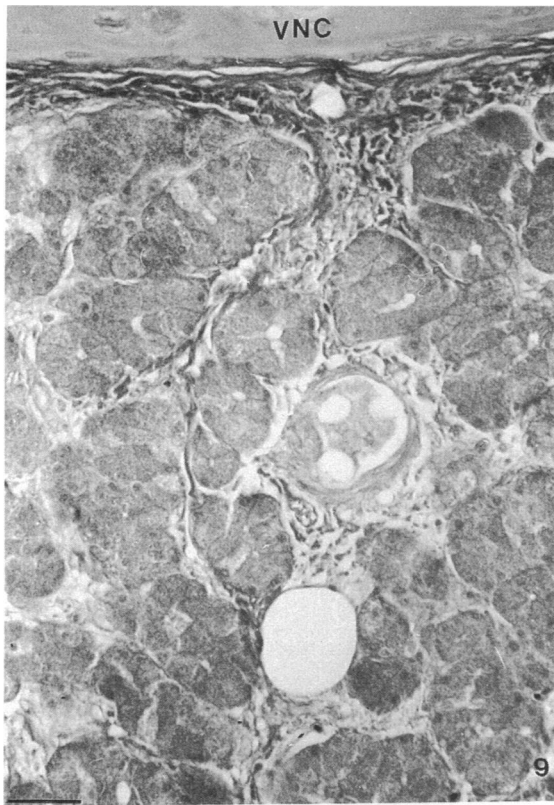


Fig. 9. General distribution of connective tissue between the vomeronasal cartilage (VNC) and the inside of the soft tissue. Weigert. Bar, 30  $\mu$ m.

Fig. 10. Typical appearance of vomeronasal glands (G) opening in the lateral wall of the vomeronasal duct (i.e. in the respiratory epithelium, Rs). PAS. Bar, 30  $\mu$ m.

than at other levels (Fig. 12). In sections stained immunohistochemically for NSE (Fig. 13), receptor cells and their extensions are evident. Partly as a consequence of the large size of the VND itself at this level, other soft tissue components gradually come to occupy less space and present a clearer distribution. The glands, with similar characteristics to those of level 2, are located in lateral and dorsal positions. There are 1 or 2 arteries in the middle of the lateral parenchyma, surrounded by 4 veins, while some small veins are present in medial position; the venous sinus is in a lateromedial position. Between the medial wall of the VND and the medial sheet of the VNC, however, the predominant structures are nerves, less in number than at level 2, and connective tissue.

Moving rostrally through level 4 (Fig. 2<sub>4</sub>), the receptor epithelium occupies a progressively smaller proportion of the medial part of the wall and there is a marked reduction in the number of glands and nerves, while a similar picture as before in relation with the distribution and size of the blood vessels is observed.

The rostralmost part of the VNO, at level 5 (Fig. 2<sub>5</sub>), is characterised by the absence of receptor epithelium and by a transition from respiratory epithelium to stratified squamous epithelium (Fig. 14); obviously, the lumen of the VND becomes progressively smaller. Glands are scarce (indeed, practically absent from rostralmost sections) and are PAS-positive and Alcian blue-negative. The glands, like the blood vessels and connective tissue, are situated around the VND. No nerves are present.

## DISCUSSION

As far as we are aware, there have been no previous studies of the VNO involving consideration of all the soft tissue components of this organ and investigation of the distribution of these components along the organ's full extent.

There is wide agreement that the vomeronasal duct is lined by 2 different types of epithelium, respiratory and receptor (Wysocki & Meredith, 1987). This has been demonstrated at the optical level and by other more sophisticated methods (Bannister & Dodson, 1992) in a representative selection of animals. From a phylogenetic standpoint, therefore, this is now clearly established (Eisthen, 1992). The cat is no exception to this rule: both Seifert (1971) and Kogure et al. (1989) have demonstrated the presence of both types of

epithelium, and our results confirm these findings. However, neither Seifert (1971) nor Kogure et al. (1989) mention the fact that the VND is additionally lined with another 2 types of epithelium: simple columnar in the caudal part and stratified squamous in the rostral part. Steinberg (1913), in her study of the VNO based on the examination of a single 30-d-old fetus, pointed out that the characteristics of the epithelium vary depending on position; she found 4 different linings, although she provides little information on differences between them. Wöhrmann-Repenning & Ciba (1989), who examined 2 cat embryos in order to investigate the embryonic development of the vomeronasal complex, provided no information with regard to the epithelium of the VND, probably because their principal goal was to study the cartilaginous component of the VNO and the relationship between this component and adjacent structures. We have recently published a study of the vomeronasal cartilage (Salazar et al. 1995*b*), and will not discuss it further here. With respect to the VND, however, the results of Vaccarezza et al. (1981) are very interesting; these authors found the same 4 types of epithelium in the VND of rat, with a very similar distribution to that observed by us in the cat. Vaccarezza et al. (1981) also described a rotation of the VND in its caudal part, which might be related to our observation of a gradual invasion of the dorsal part of the wall by receptor epithelium between levels 2 and 3; similar findings have been reported for the house musk shrew by Matsuzaki et al. (1993). Taniguchi & Mochizuki (1983) and Mendoza (1993), among others, have described the respiratory and receptor epithelia in the VNO of rats, mice, golden hamsters and rabbits, while Adams & Wiekamp (1984) have done the same for dogs. The results of these authors are similar to ours, and likewise indicate the presence of microvilli and blood capillaries in the receptor epithelium. However, Taniguchi & Mochizuki (1983) stated that the receptor epithelium is almost devoid of basal cells, whereas we found basal cells always to be present in cats, with a constant distribution in all sections in which the receptor epithelium is present.

Probably the most important difference between our results and previous results with regard to the vomeronasal glands (Vaccarezza et al. 1981; Taniguchi & Mochizuki, 1983; Mendoza, 1986) concerns the site at which the glands open into the lumen. In general, these glands are considered to open

Fig. 11. Fascicle of the vomeronasal nerve (asterisk) in the proximity of the receptor epithelium (Re). Masson. Bar, 30  $\mu$ m.

Fig. 12. Capillary blood vessels (arrows) just beside the basal cells (sparse in this picture) of the receptor epithelium (Re). Masson. Bar, 30  $\mu$ m.

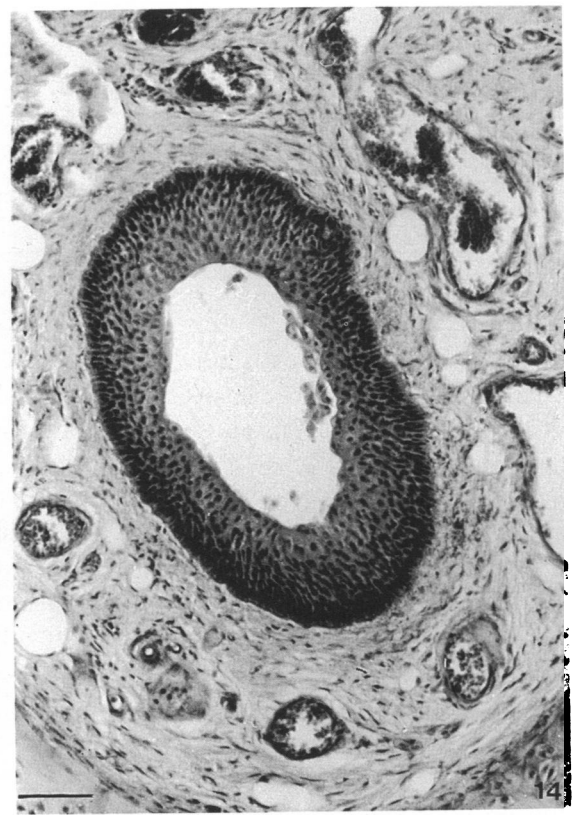
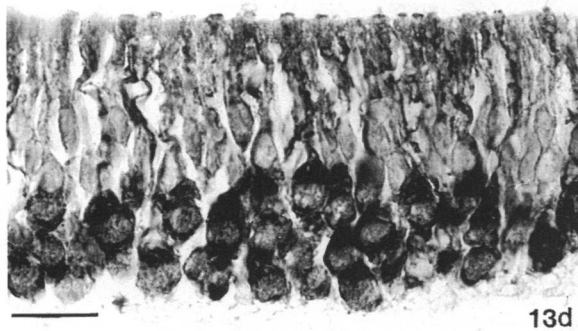
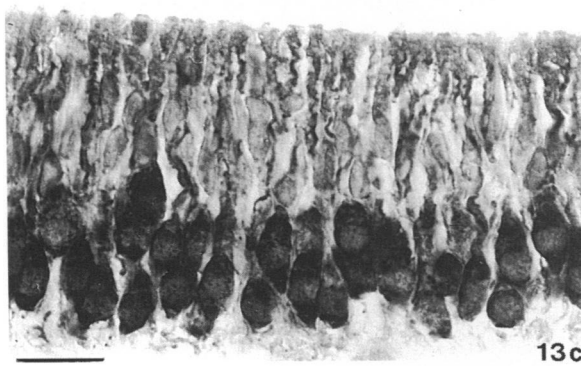
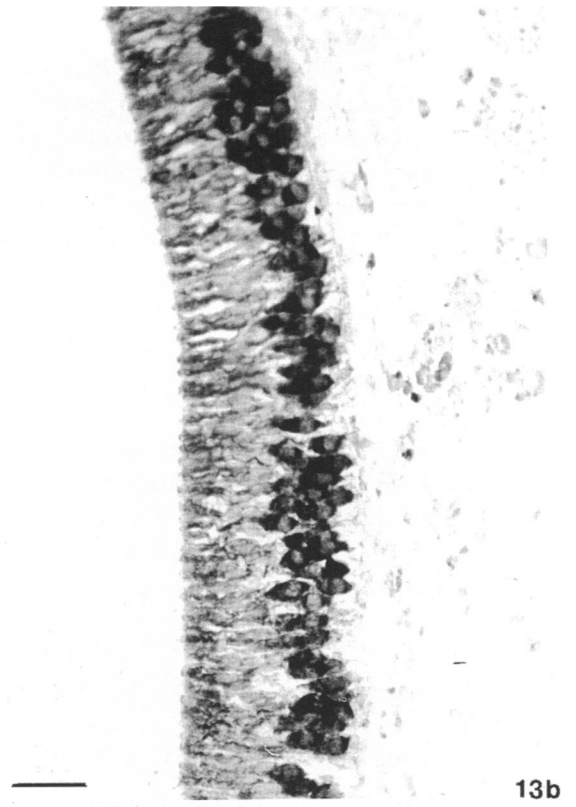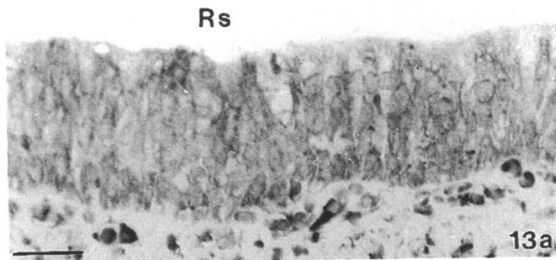
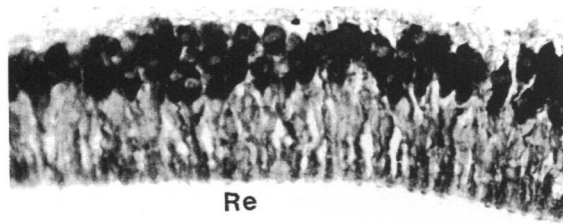


Fig. 13. NSE immunoreactivity of the wall of the vomeronasal duct to the NSE method. (a) Respiratory (Rs) and receptor (Re) epithelia. Bar, 30  $\mu$ m. (b) General appearance of receptor epithelium. Bar, 30  $\mu$ m. (c) and (d) Detail of the receptor cells including their dendrites. Bars, 20  $\mu$ m.  
Fig. 14. Stratified squamous epithelium which lines the rostrubuccal portion of the duct in transverse section. Haematoxylin and eosin. Bar, 30  $\mu$ m.



in a dorsal and ventral position, at the transition between the respiratory and receptor epithelia, as frequently observed in the present study. However, in the cat series studied by us, glands opened just as frequently in the lateral wall of the VND. Like Mendoza (1986), but unlike Taniguchi & Mochizuki (1983), we found the VNGs to be of serous acinus type; in addition, like Mendoza (1986) but unlike Vaccarezza et al. (1981), we found that the glands had a poorly developed duct system. Finally, unlike the situation in the golden hamster (Taniguchi & Mikami, 1982), the glands were Alcian blue-negative. Some of these differences might be due to between species variability or perhaps to between study differences in the segment of the VNO considered. In any case, our results confirm the serous nature of the vomeronasal glands of the cat, demonstrated under experimental conditions determined by Eccles (1982).

Comparison of our results and previous results for the characteristics and distribution of blood vessels in the VNO is complicated, partly for the reasons mentioned above and partly because most studies have paid little attention to this aspect. Adams & Wiekamp (1984), who considered veins only, reported some morphometric data. Taniguchi & Mochizuki (1983) reported that the venous sinuses are encircled by several layers of smooth muscle, while Matsuzaki et al. (1993) found that the sinuses are predominantly situated lateral to the lumen; neither of these studies considered arteries. Szabo & Mendoza (1988) have made important contributions to knowledge of the vascular system of the VNO, but their results are scarcely relevant to this discussion; nevertheless, we have previously verified that, in the cat, blood reaches the VNO mainly through the sphenopalatine artery (Salazar et al. 1995a). The vascularisation of the VNO will be considered in a forthcoming publication.

In transverse sections, at levels where receptor epithelium is present, several nerves are readily apparent between the VND and the medial sheet of the VNC. It is perhaps for this reason that previous authors have tended to report the presence of unmyelinated nerves without providing any photographic or other evidence. Even less frequently considered are the branches of the nasocaudal nerve, which terminate in the glandular complex; as in the Mendoza & Kühnel (1987) study of the mouse vomeronasal glands, we found these branches to contain both myelinated and unmyelinated axons.

#### ACKNOWLEDGEMENTS

The authors appreciate the excellent technical assistance of Ms A. Román and Mr J. Castiñeiras. This

work was supported by CICYT research grant AGF92-0561 from the Spanish Ministerio de Educación y Ciencia.

#### REFERENCES

- ADAMS DR, WIEKAMP MD (1984) The canine vomeronasal organ. *Journal of Anatomy* **138**, 771–787.
- BANNISTER LH, DODSON HC (1992) Endocytic pathways in the olfactory and vomeronasal epithelia of the mouse: ultrastructure and uptake of tracers. *Microscopy Research and Technique* **23**, 128–141.
- ECCLES R (1982) Autonomic innervation of the vomeronasal organ of the cat. *Physiology and Behaviour* **28**, 1011–1015.
- EISTHEN HL (1992) Phylogeny of the vomeronasal system and of receptor type cells in the olfactory and vomeronasal epithelia of vertebrates. *Microscopy Research and Technique* **23**, 1–21.
- HIS W (1880) *Anatomie menschlicher Embryonen*. Leipzig: Vogel.
- HSU SM, RAINE L, FANGER H (1981) The use of avidin–biotin–peroxidase complex (ABC) in immunoperoxidase techniques: a comparison between ABC and unlabelled antibody (PAP) procedures. *Journal of Histochemistry and Cytochemistry* **29**, 577–580.
- KOGURE N, AMEMORI T, MIZOGUCHI S, KIMURA J, TSUKISE A, OKANO M (1989) Scanning electron microscopical study on the feline vomeronasal organ. *Bulletin of the College of Agriculture and Veterinary Medicine, Nihon University* **46**, 108–116.
- KRETTEK JE, PRICE JL (1977a) Projections from the amygdaloid complex to the cerebral cortex and thalamus in the rat and cat. *Journal of Comparative Neurology* **172**, 687–722.
- KRETTEK JE, PRICE JL (1977b) Projections from the amygdaloid complex and adjacent olfactory structures to the entorhinal cortex and to the subiculum in the rat and cat. *Journal of Comparative Neurology* **172**, 723–752.
- KRETTEK JE, PRICE JL (1978a) Amygdaloid projections to subcortical structures within the basal forebrain and brainstem in the rat and cat. *Journal of Comparative Neurology* **178**, 225–254.
- KRETTEK JE, PRICE JL (1978b) A description of the amygdaloid complex in the rat and cat with observations on intra-amygdaloid axonal connections. *Journal of Comparative Neurology* **178**, 255–280.
- MATSUZAKI O, IWAMA A, HATANAKA T (1993) Fine structure of the vomeronasal organ in the house musk shrew (*Suncus murinus*). *Zoological Science* **10**, 813–818.
- MENDOZA A (1986) The mouse vomeronasal glands: a light and electron microscopical study. *Chemical Senses* **11**, 541–555.
- MENDOZA A (1993) Morphological studies on the rodent main and accessory olfactory systems: the regio olfactoria and vomeronasal organ. *Annals of Anatomy* **175**, 425–446.
- MENDOZA A, KÜHNEL W (1987) Morphological evidence for a direct innervation of the mouse vomeronasal glands. *Cell and Tissue Research* **247**, 457–459.
- RAISMAN G (1972) An experimental study of the projection of the amygdala to the accessory olfactory bulb and its relationship to the concept of a dual olfactory system. *Experimental Brain Research* **14**, 395–408.
- SALAZAR I, CIFUENTES JM, SANCHEZ QUINTEIRO P (1995a) The branches of the A. palatina descendens and its relationship with the vomeronasal organ of the cat. *Proceedings of the 2nd International Malpighi Symposium, Rome, Italy*.
- SALAZAR I, SANCHEZ QUINTEIRO P, CIFUENTES JM (1995b) Comparative anatomy of the vomeronasal cartilage in mammals: mink, cat, dog, pig, cow and horse. *Annals of Anatomy* **177**, 475–481.

- SANIDES-KOHLRAUSCH C, WAHLE P (1990) VIP- and PHI-immunoreactivity in olfactory centers of the adult cat. *Journal of Comparative Neurology* **294**, 325–339.
- SEIFERT K (1971) Licht- und elektronenmikroskopische Untersuchungen am Jacobsonschen Organ der Katze. *Archiv für klinische und experimentelle Ohren, Nasen und Kehlkopfheilkunde* **200**, 223–251.
- STEINBERG H (1913) Description de l'organe de Jacobson chez un foetus de chat. *Anatomischer Anzeiger* **42**, 466–472.
- SZABO K, MENDOZA AS (1988) Developmental studies on the rat vomeronasal organ: vascular pattern and neuroepithelial differentiation. I. Light microscopy. *Developmental Brain Research* **39**, 253–258.
- TANIGUCHI K, MIKAMI S (1982) Morphological studies on the vomeronasal organ in the golden hamster. *Japanese Journal of Veterinary Science* **44**, 419–426.
- TANIGUCHI K, MOCHIZUKI K (1983) Comparative morphological studies on the vomeronasal organ in rats, mice and rabbits. *Japanese Journal of Veterinary Science* **45**, 67–76.
- VACCAREZZA OL, SEPICH LN, TRAMEZZANI JH (1981) The vomeronasal organ of the rat. *Journal of Anatomy* **132**, 167–185.
- VERBERNE G (1976) Chemocommunication among domestic cats, mediated by the olfactory and vomeronasal senses. II. The relation between the function of Jacobson's organ and flehmen behavior. *Zeitschrift für Tierpsychologie* **42**, 113–128.
- VERBERNE G, DE BOER J (1976) Chemocommunication among domestic cats, mediated by the olfactory and vomeronasal senses. I. Chemocommunication. *Zeitschrift für Tierpsychologie* **42**, 86–109.
- WAHLE P, SANIDES-KOHLRAUSCH C, MEYER G, LUBKE J (1990) Substance P- and opioid-immunoreactive structures in olfactory centers of the cat: adult pattern and postnatal development. *Journal of Comparative Neurology* **302**, 349–369.
- WÖHRMANN-REPENNING A, CIBA B (1989) Zur spätembryonalen Entwicklung des Vomeronasalkomplexes der Katze. *Gegenbaurs Morphologisches Jahrbuch* **135**, 917–927.
- WYSOCKI CJ (1979) Neurobehavioral evidence for the involvement of the vomeronasal system in mammalian reproduction. *Neuroscience and Biobehavioral Reviews* **3**, 301–341.
- WYSOCKI CJ, MEREDITH M (1987) The vomeronasal system. In *Neurobiology of Taste and Smell* (ed. T. E. Finger & W. L. Silver), pp. 125–150. New York: John Wiley & Sons.