

Short Report

The apical caecal diverticulum of the chicken identified as a lymphoid organ

HIROSHI KITAGAWA, TOMOHIRO IMAGAWA AND MASATO UEHARA

Department of Veterinary Anatomy, Faculty of Agriculture, Tottori University, Japan

(Accepted 11 July 1996)

ABSTRACT

A peculiar structure, observed as a dome-like protrusion at the apex of the caecum, was investigated macroscopically and histologically in healthy White Leghorn chickens. It was hemispheric or spherical in shape and as it consisted of a lumen with a wall occupied by lymphoid tissue, this structure was designated the apical caecal diverticulum (ACD). ACD were detected in 25.2% of examined chickens and had a mean diameter and height of 1.9 mm and 1.2 mm respectively. Histologically, both the lamina propria mucosae and the submucosa of ACD consisted of well developed aggregated lymphoid nodules. Each nodule was covered by follicle-associated epithelium which contained cells resembling M cells. Some secondary nodules extended into the subserosa. The muscularis mucosae and the stratum circulae of the tunica muscularis disappeared near the entrance to ACD. The stratum longitudinale also gradually decreased in thickness around the entrance, becoming an extremely thin layer in the diverticulum wall. At the caecal apex, each stratum of the tunica muscularis was thinner than in the caecal body and separated into several muscle bundles. These bundles were occasionally displaced by developed lymphoid nodules, causing them to protrude into the subserosa. The high frequency of ACD suggests that caecal apex may be sites for immunological surveillance in the chicken caecum. In addition to the intense and frequent antiperistalsis at the apex suggested by Yasukawa (1959), possible causes for the formation of ACD included (1) the fragility of the tunica muscularis at the ACD, and (2) the local removal of the physical supporting structures by the development of lymphoid nodules.

Key words: Alimentary tract; gut-associated lymphoid tissue; large intestine; caecum; immunological surveillance.

INTRODUCTION

In most birds, the caeca commonly arise bilaterally at the junction of the small and large intestines. The caeca may be classified according to length into long, intermediate, short and vestigial categories. As in most birds, the chicken caecum is long and simple (McLelland, 1989). The galliform caeca are generally subdivided into a proximal portion or base, a middle portion, the body, and the tip or apex (McLelland, 1993). Both the body and apex occupy a major part of the caecum, preserving a unique environment. These areas are mainly populated by uric acid-degrading

bacteria that produce volatile fatty acids from retrogradable flowing urine. These acids are then reabsorbed by the caecal epithelium (Mead, 1989; Braun & Campbell, 1989). To continuously regulate the proliferation of specific microflora and to prevent the infection by foreign organisms, the gut-associated lymphoid tissue (GALT) must be richly populated at the caecal mucosa. However, no detailed distribution of lymphoid nodules has been reported in the mucosa of the body and apex, whereas well developed accumulated lymphoid nodules, termed the caecal tonsil, and distal lymphoid nodules have both been reported in the base (Hodges, 1974; Del Cacho et al.

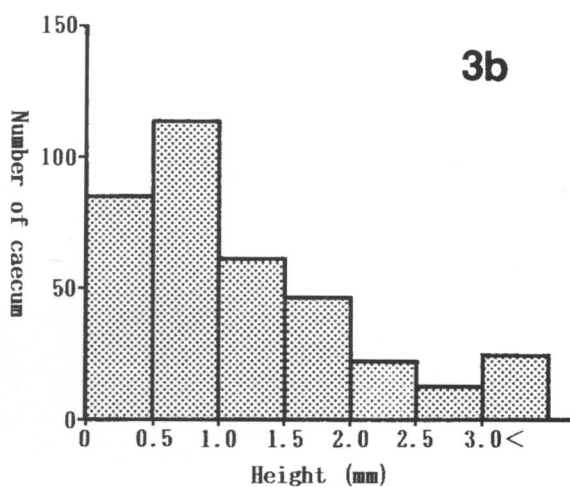
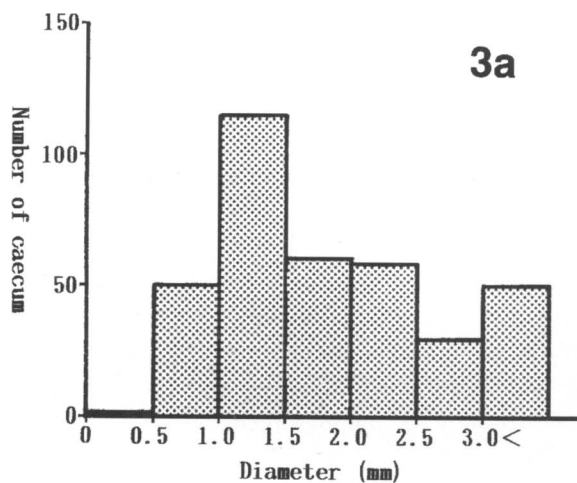
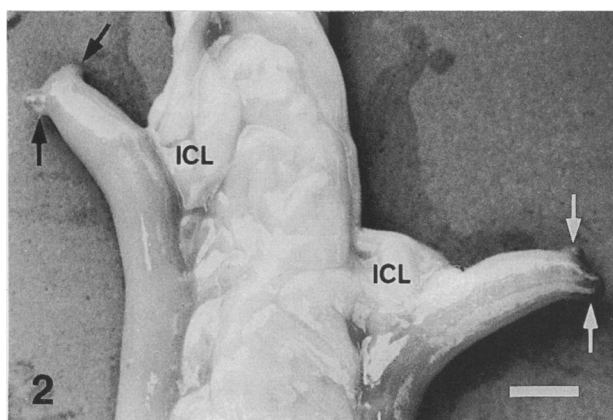
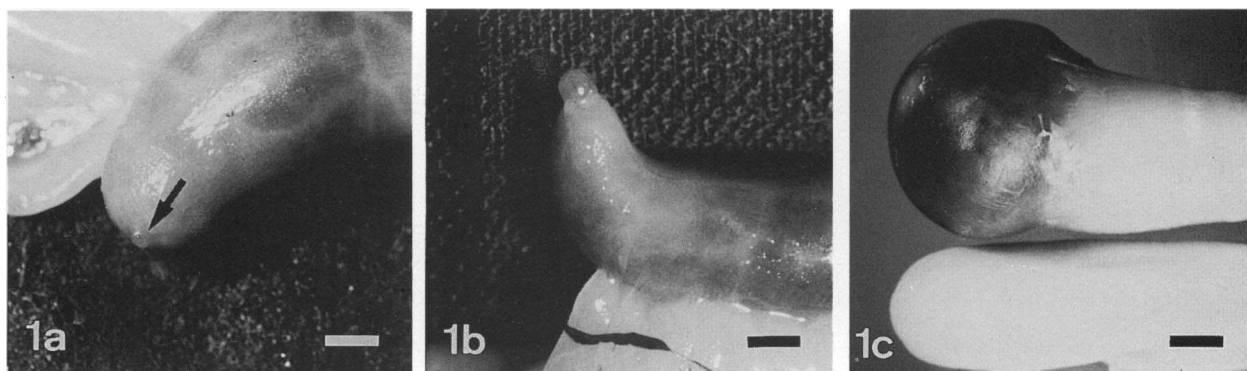


Fig. 1. Various sizes of apical caecal diverticulum (ACD) of chicken caeca. (a) Small ACD (arrow) with hemispheric form. (b) Medium ACD with an almost spherical form. (c) Large ACD presenting a dark colour from the luminal contents seen through the wall. Bar, 3 mm.

Fig. 2. Multiple apical caecal diverticula (arrows) at a caecal apex. ICL, ileocaecal ligament. Bar, 5 mm.

Fig. 3. Size variation of apical caecal diverticula in the chicken. (a) Diameter, (b) height.

1993). Our preliminary examination for GALT in the chicken caecum frequently revealed small diverticula at the apex in chickens of TU-1 line, which are

maintained as inherited dysgammaglobulinaemic chickens in Tottori University. This apical caecal diverticulum (ACD) was lined by well developed

lymphoid tissue. It is considered that the ACD may play an important role in immunological surveillance in the chicken caecum, similar to that provided by the caecal tonsils and distal lymphoid nodules. The existence and detailed morphology of ACD has not been described previously in domestic fowls. This study clarifies the gross anatomical and histological features of the ACD in the normal adult chicken caecum and also advances possible reasons for its genesis in the caecal apex.

MATERIALS AND METHODS

Gross anatomical examination

A total of 1068 pairs of caeca were obtained from healthy adult White Leghorn chickens from the commercial farms in the Tottori prefecture and from our colonies at Tottori University. Dysgamma-globulinaemic chickens were excluded. Spot checks using a radial immunodiffusion method demonstrated the normoglobulinaemic nature of these animals. The animals were killed by cervical exsanguination under anaesthesia by inhalation of diethyl ether or an i.v. injection of pentobarbital sodium. The number of ACD was recorded and their height and diameter were measured with a slide calliper on each side of paired caeca. The height was measured from the plane of the serous membrane to the tip of the ACD; the diameter was taken on a plane parallel to the serosa.

Histological examination

Thirty eight pairs of caeca were used. The fresh caeca were perfused intraluminally with neutral buffered 10% formalin solution or Bouin's fixative and cut into small specimens which were postfixed for 2–3 d in the same fixative. Serial paraffin sections (4 μ m) were obtained in a longitudinal plane through the ileocaecal ligament or transversely. The sections were stained alternately by haematoxylin-eosin and Masson's trichrome.

RESULTS

Gross anatomical examination

The ACD were recognised visually as dome-like protrusions at the caecal apex. They were hemispheric or spherical in shape. In large ACD, the luminal contents were faintly visible through the wall because

of its thinness (Fig. 1). ACD were present in 269 chickens (25.2% of the 1068 examined chickens). They were observed on the left in 6.2%, on the right in 13.9% and in both caeca in 5.1% of examined chickens. A single ACD was the most common finding (88% of chickens in which ACD were found); the remainder showed plural ACD at one apex (Fig. 2). The maximum number at a single apex was 5, seen in 0.3% of chickens with ACD, with frequencies for 2, 3 and 4 ACD of 9.9, 1.2 and 0.6%.

The diameter of ACD ranged from 0.3 mm to 8.7 mm, averaging 1.9 mm; the height ranged from 0.1 mm to 7.0 mm, averaging 1.2 mm (Fig. 3). No significant differences were detected in the size and the form of ACD between left and right caeca.

Histological examination

Numerous longitudinal folds usually protruded into the lumen of the body but not that of the apex. The appearance of the folds changed in relation to the contents of the lumen. In the folds there was diffuse lymphoid tissue mainly composed of lymphocytic infiltration which was abundantly distributed. The intestinal villi gradually became lower towards the caecal apex. Consequently the villi never presented typical appearances at the apex, whereas the crypts at this site were similar to those of the body. Numerous lymphoid nodules were distributed both in the lamina propria and the submucosa of the caecal apex where the tunica muscularis was thinner than in the body. Each stratum was divided into several muscle bundles which were arranged in different directions (Fig. 4).

In the ACD both the lamina propria and the submucosa were occupied by well-developed aggregated lymphoid nodules (Fig. 5). These consisted of diffuse lymphoid tissue and secondary nodules with germinal centres. The nodules were covered by follicle-associated epithelium which was composed predominantly of columnar epithelial cells with occasional goblet cells and a few cells resembling M cells with narrow striated borders. The latter generally exhibited paler cytoplasm and nuclei and were accompanied by numerous migrating intraepithelial cells (Fig. 6). Some secondary ACD nodules protruded into the tela subserosa.

The muscularis mucosae, which was thin at the caecal apex, began to disappear at the entrance to ACD and was never found in the lymphoid nodules of the wall (Fig. 7). The stratum circulae and stratum longitudinale both abruptly decreased in thickness around the entrance of ACD. The stratum circulae

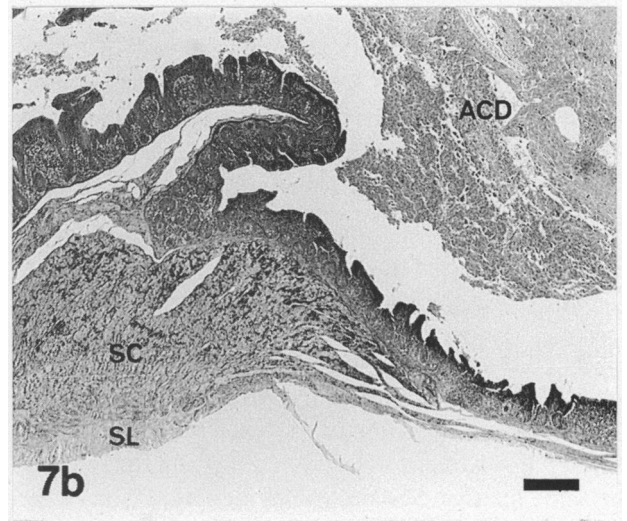
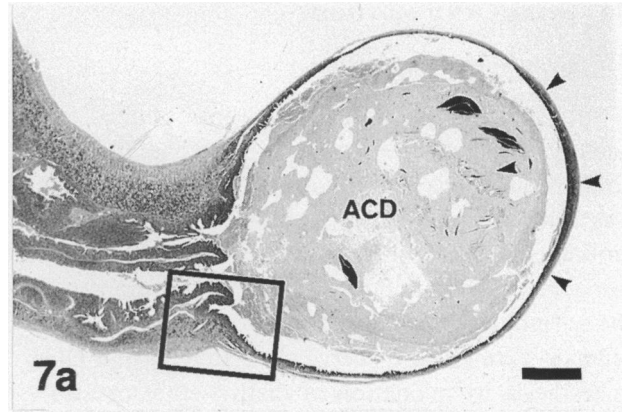
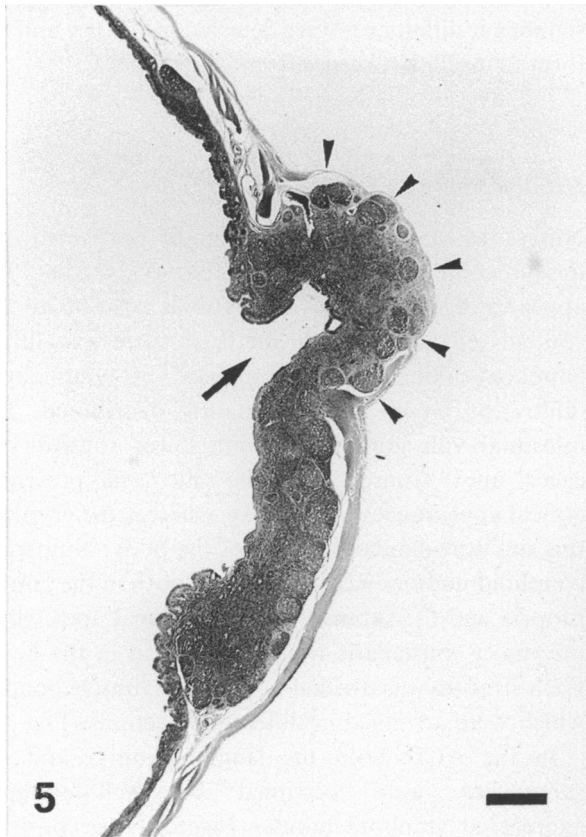
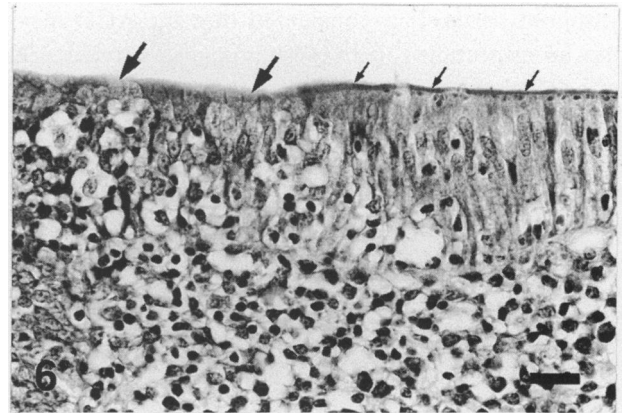
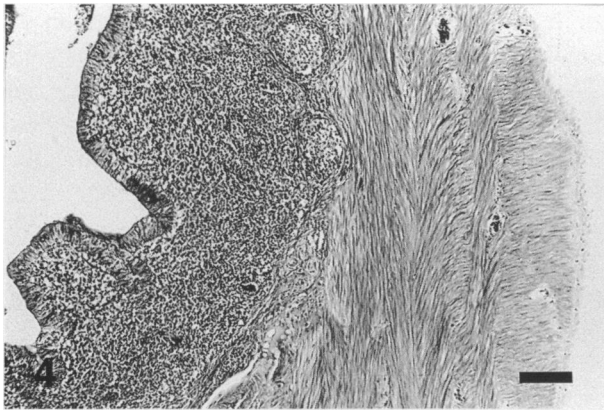


Fig. 4. Transverse section of caecal apex. Each stratum of the tunica muscularis is separated into several bundles. Bar, 100 μ m.

Fig. 5. Longitudinal section of caecal apex. Aggregated lymphatic nodules penetrate through the tunica muscularis (arrowheads). Arrow, lumen of an apical caecal diverticulum. Bar, 0.5 mm.

Fig. 6. Follicle-associated epithelium of an apical caecal diverticulum. A striated border is not visible on the cluster of M-like cells (large arrows) in the left half of the epithelium, whereas the ordinary columnar epithelium possesses a marked striated border (small arrows). The clusters of M-like cells are accompanied by numerous migrating intraepithelial cells. Bar, 20 μ m.

Fig. 7. Longitudinal sections of caecal apex. (a) Low magnification micrograph of an apical caecal diverticulum (ACD). The slightly thickened and dark wall (arrowheads) consists of flattened aggregated lymphoid nodules at the extreme end of the ACD. The area within the frame is enlarged in (b). Bar, 1 mm. (b) Both the stratum circulare (SC) and the stratum longitudinale (SL) abruptly decrease in thickness at the entrance to the ACD. Bar, 0.5 mm.

was rarely detected in the diverticulum wall whereas the stratum longitudinale remained as an extremely thin layer. In most cases, both layers of the tunica

muscularis were displaced by those developed secondary lymphoid nodules which reached the tela subserosa.

DISCUSSION

Some histological differences have been described between the 3 portions of chicken caeca. The thickness of the caecal wall gradually becomes thinner from the base to the apex (Bradley & Grahame, 1960; Hodges, 1974). Beyond the constricted part of the caecal apex the wall is much thinner, especially near its blind extremity (McLeod, 1939). In addition, the stratum circulae and the stratum longitudinale are separated respectively into several muscle bundles at this region. Thus the thinness and fragility of the tunica muscularis at the caecal apex could contribute to the development of ACD as many other factors discussed below.

The amount of lymphoid tissue increases from the mouth to the apex of chicken caeca (Turk, 1982). Profusely distributed lymphoid tissues in the mucosa of the apex (Bradley & Grahame, 1960) are consistent with our results. Lymphoid tissue with germinal centres occupies only the lamina propria in the chicken caecum (Calhoun, 1933; Kitamura et al. 1976). Looper & Looper (1929) and Hodges (1974), however, also found lymphoid nodules in the submucosa of the distal caecum. Moreover, our observation showed that both the muscularis mucosae and the tunica muscularis were displaced by developed secondary lymphoid nodules. Consequently, the development of lymphoid nodules gave rise to the local loss of the physical supporting structures at the caecal apex. The phenomenon could be regarded as another factor contributing to the genesis of ACD in addition to the fragility of the tunica muscularis.

Yasukawa (1959) clarified the detailed motility of the chicken caecum. Briefly, weak peristalsis initiated from the extreme end of the apex proceeds slowly along the caecum and strong peristalsis (mass peristalsis) from the extreme tip of the apex progresses quickly to the anal end of colon. The mass peristalsis strongly constricts the boundary between the body and the apex. Following this, strong antiperistalsis proceeds from the boundary between the body and the apex to the extreme end of the apex. Meanwhile, less vigorous antiperistalsis originating at the junction between the colon and the cloaca travels along the caeca to the apex. At the same time as this antiperistalsis passes through the boundary between the body and the apex, antiperistalsis occurs 1–3 times at the apex. Thus the wall of apex is always affected by frequent antiperistalsis. The high pressures induced by antiperistalsis may further promote the formation of ACD.

Major lymphoid tissues in the caecum have been

well documented for the caecal tonsils of the normal chicken (Muthmann, 1913) and the distal lymphoid nodules located at the distal region approximately 3 cm from the ileocaecal junction in *Eimeria tenella*-infected chickens (Del Cacho et al. 1993). The distal lymphoid nodules represent a specialised mucosa-associated lymphoid tissue that responds to antigens in the caecal lumen to enhance the mucosal defence against luminal antigens that is provided by the caecal tonsils (Del Cacho et al. 1993). The ACD are covered by follicle-associated epithelium which plays an important role in the uptake of information from the lumen as recognised for chicken Peyer's patches (Burns, 1982). Moreover, the high frequency of ACD suggests that the caecal apex represents a suitable site for immunological surveillance in the chicken caecum. This also suggests that the caecal host defence system of the chicken should not be investigated without regard to the lymphoid tissue of the apex. We are proceeding with further investigations concerned both with the ability of ACD to take up particulates and with the detailed distribution of lymphoid nodules through the caecum in order to clarify the functional significance of ACD in the caecal host defence system.

ACKNOWLEDGEMENTS

This work was supported in part by Grant-in-Aid for Scientific Research (nos 01560315 and 03660307) from the Ministry of Education, Science and Culture, Japan.

REFERENCES

- BRADLEY OC, GRAHAME T (1960) *The Structure of the Fowl*, 4th edn, pp. 31–50. Edinburgh: Oliver and Boyd.
- BRAUN EJ, CAMPBELL CE (1989) Uric acid decomposition in the lower gastrointestinal tract. *Journal of Experimental Zoology* (Suppl. 3), 70–74.
- BURNS RB (1982) Histology and immunology of Peyer's patches in the domestic fowl (*Gallus domesticus*). *Research in Veterinary Science* 32, 359–367.
- CALHOUN ML (1933) The microscopic anatomy of the digestive tract of *Gallus domesticus*. *Iowa State College Journal of Science* 7, 261–381.
- DEL CACHO E, GALLEGO M, SANZ A, ZAPATA A (1993) Characterization of distal lymphoid nodules in the chicken caecum. *Anatomical Record* 237, 512–517.
- HODGES RD (1974) *The Histology of the Fowl*, pp. 64–88. London: Academic Press.
- KITAMURA H, SUGIMURA M, HASHIMOTO Y, YAMANO S, KUDO N (1976) Distribution of lymphoid tissues in duck caeca. *Japanese Journal of Veterinary Research* 24, 37–42.
- LOOPER JB, LOOPER MH (1929) A histological study of the colic caeca in the bantam fowl. *Journal of Morphology* 48, 585–609.
- MCLELLAND J (1989) Anatomy of the avian caecum. *Journal of Experimental Zoology* (Suppl. 3), 2–9.
- MCLELLAND J (1993) Apparatus digestorius [Systema alimentarium]. In *Handbook of Avian Anatomy: Nomina Anatomica Avium*, 2nd edn (ed. Baumel JJ, King AS, Breazile JE,

- Evans HE, Vanden Berge JC). Cambridge: Nuttall Ornithological Club.
- MCLEOD WM (1939) Anatomy of the digestive tract of domestic fowl. *Veterinary Medicine* **34**, 722-727.
- MEAD GC (1989) Microbes of the avian cecum: types present and substrates utilized. *Journal of Experimental Zoology* (Suppl. 3), 48-54.
- MUTHMANN E (1913) Beiträge für vergleichende Anatomie der Blinddarmes der lymphoiden Organe des Darmkanales bei Säugetieren und Vögeln. *Anatomische Hefte* **48**, 67-114.
- TURK DE (1982) The anatomy of the avian digestive tract as related to feed utilization. *Poultry Science* **61**, 1225-1244.
- YASUKAWA M (1959) Studies on the movements of the large intestine. *Japanese Journal of Veterinary Science* **21**, 1-9.