

Short Report

Endoanal MRI of the anal sphincter complex: correlation with cross-sectional anatomy and histology

S. M. HUSSAIN¹, J. STOKER¹, A. W. ZWAMBORN¹, J. C. DEN HOLLANDER², J. W. KUIPER¹,
C. A. C. ENTIUS³, AND J. S. LAMÉRIS

Departments of ¹Radiology, ²Pathology and ³Anatomy, Erasmus University and University Hospital Rotterdam, The Netherlands

(Accepted 16 July 1996)

ABSTRACT

The purpose of this study was to correlate the *in vivo* endoanal MRI findings of the anal sphincter with the cross-sectional anatomy and histology. Fourteen patients with rectal tumours were examined with a rigid endoanal MR coil before undergoing abdominoperineal resection. In addition, 12 cadavers were used to obtain cross-sectional anatomical sections. The images were correlated with the histology and anatomy of the resected rectal specimens as well as with the cross-sectional anatomical sections of the 12 cadavers. The findings in 8 patients, 11 rectal preparations, and 10 cadavers, could be compared. In these cases, there was an excellent correlation between endoanal MRI and the cross-sectional cadaver anatomy and histology. With endoanal MRI, all muscle layers of the anal canal wall, comprising the internal anal sphincter, longitudinal muscle, the external anal sphincter and the puborectalis muscle were clearly visible. The levator ani muscle and ligamentous attachments were also well demonstrated. The perianal anatomical spaces, containing multiple septae, were clearly visible. In conclusion, endoanal MRI is excellent for visualising the anal sphincter complex and the findings show a good correlation with the cross-sectional anatomy and histology.

Key words: Anorectum; magnetic resonance imaging.

INTRODUCTION

In the surgical literature, the external anal sphincter has been described as consisting of 1, 2 or 3 parts (Dalley, 1987). According to Milligan & Morgan (1934) the external anal sphincter consists of subcutaneous, superficial and profundus components. Goligher et al. (1955), on the other hand, found no suggestion of division of the external anal sphincter into separate parts: the muscle was considered to be a single continuous sheet. Oh & Kark (1972) proposed a 2 compartment organisation and later Shafik (1975) proposed a triple-loop system. More recently, Ayoub (1979) was unable to detect any planes of separation that divided the sphincter into parts.

These concepts were based on dissection studies, often strengthened by surgical experience (Dalley, 1987). After the introduction of endoanal sonography (Law & Bartram, 1989) it became possible to visualise the anal sphincters *in vivo*. The external anal sphincter is well demonstrated with this technique (Law & Bartram, 1989). In our experience, other structures, including the external anal sphincter and the perianal anatomical spaces, were either variable in echogenicity or not visible at all. Moreover endoanal sonography is mainly restricted to the axial plane and is operator-dependent. Such limitations caused diagnostic problems in patients with faecal incontinence and fistula-in-ano.

To overcome these problems, magnetic resonance

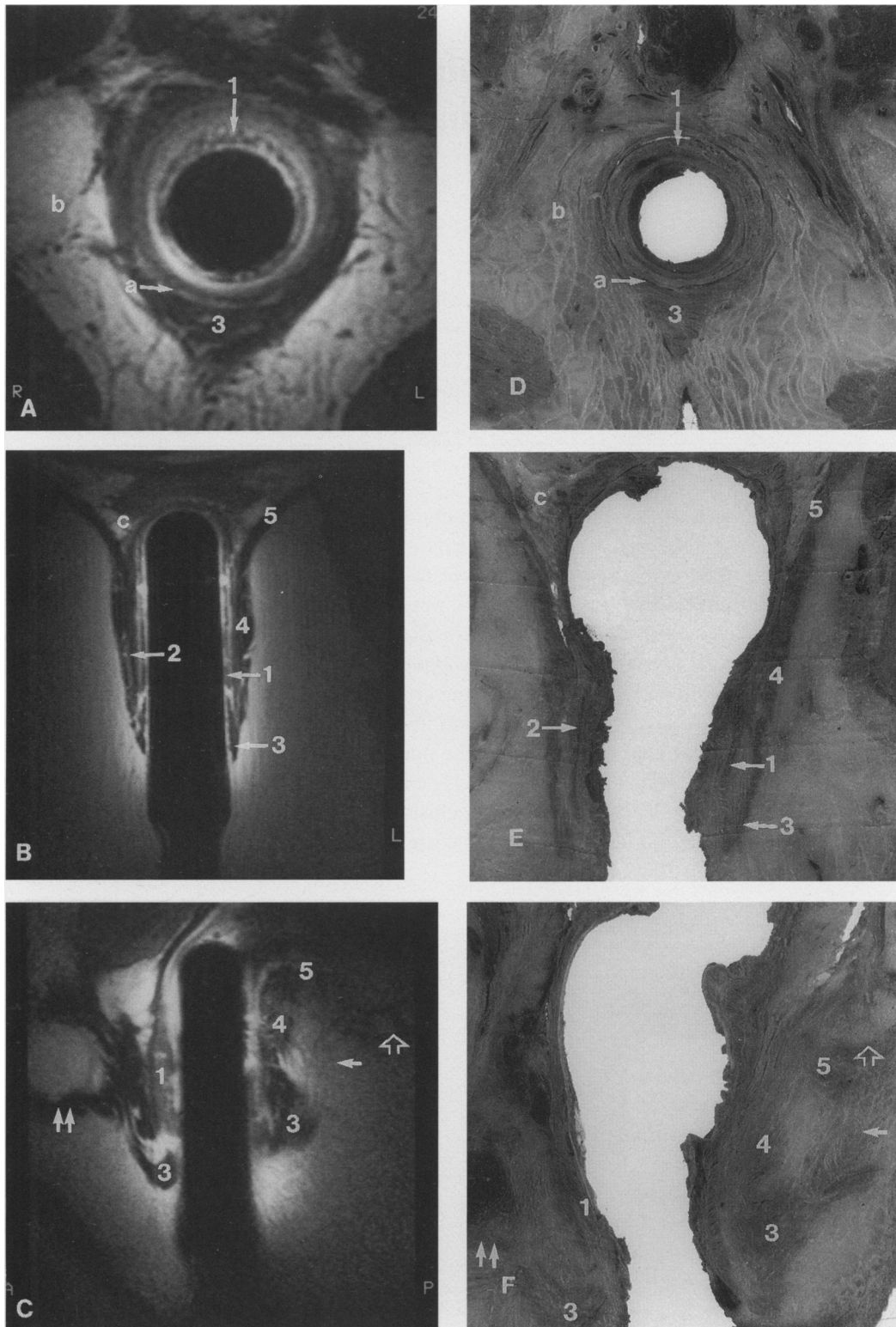


Fig. 1. MR-anatomical correlation. In the axial section (compare *A* with *D*), the muscle layers of the anal canal wall, comprising the internal anal sphincter (1), the conjoint longitudinal muscle (2), and the external sphincter (3) show an excellent correlation. In the coronal plane (compare *B* with *E*), the shape and the position of the external anal sphincter (3), the puborectalis muscle (4) and the levator ani muscle (5) should be noted. In the sagittal plane (compare *C* with *F*), note the anococcygeal ligament (arrow), which attaches the external anal sphincter (3) to the coccyx (open arrow). *a*, intersphincteric space; *b*, ischioanal space; *c*, supralelevator space; double arrow, bulbocavernosus muscle.

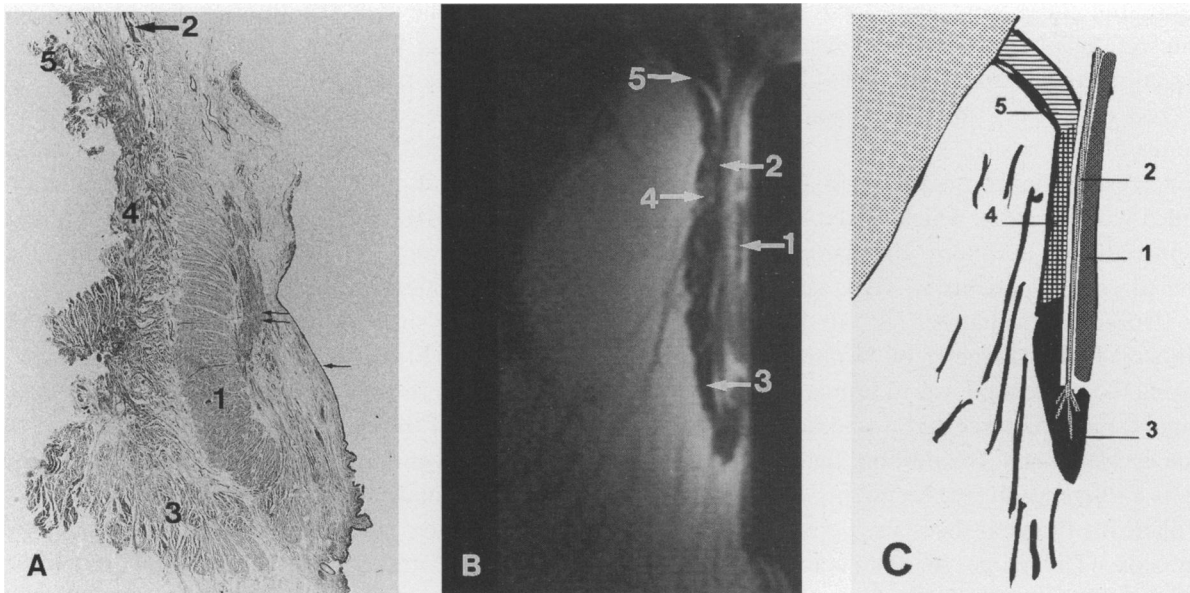


Fig. 2. MR-histological correlation. The right lateral half of the anal canal in the coronal plane is represented by a histological specimen (A), an MR image (B) with the corresponding drawing (C). The muscles of the anal sphincter complex comprising the internal anal sphincter (1), the conjoint longitudinal muscle (2), the external anal sphincter (3), the puborectalis muscle (4), and the levator ani muscle (5), show an excellent MR-histological correlation. Note in A, the epithelium (arrow) and the anal muscularis mucosae (double arrow) which are not visible on MRI (B).

imaging (MRI) with a rigid endoanal coil was introduced (Hussain et al. 1994). The anatomical concept of the anal sphincter complex emerging from the endoanal MRI was in many aspects different from the current anatomical views (Hussain et al. 1995).

The purpose of this study was to validate the recent MRI findings of the anal sphincter complex *in vivo* by obtaining a correlation between the MRI findings and the cross-sectional anatomy and histology.

MATERIALS AND METHODS

Fourteen patients (8 men and 6 women with a mean age of 58.5 y, range 27–81 y) with rectal tumours were examined with a rigid endoanal MRI coil before undergoing abdominoperineal resection. Informed consent was obtained before examination. The resected rectal preparations were used to obtain anatomical and histological slices. In addition, 12 cadavers (6 men and 6 women with a mean age of 64.3 y, range 56–71 y) were used to obtain anatomical sections. The cadavers belonged to the Department of Anatomy for research purposes.

MRI study

In each patient MRI was performed at 0.5 Tesla (Gyrosan T5-II, Philips Medical Systems, Best, The

Netherlands). To reduce bowel motion, 1 ml of butylscopolamine bromide (Buscopan 20 mg/ml, Boehringer Ingelheim, Germany) was injected intramuscularly before scanning. A recently developed rigid endoanal coil with a diameter of 19 mm (Philips Medical Systems, Best, The Netherlands) was used. The imaging was performed in the axial, coronal and sagittal planes. The axial T2-weighted 3-dimensional gradient-echo sequence (T2-weighted contrast enhanced fast field echo, acquisition time 6.5 min, imaging matrix 205×256 , number of signal averages (NSA) 2, repetition time (TR) 30 ms, echo time (TE) 13 ms, flip angle 60° , field of view (FOV) 140 mm, slice thickness 2 mm), was placed perpendicular to the long axis of the endoanal coil. Thirty-two contiguous slices were obtained. For the sagittal and the coronal scans, a T2-weighted turbo spin-echo was performed (acquisition time 5.0 min, imaging matrix 186×256 , NSA 8, TR 2800, TE 120, turbo factor 10, FOV 120 mm, slice thickness 4.0 mm with an interslice gap of 0.4 mm).

Anatomical and histological study

The rectal preparations of the patients were sliced in the axial, coronal and sagittal directions. For histology, anatomical slices of 4 different rectal preparations were fixed in 4% formalin for 2 d. After

fixation, the slices were embedded in paraffin and 10 µm sections obtained for histological examination. The sections were stained with Masson trichrome for easy recognition of muscles, ligaments and collagenous fibrous tissue.

For cross-sectional anatomy, in each cadaver a rounded wooden stick, which served as a pseudocoil, was introduced at about the same angle as the endoanal coil in patients *in vivo*, and the cadavers were frozen immediately for at least 3 d. The pseudocoil had a diameter of 18 mm. The rationale for using the pseudocoil was to simulate all changes in the anal canal structures that would have been caused by the endoanal coil. In addition, the pseudocoil was used as a reference during sectioning of the cadavers. The plane for the axial slices was perpendicular to the pseudocoil. The plane for the coronal slices was parallel to the pseudocoil. The sagittal plane was determined by drawing a line between the processus spinosi and the pseudocoil.

The MRI scans and anatomicohistological sections of the rectal preparations and the cadavers were compared side-by-side in order to correlate MR findings with the anatomy and histology.

RESULTS

The MRI scans from 2 patients were excluded because of excessive movement artifact. Of the 14 rectal resection preparations from the patients, 3 were omitted because of histological evidence of invasion of the internal anal sphincter. Of the 12 cadavers, 2 had to be excluded because of errors which occurred during sectioning. The data from the remaining 8 patients, 11 rectal preparations and 10 cadavers were compared.

In these cases, endoanal MRI correlated well with the cross-sectional anatomy and histology in the axial, coronal and sagittal planes (Figs 1, 2). In the axial plane, the layers of the anal canal wall correlated well with the anatomical sections (Fig. 1*A, D*). In the coronal plane, the muscle layers of the lower and upper parts of the anal canal differed (Fig. 1*B, E*). The lower part of the anal canal was surrounded by the internal anal sphincter, the longitudinal muscle and the external anal sphincter. The upper part comprised the internal anal sphincter, the longitudinal muscle and the sling of the puborectalis muscle (Fig. 1*B, E*). The males and females differed particularly in the anterior part of the external anal sphincter. In the female, the anterior external anal sphincter was shorter and had no muscular support anteriorly,

whereas in the male the anterior part of the external anal sphincter was connected to the bulbocavernosus muscle of the penis.

Due to the compressive effect of the MRI coil, the epithelium and the subepithelial structures, such as the anal musculus submucosae were difficult to identify by MRI (Fig. 2). The muscle layers of the anal canal wall were well visualised. The internal anal sphincter, which is the inner most muscle layer of the anal canal, showed an excellent MRI-anatomical correlation (Figs 1, 2). The longitudinal muscle, the layer next to the internal anal sphincter, traversed the distal part of the external anal sphincter (Figs 1*C, 2*). The external anal sphincter surrounded only the lower part of the anal canal. The distal ends of the external anal sphincter, particularly in the midcoronal plane, were folded inwards and upwards. This important finding correlated well with the cross-sectional anatomy (Fig. 1*B, E*) and histology (Fig. 2). The puborectalis muscle formed a sling around the upper part of the anal canal. The levator ani muscle was easily recognisable on MR images and in the anatomical sections (Fig. 1*B, E*).

Of the perianal anatomical spaces, the intersphincteric space, i.e. the space between the internal and the external anal sphincters and the puborectalis, was filled with connective tissue as well as fibres of the longitudinal muscle (Fig. 2). The ischioanal space, i.e. the space around the anal canal, contained fatty tissue mixed with multiple fibrous septae (Figs 1, 2). Also the deep postanal space of Courtney, i.e., the space posterior to the anal canal and above the ano coccygeal ligament, was clearly identifiable (Fig. 1*C, F*). The supralelevator space was well identifiable above the levator ani muscle (Figs 1*B, 2*).

DISCUSSION

In this study, MRI of the patients was correlated with the resected rectal specimens of the same patients as well as with cross-sectional cadaveric anatomy. The cadaveric material was necessary because of a frequently incomplete removal of the anal sphincter complex during abdominoperineal resection. A direct MR-anatomical correlation with the cadaveric material was not possible as the signal intensity of the muscles in the cadaveric MR images, probably due to tissue changes during fixation, was very low.

The basic anatomical concept of the anal sphincter complex has been controversial in the literature (Dalley, 1987). Endoanal MRI is a new technique which provides a different way of looking at the

anatomy of the anal sphincter complex (Hussain et al. 1995). Endoanal MRI findings show an excellent correlation with the cross-sectional anatomy and histology.

The use of the rigid MRI coil leads to the high-resolution thin MR images. The muscle layers of the anal canal were therefore well recognisable. A disadvantage of the rigid coil, which has to be placed within the anal canal, is the compression of the epithelium and the subepithelial tissue, such as the anal musculus mucosae, of the anal canal. The visualisation of the muscle layers of anal canal and the perianal anatomical spaces is, however, clinically more important, for instance, in patients with perianal fistulae and faecal incontinence.

The laminar concept of the external anal sphincter (Milligan & Morgan, 1934; Goligher et al. 1955; Oh & Kark, 1972; Shafik, 1975) has probably originated from using different dissection techniques and by studying slightly different parts of the sphincters. The differences between these previous concepts and the endoanal MRI findings of the anal canal have been stressed previously (Hussain et al. 1995).

Soon after the introduction of endosonography (Law & Bartram, 1989), normal appearance of the sphincters was correlated with anatomy (Sultan et al. 1993a). This study showed a good correlation between endosonography and anatomy at certain levels of the anal canal in the axial plane, although, due to the limitations of endosonography, the complex anatomical nature of this region was not fully understood.

An additional, important observation during the current study was that the anal sphincter complex is contained within a small volume, not much larger than about 6 cm³. Within this space, the muscles changed their configuration as well as their relationship to the adjacent structures. For instance, in the coronal plane, at the level of the anal canal, the puborectalis muscle appears as a part of the external sphincter, while more anteriorly, in the same plane, it becomes a component of the levator ani muscle (Hussain et al. 1995). The puborectalis may, therefore, have been mistaken for the profundus part of the external anal sphincter (Milligan & Morgan, 1934; Goligher et al. 1955; Oh & Kark, 1972; Shafik, 1975). Currently the puborectalis muscle, its location in the upper part of the anal canal, was seen to contribute fibres to the longitudinal muscle. This finding was important in distinguishing the puborectalis muscle from the external anal sphincter.

With a combination of multiplanar capability and high soft tissue contrast of endoanal MRI, it is easier to understand the complexity of the sphincters. The

exact position of each MR slice is known. To identify a particular anatomical structure it is possible to go back and forth within a series of slices (Hussain et al. 1995). The previous workers (Milligan & Morgan, 1934; Goligher et al. 1955; Oh & Kark, 1972; Shafik, 1975; Ayoub, 1979) lacked this facility during anatomical studies of the anal sphincter complex. This may also have played an important role in the development of many misconceptions about the sphincter anatomy existing in the literature (Dalley, 1987). Despite using an angle of reference in the current study, errors during sectioning were unavoidable in 2 cadavers.

Knowledge of the exact anatomy of the anal sphincter complex is essential for management of pathology in this area. In this respect, the findings of the current study can be of great clinical importance. For instance, in patients with anal fistulae, endoanal MRI could provide a road-map for surgical procedures. This could help in reducing the recurrence rate of perianal fistulae and the occurrence of postoperative faecal incontinence. Due to the direct visualisation of the external anal sphincter by endoanal MRI, this modality could also be valuable in patients with faecal incontinence. Currently, endoanal sonography is the modality of choice in patients with perianal fistulae and faecal incontinence (Choen et al. 1991; Sultan et al. 1993b). To determine the value of endoanal MRI in both groups of patients, comparative studies will be performed in our hospital.

ACKNOWLEDGEMENTS

We thank Mrs J. J. M. van Loon-van Luijt for preparation of the histological sections and T. Rijdsdijk for photographic assistance. This paper was presented at the Röntgen Centenary Congress, Birmingham, UK, 1995.

REFERENCES

- AYOUB SF (1979) Anatomy of the external anal sphincter in man. *Acta Anatomica* **105**, 25–36.
- CHOEN S, BURNETT S, BARTRAM CI, NICHOLLS RJ (1991) Comparison between anal endosonography and digital examination in the evaluation of anal fistulae. *British Journal of Surgery* **78**, 445–447.
- DALLEY AF II (1987) The riddle of the sphincters. The morphology of the anorectal mechanism reviewed. *American Surgeon* **53**, 298–306.
- GOLIGHER JC, LEACOCK AG, BROSSY JJ (1955) The surgical anatomy of the anal canal. *British Journal of Surgery* **43**, 51–61.
- HUSSAIN SM, STOKER J, KUIPER JW, SCHOUTEN WR, DEN HOLLANDER JC, LAMÉRIS JS (1994) MR imaging of anal sphincter complex with an endoanal coil: normal anatomy and pathology. *Radiology* **193(P)**, 445.

- HUSSAIN SM, STOKER J, LAMÉRIS JS (1995) Anal sphincter complex: endoanal MR imaging of normal anatomy. *Radiology* **197**, 671–677.
- LAW PJ, BARTRAM CI (1989) Anal endosonography: technique and normal anatomy. *Gastrointestinal Radiology* **14**, 349–353.
- MILLIGAN ETC, MORGAN CN (1934) Surgical anatomy of the anal canal. *Lancet* **ii**, 1150–1156.
- OH C, KARK AE (1972) Anatomy of the external anal sphincter. *British Journal of Surgery* **59**, 717–723.
- SHAFIK A (1975) A new concept of the anatomy of the anal sphincter mechanism and the physiology of defecation. The external anal sphincter: a triple-loop system. *Investigative Urology* **12**, 412–419.
- SULTAN AH, NICHOLLS RJ, KAMM MA, HUDSON CN, BEYNON J, BARTRAM CI (1993a) Anal endosonography and correlation with in vitro and in vivo anatomy. *British Journal of Surgery* **80**, 508–511.
- SULTAN AH, KAMM MA, HUDSON CN, THOMAS JM, BARTRAM CI (1993b) Anal-sphincter disruption during vaginal delivery. *New England Journal of Medicine* **329**, 1905–1916.