

Mystery of the missing epidural tip! Was it really missing?

Dear Editor,

A broken epidural catheter is a rare complication that is known to occur in 0.002% of cases of epidural catheter insertion.^[1]

An elderly female underwent surgery for fracture neck of femur under combined spinal epidural technique in our institute. Under strict aseptic precautions, using a 16-G Touhy needle, epidural space was identified using the LOR technique, and the epidural catheter was advanced and fixed at 11 cm. Patency of the epidural catheter was confirmed, and top-ups were given at regular intervals till 48 h postoperatively, after which the epidural catheter was removed. However, it was noticed that the radiopaque colored tip was missing, creating

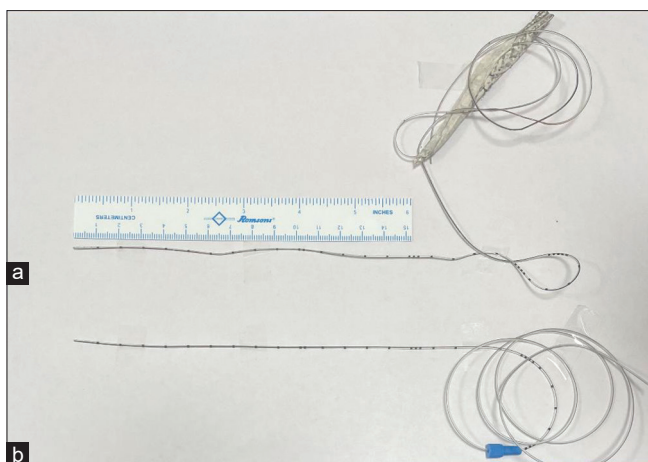


Figure 1: Comparison of the two epidural catheters. (a) Epidural Catheter removed from patient (b) New epidural catheter from same manufacturer

an alarming situation. To ascertain the length of the missing fragment, the length of the tip from various marks on the epidural catheter was measured and found to be adequate. A new packing of the same brand was opened, and both the catheters were compared.^[1] [Figure 1]. It was noticed that the catheters of this brand were manufactured without a colored tip. Obviously, the pre-use check was not done.

Checklists are the most common cognitive aids that enlist the set of actions that need to be performed in a given clinical procedure or scenario to ensure that none of the steps are omitted or forgotten as well as improve the quality of handovers without missing any vital information.^[2]

Lessons can be learned from the aviation industry's "Crew Resource Management" wherein checklists are used at every step and followed. We solved the mystery of the missing epidural catheter, which was in fact, the missing pre-use check and the checklist.

Financial support and sponsorship

Nil.

Conflicts of interest

There are no conflicts of interest.

**Navneh Samagh, Jyoti Sharma, Shashank Paliwal,
Anju Grewal**

Department of Anaesthesiology, AIIMS Bathinda, Punjab, India

Address for correspondence: Dr. Jyoti Sharma,
Department of Anaesthesiology, AIIMS Bathinda, Punjab, India.
E-mail: drjyotisharma1014@gmail.com

References

- Gompels B, Rusby T, Slater N. Fractured epidural catheter with retained fragment in the epidural space- A case study and proposed management algorithm. *BJA Open* 2022;4:100095.
- Grigg E. Smarter clinical checklists: How to minimize checklist fatigue and maximize clinician performance. *Anesth Analg* 2015;121:570-3.

This is an open access journal, and articles are distributed under the terms of the Creative Commons Attribution-NonCommercial-ShareAlike 4.0 License, which allows others to remix, tweak, and build upon the work non-commercially, as long as appropriate credit is given and the new creations are licensed under the identical terms.

| Access this article online | |
|--|---|
| Quick Response Code: | Website: https://journals.lww.com/joacp |
|  | DOI: 10.4103/joacp.joacp_367_23 |

How to cite this article: Samagh N, Sharma J, Paliwal S, Grewal A. Mystery of the missing epidural tip! Was it really missing? *J Anaesthesiol Clin Pharmacol* 2024;40:727-8.

Submitted: 17-Aug-2023

Revised: 06-Oct-2023

Accepted: 06-Oct-2023

Published: 15-Nov-2024

©2024 Journal of Anaesthesiology Clinical Pharmacology | Published by Wolters Kluwer - Medknow