

## Spiral nerve endings and dapple motor end plates in monkey extra-ocular muscles

G. L. RUSKELL AND JOSÉ WILSON

*Department of Optometry and Visual Science, The City University,  
London EC1V 0HB*

(Accepted 17 March 1982)

### INTRODUCTION

The principal receptors of most striated muscles are the muscle spindle and the Golgi tendon organ, but extra-ocular muscles differ, firstly in possessing myotendinous cylinders rather than Golgi tendon organs (Ruskell, 1979; Alvarado-Mallart & Pinçon-Raymond, 1979) and secondly in the absence of muscle spindles from those of some but not all mammals (Cooper, Daniel & Whitteridge, 1955; Maier, DeSantis & Eldred, 1975). Extra-ocular muscles appear to differ further by the presence of large numbers of unencapsulated spiral nerve endings which have not been found in other muscles except for a single instance (FitzGerald & Sachithanandan, 1979). Spiral endings are generally accepted to be part of the sensory apparatus of extra-ocular muscles and it has been suggested that they serve as substitute stretch receptors in animals lacking muscle spindles (Barker, 1974).

The simplest form of spiral ending consists of a myelinated nerve fibre that applies itself tightly about a single muscle fibre for three or more turns in a spiral fashion before terminating. They have been noted in cats and monkeys (Cooper & Fillenz, 1955) and several of the endings drawn by Dogiel (1906) from extra-ocular muscles of a variety of animals are of spiral form, but the spiral ending has been described most fully in human extra-ocular muscles (Daniel, 1946; Sas & Appeltauer, 1963). They are numerous and mostly positioned distal to the motor end plate region in the middle third of each muscle. Division of the nerve fibre before terminating produces other forms, such as multiple spirals, clasp or pincer endings which may be regarded as variants of the simple spiral. Sas & Appeltauer found that some spiral endings were encapsulated and considered them to be an intermediate form of muscle spindle.

Recognition of the potential capacity of spiral endings to record the increased cross sectional area of contracting muscle fibres is the reason for their classification as sensory; no other support for their identification as receptors is available. As part of a review of extra-ocular muscle nerve endings undertaken in this laboratory, spiral endings and other terminals partially or completely embracing single muscle fibres were studied in monkey extra-ocular muscles and it will be shown that, contrary to the accepted view, they have the morphological characteristics of motor not sensory terminals.

### MATERIALS AND METHODS

Twenty one muscles from the control sides of four rhesus (*Macaca mulatta*) and three cynomolgus (*Macaca fascicularis*) monkeys used in another study were prepared for light and electron microscopy. After fixation with 5% or 6.5% glutaraldehyde in cacodylate buffer at pH 7.4 by perfusion through the common carotid

arteries, the lateral rectus, inferior rectus and superior oblique muscles were cut transversely into pieces about 4 mm in length. Three consecutive pieces at and distal to the position of entry of the nerve were retained and cut into several longitudinal strips. After washing, the tissues were immersed in a 1% unbuffered solution of osmium tetroxide for 1 hour and subsequently dehydrated in graded alcohols, cleared in xylene and embedded in Araldite.

Survey sections were cut to select an appropriate region and then transverse or longitudinal serial sections, either full or interrupted, were prepared for light microscopy from one or more pieces of each muscle and stained with toluidine blue. Thin sections were cut at intervals, mounted on copper grids and immersed in a saturated solution of uranyl acetate in 70% ethanol for about 20 minutes and 0.4% lead citrate in 0.1 N sodium hydroxide for 10 minutes.

The lateral rectus muscles from the right orbits of two further cynomolgus monkeys were removed shortly before the animals were fixed by perfusion for another study and fixed by immersion in 10% neutral formalin overnight. The muscles were teased into small groups of fibres and stained for acetylcholinesterase using a copper thiosulphate method (Karnovsky & Roots, 1964). The pieces were then further teased and stained regions were mounted on slides and photographed. Some pieces were exposed to osmium tetroxide vapour for 10 minutes to obtain a light staining of myelin.

Parts of the two lateral rectus muscles used for acetylcholinesterase staining were instead prepared with the ammoniacal silver impregnation method of Glees and Marsland, and sections 30–50  $\mu\text{m}$  thick were cut.

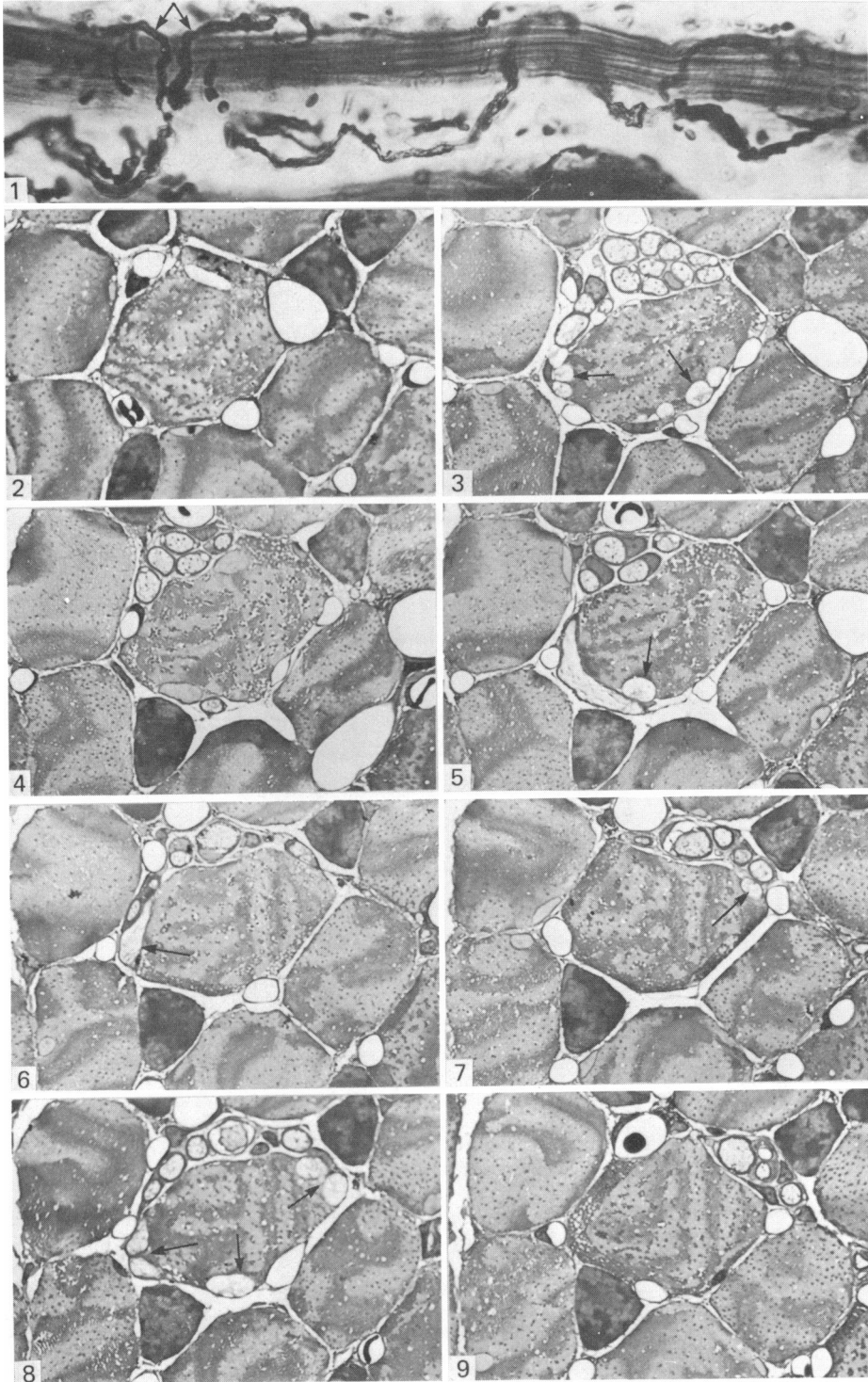
## RESULTS

Many terminating myelinated nerve fibres embraced single muscle fibres in a spiral fashion in the motor end plate region. Spirals were most obvious in thick silver sections because the full nerve ending could be followed with the exception of the neuromuscular junctions (Fig. 1). The spiral form was also evident in thin serial toluidine blue-stained sections and these revealed more details of the relationship between nerve and muscle fibre (Figs. 2–10). The nerve fibres displayed a wide variety of forms including serpentine and pincer-like configurations and spirals of differing complexity and number of turns. Fibres usually branched before or after the spiral commenced. A double spiral, resulting from the two branches of an approaching nerve fibre turning in opposite directions along the fibre, was a common pattern among the longest spirals. For convenience they will all be referred to as spiral endings. Spiralling regularly commenced while the myelinated fibre was still within a perineurial sheath, where fibre division was sometimes observed. The perineurium terminated and the nerve fibre continued to turn, first with a myelin sheath and then without one. The length of the spirals varied from about 100–270  $\mu\text{m}$ ,

---

Fig. 1. A spiral ending. The nerve fibre divides, contacts the muscle fibre and sends coils in both directions (arrows). Cynomolgus; lateral rectus; Marsland-Glees.  $\times 840$ .

Figs. 2–9. Serial transverse sections through a spiral nerve ending: a selection presented in sequence. Figs. 3, 5, 6, 7 and 8 display end plate boutons (arrows). The boutons occur at intervals in groups applied to various aspects of the muscle fibre. Evidence of spiralling is most clearly shown in Fig. 5. Figs. 3 and 8, the first and last to show boutons, were separated by a distance of 140  $\mu\text{m}$ . Cynomolgus; superior oblique; toluidine blue.  $\times 680$ .



averaging 180  $\mu\text{m}$ . Most of the spiral endings were found among the perimeter muscle fibres, especially at the orbital surface of rectus muscles where they were often grouped together. However, scattered spiral endings were also observed in the centre of the muscles.

Indentation of the sarcoplasm by the nerve fibre was present in every spiral ending but it was variable in extent and depth along a single spiral and between spirals. At the commencement of a spiral the ensheathed nerve was often loosely related to the muscle fibre and indentation was more common after the perineurium had been shed. The unmyelinated terminal portion almost invariably indented the sarcoplasm.

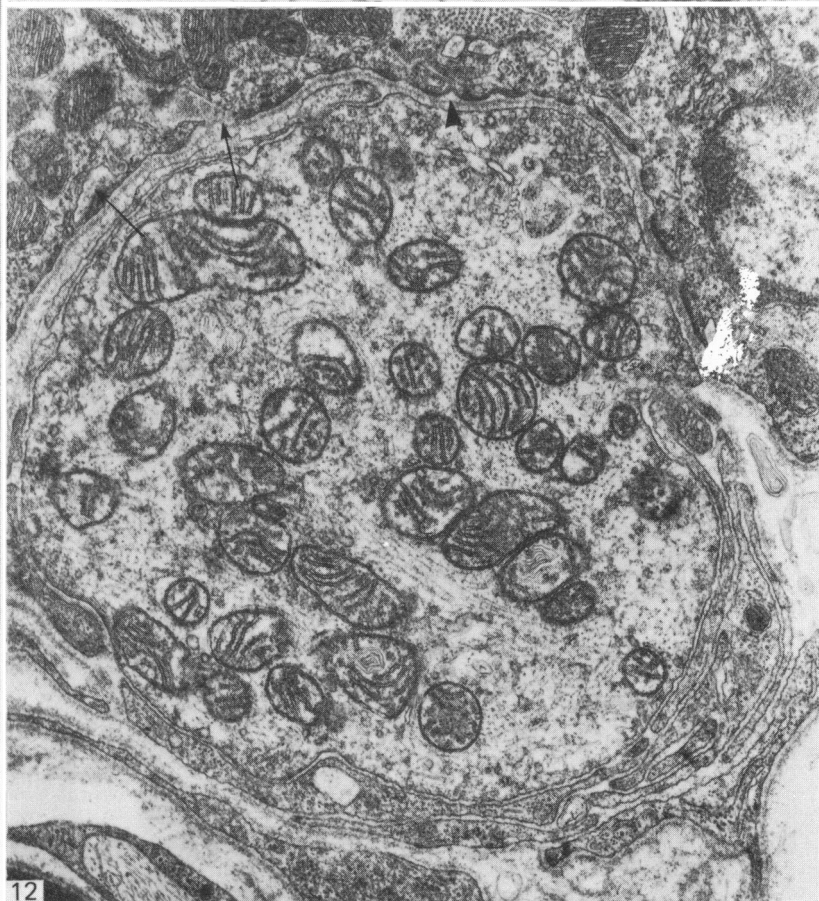
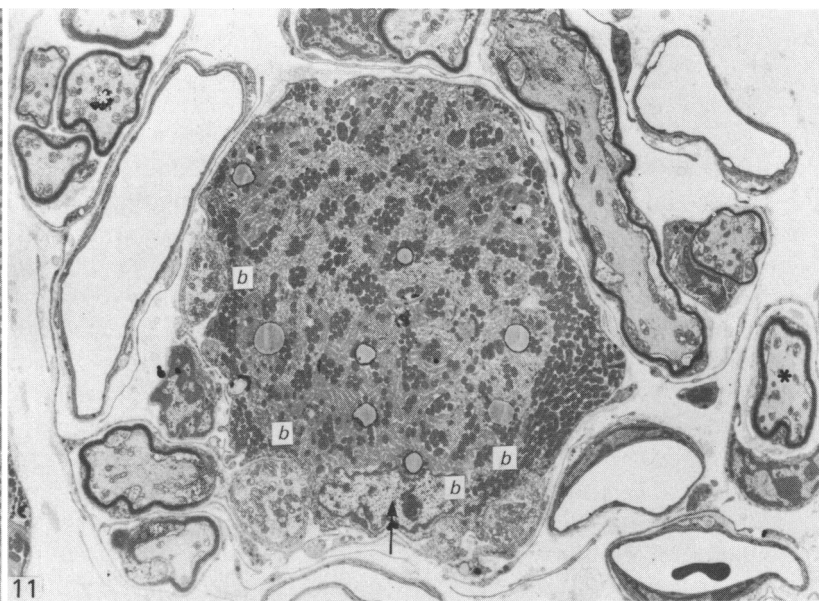
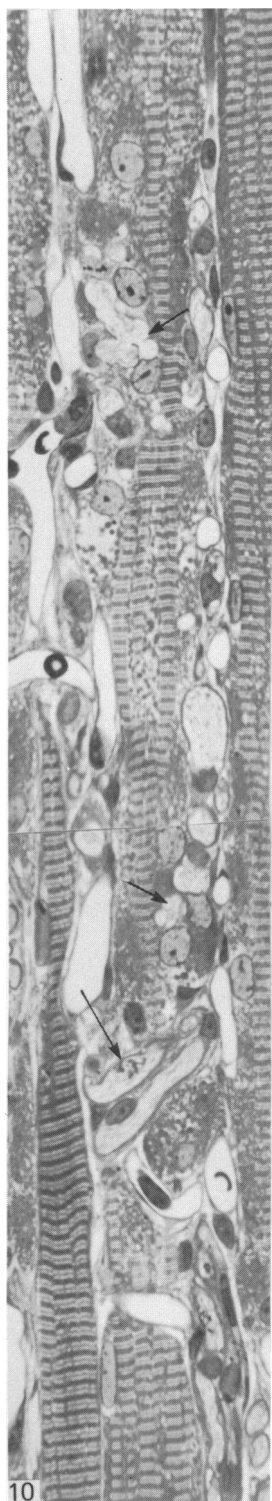
Numerous very short branches passed from the spiralling axon and terminated in a complex motor end plate. Branches stemmed from the unmyelinated terminal portion of the axons and others issued from nodes along the myelinated portion. The end plate was usually spread over a length nearly as long as the spiral and surprisingly it was composed of several separate groups of boutons, numbering from 3–16 in each group, as determined from serial light microscopic sections. The groups of boutons were often quite widely separated and applied to several aspects of the muscle fibre (Figs. 2–10). They rarely failed to indent the muscle fibre (Figs. 11, 12) to an extent more marked than that found proximal to the boutons, and some of them occupied deep invaginations of the sarcoplasm, penetrating between myofibrils. Axons terminated in single bouton expansions or as two, three or four boutons in series, each forming a neuromuscular junction. This feature could be resolved with light microscopy, as shown in Figure 10. In addition to the groups of boutons, pre-terminal neuromuscular junctions occurred along the axon coils well before they terminated in boutons.

Agranular vesicles about 50 nm in diameter were present in large numbers in the terminals, occasionally filling a bouton, but far more commonly they aggregated near the axon membrane at the neuromuscular junction with few vesicles elsewhere (Figs. 12, 13). In all boutons, small tight clusters of vesicles were apposed to the membrane at foci often marked by increased membrane density (Fig. 13). Other organelles included mitochondria, neurofilaments and microtubules. A basal lamina lay within the synaptic cleft at all junctions (Figs. 12, 13) but occasionally the lamina was attenuated, leaving part of the cleft empty. Post-junctional folds were usually very shallow and in a few instances the sarcoplasmic membrane was smooth. Much of the

Fig. 10. Longitudinal section through a muscle fibre with a spiral nerve ending. Two adjacent myelinated nerve fibres, forming part of the spiral and indenting the sarcoplasm, are revealed where the section grazes the surface of the muscle fibre (long arrow). Other myelinated and unmyelinated nerve fibre profiles of the spiral ending are discernible for nearly the full length of the Figure. Two large groups of light-staining boutons (short arrows) nestle among concentrations of muscle fibre nuclei. Numerous capillaries are present. Rhesus; lateral rectus; toluidine blue.  $\times 480$ .

Fig. 11. Transverse section through a muscle fibre showing part of a compound spiral nerve ending. Two groups of nerve fibres, both marked by asterisks, have a perineurium but the others, which are all elements of the spiral ending, do not. Four terminal boutons (*b*) are shown with a nucleus (arrow) underlying three of them. Superficial aggregations of mitochondria are present in the sarcoplasm. Capillary spirals are also represented. Cynomolgus; inferior rectus muscle.  $\times 3100$ .

Fig. 12. Detail of one of the boutons shown in Fig. 11. It contains mitochondria, neurofilaments, microtubules and small agranular vesicles that are mainly aggregated at the presynaptic membrane. The synaptic cleft contains a basal lamina (arrowhead) and the postsynaptic folds are shallow and irregular (arrows).  $\times 21000$ .



sarcoplasm underlying junctions and for some distance on each side was packed with mitochondria and a few other organelles and the incidence of nuclei increased (Figs. 10, 11, 14, 15). Neurofilaments and microtubules were continuous through the pre-terminal neuromuscular junctions and the postsynaptic membrane was smooth. The morphological features of each neuromuscular junction were consistent with those of motor end plates and the junctions compared in every detail with the simple motor end plates observed on neighbouring muscle fibres, except that some of the latter possessed deeper and more regular post-junctional folds.

The muscle fibres were thickened to accommodate the large accumulations of surface mitochondria in the spiral motor end plate regions, and shaped by the indenting nerve fibre coils so that the muscle fibre had a scalloped surface as seen in longitudinal section. Observed in three dimensions, the surface appearance would presumably approximate to the thread of a bolt pin. All fibres receiving spiral nerve endings were of the Fibrillenstruktur type with discrete myofibrils and a well developed sarcoplasmic reticulum.

Nerves were not the only cause of the scalloped appearance of muscle fibres for the tight coils of capillaries mimicked those of the nerves (Figs. 10, 11, 14). The number of capillary profiles seen in section was increased in the region of the spiral end plates, probably due to a greater frequency of undulations and occasional spiralling of the capillary network strands. Capillary indentation of the surface sarcoplasm often extended well beyond the end plate region on each side.

A surprising feature of a number of the muscle fibres in receipt of spiral endings was the shortening of sarcomeres at the end plate. The sarcomeres lost their banding, except for the Z-lines which were broad and irregular (Fig. 15). This was due to the extension of myosin filaments throughout the sarcomeres, which were reduced to about two thirds of the length of the sarcomeres outside the end plate region. The zone of sarcomere shortening varied, sometimes occupying less or more than the full end plate region, but shortening invariably occurred across the fibre width which was increased by up to one third. Sarcomere shortening of this form was rarely found opposite other types of motor end plates or elsewhere, and the incidence of shortening varied between monkeys from very few to nearly half the spiral end plates.

An assessment of the proportion of motor end plates composed of separate bouton clusters with spiral endings was not attempted beyond the observation that they formed a substantial minority.

The distinctiveness of the end plate form of spiral endings was best expressed in the acetylcholinesterase-stained material. The teased specimens revealed various end plate patterns that could be grouped, with some fidelity, into continuous and dis-

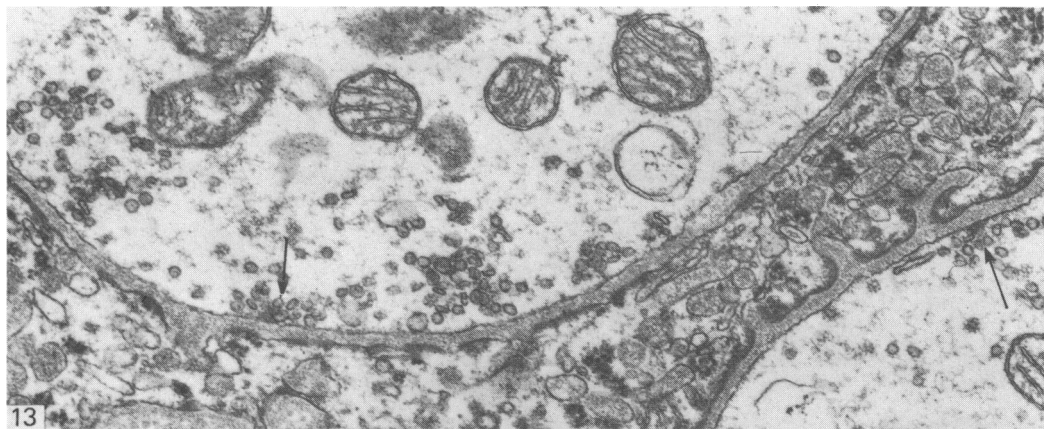
Fig. 13. Boutons of a spiral nerve ending. The synaptic vesicles are mostly aggregated at the presynaptic membrane, in two instances adjacent to areas of increased membrane density (arrows). Rhesus; superior oblique.  $\times 40000$ .

Fig. 14. Grazing section through a muscle fibre, running from bottom left to top right, in receipt of a spiral nerve ending. One of the myelinated fibres of the complex spiral indents the sarcoplasm which is rich in boutons (arrows) and surface mitochondria. Rhesus; superior oblique.  $\times 2700$ .

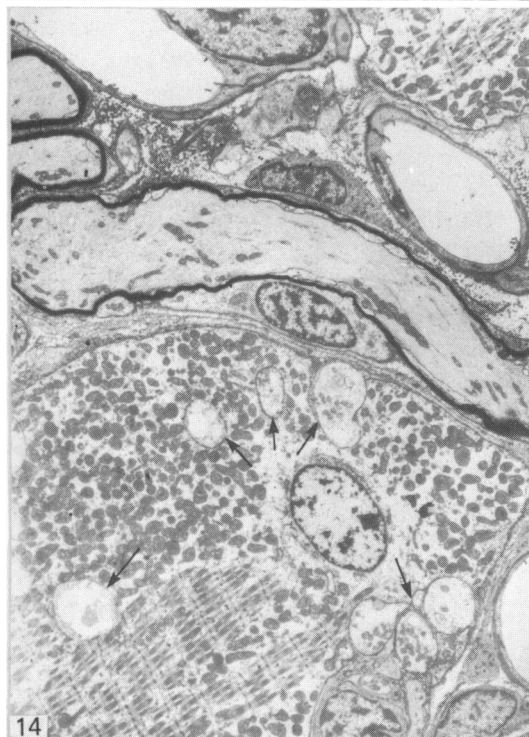
Fig. 15. A myofibril showing no cross banding except for broad, irregular Z-lines. A bouton of the spiral nerve ending is indicated (*b*). Rhesus; superior oblique.  $\times 9100$ .

Fig. 16. Dapple end plate showing at least six well separated stained areas. The spirals of the nerve fibre or fibres (and possibly capillaries) show faintly. Cynomolgus; lateral rectus; acetylcholinesterase stain and osmium tetroxide.  $\times 790$ .

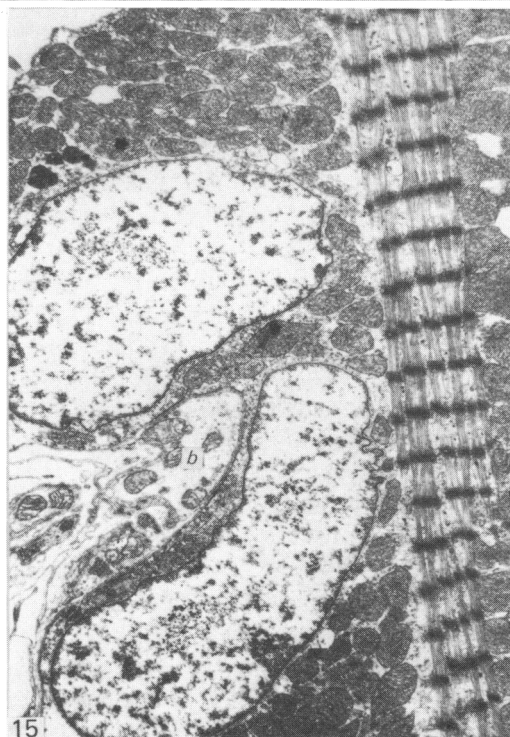




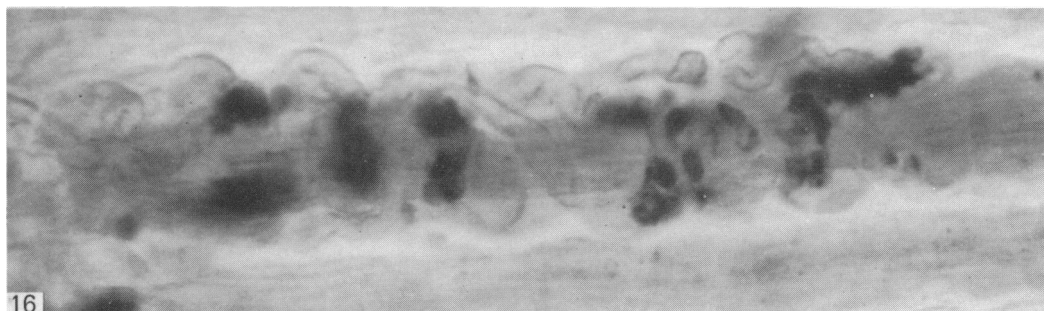
13



14



15



16

continuous end plates. The larger, continuous group consisted of several end plate patterns ranging from button-like staining to irregular serpiginous forms. Occasionally an element of the latter was separated by a short interval from the remainder, but otherwise the two classes were discrete. In the discontinuous spiral group, between four and nine separate, substantial, stained zones were present and extended over a distance of up to 170  $\mu\text{m}$  to give a dappled appearance and suggesting the name *dapple end plate* (Fig. 16). Another type of terminal, forming a subgroup of the discontinuous variety, consisted of one and sometimes two or three small and close spots which were assumed to indicate the so-called grape endings associated with Felderstruktur fibres. They could be distinguished without difficulty from the dapple type because the stained spots were only a fraction of the size and were separated by far greater distances. In some partially teased muscle fibre bundles taken from the perimeter, dapple end plates were found grouped together with other types unrepresented.

Specimens treated with acetylcholinesterase and subsequently stained with osmium tetroxide vapour revealed the spiralling or serpentine form of myelinated nerves surrounding the muscle fibres with dapple end plates in most instances (Fig. 16), whereas complex nerve fibre forms were rarely observed in association with continuous end plates. Nerve fibres could not be traced to all end plates in these preparations.

#### DISCUSSION

The terminals described in this paper are presumably similar to the spiral and clasp endings observed in monkeys by Cooper & Fillenz (1955) but a satisfactory comparison is possible only with human spiral endings for no others are adequately described and none is illustrated. Daniel (1946) described the simple, myelinated spiral ending, with three to eight complete spiral turns around a single small muscle fibre, and terminating in a form resembling an end plate, or in a single fine point sometimes associated with one or more nuclei. Other multiple or complex spiral endings consisted of a single myelinated fibre dividing into two or more fibrils that enclose the muscle fibre ". . . much as the thumb and fingers of a hand encircle a tube in grasping it". No spiral seen in the present study completed more than three or four turns nor did any have the regular appearance that Daniel illustrated for man, but otherwise the spirals are similar. The shorter of the complex spirals present in man correspond well with the clasp endings observed in monkeys. The double spiral form represented in Figure 1 compares with Sas & Appeltauer's (1963) description in man except that it is less elaborate, but encapsulated spiral endings as described by these workers were not seen.

The results leave little doubt that the sites of acetylcholinesterase staining correspond to the multiple bouton groups seen with light and electron microscopy. In both cases the sites were mostly well separated, similarly disposed, of comparable dimensions and spread over approximately the same lengths of muscle fibres. Both, then, are representations of dapple end plates which are in receipt of spiral, serpentine or pincer nerve endings. The results obtained from silver preparations were fully consistent. The singularity of the association of spiral endings with dapple end plates need be questioned only because the separation of nerve endings into spiral and non-spiral categories cannot be done with precision. That a few dapple end plates, as revealed by acetylcholinesterase staining, did not have spiral or equivalent nerve fibres attached is to be expected with the teasing technique used. Similarly the rigour



of teasing explains the absence of nerve fibres from some conventional continuous end plates.

Daniel's (1946) logic of attributing a sensory function to the spiral endings, as expressed in the Introduction, is augmented by the parallel of the well known annulospiral endings of muscle spindles which are generally acknowledged to be sensory. The compelling appearance of the endings seen in thick sections with the light microscope inhibits challenge except to observe, encouraged by the other results of this study, that end plate characteristics of spiral endings are apparent in thick silver preparations.

When they were first seen in semithin sections there was still no reason to doubt that spiral endings were sensory, because the feature of scattered terminals that they revealed, by itself offered no mandate to dismiss the sensory notion, for the sensory endings in the nuclear zones of muscle spindles, if not scattered, are at least extended (Kennedy, Webster & Yoon, 1975). Consequently the motor features of the endings revealed by electron microscopy were unexpected and at first were overlooked (Ruskell, 1977).

Spiral endings contain vesicles and mitochondria in common with known sensory endings of muscle and tendon, but the overall content is dissimilar. Mitochondria, although present, do not make up the bulk of organelles as in mature Golgi tendon organs (Ruskell, 1979) and the cytoplasm is free of the fine flocculent or amorphous material found in muscle spindle sensory endings (Kennedy *et al.* 1975). Against this must be set the recent observation of myotendinous cylinders with putative sensory endings containing a predominance of small agranular vesicles and lacking amorphous material (Ruskell, 1978). The only obvious dissimilarity between boutons (or varicosities) of myotendinous cylinders and spiral endings is the presence in the latter of small aggregates of vesicles adjacent to the membrane which itself is frequently of increased density. This is a feature of motor not sensory terminals. Yet the bouton features supporting a motor identity of spiral endings are arguably marginal and one must look to other elements of the terminals for more substantive evidence. Motor junctions have a synaptic cleft about 60 nm wide containing a basal lamina (see Barker, 1974 for review). These features were present in all spiral endings, although in a few instances short lengths of the synaptic clefts were without a lamina. In contrast, sensory endings have a narrower cleft with occasional attachment plaques and no basal lamina. Regular invagination of the sarcoplasm by boutons, sarcoplasmic modifications and infolding of the cell membrane, all found in spiral endings, are features of motor terminals. It was noted that a few of the terminals lacked post-junctional folds but this is not exceptional among motor nerve endings in extra-ocular muscles (Miller, 1971). Clearly the spiral endings meet most of the morphological criteria of motor end plates and possess none of the exclusive fine structural features of sensory endings.

The histochemical properties of the dapple end plates associated with the spiral endings also support the view that they are motor. The density of staining for acetylcholinesterase was equivalent to that obtained in the conventional motor end plates, indicating a similar concentration of the enzyme. It is well known that sensory terminals elsewhere show a positive acetylcholinesterase reaction, in the cornea for example (Millodot, Lim & Ruskell, 1979), but the optimal pH of the reagent used is higher and the incubation time longer and, under the conditions used in this study, known sensory endings would not have stained.

Abandoning a sensory function for the spiral endings poses the question of why a

motor terminal should have such an elaborate form. The spiral or serpentine form of the nerve terminal is probably no more than a device for conveying boutons to the dapple end plates, so the real question to answer is why a motor end plate should be made up of several separate parts. Reference to other muscles is unhelpful because the dapple end plate appears to be a feature unique to extra-ocular muscles, at least among mammals. The peculiarities of the nerve endings may be of little significance but on the other hand the electrical and mechanical properties of the recipient fibres might be different from the remainder; there is insufficient information available to justify speculation.

The well documented correlation between structural and functional characteristics of mammalian muscle fibres (Burke, 1978) is usually made without reference to variety of end plate form, although varieties have been recognised (Korneliussen & Waerhaug, 1973; Wong & Ip, 1978). Perhaps the most clear cut example of the relationship between muscle fibre type and the morphological features of the nerve terminal is in the so-called en grappe or grape endings of slow, non-twitch, Felderstruktur fibres of extra-ocular muscles (Hess & Pilar, 1963) which also receive exclusive sensory endings (Ruskell, 1978; Alvarado-Mallart & Pinçon-Raymond, 1979). Fibre typing in extra-ocular muscles has been attempted in several laboratories, using either ultrastructural or histochemical criteria (Alvarado & van Horn, 1975; Ringel *et al.* 1978; Vita, Mastaglia & Johnson, 1980) but, apart from the example stated, variety in the form of motor innervation within a single species has not been recognised hitherto. The muscle fibres receiving spiral endings were Fibrillenstruktur (fast, twitch) in type and of similar structure in all muscles in both species of monkey examined. Other end plates stained for acetylcholinesterase were not uniform and in the future it may be possible to relate discrete forms of end plates and Fibrillenstruktur fibres further.

Finally, the unusual form of sarcomeres opposite some dapple motor end plates is worthy of comment. There is little doubt that the shortened sarcomeres and the altered sarcomere banding indicate a local hypercontracted state induced by fixation. The extreme state of contraction had caused collision of myosin filaments with the Z-line which consequently appears irregular and broad. When fresh muscle pieces were immersed in an iodo-acetic solution, which is used for experimental induction of rigor (Huxley & Brown, 1967), and subsequently prepared for microscopy, all muscle fibres displayed shortened sarcomeres, along their full length, similar in appearance to the altered zones of standardly prepared material. Other characteristics of the fibres, such as aggregation of mitochondria, were also similar. Thus, the shortened sarcomeres and associated features of muscle fibres at some dapple motor end plates are rigor-like. The lack of these changes at most end plates is presumably attributable to variation of the physiological state of the endings at the moment of fixation.

#### SUMMARY

The suggestion that spiral nerve endings in extra-ocular muscles are sensory was tested. Spiral, serpentine and pincer-like endings were identified in extra-ocular muscles of rhesus and cynomolgus monkeys in light and electron microscopic preparations. Spiral and other complex nerve endings each terminated in the motor end plate zone as well separated clusters of boutons applied to various aspects of the muscle fibre, in contrast to the single group of boutons of other endings. They displayed a dappled appearance with acetylcholinesterase stain. Dapple endings had

morphological features and staining characteristics consistent with motor end plates. Hence, spiralling of nerve fibre endings is shown to be a device for conveying boutons to dapple motor end plates rather than for monitoring the contraction of muscle fibres.

We thank Professors R. J. Warwick and J. Joseph of Guy's Hospital Medical School for the provision of certain facilities and Mr A. Haque and Miss S. Leach for technical assistance.

## REFERENCES

- ALVARADO, J. A. & VAN HORN, C. (1975). Muscle cell types of the cat inferior oblique. In *Basic Mechanisms of Ocular Motility and Their Clinical Implications* (ed. G. Lennerstrand & P. Bach-y-Rita), pp. 15–45. Oxford: Pergamon.
- ALVARADO-MALLART, R. M. & PINÇON-RAYMOND, M. (1979). The palisade endings of cat extraocular muscles, a light and electron microscopic study. *Tissue and Cell* **11**, 567–584.
- BARKER, D. (1974). The morphology of muscle receptors. In *Handbook of Sensory Physiology*, vol. III/2, pp. 1–190. Berlin: Springer.
- BURKE, R. E. (1978). Motor units-physiological-histochemical profiles, neural connectivity and functional specializations. *American Zoologist* **18**, 127–134.
- COOPER, S., DANIEL, P. M. & WHITTERIDGE, D. (1955). Muscle spindles and other sensory endings in the extrinsic eye muscles; the physiology and anatomy of these receptors and of their connexions with the brain-stem. *Brain* **78**, 564–583.
- COOPER, S. & FILLENZ, M. (1955). Afferent discharges in response to stretch from the extraocular muscles of the cat and monkey and the innervation of these muscles. *Journal of Physiology* **127**, 400–413.
- DANIEL, P. (1946). Spiral nerve endings in the extrinsic eye muscles of man. *Journal of Anatomy* **80**, 189–193.
- DOGIEL, A. S. (1906). Die Endigungen der sensiblen Nerven in den Augenmuskeln und deren Sehnen beim Menschen und den Säugetieren. *Archiv für mikroskopische Anatomie und Entwicklungsmechanik* **68**, 501–526.
- FITZGERALD, M. J. T. & SACHITHANANDAN, S. R. (1979). The structure and source of lingual proprioceptors in the monkey. *Journal of Anatomy* **128**, 523–552.
- HESS, A. & PILAR, G. (1963). Slow fibres in the extraocular muscles in the cat. *Journal of Physiology* **169**, 780–798.
- HUXLEY, H. E. & BROWN, W. (1967). The low-angle X-ray diagram of vertebrate striated muscle and its behaviour during contraction and rigor. *Journal of Molecular Biology* **30**, 383–434.
- KARNOVSKY, M. & ROOTS, L. (1964). A 'direct-coloring' thiocholine method for cholinesterases. *Journal of Histochemistry and Cytochemistry* **12**, 219–221.
- KENNEDY, W. R., WEBSTER, H. DE F. & YOON, K. S. (1975). Human muscle spindles: fine structure of the primary sensory endings. *Journal of Neurocytology* **4**, 697–712.
- KORNELIUSSEN, H. & WAERHAUG, O. (1973). Three morphological types of motor terminals in the rat diaphragm and their possible innervation of different muscle fibre types. *Zeitschrift für Anatomie und Entwicklungsgeschichte* **140**, 73–84.
- MAIER, A., DE SANTIS, M. & EL DRED, E. (1975). The occurrence of muscle spindles in extraocular muscles of various vertebrates. *Journal of Morphology* **143**, 397–408.
- MILLER, J. E. (1971). Recent histologic and electron microscopic findings in extraocular muscles. *Transactions of the American Academy of Ophthalmology and Otolaryngology* **75**, 1175–1185.
- MILLODOT, M., LIM, C. H. & RUSKELL, G. L. (1979). A comparison of corneal sensitivity and nerve density in albino and pigmented rabbits. *Ophthalmic Research* **10**, 307–311.
- RINGEL, S. P., ENGEL, W. K., BENDER, A. N., PETERS, N. D. & YEE, R. D. (1978). Histochemistry and acetylcholine receptor distribution in normal and denervated monkey extraocular muscle. *Neurology* **28**, 55–63.
- RUSKELL, G. L. (1977). New and neglected nerve terminals in extrinsic eye muscles. *American Journal of Optometry and Physiological Optics* **54**, 524–527.
- RUSKELL, G. L. (1978). The fine structure of innervated myotendinous cylinders in extraocular muscles of rhesus monkeys. *Journal of Neurocytology* **7**, 693–708.
- RUSKELL, G. L. (1979). The incidence and variety of Golgi tendon organs in extraocular muscles of the rhesus monkey. *Journal of Neurocytology* **8**, 639–653.
- SAS, J. & APPELTAUER, C. (1963). Atypical muscle spindles in the extrinsic eye muscles of man. *Acta anatomica* **55**, 311–322.
- VITA, G. F., MASTAGLIA, F. L. & JOHNSON, M. A. (1980). A histochemical study of fibre types in rat extraocular muscles. *Neuropathology and Applied Neurobiology* **6**, 449–464.
- WONG, Y. C. & IP, M. C. (1978). Structural differences of pale and strongly stained motor end-plates of the rat diaphragm. *American Journal of Anatomy* **152**, 529–538.