

Melissa Orzechowski Xavier: Drafting and editing of the manuscript.

Rossana Patricia Basso: Collection, analysis and interpretation of data; methodology.

Karine Ortiz Sanchotene: Collection, analysis and interpretation of data.

Fabiana Fedatto Bernardon: Methodology.







Vanice Rodrigues Poester: Drafting and editing of the manuscript; critical review of the manuscript.

Conflicts of interest

None declared.

References

- Poester VR, Mattei AS, Madrid IM, Pereira JTB, Klafke GB, Sanchotene KO, et al. Sporotrichosis in Southern Brazil, towards an epidemic? *Zoonoses Public Health*. 2018;65: 815–21.
- Orofino-Costa R, Freitas DFS, Bernardes-Engemann AR, Rodrigues AM, Talhari C, Ferraz CE, et al. Human sporotrichosis: recommendations from the Brazilian Society of Dermatology for the clinical, diagnostic and therapeutic management. *An Bras Dermatol*. 2022;97:757–77.
- Crestani L, Souza BCE, Kakizaki P, Valente NYS. Therapeutic failure with itraconazole in sporotrichosis due to bariatric surgery. *An Bras Dermatol*. 2020;95:241–3.
- Poester VR, Stevens DA, Basso RP, Munhoz LS, Zanchi M, Benelli JL, et al. CATastrophe: response to the challenges of zoonotic sporotrichosis in southern Brazil. *Mycoses*. 2022;65:30–4.
- Xavier MO, Bittencourt LR, Silva CM, Vieira RS, Pereira HC. Atypical presentation of sporotrichosis: report of three cases. *Rev Soc Bras Med Trop*. 2013;46:116–8.
- Poester VR, Xavier MO, Munhoz LS, Basso RP, Zancopé-Oliveira RM, Freitas DFS, et al. *Sporothrix brasiliensis* causing atypical sporotrichosis in Brazil: a systematic review. *J Fungi (Basel)*. 2024;10:287.
- Padwal R, Brocks D, Sharma AM. A systematic review of drug absorption following bariatric surgery and its theoretical implications. *Obes Rev*. 2010;11:41–50.
- Sardana K, Khurana A, Gupta A. Parameters that determine dissolution and efficacy of itraconazole and its relevance to recalcitrant dermatophytoses. *Expert Rev Clin Pharmacol*. 2019;12:443–52.
- Gómez-López A. Antifungal therapeutic drug monitoring: focus on drugs without a clear recommendation. *Clin Microbiol Infect*. 2020;26:1481–7.

Maria Eduarda Resende Melo  ^{a,*},
Melissa Orzechowski Xavier  ^{a,b},
Rossana Patricia Basso  ^{a,c},
Karine Ortiz Sanchotene  ^{a,b,c},
Fabiana Fedatto Bernardon  ^{a,c},
Vanice Rodrigues Poester  ^{a,b}

^a *Mycology Laboratory, Faculty of Medicine, Universidade Federal do Rio Grande, Rio Grande, RS, Brazil*

^b *Postgraduate Program in Health Sciences, Faculty of Medicine, Universidade Federal do Rio Grande, Rio Grande, RS, Brazil*

^c *Hospital Universitário Dr. Miguel Riet Corrêa Jr., Universidade Federal do Rio Grande, Empresa Brasileira de Serviços Hospitalares, Rio Grande, RS, Brazil*

* Corresponding author.

E-mail: rmeloduda@gmail.com (M.E. Melo),
vanicerp@gmail.com (V.R. Poester).

Received 6 June 2024; accepted 27 July 2024

Available online 9 November 2024

<https://doi.org/10.1016/j.abd.2024.07.005>

0365-0596/ © 2024 Sociedade Brasileira de Dermatologia.

Published by Elsevier España, S.L.U. This is an open access article under the CC BY license (<http://creativecommons.org/licenses/by/4.0/>).

Cutaneous amoebiasis: a dermatological rarity[☆]



Dear Editor,

Cutaneous amoebiasis (CA) is a rare infectious disease caused by *Entamoeba histolytica*, a protozoan present worldwide, with higher frequency in patients from the intertropical region.¹ CA occurs as a primary event when the protozoan is inoculated directly into the skin (surgical procedures, via catheter), and secondary when associated with digestive tract infection through hematogenous dissemination, or by contiguity, mainly in the perianal/vulvar region, in the skin around the drainage of a liver abscess and around colostomies.^{1,2} Secondary events are the most frequent, and cutaneous involvement without intestinal contiguity is rare.²

The present case describes a 47-year-old female patient with a history of chronic kidney disease requiring during an acute episode, referred to the Dermatology department with nodular lesions and abscesses, presenting purulent secretion drainage, which appeared primarily at the site of a Shilley catheter implantation in the right subclavian vein four months before. The lesions spread to the abdomen, anterior and posterior thorax, and were painful to palpation. The patient denied systemic symptoms such as fever, unintentional weight loss, and night sweats. Empirical treatment with antimicrobials (ciprofloxacin and cephalexin) was instituted, without improvement of the condition.

On physical examination, several nodules and subcutaneous tumors measuring up to six centimeters in their largest axis were observed, covered by slightly desquamative erythematous-violaceous skin with an ulcerated center, some of which showed spontaneous drainage of purulent secretion (Fig. 1).

Fine-needle aspiration biopsy guided by dermatological ultrasound was performed on a lesion in the posterior thorax (the largest lesion). The collected material was

[☆] Study conducted at the Clinic of Dermatology, Santa Casa de São Paulo Hospital, São Paulo, SP, Brazil.

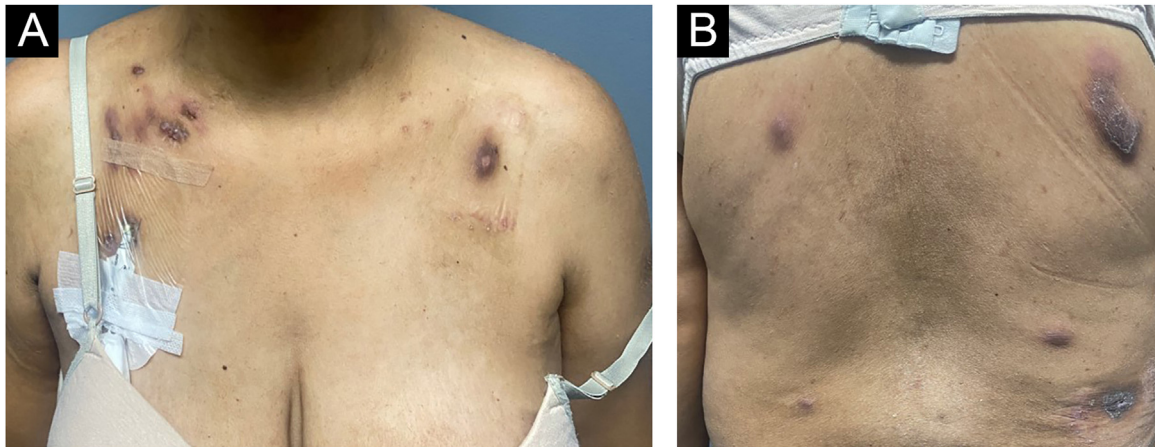


Fig. 1 Clinical appearance of patient with cutaneous amebiasis at the first dermatological consultation: nodular lesions and tumors on the abdomen, anterior and posterior thorax covered by slightly desquamative erythematous-violaceous skin; some lesions showed spontaneous drainage of purulent secretion.

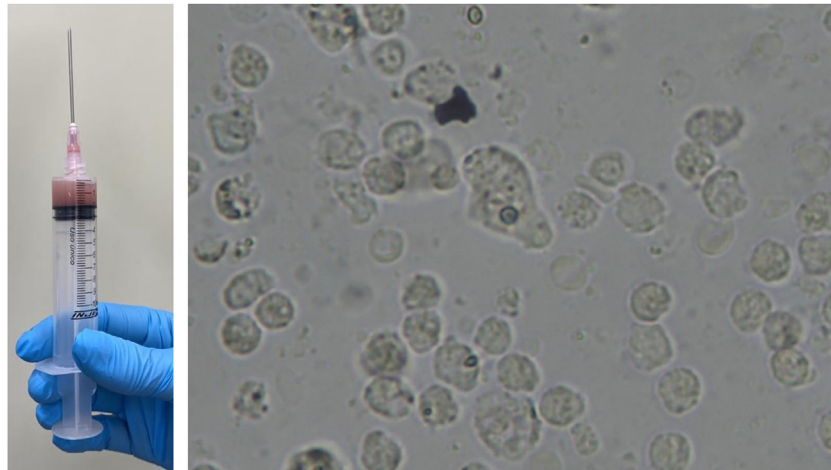


Fig. 2 Direct examination of secretion collected by ultrasound-guided puncture (A) showing the parasite *Entamoeba histolytica* in the form of cysts and, in the center of the image (B), trophozoites.

sent to the microbiology laboratory for culture of aerobic, anaerobic and micro bacteria, which did not show growth of bacterial colonies, and to the parasitology laboratory, where direct examination showed structures compatible with cysts and trophozoites of *Entamoeba histolytica* (Fig. 2). A skin biopsy was also performed, and histopathology showed a histiocytic reaction surrounding abscesses in the superficial and deep dermis, with trophozoites of *Entamoeba histolytica* identified on high power microscopy (Fig. 3).

Additional tests were performed to investigate involvement in other organs by the parasites. The parasitological stool examination was negative in three samples for helminths and protozoa, and computed tomography scans of the abdomen and pelvis did not show the presence of a liver or intestinal abscess.

Laboratory tests performed before and after treatment did not show any changes in liver enzymes, either canalicular or transaminases. The patient had normo-

cytic and normochromic anemia related to her underlying disease.

Oral treatment with metronidazole 250 mg every eight hours for 20 days combined with ivermectin 12 mg, in a single dose, was performed. The patient was reevaluated 30 days after the end of metronidazole therapy, showing significant improvement in the lesions, with regression of the nodules and subcutaneous tumors, absence of erythema, and only residual hyperchromia (Fig. 4).

Amebiasis is a public health problem worldwide, particularly in developing countries. The first reports were probably made by Hippocrates, who discussed dysentery associated with inflammation of the liver.³ However, cutaneous involvement is extremely rare. Review studies that assess decades of care and scientific publications show modest numbers of at most 26 cases in children and adults.³⁻⁵

Although the cutaneous lesions can occur anywhere in the body, anogenital ulcers are the main manifestation, and the location has been reported in both children and adults.^{3,4} The trophozoites are continually shed and the

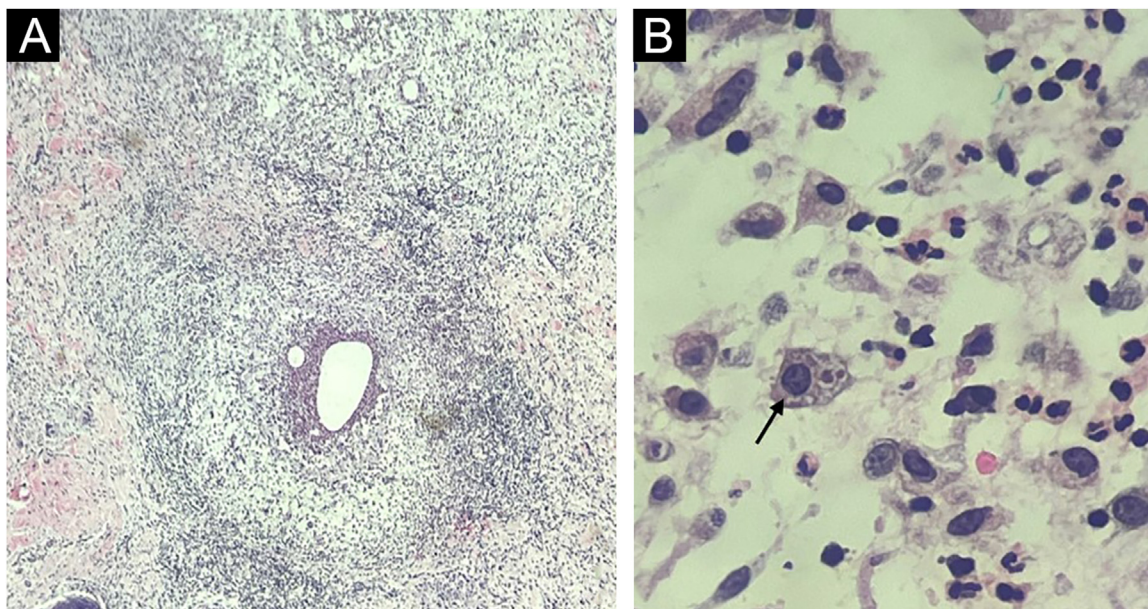


Fig. 3 Histopathology. (A) Skin section showing an histiocytic reaction surrounding abscesses in the superficial and deep dermis (Hematoxylin & eosin, $\times 40$). (B) Evidence of *Entamoeba histolytica* trophozoites with similar morphology as on direct examination (Hematoxylin & eosin, $\times 1000$ under immersion oil).

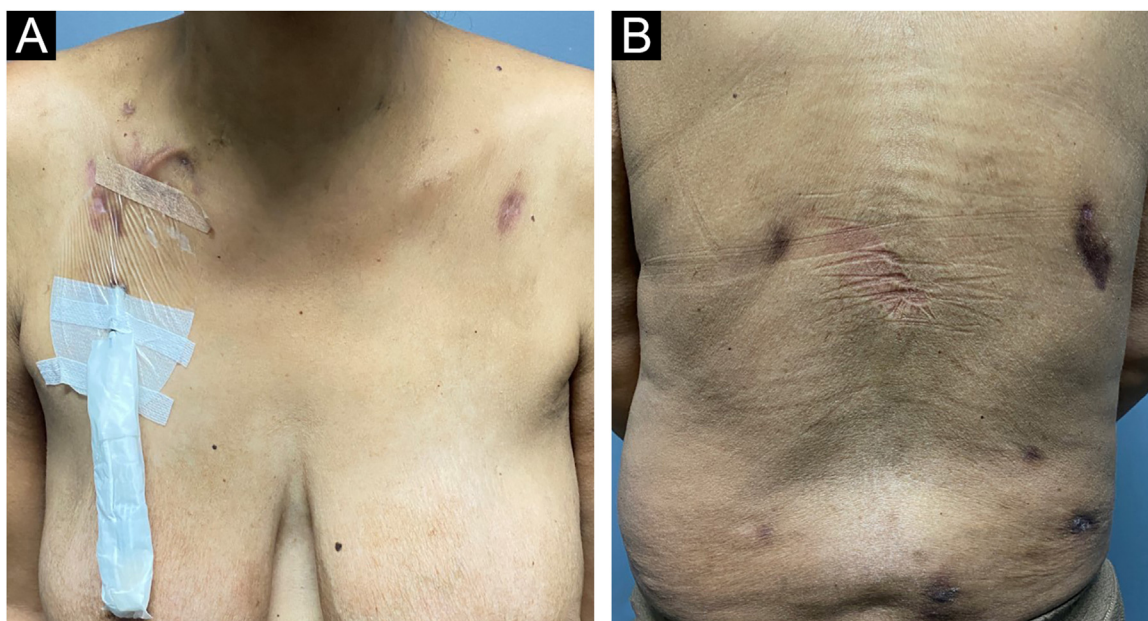


Fig. 4 Clinical appearance of the patient with cutaneous amebiasis after treatment with metronidazole and ivermectin, showing only residual lesions.

surrounding skin undergoes repeated trauma, which is the main mechanism of infection: the amoebae escape from the intestine to the adjacent skin.² Transmission can also occur through contact with contaminated fomites, as well as through sexual intercourse. Hematogenous dissemination occurs when the trophozoites carried by the bloodstream reach the liver – or rarely other organs such as the lungs – and migrate to the skin in a secondary invasion movement.³ In the present case, the association with the placement of a Shiley catheter was already evident in the anamnesis, and

the absence of evidence of amoebiasis in the complementary exams reinforces this pathogenesis. Subsequent hematogenous dissemination occurred, demonstrated by the presence of disseminated lesions, not only at the site of catheter implantation.

Diagnosis can be easily confirmed both by direct examination of lesion secretion (smear in ulcers, puncture of nodules/abscesses), and by histopathology which can demonstrate *E. histolytica* trophozoites on routine staining (Hematoxylin & eosin).^{3,6} Treatment is carried out with

metronidazole in most cases, and other medications such as chloroquine, tinidazole, and emetine may be used, or surgical excision of lesions may be performed.^{2,3} Without a correct diagnosis and immediate treatment, it can result in serious morbidity and even death.⁴ The present patient was treated with metronidazole and ivermectin, and the catheter was also replaced, which did not show any parasites in laboratory tests. The patient showed a good therapeutic response and is being followed at the dermatology outpatient clinic.

Financial support

None declared.

Authors' contributions

John Verrinder Veasey: Design and planning of the study; collection of data, or analysis and interpretation of data; drafting and editing of the manuscript or critical review of important intellectual content; collection, analysis, and interpretation of data; intellectual participation in the propaedeutic and/or therapeutic conduct of the studied cases; critical review of the literature; approval of the final version of the manuscript.

Helena Pladevall Moreira: Collection of data, or analysis and interpretation of data; drafting and editing of the manuscript or critical review of important intellectual content; collection, analysis and interpretation of data; intellectual participation in the propaedeutic and/or therapeutic conduct of the studied cases; critical review of the literature; approval of the final version of the manuscript.

Mariana de Figueiredo Silva Hafner: Intellectual participation in the propaedeutic and/or therapeutic conduct of the studied cases.





Rute Facchini Lellis: Collection of data, or analysis and interpretation of data; collection, analysis and interpretation of data; critical review of the literature; approval of the final version of the manuscript.

Conflicts of interest

None declared.

References

1. Eichelmann K, Tomecki KJ, Martínez JD. Tropical dermatology: cutaneous larva migrans, gnathostomiasis, cutaneous amebiasis and trombiculiasis. *Semin Cutan Med Surg.* 2014;33:133–5, <http://dx.doi.org/10.12788/j.sder.0109>.
2. Parshad S, Grover PS, Sharma A, Verma DK, Sharma A. Primary cutaneous amoebiasis: case report with review of the literature. *Int J Dermatol.* 2002;41:676–80, <http://dx.doi.org/10.1046/j.1365-4362.2002.01569.x>.
3. Fernández-Díez J, Magaña M, Magaña ML. Cutaneous amebiasis: 50 years of experience. *Cutis.* 2012;90:310–4.
4. Kenner BM, Rosen T. Cutaneous amebiasis in a child and review of the literature. *Pediatr Dermatol.* 2006;23:231–4, <http://dx.doi.org/10.1111/j.1525-1470.2006.00223.x>.
5. Magaña ML, Fernández-Díez J, Magaña M. Cutaneous amebiasis in pediatrics. *Arch Dermatol.* 2008;144:1369–72, <http://dx.doi.org/10.1001/archderm.144.10.1369>.
6. Magaña M, Magaña ML, Alcántara A, Pérez-Martín MA. Histopathology of cutaneous amebiasis. *Am J Dermatopathol.* 2004;26:280–4, <http://dx.doi.org/10.1097/00000372-200408000-00003>.

John Verrinder Veasey  ^{a,b,*},
Helena Pladevall Moreira  ^a,
Mariana de Figueiredo Silva Hafner  ^a,
Rute Facchini Lellis  ^{a,c}

^a *Clinic of Dermatology, Santa Casa de São Paulo Hospital, São Paulo, SP, Brazil*

^b *Discipline of Dermatology, Santa Casa de São Paulo School of Medical Sciences, São Paulo, SP, Brazil*

^c *Laboratory of Pathology, Santa Casa de São Paulo Hospital, São Paulo, SP, Brazil*

* Corresponding author.

E-mail: johnvveasey@gmail.com (J.V. Veasey).

Received 8 February 2024; accepted 1 April 2024

Available online 26 November 2024

<https://doi.org/10.1016/j.abd.2024.04.008>

0365-0596/ © 2024 Sociedade Brasileira de Dermatologia.

Published by Elsevier España, S.L.U. This is an open access article under the CC BY license (<http://creativecommons.org/licenses/by/4.0/>).