


# The skin mucosal barrier of lumpfish (*Cyclopterus lumpus* L.) is weakened by exposure to potential aquaculture production-related stressors

Elisabeth Ytteborg  | Carlo C. Lazado | Chris Noble | Roy Inge Hansen | Lill-Heidi Johansen

Division of Aquaculture, Nofima, Tromsø, Norway

## Correspondence

Elisabeth Ytteborg, Division of Aquaculture, Nofima, Tromsø, Norway.

Email: [elisabeth.ytteborg@nofima.no](mailto:elisabeth.ytteborg@nofima.no)

## Funding information

Fiskeri - og havbruksnæringens forskningsfond,

Grant/Award Number: 901472; Norges

Forskningsråd, Grant/Award Number: 194050

## Abstract

Various cleaner fish species, such as the lumpfish (*Cyclopterus lumpus* L.), are used in the sea cage production of Atlantic salmon (*Salmo salar* L.) as a control measure against the ectoparasitic salmon louse (*Lepeophtheirus salmonis*). Nonetheless, during severe lice infestation, alternative treatments are required to control parasitic burden. The aim of this study was to gain insight into how lumpfish skin responds to different chemicals used to treat parasites. The authors collected skin from lumpfish from both research facilities (tank-reared fish) and commercial production (cage-reared fish) and used operational welfare indicators, *in vitro* models, histology and transcriptomics to study how the skin responded to two anti-parasitic oxidative chemicals, hydrogen peroxide (H<sub>2</sub>O<sub>2</sub>) and peracetic acid. Lumpfish sampled from the farm were classified as clinically healthy or weak based on their morbidity status, and fish from each category were used to gain insight into how the therapeutics affect the skin barrier. Differences between healthy and weakened (moribund) fish, and between treated fish from each of the two groups, were observed. Histological examination showed an overall reduced skin quality in fish characterized as moribund, including different grades of exposed bony plates. *In vitro* oxidant-treated lumpfish skin had reduced the migration capacity of keratocytes, a weakened epidermal barrier, and altered gene transcription, changes that are known predisposing factors to secondary infections. Skin from non-treated, healthy fish sampled from commercial farms exhibited similar features and attributes to oxidant-exposed tank-reared fish from a research facility, suggesting that apparently healthy cage-held lumpfish exhibited stress responses in the epidermal barrier. The results of the study outline the risks and consequences lumpfish can face if accidentally subjected to potential anti-parasitic oxidant treatments aimed at Atlantic salmon. It also strengthens the evidence behind the requirement that lumpfish should be removed from the cages before being potentially

This is an open access article under the terms of the [Creative Commons Attribution-NonCommercial-NoDerivs](https://creativecommons.org/licenses/by-nc-nd/4.0/) License, which permits use and distribution in any medium, provided the original work is properly cited, the use is non-commercial and no modifications or adaptations are made.

© 2023 The Authors. *Journal of Fish Biology* published by John Wiley & Sons Ltd on behalf of Fisheries Society of the British Isles.

exposed to this type of treatment and outlines the potential risks of differing husbandry practices upon lumpfish health, welfare and resilience.

#### KEYWORDS

hydrogen peroxide, lumpfish, operational welfare indicators, peracetic acid, salmon lice, skin, treatment

## 1 | INTRODUCTION

Infestations of the ectoparasite salmon louse (*Lepeophtheirus salmonis*) can be detrimental to the health and welfare of farmed and wild salmon (Fast, 2014), cause significant economic losses and are a factor impeding the growth of Atlantic salmon (*Salmo salar*) aquaculture (Costello, 2009; Jones & Gettinby, 2013; McVicar, 2004). Because no effective vaccine against sea lice is presently available, the industry relies heavily on the use of non-medicinal treatments or chemical therapeutics when parasitic loads in the farms approach or go beyond thresholds stipulated by national authorities (Helgesen *et al.*, 2015). Sea lice treatments are logistically demanding and expensive. In Norway alone, it is estimated to cost at least €430 million per year (Iversen *et al.*, 2015). They can also have a detrimental impact on the health and welfare of the fish they are treating and lead to increased mortalities (Overton *et al.*, 2019). It has also been documented that the parasites are evolving and developing resistance to chemical therapeutics, thereby dampening the efficacy of these treatments (Jones & Gettinby, 2013; Lees *et al.*, 2008). In addition, extensive release of chemicals after the treatment poses a significant environmental threat (Burridge *et al.*, 2010; Pedersen & Lazado, 2020) and can cause mortality to animals living in the vicinity of the farms, such as shrimps (Akvaplan-Niva, 2019; Bechmann *et al.*, 2019). These threats drive exploration of alternative non-medicinal solutions for sea lice control, and treatments and biological control agents, such as cleaner fish, have been extensively used in commercial production facilities (Overton *et al.*, 2019).

The use of cleaner fish such as lumpfish (*Cyclopterus lumpus*) is an alternative approach to combatting sea lice, reduces the dependence on chemical and mechanical treatments and exerts little risk to the immediate environment (Powell *et al.*, 2017; Treasurer, 2002). The number of cleaner fish used in Norwegian farms increased exponentially in the past decade, from 10 million in 2010 to 51 million in 2020 (Fiskeridirektoratet, 2021). Nonetheless, cleaner fish are only preventive, and a severe lice outbreak still requires treatment, either with chemical therapeutics or with mechanical methods (Erkinharju *et al.*, 2021; Powell *et al.*, 2017). Operational procedures before treatment ideally involve the removal of cleaner fish from the cages, but this is unfortunately not always the case, and cleaner fish are often subjected to the same delousing procedure as salmon (Mattilsynet, 2019). Traditionally overlooked, the welfare of cleaner fish in salmon farms has now been openly discussed, and several reports have indicated that there is a cause for concern on how they are being handled during production (Barrett *et al.*, 2020; Rabadan *et al.*, 2021; Veterinærinstituttet, 2014). At least 40% of the cleaner fish used in Norwegian farms die during production, and this is

attributed mainly to delousing, injury during transport or release of poor-quality fish (Stien *et al.*, 2020). Although the risk of delousing for cleaner fish health and welfare is recognized and acknowledged, there is limited knowledge on the extent of these impacts, particularly at the physiological level of the chemotherapeutics being used during de-licing. The establishment of toolboxes and frameworks for assessing lumpfish health and welfare is currently an ongoing initiative (Geitung *et al.*, 2020; Imsland *et al.*, 2020; Noble *et al.*, 2019; Rabadan *et al.*, 2021; Rey *et al.*, 2021), and insights into the physiological responses of cleaner fish to these treatments will provide scientific robustness to these strategies.

Many of the therapeutics used in aquaculture target ectoparasites on mucosal surfaces, *e.g.*, gills and skin (Lazado, Haddeland, *et al.*, 2020; Pedersen & Lazado, 2020). Although the use of these therapeutics focuses on lowering the parasitic load, few studies have demonstrated their impact on the mucosal surfaces themselves. Mucosal surfaces of fish are highly responsive to environmental changes and can be indicative of not only the physiological status of fish but also environmental quality (Cabillon & Lazado, 2019). For example, fish skin provides protection against external stimuli and has a high capacity for healing and regeneration, and its structural changes provide insights into the quality of the production environment (Sveen *et al.*, 2020). Hydrogen peroxide (H<sub>2</sub>O<sub>2</sub>), one of the most widely used oxidative therapeutics in salmon, can alter mucous production and transcription profile and reduce the regeneration capacity of salmon skin after exposure (Karlsen *et al.*, 2021; Ytteborg *et al.*, 2020). Peracetic acid (PAA), another potent oxidative therapeutic with a broad antimicrobial spectrum, has been shown to be less damaging to the skin than the gills in salmon (Lazado *et al.*, 2021; Lazado, Pedersen, *et al.*, 2020). PAA is currently being explored as a candidate treatment for amoebic gill disease and has shown promise in reducing the parasite load in the gills of infected fish (Furtado *et al.*, 2022; Lazado *et al.*, 2022). In another salmonid, rainbow trout (*Oncorhynchus mykiss*), PAA can reduce mucous cell density on the skin epithelium (Liu *et al.*, 2020). The effect of these therapeutics on lumpfish and specifically their skin health is unknown.

The interactions between cleaner fish and Atlantic salmon in sea cages are poorly documented, and there is currently a mismatch between the existing evidence base and the field data from the industry (Overton *et al.*, 2020). Addressing this gap is pivotal in developing measures to address the challenging welfare-related issues and ethical concerns regarding the use of cleaner fish in the farms. The present study investigated the potential consequences of accidentally exposing lumpfish to oxidative therapeutics relevant to salmon farming. Lumpfish were sourced from both a controlled tank-based research facility and two sampling visits to a commercial salmon farm in Norway.

Farm-sourced fish were further classified as moribund or clinically healthy and were sampled during (a) normal production conditions during autumn and (b) a tenacibaculosis outbreak during spring. The authors focused on the documentation of responses in the skin mucosa and employed histological and molecular approaches to profile the impacts. Similarly, they used an *in vitro* system to study how these therapeutics affect keratocytes, one of the cells important for barrier functionality and resilience of the skin. Key epidermal operational welfare indicators (OWI) were also documented from sampled fish.

## 2 | MATERIALS AND METHODS

### 2.1 | Ethics statement

All fish handling and manipulations in the study adhered to the guidelines and protocols of the European Union Directive 2010/63/EU. An approval from the Norwegian Food Safety Authorities was not needed because all animals were killed with an overdose of anaesthetics before exposure/use.

### 2.2 | Trial 1: oxidant exposure of tank-raised fish from a research facility

The experiment was carried out at the Nofima Centre for Marine Aquaculture, Kraknes near Tromsø, Norway. Juvenile lumpfish with an average weight of  $46.9 \pm 7.1$  g (mean  $\pm$  s.d.) were obtained from the Akvaplan-Niva research facility at Kraknes near Tromsø, Norway. The fish were a mix of 10 families and were offspring from wild-caught broodfish hatched between 3 and 5 November 2019. From start feeding, fish were fed Otohime B1/B2 (PTAqua, Dublin, Ireland) followed by Clean assist 0.8–1.8 (Skretting, Stavanger, Norway). Fish were kept at the Akvaplan-Niva research facility in a flow-through indoor raceway system at a density of  $10 \text{ kg m}^{-3}$ , subjected to water temperatures of  $6.5^\circ\text{C}$ , saltwater conditions, dissolved oxygen saturations of greater than 90% and 24 h light photoperiod. They had previously been vaccinated with Amarine micro 3.1 (Pharmaq, Oslo, Norway).

Skin from teleosts consists of living cells that may be cultured *in vitro*, even after the fish has been dead for several hours (Karlsen *et al.*, 2021; Lazado, Pedersen, *et al.*, 2020; Ytteborg *et al.*, 2020). Lumpfish ( $n = 3$  per treatment) were killed by exposure to an overdose of metacaine (Finquel, Oslo, Norway,  $0.4 \text{ g ml}^{-1}$ ). Hydrogen peroxide ( $\text{H}_2\text{O}_2$ ) (Sigma-Aldrich, Gillingham, UK) and PAA (Divosan Forte, Lilleborg AS, Oslo, Norway) were used for therapeutic exposure studies. Euthanized fish were exposed to either high (high  $\text{H}_2\text{O}_2$ , 10,000 ppm) or low (low  $\text{H}_2\text{O}_2$ , 2000 ppm) concentrations of  $\text{H}_2\text{O}_2$ , to high (high PAA, 10 ppm) and low (low PAA, 2 ppm) concentrations of PAA or to saltwater (Ctrl 40) for 40 min in separate buckets (10 l). In addition, control fish (Ctrl) were sampled immediately after killing the fish. The low concentration of  $\text{H}_2\text{O}_2$  is similar to the dose used by the industry for de-licing in sea cages (Treasurer & Grant, 1997), whereas the high concentration is five times the recommended dose

used. The high concentration was selected after conversation with farmers on what could be the possible highest concentration fish potentially could be exposed to. Samples were collected before and immediately after exposure from  $n = 3$  fish per treatment group. To evaluate the impact of the collection method, skin mucus was collected either by scraping with the use of sterile glass slide or by using FLOQSwab (COPAN Diagnostics, Murrieta, CA, USA) and snap-frozen in dry ice. Skin from the dorsal region ( $1 \times 0.5 \text{ cm}$ ) was dissected and divided into two portions. The first half was fixed in buffered formalin (Cellstore, CellPath, Newtown, UK) and stored at  $4^\circ\text{C}$  until tissue processing (Section 2.4). The other half was suspended in RNA-later (Ambion, Thermo Fisher, Carlsbad, CA USA), allowed to penetrate for 24 h and thereafter stored at  $-20^\circ\text{C}$  until gene expression analysis (Section 2.5). In addition, skin biopsies from control and exposed fish were sampled for *in vitro* studies (Section 2.6).

### 2.3 | Trial 2: samples from a commercial production facility

Lumpfish used in this study were produced at Langstein Fisk AS, Skatval, Norway, and were offspring from wild-caught broodfish from northern Norway (Finnmark) that were hatched on 25 September 2019 and 9 December 2019, respectively. Before transfer they were fed with Otohime A, B1 and B2, followed by Atlantic Gold 0.5–2.0 (PTAqua, Dublin, Ireland). Before seawater (SW) transfer, the fish were subjected to 24 h light and an average water temperature of  $8.2^\circ\text{C}$  and had been vaccinated with Amarine Micro 3-1 (Pharmaq). These lumpfish were transferred to a commercial Atlantic salmon marine cage facility in Tromsø, c.  $70^\circ \text{N}$ , Norway, on 28 June (74,562 fish, mean weight: 40 g) and 31 August 2020 (c. 65,000 fish, mean weight: 55 g). Cages at this site had a circumference of 157 m and a depth of 15 m at the cage wall and were equipped with lice skirts from the time of stocking that were either c. 4.5 or 4.8 m deep. The numbers of lumpfish stocked in each cage were c. 18,400, and this equated to a lumpfish to salmon stocking ratio of c. 10%. Lumpfish were provided with commercial lumpfish hides,  $\times 2$  rows  $\times$  16 m length and 10 m depth per cage (Norse Aqua, Oslo, Norway), constituting  $300 \text{ m}^2$  hides per cage, which were located 3 and 5 m from the cage edge, respectively. They were deployed parallel to the prevailing current direction in the cages. Average water temperatures during stocking were  $8.6$  and  $10.9^\circ\text{C}$  in June and August 2020, respectively.

The health status of the lumpfish was audited at the hatchery, and before cage transfer the fish were screened and found negative for lumpfish flavivirus, *Pseudomonas* sp., *Pasteurella* sp., *Moritella viscosa* and *Tenacibaculum* sp. After cage transfer, health status was routinely followed up by the local Fish Health Service on a monthly basis and in addition when a need arose. Fish were also inspected daily, and mortalities, where possible, were removed on a daily basis. Tenacibaculosis, caused by *Tenacibaculum* sp., was diagnosed on the site for the first time in September 2020 and seemed to be a recurring problem but not in all cages simultaneously. The same diagnosis was also confirmed in March 2021, and the causative agent was confirmed to be *Tenacibaculum finnmarkense* by the Norwegian Veterinary Institute

diagnostics lab (information reported to the authors from the local Fish Health Service). In general, lumpfish mortalities registered on the site seemed to fall into two main categories: wound developments caused by tenacibaculosis and/or handling and mechanical salmon lice treatments (reported from the local Fish Health Service).

Two sampling points were included in this work. The first sampling was carried out on 29 October 2020, 27 days after the salmon in the cage were thermally deloused using thermolicer delousing technology. Water temperature during sampling was 8.4°C. Eleven lumpfish were netted from a single cage on the farm site. Six moribund and five healthy lumpfish were sampled and divided into clinically *healthy* or *weakened* individuals based on their morbidity status (evaluated by a trained personnel). Fish from both groups were killed with an overdose of metacaine (Finquel, 0.4 g ml<sup>-1</sup>), and fish were photographed (left side) using a Canon EOS 6D camera fitted with a Canon EF 17–40 mm f/4L USM lens 40 mm (Canon Inc., Tokyo, Japan). Length and weight were recorded during sampling. Skin was sampled as described in Section 2.2. Moribund fish were generally smaller (78.3 ± 33.0 g) than those fish classified as clinically healthy (146 ± 31.9 g).

The second sampling was carried out on 20 April 2021, during an ongoing tenacibaculosis outbreak on the farm. Twenty lumpfish were netted from another single cage on the farm site. This sampling followed three delousing events using Thermolicer delousing technology on 20 October 2020 and 5 December 2020 and Salmosan (Salmosan Vet, Benchmark Animal Health, Bergen, Norway) bath treatment on 7 February 2021. All lumpfish were treated with Salmosan together with the salmon. Water temperature during sampling was 4.4°C. Ten moribund and 10 other lumpfish were sampled and divided into clinically *healthy* or *weakened* individuals based on their morbidity status (evaluated by a trained personnel). Fish from both groups were killed with an overdose of metacaine (Finquel), and fish were photographed (left side) using a Canon EOS 6D camera fitted with a Canon EF 17–40 mm f/4L USM lens 40 mm (Canon Inc.). Length and weight were recorded during sampling. Moribund fish were again somewhat smaller (270.9 ± 66.6 g, mean ± s.d.) than those fish classified as clinically healthy (297.2 ± 94.0 g, mean ± s.d.). After euthanasia, five moribund and five clinically healthy individuals had their skin sampled as described in Section 2.2 (0 samples,  $n = 5$ ). The remaining moribund and clinically healthy euthanized fish ( $n = 5$  per group) were exposed to a low dose (2000 ppm) of H<sub>2</sub>O<sub>2</sub> for 40 min (hereafter termed the healthy/weak low H<sub>2</sub>O<sub>2</sub> treatment), and the skin was sampled as described in Section 2.2. Skin cell cultures were developed from all groups and treatments as described in Section 2.6. Epidermal and caudal fin conditions were audited as OWIs from the images using the OWI scoring scheme, as outlined in Imsland *et al.* (2020).

## 2.4 | Histology

Skin samples were fixed in buffered 4% formalin ( $n = 3$  per treatment from the controlled tank-based exposure study,  $n = 5/n = 6$  per treatment from the commercial cage sampling events) and were carefully dissected, orientated and placed in a tissue embedding cassette

(Simport, Quebec, Canada). The samples were dehydrated first in 100% alcohol and then in a clearant Xylene bath, using an automated tissue processor (TP1020, Leica Biosystems, Nussloch GmbH, Heidelberg, Germany), before being infiltrated in melted paraffin (60°C, Merck KGaA, Darmstadt, Germany). Paraffin-embedded tissue samples were cut into 5 µm sections using a microtome (Leica RM 2165), mounted on polysin-coated slides (VWR, Avantor, Radnor, PA, USA) and dried overnight at 37°C. The sections were deparaffinized and rehydrated, and staining was performed using an automated special stainer (Autostainer XL Leica Biosystems, Nussloch GmbH). Paraffin sections were stained with Alcian Blue periodic acid Schiff (AB/PAS, pH 2.5, Alcian Blue 8GX, Sigma-Aldrich). The slides were examined using a light microscope slide scanner and evaluated in Aperio Image Scope (Leica Microsystems, Heidelberg, Germany).

## 2.5 | RNA isolation and gene expression analysis

To evaluate the molecular responses in the skin, the authors performed gene expression analysis using a selected panel of genes relevant for mucosal barrier integrity. Total RNA from the skin tissue (mirVana miRNA isolation kit, ThermoFisher Scientific, Winsford, UK) and mucous (miRNeasy serum/plasma advanced kit, Qiagen, Hilden, Germany) samples was isolated using commercially available kits. The total RNA concentration was measured using a NanoDrop 1000 spectrometer (ThermoFisher Scientific), and RNA integrity was further assessed using an Agilent 2100 Bioanalyzer with RNA Nano kits (Agilent Technologies, Winsford, UK). Complementary DNA (cDNA) was prepared using a High-Capacity RNA-to-cDNA kit (Applied Biosystems, Santa Clara, CA, USA) with a 200 ng template RNA in a 10 µl reaction. Real-time quantitative PCR was performed in a QuantStudio 5 Real-Time PCR system (Applied Biosystems). The 10 µl reaction mixture contained 5 µl of PowerUP SYBR Green PCR Master Mix (Applied Biosystems), 0.5 µl of each forward/reverse primer (10 µM) and 4 µl of diluted cDNA. Positive and no-template controls were included in the assay. The following cycling parameters were used: 2 min of pre-incubation at 95°C; amplification with 40 cycles for 1 s at 95°C and 30 s at 60°C; and a melt curve stage of 15 s at 95°C, 1 min at 60°C and 15 s at 95°C. To calculate the amplification efficiency, an eight-step standard curve of two-fold dilution series was prepared from pooled cDNA. Transcript level was expressed as relative expression after normalization with the geometric mean of two reference genes (for tissue: β-actin and 16S ribosomal RNA; for mucus: β-actin and 60S ribosomal protein L13) (Nagasawa *et al.*, 2012). The primers used in the study are presented in Table 1.

## 2.6 | In vitro primary keratocyte cell culture

Lumpfish keratocytes were cultured from whole skin explants and used to investigate the effect of H<sub>2</sub>O<sub>2</sub> and PAA on cell migration. Skin biopsies were cut from the left dorsal side and placed in 12-well tissue culture plates (Falcon Multiwell, Becton Dickinson, Frankfurt,



**TABLE 1** qPCR primers used in the present study

Gene name	Abbreviation	Sequence information
Collagen $\alpha$ -1(I) chain	<i>col1a1</i>	F: CTGAGGTTGCCAAGAAGAACTG R: GTACTCGAACTGGAATCCGTC
Catalase	<i>cat</i>	F: TCTTACCAAGTTTGGTCTCAC R: CATGTTGCTGGGATCGAAGG
Transcription regulator protein BACH1	<i>bach1</i>	F: TCTCAACTCAGGGGAGGATG R: TGCTGGCCCTCTCTTGT
Transcription regulator protein BACH2	<i>bach2</i>	F: AGGAAGCTCGA-TGCATCAT R: CGTCAGCAGCTTCTCTTCT
Cyclic AMP-dependent transcription factor	<i>atf7</i>	F: TCTGGCCCTCTCTTGTGT R: GACTGCCCGGTCCTGTTAT
$\beta$ -Actin	<i>actb</i>	F: ACAGGTCCTTACGGATGTCG R: CTCTCCAGCCTTCCTTCT
16S ribosomal RNA	16S	F: CCGAAGACGATAAGACCCTAAGAC R: CGCTGTTATCCCTAAGGTACCTATG
60S ribosomal protein L13	<i>rpl13</i>	F: CTCGGTCGGTGAGTAGAGC R: TGCCAGTCTTTGTGGAAGTG

Abbreviation: qPCR, quantitative PCR.

Germany), with five biopsies (c. 1 mm<sup>2</sup>) per well and three wells per fish. Each well contained L-15 supplemented with 10% fetal bovine serum (FBS), 25  $\mu$ g of amphotericin B, 10 ml l<sup>-1</sup> of antibiotics and antimycotics and 0.01 M HEPES (N-2-hydroxyethylpiperazine-N'-2-ethanesulfonic acid, Sigma-Aldrich). Plates were incubated at 8°C in a cell incubator without CO<sub>2</sub>. After 1, 2 and 3 days, biopsies were microscopically analysed (Zeiss, AxioVision, Gillingham, Germany). Cultures were compared by the percentage of biopsies with migrating cells (defined as cells moving to the bottom of the well making a confluent cell sheet surrounding the scales) to the total number of biopsies. The morphology of migrating cells was documented.

## 2.7 | Data handling

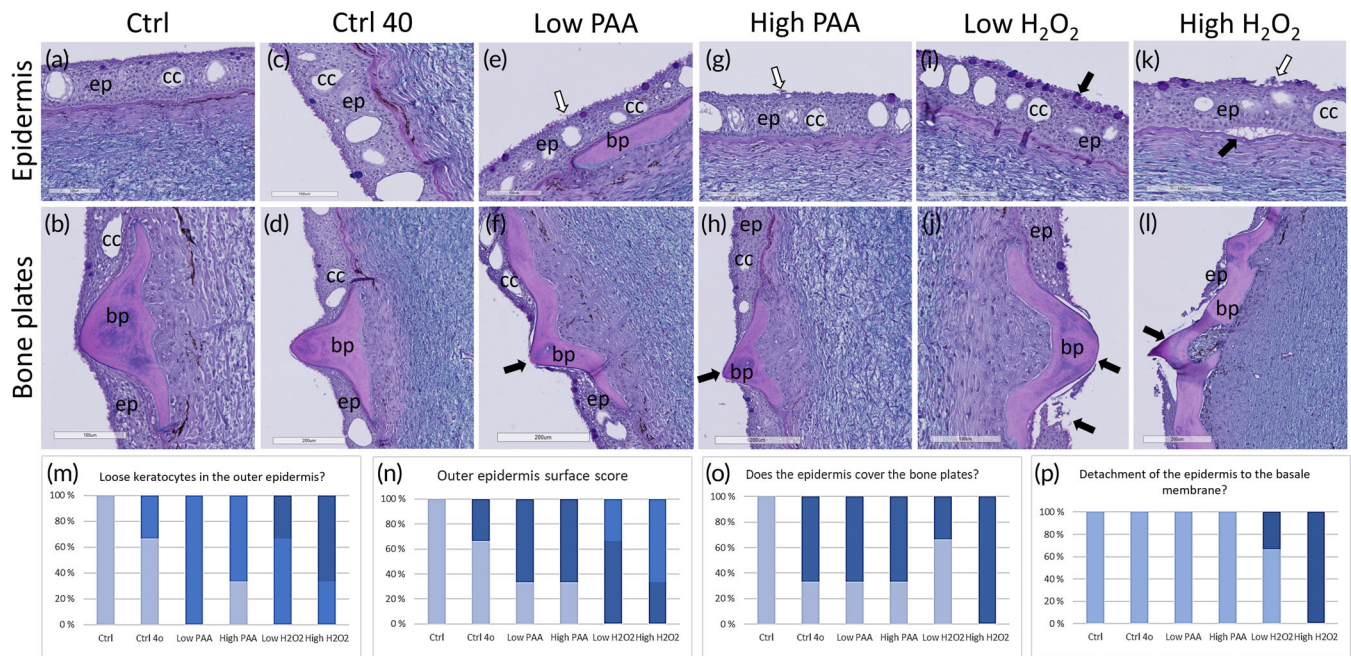
Gene expression data were analysed using either a one-way (for skin samples) or two-way (for mucous samples) ANOVA followed by a pair-wise multiple comparison using the Holm-Sidak method. All data are presented as mean  $\pm$  s.d. When the data set did not fulfil requirements of normality (Shapiro-Wilk) or equality of variance (Brown-Forsythe), the data were transformed to log<sub>10</sub> before performing the ANOVA. Histological statistical measures were calculated using a t-test. Fulton's condition factor (K) of lumpfish in the commercial cage study was calculated using the formula  $K = 100 \times W/L^3$ , where *W* is the wet weight of the fish to the nearest gram and *L* is the total length of the fish to the nearest 0.5 cm. The body mass index (BMI, %) of lumpfish in the commercial cages was calculated using the Lumpfish Welfare Watcher app by de Leaniz *et al.* (2022) using their length-weight regression coefficients for lumpfish stocked in salmon cages. The BMI calculator then classifies its outputs into (a) emaciated (BMI < 75), where fish weight is 25% or more below expected;

(b) underweight (BMI = 75–90), where fish weight is 10%–25% below expected; (c) normal (BMI > 90–110), where fish weight is as expected; and (d) above normal ( $\geq 110$ ), where fish weight is 10% or more than that expected (de Leaniz *et al.*, 2022). The level of significance in all statistical tests was at  $P \leq 0.05$ .

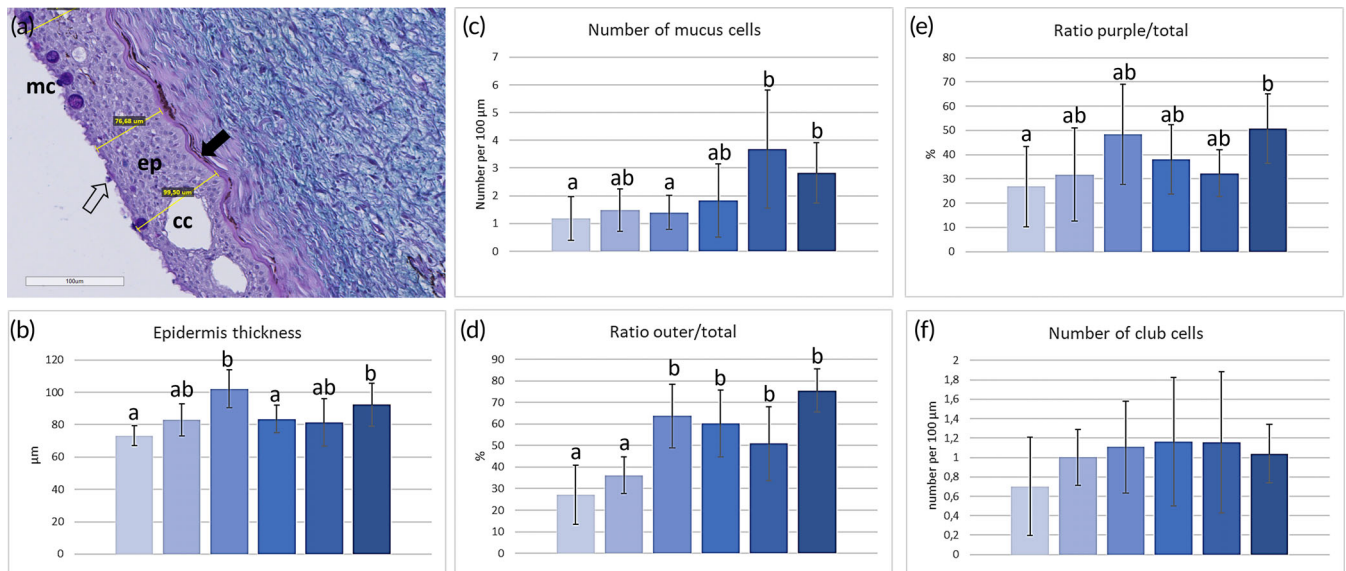
## 3 | RESULTS

### 3.1 | Samples on tank-reared fish from a research facility

Lumpfish skin shares the general skin features of many fish species, including mucous cells, keratocytes and club cells. They lack scales but have bony plates and club cells. Histological examination of control fish (0 sample, Ctrl) showed smooth keratocytes at the outer part of the epidermis and few but evenly distributed mucous cells in the deeper epidermis (Figure 1a,b). Skin sampled from fish that were euthanized and kept for 40 min in SW (Ctrl 40) showed a similar phenotype, with no significant deviations from the control (Figure 1c,d). Nonetheless, one of the three fish exhibited outer epidermal keratocytes that were looser, and there were also breaches in the continuous epidermal barrier covering the bony plates (Figure 1n–p). Treatments with H<sub>2</sub>O<sub>2</sub> or PAA resulted in morphological alterations in the microarchitecture of skin. The epidermal border was rougher, and bony plates lacked epidermis in the groups that were exposed to low and high doses of PAA (Figure 1e–h). Treatment with H<sub>2</sub>O<sub>2</sub> at both concentrations led to more pronounced effects than treatment with PAA (Figure 1i–k). When summarizing the findings (Figure 1n–p), results from the controlled studies on tank-raised fish showed that treatment with oxidative agents increased the number of mucous cells, induced a rougher outer



**FIGURE 1** Histology of skin samples from the controlled tank trial stained with AB/PAS (Alcian Blue periodic acid Schiff) showing changes in the epidermis in (a, b) control and (c, d) control fish 40 min after death and after exposure to (e, f) low PAA (peracetic acid) doses, (g, h) high PAA doses, (i, j) low H<sub>2</sub>O<sub>2</sub> doses and (k, l) high H<sub>2</sub>O<sub>2</sub> doses. The epidermis was more damaged, and bone plates were more exposed in fish going through the different treatments. Score values of skin showed (m) loose keratocytes, (n) reduced outer epidermal roughness, (o) less coverage of the bone plates and (p) detachment of the epidermis from the basal membrane after H<sub>2</sub>O<sub>2</sub> treatment. Scale bar as indicated. Top row: white arrows indicate loose keratocytes, and black arrows indicate mucous cells in the outer part of the epidermis. Mid row: black arrows indicate disrupted keratocyte layer and exposed bone plates. Ep, epidermis; cc, club cell; bp, bone plate. ■, None; ■, Few; ■, Many; ■, Even; ■, 50% rough; ■, 100% rough; ■, Yes; ■, No; ■, Yes; ■, No



**FIGURE 2** (a) Histological measures of skin samples from the controlled tank trial stained with AB/PAS (Alcian Blue periodic acid Schiff), showing the basement membrane (black arrow), mucous cells (white arrow) and epidermis thickness (yellow lines). Results showed that (b) epidermis thickness, (c) number of mucous cells, (d) ratio of mucous cells in the outer part of the epidermis, (e) ratio of purple mucous cells and (f) number of club cells increased with treatments and doses. Significant numbers ( $P \leq 0.05$ ) are indicated with different letters (a, b). Ep, epidermis; cc, club cell. ■, Ctrl; ■, Ctrl 40; ■, Low PAA; ■, High PAA; ■, Low H<sub>2</sub>O<sub>2</sub>; ■, High H<sub>2</sub>O<sub>2</sub>; ■, Ctrl; ■, Ctrl 40; ■, Low PAA; ■, High PAA; ■, Low H<sub>2</sub>O<sub>2</sub>; ■, High H<sub>2</sub>O<sub>2</sub>; ■, Ctrl; ■, Ctrl 40; ■, Low PAA; ■, High PAA; ■, Low H<sub>2</sub>O<sub>2</sub>; ■, High H<sub>2</sub>O<sub>2</sub>; ■, Ctrl; ■, Ctrl 40; ■, Low PAA; ■, High PAA; ■, Low H<sub>2</sub>O<sub>2</sub>; ■, High H<sub>2</sub>O<sub>2</sub>

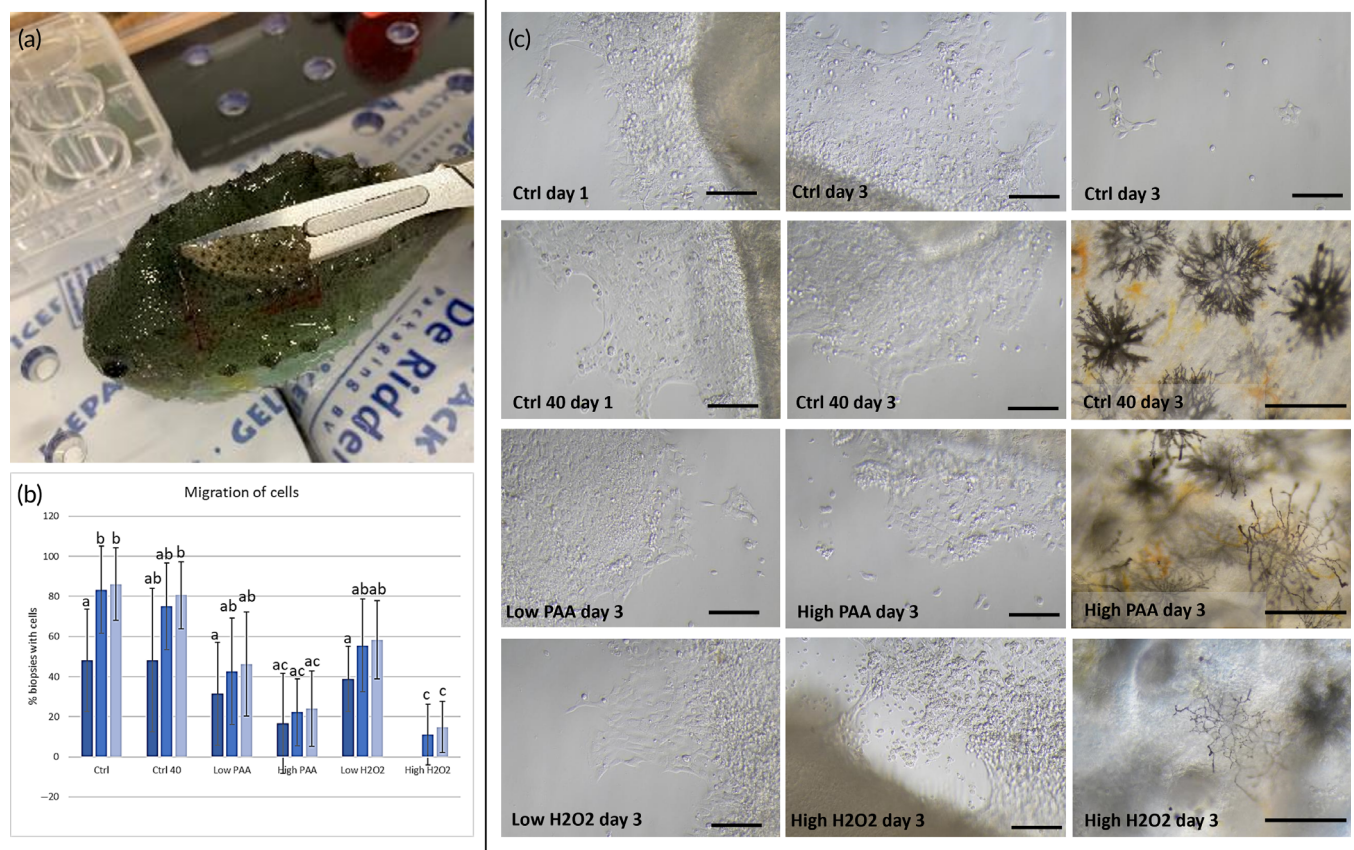
epidermal border, removed epidermis from the bony plates and detached the epidermis from the basement membrane.

Histological measurements reported a significant difference between groups on various skin barrier parameters, including mucous cell number, the ratio of purple to blue mucous cells, the thickness of the epidermis, the ratio of the outer and total number of mucous cells to the number of club cells (Figure 2). The high  $H_2O_2$  treatment had the most substantial effect, with different ratios between purple and blue mucous cells, more mucous cells in the outermost part of the epidermis and more club cells. Nonetheless, all treatments showed different measures in one or more of these morphometric parameters compared to the control.

Cell cultures of lumpfish skin keratocytes were obtained from skin biopsies (Figure 3a). The migration capacity from both control fish and those kept for 40 min in SW after euthanasia was markedly more efficient compared to treated skin, with more than 80% efficiency in both groups after 3 days compared to less than 60% in all the treated groups (Figure 3b). Examples of migrating cells from the different biopsies are shown in Figure 3c. Cells had the same morphology as previously described for migrating fish keratocytes, with a body and a

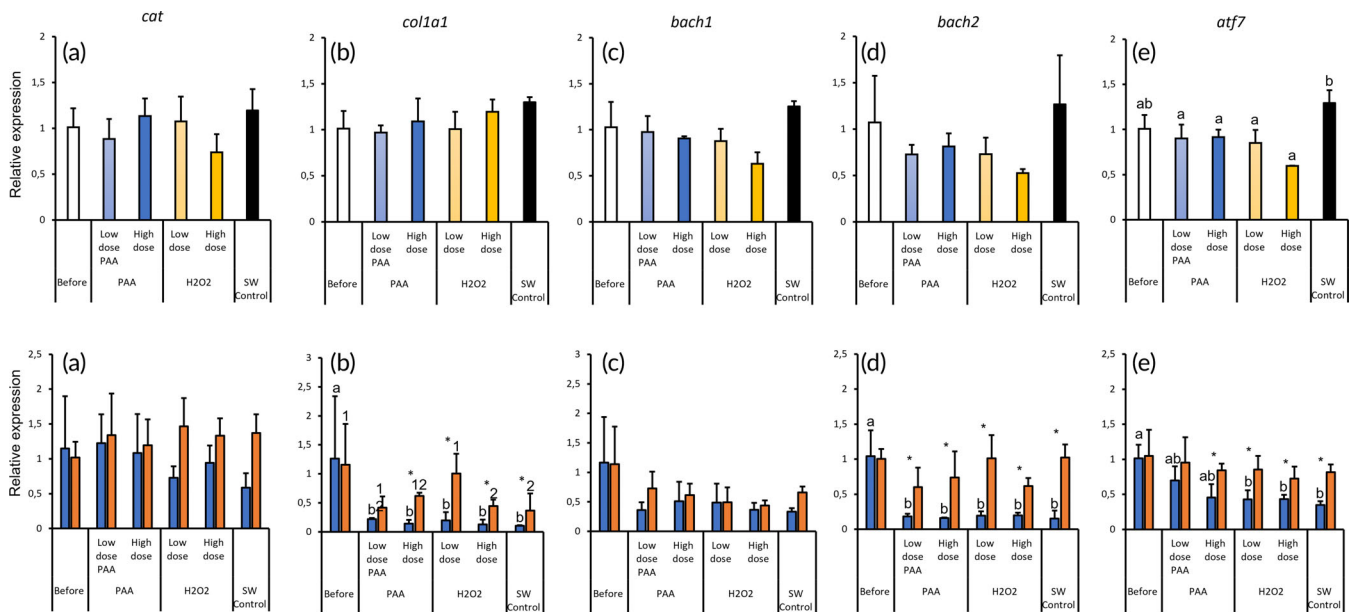
directional lamellipodium. Interestingly, melanocytes in the skin had a more spindle-shaped appearance in skin from fish treated with both high doses of PAA and  $H_2O_2$ .

The expression of the five marker genes in the skin tissue did not significantly change after exposure to oxidative therapeutics except for *atf7* (Figure 4a–e). *atf7* expression in the skin of oxidant-exposed lumpfish, regardless of the dose, was significantly lower compared to the SW control. Nonetheless, the transcript level of *atf7* in all oxidant-exposed groups was not significantly different from that in the pre-exposure level (Figure 4e). Unlike in skin tissue, the expression of the same marker genes displayed pronounced variability in the skin mucus, and collection technique played an influence (Figure 4a–e). Samples collected by scraping in all treatment groups, including the SW control, displayed significantly lower *col1a1* expression compared to the pre-exposure level. Such a tendency was observed only in samples collected by swabbing in high-dose  $H_2O_2$  and SW control. Except for pre-exposure and low-dose PAA, the expression of *col1a1* in skin mucus collected by swabbing was significantly higher than that in their counterparts collected by scraping (Figure 4b). The expression of *bach2* and *atf7* in the skin mucus displayed significant variations only



**FIGURE 3** Cell cultures from tank-reared fish from the controlled tank trial. (a) Cell cultures were prepared from skin biopsies, 1 x 1 mm. (b) Migration, measured as percentage of biopsies with migrating keratocytes, was followed for 3 days ( $n = 15$  biopsies per treatment). Notice the low percentage in cultures from fish treated with high doses of PAA (peracetic acid) and both low and high doses of  $H_2O_2$ . Significant numbers ( $P \leq 0.05$ ) are indicated by different letters. (c) Representative images of cells from the different treatments. Biopsies from both ctrl and ctrl 40 made confluent sheets of cells and had strong coloured melanocytes. High doses of PAA and  $H_2O_2$  resulted in smaller cell sheets and reduced colouration and spindle-shaped melanocytes. Scale bar 100  $\mu m$ . ■, Day 1; ■, Day 2; ■, Day 3





**FIGURE 4** Expression of selected genes in the skin tissue (a–e) and mucus (a–e) of lumpfish exposed to selected oxidative therapeutics [PAA (peracetic acid) and H<sub>2</sub>O<sub>2</sub>]. Values are given as mean  $\pm$  s.d. ( $n = 3$ ). Samples were collected before and upon termination of the 40 min exposure. For (A–E), different letters denote significant difference among the groups. For (a–e), significant difference within the samples collected by scraping was designated with different letters, whereas different numbers are used to indicate significant difference within the samples collected by swabbing. Significant difference between scraping and swabbing in a particular treatment group is denoted by an asterisk (\*). The level of significance was set at  $P \leq 0.05$ . ■, Scraping; ■, Swabbing; ■, Scraping; ■, Swabbing; ■, Scraping; ■, Swabbing; ■, Scraping; ■, Swabbing

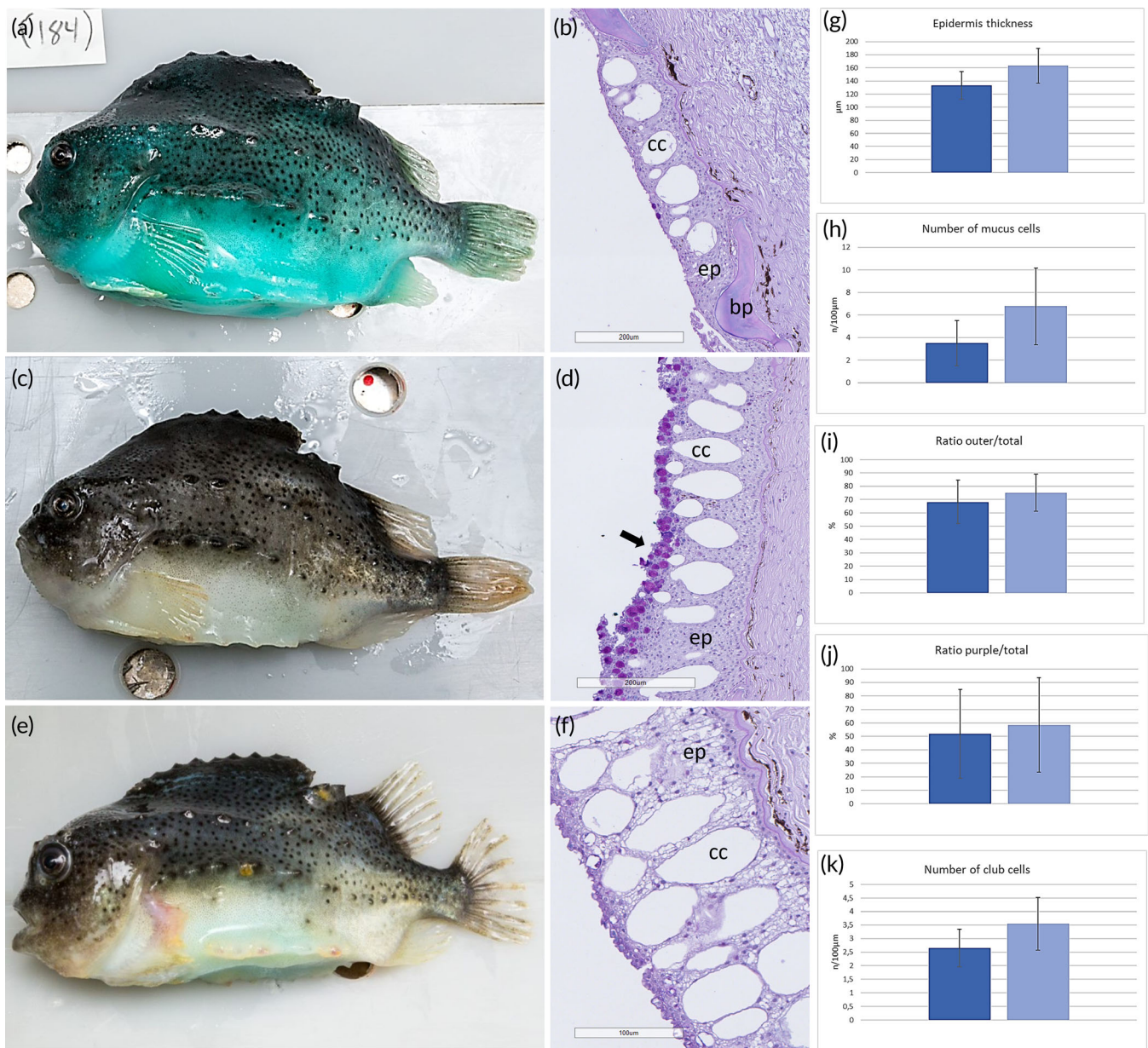
in samples collected by scraping (Figure 4d,e). All oxidant-exposed groups, including the SW control, showed significantly lower expressions compared to the pre-exposure level. A similar tendency was also observed in *atf7* expression, with a significant change identified in H<sub>2</sub>O<sub>2</sub>-exposed fish and in the SW control. Moreover, the expression of *atf7* in skin mucus sampled by swabbing was significantly higher compared with the samples taken by scraping in low-dose PAA, both doses in H<sub>2</sub>O<sub>2</sub> and in SW control (Figure 4e). The expression of catalase and *bach2*, regardless of sampling technique, remained unchanged in the skin mucus (Figure 4a,c).

### 3.2 | Samples on fish sourced from commercial Atlantic salmon production cages

In the first sampling in October 2020, the authors found differences in mucous cell abundance between moribund and healthy individuals, with moribund fish exhibiting increased cell abundance in the outer part of the epidermis compared to the skin of healthy individuals (Figure 5). Some of the moribund fish also showed severe morphological changes in the keratocytes in the epidermis, including vacuolization in the keratocytes (Figure 5f) and empty mucous cells. Some of the samples had no epidermis at all (not shown). Mucous cell numbers were significantly higher in the moribund group, and there was a trend towards a thinner epidermis, a higher percentage of mucous cells in the outer epidermis, pink mucous cells and more club cells in moribund fish (Figure 5g–k).

OWI analysis of the images was carried out based on the scale developed by Imsland *et al.* (2020). All moribund fish in the first sample had minor macro-level epidermal injuries ( $n = 6$ ), which involved minor localized epidermal damage (Imsland *et al.*, 2020). Interestingly, none of this damage was apparent on the left-side dorsal area, which was the standardized side sampled for histology. Four of the six fish had active caudal-fin damage that could be classified as major loss of the fin tissue and fin rays (Imsland *et al.*, 2020). The condition factor of the moribund fish was classified as moderate, and Fulton's condition factor ( $K$ ) for moribund fish was  $3.90 \pm 0.21$ . The mean BMI (%) estimate of moribund fish was classified as normal (BMI range >90–110 after Garcia de Leaniz *et al.*, 2022) and was  $106.53 \pm 6.68\%$ . Within this classification four of the fish had a normal BMI, whereas the others had a BMI that was classified as above normal (Garcia de Leaniz *et al.*, 2022). With regard to the clinically healthy fish ( $n = 5$ ) only one fish had minor localized epidermal damage (Imsland *et al.*, 2020), and the damage was not localized to the left-side dorsal area that was sampled for histology. All healthy fish had only minor active caudal-fin damage. Two of the five fish had a condition factor that can be classified as good, and the rest had a moderate condition factor (Imsland *et al.*, 2020). Fulton's condition factor ( $K$ ) for healthy fish was  $4.28 \pm 0.26$ . The BMI (%) estimate for healthy fish was  $127.72 \pm 6.68\%$ , and all healthy fish had a BMI classified as above normal (Garcia de Leaniz *et al.*, 2022).

In the second sampling during April 2021, OWI analysis of the images was again carried out based on the scale developed by Imsland *et al.* (2020). All moribund fish in this sampling ( $n = 10$  individuals) exhibited clinical symptoms of tenacibaculosis (the causative agent



**FIGURE 5** Fish from commercial production, first sampling, showing the sampled fish and the histology of skin from (a, b) healthy and (c–f) weakened (moribund) fish. Notice the reorganization of the mucous cells to the outer layer in (d) and the vacuolization in the epidermis in (f). Histological measures were evaluated: (g) epidermal thickness, (h) number of mucous cells, (i) ratio of mucous cells in the outer part of the epidermis to the control, (j) ratio of purple to blue mucous cells and (k) number of club cells. Significant numbers ( $P \leq 0.05$ ) are indicated with different letters. Ep, epidermis; cc, club cells; bp, bony plates. ■, Healthy; □, Weakened; ■, Healthy; □, Weakened; ■, Healthy; □, Weakened; ■, Healthy; □, Weakened; ■, Healthy; □, Weakened

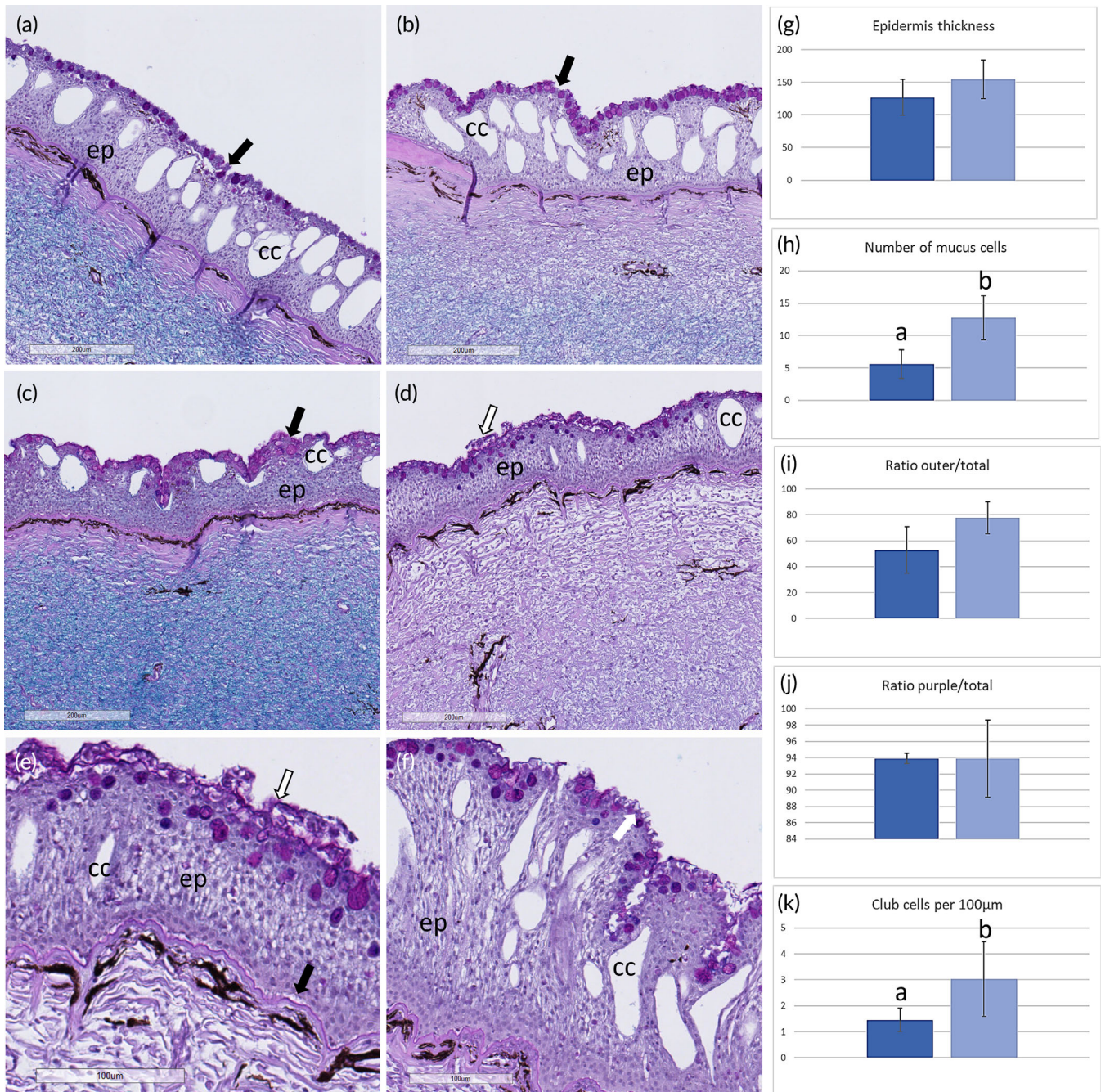
was confirmed to be *T. finnmarkense* in March 2021) and had major macro-level epidermal damage that involved pronounced ulceration. None of this macro-level damage was apparent in the left-side dorsal area that was sampled for histology. Four of the 10 moribund fish had active caudal-fin damage that could be classified as major loss of the fin tissue and fin rays (Imsland *et al.*, 2020). The condition factor of 7 out of 10 moribund fish was classified as moderate, and the other three fish had a good condition factor. Fulton's condition factor (K) for all moribund fish was  $4.24 \pm 0.78$ . The BMI (%) estimate for moribund fish was  $138.48 \pm 22.81\%$ , and all fish had a BMI that was classified as above normal (Garcia de Leaniz *et al.*, 2022). With regard to the

clinically healthy fish ( $n = 10$ ), only three fish had minor localized epidermal damage (Imsland *et al.*, 2020), and this damage was not localized to the left-side dorsal area that was sampled for histology. Only three healthy fish had minor active caudal-fin damage, and the other seven had fin damage that was classified as major loss of the fin tissue and fin rays (Imsland *et al.*, 2020). Seven of the 10 healthy fish had a condition factor classified as good, and the rest had a moderate condition factor (Imsland *et al.*, 2020). Fulton's condition factor (K) for healthy fish was  $4.91 \pm 0.90$ . The BMI (%) estimate for healthy fish was  $157.86 \pm 20.33\%$ , and all fish had a BMI that was classified as above normal (de Leaniz *et al.*, 2022).



During histological examination, all fish had mucous cells in the outer part of the epidermis, and overall, the morphology indicated reduced skin quality. All fish examined had different grades of exposed bony plates not covered by epidermis, but differences

between healthy and weakened (moribund) fish, and between treated fish from each of the two groups, were observed (Figure 6a-f). The number of mucous cells and club cells was different between weakened (moribund) and healthy fish ( $P \leq 0.05$ ), and there was a non-



**FIGURE 6** Fish from commercial production, second sampling, showing the histology of skin from (a) healthy and (b) weakened groups. Both groups had the majority of mucous cells (black arrow) in the outer layer of the epidermis. Weakened fish, both (c) non-treated and (d) treated, had more mucous cells and detaching cells (hollow arrow), and a rougher epidermal border compared to the normal fish. (e) A magnified image of a mucous layer (hollow arrow) covering the epidermis in weakened and treated fish, and detachment from the basement membrane (black arrow). (f) Empty mucous cells (white arrow) and vacuolization were detected in weakened and treated fish. Histological measures were evaluated in healthy and weakened fish, including (g) their epidermal thickness, (h) number of mucous cells, (i) ratio of mucous cells in the outer part of the epidermis, (j) ratio of purple to blue mucous cells and (k) number of club cells. The number of mucous cells and club cells was different between the healthy and weakened groups. Significant differences ( $P \leq 0.05$ ) are indicated with different letters. Ep, epidermis; cc, club cells. ■, Healthy; ■, Weakened; ■, Healthy; ■, Weakened; ■, Healthy; ■, Weakened; ■, Healthy; ■, Weakened; ■, Healthy; ■, Weakened



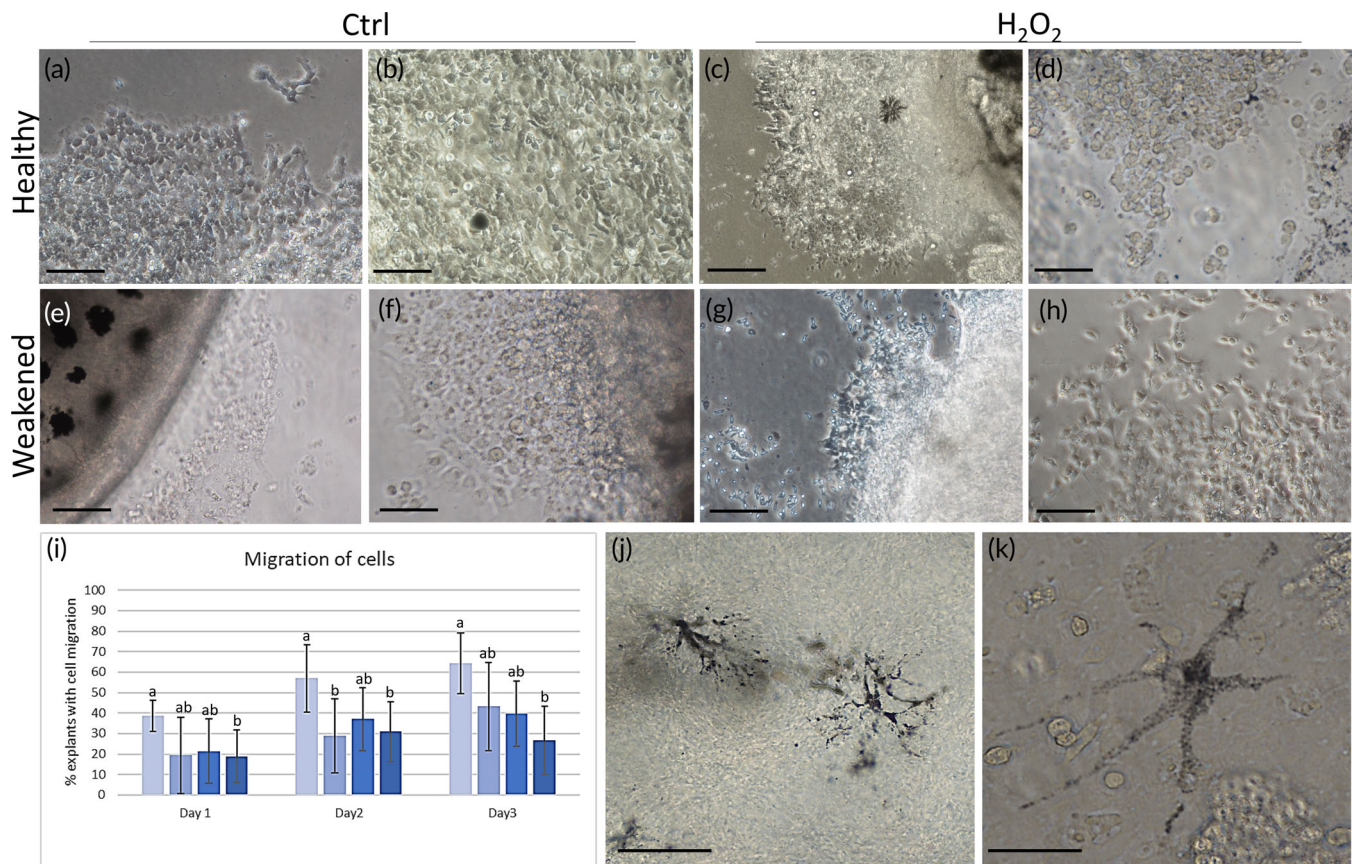
significant trend with regard to increased ratio of the outer to the total number of mucous cells in the epidermis ( $P \leq 0.061$ ). In fish treated with  $H_2O_2$ , morphological measures were not possible due to the damaged epidermis, too many mucous cells, empty mucous cells and changes in the keratocyte layer, including vacuolization and fish missing the outer epidermal layer (Figure 6e). Vacuolization of the epidermis was also observed in weakened fish not treated with  $H_2O_2$ . In treated fish, both healthy and weakened, the epidermal layer detached from the basement membrane (Figure 6f).

Cell cultures of lumpfish skin keratocytes were obtained from skin biopsies (Figure 7a) of fish sampled during the second sampling event on the commercial farm. Cell sheets formed in all groups; nonetheless, the front cells in cell sheets from healthy, untreated fish had a more uniform front compared to the weakened fish, and to those that were treated, irrespective of whether they were healthy or weakened (Figure 7a-h). The migration capacity of the cells from healthy and weakened fish was also measured, as well as from both groups exposed to  $H_2O_2$ . The migration capacity was lower for all fish compared to the fish raised in tanks in the research facility. Untreated fish from the healthy group had the best capacity (c. 64%). Weakened fish

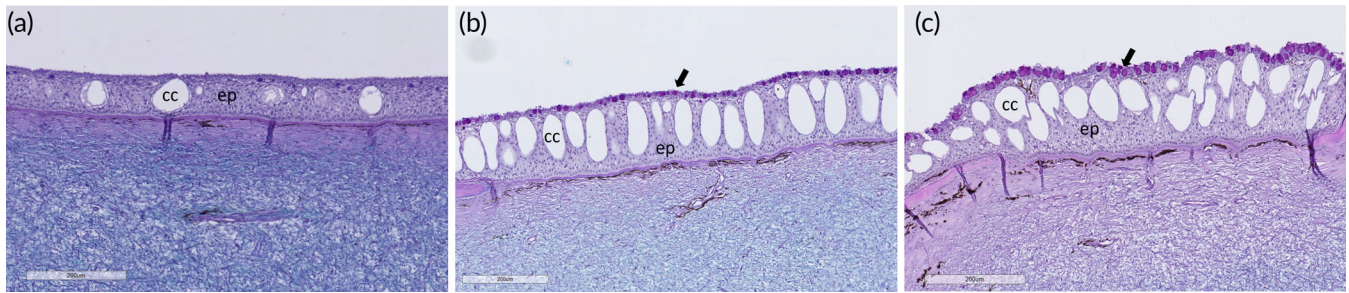
exposed to  $H_2O_2$  performed the worse, with less than 30% of the biopsies having migrating cells on day 3 (Figure 7i). Melanocytes from  $H_2O_2$ -treated healthy and weakened lumpfish skin showed a similar phenotype as melanocytes from  $H_2O_2$ -exposed tank-raised fish from the research facility, showing low colouration and spindle shape (Figure 7j-k).

### 3.3 | Comparison of fish from commercial setting vs. fish from research facility

Comparing the skin architecture of fish that were either tank reared (from a research facility) or cage reared (from a commercial production facility) revealed some interesting insights and differences: healthy fish samples from the commercial field trials resembled the samples from the treated tank-reared groups. As with the treated tank-reared fish (Figure 1), fish from the commercial cage had increased number of club cells and accumulation of mucous cells in the outer region of the epidermis (Figure 8). Skin biopsies from tank-reared fish revealed that control fish had a club cell frequency of less than 1 per  $\mu m$



**FIGURE 7** Cell cultures from skin biopsies sampled from fish in commercial production. (a, b) Healthy fish had confluent sheets of cells migrating from the biopsies, but these were reduced in fish exposed to  $H_2O_2$ . In addition, the front-line cells had a more (c) distorted pattern, and in some biopsies cells had a (d) rounded morphology. (e, f) Biopsies from weakened fish had smaller cell sheets, and (g, h) these became even smaller and less confluent in fish exposed to  $H_2O_2$ . (i) Cultures developed from healthy fish had the highest migration percentage ( $n = 15$  biopsies per treatment). Significant numbers ( $P \leq 0.05$ ) are indicated by different letters. Melanocytes from  $H_2O_2$ -treated (j) healthy and (k) weakened groups. Scale bar 100  $\mu m$ . ■, Ctrl Healthy; ■, Ctrl Weakened; ■,  $H_2O_2$  Healthy; ■,  $H_2O_2$  Weakened



**FIGURE 8** Comparison of skin from healthy fish sampled from (a) non-treated fish from tanks in a research facility and (b, c) commercial production, where (b) is from the first sampling and (c) is from the second sampling. Fish from commercial settings had more mucous cells in the outer epidermis and more club cells. Black arrow points at mucous cells in the outermost part of the epidermis. Ep, epidermis; cc, club cells. Scale bar as indicated

(Figure 1) and treated fish more than 1 per  $\mu\text{m}$  (Figure 5). From the commercial cage field samples, all skin samples had a club cell frequency of more than 2 per  $\mu\text{m}$ , at both sampling points and in both healthy and weakened individuals. Epidermal thickness also increased in these groups, most likely because of an increased number of club cells and more mucous cells. Tank-reared fish from the control group and those kept for 40 min in SW after euthanasia had an outer to total ratio of mucous cells of 30%–40%, whereas all treated groups had a ratio between 50% and 75%. Samples from fish from the commercial production cages were between 55% and 60%.

## 4 | DISCUSSION

The health and welfare of lumpfish during their commercial deployment at sea is an area of increasing concern for a range of stakeholders associated with the Norwegian salmon aquaculture industry and beyond. This concern can be especially directed at the potentially avoidable conditions that they can be exposed to when salmon are subjected to different husbandry operations. For example, there have been instances where lumpfish have accidentally been subjected to the same mechanical de-licing procedures as the salmon (Imsland *et al.*, 2020; Mattilsynet, 2019), and this has raised serious ethical concerns (Garcia de Leaniz *et al.*, 2022). The present work reveals the profound effects of two different anti-parasitic chemicals on the skin of lumpfish, one currently used to treat sea lice and the other with a potential to be used to treat parasites. Lumpfish skin from both research facilities and commercial production was studied using *in vitro* models, histology and transcriptomics to document how the skin responds to  $\text{H}_2\text{O}_2$ ; an existing chemotherapeutic for sea lice; and PAA, a potential future chemotherapeutic for Amoebic gill diseases (AGD). Imsland *et al.* (2020) reported that in certain instances, both mechanical and thermal de-licing treatments increased lumpfish post-treatment mortality in their study. The authors' results show that lumpfish skin is severely affected by chemical exposure, both at high and low doses. An increased focus should be to ensure that the operational procedures for separating lumpfish before anti-parasite treatments are vigorous and diligently followed.

*In vitro* oxidant-treated lumpfish skin exhibited morphological alterations that are typically characteristic of fish skin that has been exposed to stressful conditions, as observed previously in Atlantic salmon (*S. salar*), Atlantic cod (*Gadus morhua*) and polar cod (*Boreogadus saida*) (Karlsen *et al.*, 2021; Sveen *et al.*, 2018; Ytteborg *et al.*, 2020). These alterations included mucous cell hyperplasia in the distal part of the epidermis, a rougher outer border of detaching keratocytes, reduced epidermal thickness and an increased number of club cells. In addition, fish had a diminished epidermis covering the bone plates, leaving these protective plates vulnerable to pathogens in the external environment. The epidermis of treated lumpfish was also detaching from the basement membrane. These findings are indicative of a compromised epidermal barrier, predisposing lumpfish skin to potential secondary infections after treatment. These observations and documentations are important to consider when handling lumpfish in commercial settings, both during potential procedures and during the days following a procedure, where the health and welfare of the fish can be potentially further compromised. For example, a compromised outer barrier may reduce the robustness of fish and lead to a higher mortality rate. Higher mortalities were seen after mechanical and thermal de-licing in another study (Imsland *et al.*, 2020).

Biopsies taken from fish exposed to high doses of PAA and both low and high doses of  $\text{H}_2\text{O}_2$  did not acquire the same migration capacity as untreated control fish, even after 3 days. Keratocytes in fish skin are extremely dynamic and motile, and this is an important attribute for the sealing and healing of mechanically induced wounds and superficial abrasion injuries such as scratches to prevent further damage and potential secondary infections (Karlsen *et al.*, 2012; Sveen *et al.*, 2019; Sveen *et al.*, 2020; Tadiso *et al.*, 2011). Migration capacity is thus an important component of the regeneration and healing of skin in fish, and delayed migration may reduce efficacy of these processes. Moreover, melanocytes were observed in the skin explants and showed reduced colouration and a more spindle-shaped morphology compared to melanocytes from non-exposed fish. It has recently been reported that melanin spots in salmon fade after operational procedures, such as crowding and netting (Thorsen, 2019), and it has been further suggested that the fading phenomenon might be stress induced. To the authors' knowledge, similar findings have not

been documented in lumpfish, and a thorough study of the abundance and function of the different chromatophores in lumpfish skin has not been undertaken. Skin melanocytes may also function as antioxidants and contribute to the inactivation of free radicals (Galano *et al.*, 2013; Hardeland, 2005). Overall, these results indicate that chemical treatment may induce long-term effects in the skin of lumpfish, and it would have been interesting to follow the potential recovery period of the skin under different farming conditions. As a cautionary proxy, it is essential that lumpfish are handled appropriately and separated from the population before chemotherapeutic treatments and then also followed closely after this separation and handling procedure to minimize the risks to their health and welfare.

The gene expression profile of the skin after exposure to the different chemicals at either dosage level remained unchanged after treatment. Nonetheless, moderate changes were observed in the gene expression profile of the mucus, specifically affecting genes associated with the extracellular matrix (*i.e.*, *col1a1*) and immunity (*i.e.*, *bach2*). The number of genes studied and the magnitude of their change were not comprehensive, but differences in gene expression could provide insights into a potential confounding factor that may be at play when using the two biological matrices (tissue vs. mucus), and this must be accounted for in future trials. Using mucus as a matrix is favourable as it opens for more non-lethal and non-invasive diagnostics tools. It has earlier been reported that sampling strategies for mucus play a critical role in delineating the mucosal responses in salmon (Tartor *et al.*, 2020). In this study, the authors demonstrated that the sampling procedure was a factor that could reshape the response profile in the mucus. It was found that scraping the mucus led to more variable results than swabbing, and this may perhaps be attributed to the epidermal layer being inadvertently included in the sample, which can alter that transcriptional profile.

Fish from the commercial production study were classified as clinically healthy or weak based on their morbidity status at the time of capture, and a small number of individual outcome-based OWIs related to fish condition and injury status were documented. Lumpfish condition is an OWI of particular concern with regard to their commercial deployment in sea cages and has been used as a key OWI in numerous studies (Johannesen *et al.*, 2018; Rabadan *et al.*, 2021; Rey *et al.*, 2021). None of the fish sampled in the current study were emaciated. Fulton's condition factor, while generally lower in moribund fish at both sampling points, was still classified as moderate/good in these fish based on Imsland *et al.* (2020). When using BMI as an indicator of condition (de Leaniz *et al.*, 2022), the authors' results showed that moribund fish had a normal BMI in October and healthy fish had a BMI that was above normal. In April the following year, all fish had a BMI that was above normal, and both condition factor and BMI of the sampled fish increased over winter. None of the challenges associated with skin status could therefore be associated with the energy reserves or feeding status of the fish.

Fin and epidermal damage is also an OWI of concern in lumpfish production and deployment (Imsland *et al.*, 2020; Noble *et al.*, 2019; Rey *et al.*, 2021) and is suggested as the OWI with most utility in OWI toolboxes for cleaner fish (de Leaniz *et al.*, 2022). Macro-level

evaluation of epidermal injuries in October charted minor localized epidermal injuries in all moribund fish, and the same level of injuries was documented in only one healthy fish. Interestingly, none of these macro-level injuries were in the skin area that was sampled for histology, and yet there were marked histological differences between moribund and healthy individuals with regard to mucous cell numbers and a trend for a thinner epidermis. In April, all moribund fish had major macro-level epidermal damage that involved pronounced ulceration and exhibited clinical symptoms of tenacibaculosis. In contrast, only three of the healthy fish had minor epidermal damage. Histological differences between moribund and healthy fish in April were again primarily attributed to the number of mucous cells and club cells, and there was a non-significant tendency towards an increased ratio of the number of outer to the total mucous cells in the epidermis. Two-thirds of the moribund fish had major caudal-fin damage in October, in comparison to only mild caudal-fin damage being observed in healthy fish at that time. This situation changed in April, with 70% of the healthy fish exhibiting major caudal-fin damage in comparison to 40% of the moribund fish. Nonetheless, as only 5–10 moribund and healthy fish were sampled at all time points, caudal and epidermal injury frequency data should be interpreted with some caution. Rey *et al.* (2021) reported that body condition was not predictive of fin damage status and reported a marked variability in fin damage status in commercially deployed lumpfish, suggesting this was unsurprising due to the range of conditions the fish were subjected to during a production cycle. Problematic fin damage has been observed in other studies (Imsland *et al.*, 2020; Gutierrez Rabadan *et al.*, 2021; Rey *et al.*, 2021), and production-related injuries such as fin damage may be vectors for opportunistic pathogens or may also be detrimental to the swimming performance of the lumpfish (see Gutierrez Rabadan *et al.*, 2021, and references therein).

Interestingly, results showed that skin from non-treated, healthy fish sampled from commercial farms were similar to skin sampled from oxidant-treated fish from the controlled laboratory trial. The skin of commercial fish had more mucous cells in the distal border and a higher number of club cells. Mucous cell hyperplasia in the outer epidermis in skin is, as previously stated, associated with increased stress. Club cells are considered to function as both alarm cells and immune cells (Chivers *et al.*, 2015); may act as a first line of defence against pathogens and parasites (Chivers *et al.*, 2007); and respond in numbers to environmental stressors, such as temperature changes and poor water quality, and production-related stressors, such as handling and transportation. The sensory mechanisms involved in determining club cell density in lumpfish are still not fully understood, and the morphological differences observed between fish from the tank trial and those from commercial production can be driven and confounded by many factors such as size, seasonal variation, response to pathogens, parasites and feed level. One should therefore be cautious when making conclusions based on club cell number, but the findings are interesting and should be considered in future studies. Skin samples from healthy fish from commercial farming also showed spacing between keratocytes in the epidermis, a morphology more pronounced in exposed fish from both tank trials and sea cage and moribund fish,



indicating that this response may be stress induced, as previously shown in salmon skin (Sveen *et al.*, 2019). The overt similarities between the results of the current study and others indicate that lumpfish in salmon net-cages have skin features and responses that can be indicative of a stressful environment. Whether this is chronic stress induced by living with salmon, or stress induced by operational procedures at the farm, needs to be investigated further. For example, a recent study has shown that lumpfish cohabitation with salmon in controlled studies does not negatively impact their welfare in terms of a range of welfare indicators but does affect brain neuromodulators (Staven *et al.*, 2022). Cell cultures also showed a reduced migration capacity of keratocytes from fish in commercial settings, compared to non-treated healthy fish from a controlled tank environment. This further supports the suggestion that the rearing environment in commercial production has a considerable impact on skin barrier functionality, and establishing the direct cause and drivers of this is important for the protection and handling of cleaner fish in cages.

## 5 | CONCLUSION

This study demonstrated the adverse effects of common or potential chemical treatments used in salmon farming on lumpfish skin, including acute responses inferred by histology and delayed migration from the *in vitro* skin explants. Acute responses included damaged skin barrier, exposed spikes and a reorganization of mucous cells. Delayed migration of keratocytes may increase the risk of wound development and secondary infections. This study suggests that potential chemotherapeutic interventions in salmon present a serious predisposing risk for lumpfish to develop secondary or long-term effects, which further highlights the need for these fish to be isolated and removed from the cage before any chemotherapeutic treatments.

Skin challenges in moribund fish sampled from commercial production could not be associated with their energetic status as all sampled fish had a condition factor that was moderate/good and a BMI that was normal or above normal. Salmon farmers using cleaner fish in their cages must be attentive when mechanically treating sea lice, and the handling of lumpfish in salmon aquaculture should be reviewed and adapted accordingly. If the use of lumpfish for biological control of sea lice in salmon farming continues, operational procedures at farms affecting the health and welfare of cleaner fish must be improved for ethical use of these animals.

## ACKNOWLEDGEMENTS

The authors are grateful to the Akvaplan-Niva research and innovation facility in Kraknes, Tromsø, for providing them with lumpfish produced at the facility. The authors are also grateful to SalMar ASA for providing them with lumpfish from one of their salmon farms. They thank Lisbeth Rørmark (Lilleborg AS) for the PAA used in the study.

## FUNDING INFORMATION

This research was financed by the Norwegian Research Council, grant agreement number 194050 (Insight); the Norwegian Seafood Research Fund, grant agreement number 901472 (PERAGILL); and Bjørøya AS

(R&D licence project Cyclus II, licence numbers NTF-36 and NTF-37) and Tromsø Aquaculture Research Station (R&D licence project HVI Toolbox II, licence number T-T-35, project number 200005).

## CONFLICT OF INTEREST STATEMENT

No competing interests declared. Mention of trade names or commercial products in this paper is solely for the purpose of reporting and does not imply recommendation or endorsement by Nofima.

## ORCID

Elisabeth Ytteborg  <https://orcid.org/0000-0002-3131-020X>

## REFERENCES

- Akvaplan-Niva. (2019). *Risk assessment and risk reducing measures for discharges of hydrogen peroxide (H<sub>2</sub>O<sub>2</sub>)*. Tromsø: Akvaplan Niva.
- Barrett, L. T., Oppedal, F., Robinson, N., & Dempster, T. (2020). Prevention not cure: A review of methods to avoid sea lice infestations in salmon aquaculture. *Reviews in Aquaculture*, 12, 2527–2543.
- Bechmann, R. K., Arnberg, M., Gomiero, A., Westerlund, S., Lyng, E., Berry, M., ... Burrridge, L. E. (2019). Gill damage and delayed mortality of northern shrimp (*Pandalus borealis*) after short time exposure to anti-parasitic veterinary medicine containing hydrogen peroxide. *Ecotoxicology and Environmental Safety*, 180, 473–482.
- Burrridge, L., Weis, J. S., Cabello, F., Pizarro, J., & Bostick, K. (2010). Chemical use in salmon aquaculture: A review of current practices and possible environmental effects. *Aquaculture*, 306, 7–23.
- Cabillon, N. A. R., & Lazado, C. C. (2019). Mucosal barrier functions of fish under changing environmental conditions. *Fishes*, 4, 2.
- Chivers, D., Wisenden, B. D., Hindman, C., Michalak, T. A., Kusch, R., Kaminskyj, S. G., ... Mathis, A. (2007). Epidermal 'alarm substance' cells of fishes maintained by non-alarm functions: Possible defence against pathogens, parasites and UVB radiation. *Proceedings in Biological Science*, 274, 2611–2619.
- Chivers, D., Brown, G., & Ferrari, M. (2015). The evolution of alarm substances and disturbance cues in aquatic animals. *Chemical Ecology in Aquatic Systems*, 9, 127–139.
- Costello, M. J. (2009). The global economic cost of sea lice to the salmonid farming industry. *Journal of Fish Diseases*, 32, 115–118.
- de Leaniz, G., Carlos, C. G., Rabadan, S. I., Barrento, R. S., Howes, P. N., Whittaker, B. A., ... Pavlidis, M. (2022). Addressing the welfare needs of farmed lumpfish: Knowledge gaps, challenges and solutions. *Reviews in Aquaculture*, 14, 139–155.
- Erkinharju, T., Dalmo, R. A., Hansen, M., & Seternes, T. (2021). Cleaner fish in aquaculture: Review on diseases and vaccination. *Reviews in Aquaculture*, 13, 189–237.
- Fast, M. D. (2014). Fish immune responses to parasitic copepod (namely sea lice) infection. *Developmental Comparative Immunology*, 43, 300–312.
- Fiskeridirektoratet. (2021). Use of cleanerfish, 2020. *Statistics for Aquaculture, Cleanerfish* [www.fiskeridir.no](http://www.fiskeridir.no).
- Furtado, F., Breiland, M. W., Strand, D., Timmerhaus, G., Carletto, D., Pedersen, L.-F., ... Lazado, C. C. (2022). Regulation of the molecular repertoires of oxidative stress response in the gills and olfactory organ of Atlantic salmon following infection and treatment of the parasite *Neoparamoeba perurans*. *Fish & Shellfish Immunology*, 130, 612–623.
- Galano, A., Tan, D. X., & Reiter, R. J. (2013). On the free radical scavenging activities of melatonin's metabolites. *AFMK and AMK*, *Journal of Pineal Research*, 54, 245–257.
- Geitung, L., Wright, D. W., Oppedal, F., Stien, L. H., Vågseth, T., & Madaro, A. (2020). Cleaner fish growth, welfare and survival in Atlantic salmon sea cages during an autumn-winter production. *Aquaculture*, 528, 735623.
- Hardeland, R. (2005). Antioxidative protection by melatonin. *Endocrine*, 27, 119–130.



- Helgesen, K. O., Romstad, H., Aaen, S. M., & Horsberg, T. E. (2015). First report of reduced sensitivity towards hydrogen peroxide found in the salmon louse *Lepeophtheirus salmonis* in Norway. *Aquaculture Reports*, 1, 37–42.
- Imsland, A., Reynolds, P., Lorentzen, M., Eilertsen, R. A., Micallef, G., & Tvenning, R. (2020). Improving survival and health of lumpfish (*Cyclopterus lumpus* L.) by the use of feed blocks and operational welfare indicators (OWIs) in commercial Atlantic salmon cages. *Aquaculture*, 527, 735476.
- Iversen, A., Øystein, H., Otto, A., Ruth, K. B., Anders, M., & Ragnar, N. (2015). 'Kostnadsdrivere i lakseoppdrett', 41. Nofima report (43 p). Nofima.
- Johannesen, A., Joensen, N. E., & Magnussen, E. (2018). 'Shelters can negatively affect growth and welfare in lumpfish if feed is delivered continuously', *peer J publishing. Aquatic Biology*, 6, e4837.
- Jones, P. G., Hammell, K. L., Gettinby, G., & Revie, C. W. (2013). Detection of emamectin benzoate tolerance emergence in different life stages of sea lice, *Lepeophtheirus salmonis*, on farmed Atlantic salmon, *Salmo salar* L. *Journal of Fish Diseases*, 36, 209–220.
- Karlsen, C., Bøgevik, A. S., Krasnov, A., & Ytteborg, E. (2021). In vivo and in vitro assessment of Atlantic salmon skin exposed to hydrogen peroxide. *Aquaculture*, 540, 736660.
- Karlsen, C., Sorum, H., Willassen, N. P., & Asbakk, K. (2012). *Moritella viscosa* bypasses Atlantic salmon epidermal keratocyte clearing activity and might use skin surfaces as a port of infection. *Veterinary Microbiology*, 154, 353–362.
- Lazado, C. C., Haddeland, S., Timmerhaus, G., Berg, R. S., Merkin, G., Pittman, K., & Pedersen, L.-F. (2020). Morphomolecular alterations in the skin mucosa of Atlantic salmon (*Salmo salar*) after exposure to peracetic acid-based disinfectant. *Aquaculture Reports*, 17, 100368.
- Lazado, C. C., Pedersen, L.-F., Kirste, K. H., Soleng, M., Breiland, M. W., & Timmerhaus, G. (2020). Oxidant-induced modifications in the mucosal transcriptome and circulating metabolome of Atlantic salmon. *Aquatic Toxicology*, 227, 105625.
- Lazado, C. C., Strand, D. A., Breiland, M. W., Furtado, F., Timmerhaus, G., Gjessing, M. C., ... Krasnov, A. (2022). Mucosal immune and stress responses of *Neoparamoeba perurans*-infected Atlantic salmon (*Salmo salar*) treated with peracetic acid shed light on the host-parasite-oxidant interactions. *Frontiers in Immunology*, 13, 948897.
- Lazado, C. C., Sveen, L. R., Soleng, M., Pedersen, L.-F., & Timmerhaus, G. (2021). Crowding reshapes the mucosal but not the systemic response repertoires of Atlantic salmon to peracetic acid. *Aquaculture*, 531, 735830.
- Lees, F., Baillie, M., Gettinby, G., & Revie, C. W. (2008). Factors associated with changing efficacy of emamectin benzoate against infestations of *Lepeophtheirus salmonis* on Scottish salmon farms. *Journal of Fish Diseases*, 31, 947–951.
- Liu, D., Lazado, C. C., Pedersen, L.-F., Straus, D. L., & Meinelt, T. (2020). Antioxidative, histological and immunological responses of rainbow trout after periodic and continuous exposures to a peracetic acid-based disinfectant. *Aquaculture*, 520, 734956.
- Mattilsynet (2019). Velferd hos rensefisk. In *In: Nasjonalt tilsynskampanje 2018/2019*. Nofima: OWI fact sheet series.
- McVicar, A. H. (2004). Management actions in relation to the controversy about salmon lice infections in fish farms as a hazard to wild salmonid populations. *Aquaculture Research*, 35, 751–758.
- Nagasawa, K., Lazado, C., & Fernandes, J. (2012). *Aquaculture*. (IntechOpen). In Z. A. Muchlisin, (Ed.), 'Validation of endogenous reference genes for qPCR quantification of muscle transcripts in Atlantic cod subjected to different photoperiod regimes' (pp. 81–92). Croatia: InTech.
- Noble, Chris, Martin Iversen, Ingrid Lein, Jelena Kolarevic, Lill-Heidi Johansen, Gerd Berge, Erik Burgerhout, Velmurugu Puvanendran, Atle Mortensen, Anne Stene, and Åsa Espmark. 2019. Rensvel OWI fact sheet series: An introduction to operational and laboratory-based welfare indicators for lumpfish (*Cyclopterus lumpus* L.).
- Overton, K., Barrett, L. T., Oppedal, F., Kristiansen, T. S., & Dempster, T. (2020). Sea lice removal by cleaner fish in salmon aquaculture: A review of the evidence base. *Aquaculture Environment Interactions*, 12, 31–44.
- Overton, K., Dempster, T., Oppedal, F., Kristiansen, T. S., Gismervik, K., & Stien, L. H. (2019). Salmon lice treatments and salmon mortality in Norwegian aquaculture: A review. *Reviews in Aquaculture*, 11, 1398–1417.
- Pedersen, L.-F., & Lazado, C. C. (2020). Decay of peracetic acid in seawater and implications for its chemotherapeutic potential in aquaculture. *Aquaculture Environment Interactions*, 12, 153–165.
- Powell, A., Treasurer, J., Pooley, C., Keay, A., Lloyd, R., Imsland, A., & Leaniz, C. G. (2017). Use of lumpfish for sea-lice control in salmon farming: Challenges and opportunities. *Reviews in Aquaculture*, 10.
- Gutierrez Rabadan, C., Spreadbury, C., Consuegra, S. & Garcia de Leaniz, C. (2021). Development, validation and testing of an operational welfare score index for farmed lumpfish *Cyclopterus lumpus* L. *Aquaculture*, 531, 735777.
- Rey, S., Treasurer, J., Pattillo, C., & McAdam, B. J. (2021). Using model selection to choose a size-based condition index that is consistent with operational welfare indicators. *Journal of Fish Biology*, 99, 782–795.
- Staven, F. R., Gesto, M., Iversen, M. H., Andersen, P., Patel, D. M., Nordeide, J. T., & Kristensen, T. (2022). Cohabitation with Atlantic Salmon (*Salmo salar*) affects brain neuromodulators but not welfare indicators in lumpfish (*Cyclopterus lumpus*). *Frontiers in Physiology*, 13.
- Stien, L. H., Størkersen, K. V., & Gåsnes, S. K. (2020). Analysis of mortality data from survey on cleaner fish. *Rapport Fra Havforskningen*, 6, 1893–4536.
- Sveen, L., Karlsen, C., & Ytteborg, E. (2020). Mechanical induced wounds in fish – A review on models and healing mechanisms. *Reviews in Aquaculture*, 12, 2446–2465.
- Sveen, L. R., Timmerhaus, G., Krasnov, A., Takle, H., Stefansson, S. O., Handeland, S. O., & Ytteborg, E. (2018). High fish density delays wound healing in Atlantic salmon (*Salmo salar*). *Scientific Reports*, 8, 16907.
- Sveen, L., Timmerhaus, G., Krasnov, A., Takle, H., Handeland, S., & Ytteborg, E. (2019). Wound healing in post-smolt Atlantic salmon (*Salmo salar* L.). *Scientific Reports*, 9, 3565.
- Tadiso, T. M., Krasnov, A., Skugor, S., Afanasyev, S., Hordvik, I., & Nilsen, F. (2011). Gene expression analyses of immune responses in Atlantic salmon during early stages of infection by salmon louse (*Lepeophtheirus salmonis*) revealed bi-phasic responses coinciding with the copepod-chalimus transition. *BMC Genomics*, 12, 141.
- Tartor, H., Monjane, A. L., & Grove, S. (2020). Quantification of defensive proteins in skin mucus of Atlantic salmon using minimally invasive sampling and high-sensitivity ELISA. *Animals*, 10, 1374.
- Thorsen, D. K. (2019). "Melanin-based skin pigmentation and stress in Atlantic salmon (*Salmo salar*)."
- Treasurer, J. W. (2002). A review of potential pathogens of sea lice and the application of cleaner fish in biological control. *Pest Management Science*, 58, 546–558.
- Treasurer, J. W., & Grant, A. (1997). The efficacy of hydrogen peroxide for the treatment of farmed Atlantic salmon, *Salmo salar* L. infested with sea lice (Copepoda: Caligidae). *Aquaculture*, 148, 265–275.
- Veterinærinstituttet. (2014). *Rensefiskhelse - kartlegging av dødelighet og dødsårsaker*. Veterinærinstituttets rapportserie: Norway.
- Ytteborg, E., Hansen, Ø. J., Høst, V., Afanasyev, S., Vieweg, I., Nahrgang, J., & Krasnov, A. (2020). Morphology, transcriptomics and In vitro model of skin from polar cod (*Boreogadus Saida*) and Atlantic cod (*Gadus Morhua*). *Fishes*, 5, 34.

**How to cite this article:** Ytteborg, E., Lazado, C. C., Noble, C., Hansen, R. I., & Johansen, L.-H. (2025). The skin mucosal barrier of lumpfish (*Cyclopterus lumpus* L.) is weakened by exposure to potential aquaculture production-related stressors. *Journal of Fish Biology*, 106(1), 33–47. <https://doi.org/10.1111/jfb.15352>