

Use of Electrocardiogram to Position Right Atrial Catheters During Surgery

Virginia A. Watters, R.N., and John P. Grant, M.D.

From the Department of Surgery, Duke University Medical Center, Durham, North Carolina

Objective

This study evaluated the accuracy of placing right atrial catheters using an electrocardiographic (ECG) technique.

Summary Background Data

Placement of right atrial catheters for vascular access is a common operative procedure. Accurate placement is essential for proper function. Previous placement techniques have used fluoroscopy, which is both time consuming and hazardous.

Methods

The accuracy of placement of 1236 right atrial catheters using an ECG technique was compared to placement of 586 catheters using fluoroscopy between March 1991 and November 1995.

In the ECG technique, the catheter was flushed with sodium bicarbonate. A sterile left-leg ECG lead was attached to the catheter with the other ECG leads applied normally. On advancing the catheter through the superior vena cava, the P-wave amplitude (lead II) increased in negative deflection until greater than the QRS complex. Passing the sinoatrial node, the P-wave developed an initial positive then negative deflection. The catheter was positioned so the P-wave was biphasic, representing a position midway between the sinoatrial and atrioventricular nodes.

For the fluoroscopic technique, catheters were positioned under direct observation just within the atrium estimated from cardiac contour. Use of contrast was optional if atrial anatomy was unclear.

Results

Postoperative portable chest x-rays showed the ECG method to position the catheter tip within the right atrium just as accurately (average, 1.9 ± 1.3 cm) as with the use of fluoroscopy (average, 1.1 ± 1.6 cm).

The ECG method eliminated an average of 20 seconds of radiation exposure, an average of 3.0 minutes operating room time ($p < 0.04$), avoided all risks of contrast dye, and saved \$279.10 per case.

Conclusions

The ECG method is a satisfactory alternative to that of fluoroscopy for placement of long-term central venous catheters into the right atrium.

Table 1. INDICATIONS FOR VASCULAR ACCESS

Indication	No. of Patients (%)
Chemotherapy	1283 (71)
Bone marrow transplant therapy	332 (18)
Antibiotic therapy	128 (7)
Cardiac drug administration	29 (2)
Home intravenous nutrition	27 (1)
Blood sampling	23 (1)

When introduced initially, long-term indwelling central venous catheters were placed by cutdown via the cephalic or external jugular vein and tunneled subcutaneously, exiting on the anterior chest wall.¹ More recently, these catheters have been placed percutaneously using the Seldinger technique, thereby avoiding the need for surgical cutdown.² Traditionally, fluoroscopy has been used during placement to confirm correct positioning of the catheter tip. Use of fluoroscopy, however, lengthens operative time and increases expense. In addition, it exposes the operating room personnel and patient to radiation. A chest x-ray in the postoperative period still is required to rule out possible complications and to document proper catheter placement. We now report an alternate method for catheter placement that is as accurate as fluoroscopy, yet requires no radiation exposure, reduces operative time, and saves money. The technique uses the electrocardiogram (ECG) method and represents a modification of previously published methods for placement of cardiac monitoring catheters.³⁻⁷

METHODS

Between March 1991 and November 1995, 1822 catheters were placed in 1651 patients referred to the Vascular Access Service of Duke University Medical Center. The service was composed of four general surgeons, equally skilled at placing vascular access devices. There were 584 men and 1067 women with an average age of 51 years. The indications for catheter placement are listed in Table 1. All catheters were placed in the patient while he/she was in the operating room, using local anesthesia and monitored intravenous sedation. To optimize blood sampling and safe administration of irritating solutions, it was our intent to place the tips of all catheters 1 to 2 cm beyond the junction of the superior vena cava and right

atrium (Fig. 1). Intraoperative fluoroscopy was used for placement of 586 catheters, and the ECG method was used to place 1236 catheters. Patients were distributed equally by demographics, including age, sex, and diagnosis between the two techniques for placement. A portable semiupright chest x-ray was obtained on all patients after surgery to ensure no pneumothorax or other surgical complication had occurred and to document the actual catheter tip location. The catheter tip position was recorded relative to the junction of the superior vena cava with the right atrium. The total operative time and, when used, expenses related to use of fluoroscopy and intravenous contrast material were recorded.

All patients received preoperative intravenous antibiotics. Catheter insertion was performed with the patient in the supine position without the use of a rolled towel between the scapulae.⁸ When the ECG method was used, patients were placed in reverse Trendelenburg position to approximately 30°. In this position, the heart assumes a more anatomically correct position, being drawn lower in the chest by gravity and allowing for a more accurate positioning of the catheter tip. Catheters were placed according to techniques published previously.⁹ Briefly, the chest wall, shoulder, and base of neck were cleansed with povidone-iodine soap, alcohol, and povidone-iodine solution and draped in a sterile fashion. A wheal of 1% lidocaine with epinephrine mixed 1:1 with sodium bicarbonate was infiltrated at the selected skin puncture site, and a 1-cm incision was placed. An 18-gauge needle was passed through the incision into the subclavian vein by the infraclavicular technique. A guide-wire was passed through the needle and the needle removed. If an external catheter was being placed, a second injection of local

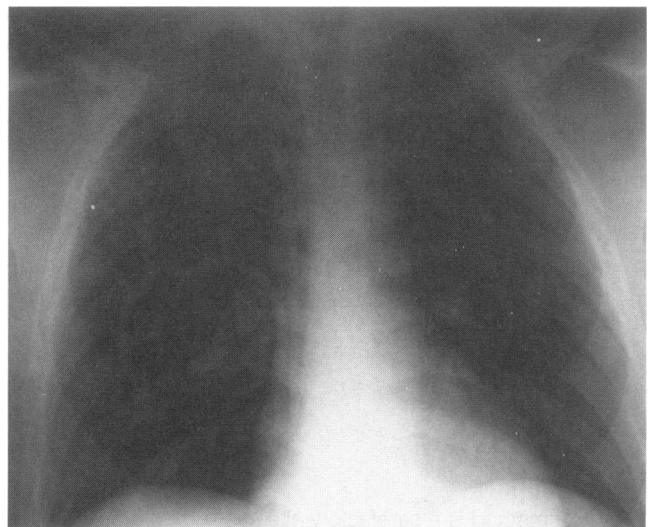


Figure 1. Optimal placement of catheter tip just inside the right atrium as seen on a postoperative portable chest x-ray.

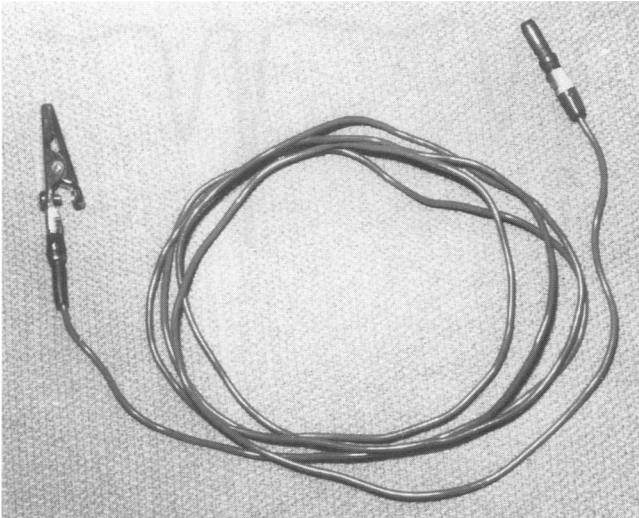


Figure 2. Electrocardiographic lead adapted for use by attaching alligator clip to one end.

anesthesia was placed at the proposed catheter exit site, and a second small incision was made. Local anesthesia with epinephrine was injected into the subcutaneous tract between the two incisions. The catheter was passed through the lower incision, within the subcutaneous tissue, and out the incision at the clavicle using a subcutaneous tunneler. The tissue in-growth cuff was positioned in the midportion of the subcutaneous tract, and the catheter was measured and cut to proper length. A split catheter sheath and dilator were passed over the guide-wire and advanced into the subclavian vein. The dilator and guide-wire were removed, and the catheter was passed through the split catheter sheath.

If fluoroscopy was being used, the catheter was flushed with heparinized saline solution and advanced until the tip was just within the right atrium as determined by anatomic landmarks. If anatomic landmarks were difficult to distinguish, 5 to 10 mL of contrast medium was injected to help visualize the location of the atrial cavity more accurately. If the ECG method was used, a sterile metal stopcock was attached to one lumen of the catheter and that lumen flushed with a sterile solution of sodium bicarbonate (1 mEq/mL). The other lumens of the catheter were flushed with sterile heparinized saline solution. A sterile ECG electrode lead was connected to the metal stopcock (using an alligator clamp) (Fig. 2) and the other end passed off the table and attached to the left-leg lead of the ECG monitor (Fig. 3). If a subcutaneous port was to be placed, one chamber of the port was flushed with a sterile solution of sodium bicarbonate (1 mEq/mL) attached to a non-coring needle. A sterile electrode lead was attached directly to the non-coring needle, and the other end passed off the table and attached to the left-leg lead of the ECG (Fig. 4). In both cases, remaining ECG

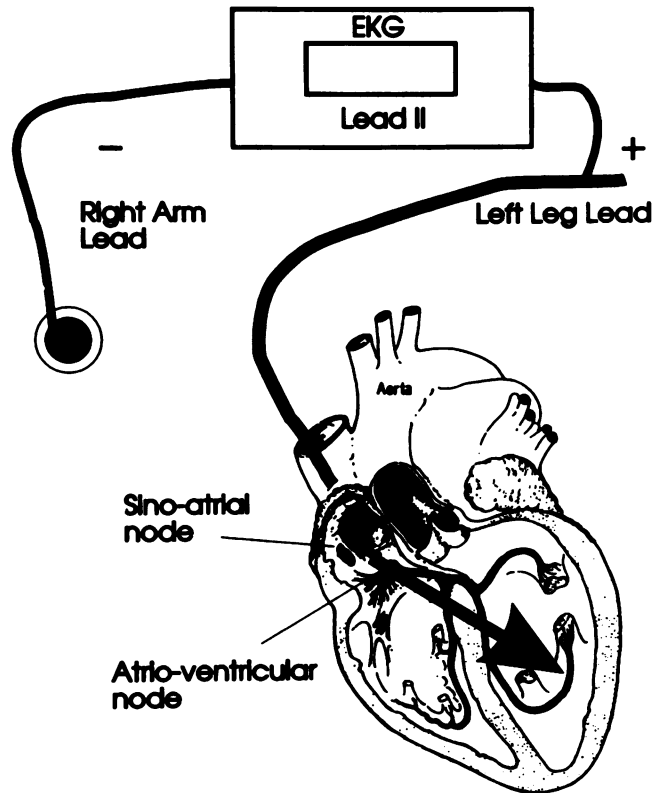


Figure 3. Connection of electrocardiographic lead from catheter to left-leg terminal of electrocardiogram monitor. The electrocardiogram monitor is set to read lead II.

leads were left attached to the patient's extremities as per routine. The ECG monitor was set to lead II, and the tracing was monitored as the catheter was advanced. When the catheter tip was in the superior vena cava, the

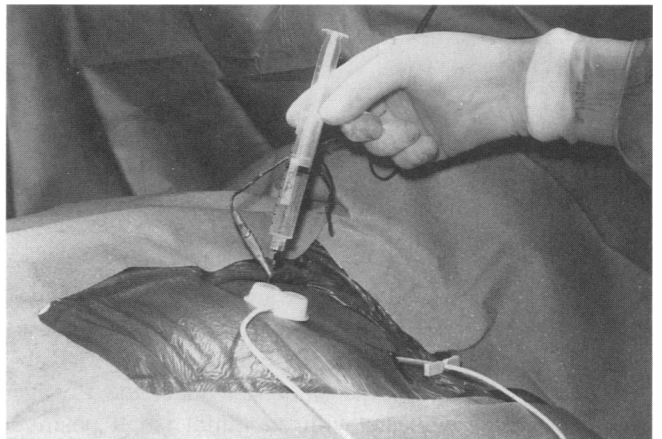


Figure 4. Attachment of alligator clamp to the non-coring needle placed in one chamber of the subcutaneous port. If an external catheter was used, the alligator clamp was attached to a metal stopcock placed in the end of the catheter.

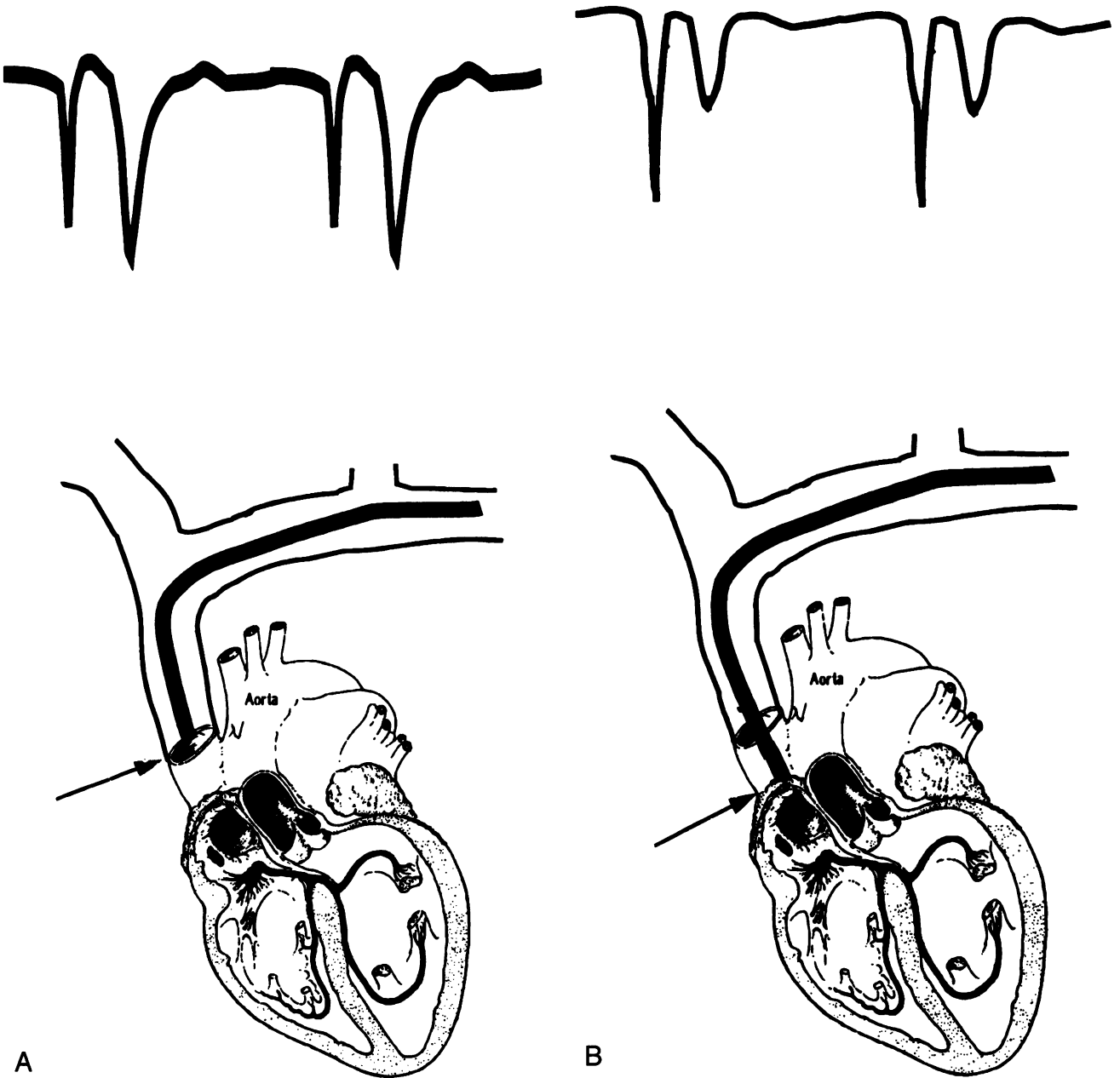


Figure 5. Progression of P-wave signal during passage of catheter into right atrium. (A) Catheter tip in superior vena cava. (B) Catheter tip just proximal to sinoatrial node of right atrium.

P-wave was noted to be negative (Fig. 5A). As the catheter tip was advanced further toward the sinoatrial node, the P-wave increased in negative amplitude until it was as large or larger than the QRS complex (Fig. 5B). As the catheter tip passed the sinoatrial node, the P-wave became slightly biphasic with an initial small positive deflection (Fig. 5C). As the catheter tip proceeded into the midatrium, the P-wave became biphasic with an equal positive and negative deflection (Fig. 5D). If advanced further, the P-wave became totally positive (Fig. 5E). If

the catheter tip entered the right ventricle, the electrical pattern was intensified greatly in its deflection. If the tip of the catheter entered the internal jugular vein, the opposite subclavian vein, or the internal mammary vein, the ECG pattern was attenuated, and the P-wave did not show the marked negative deflection with subsequent biphasic pattern as the catheter was advanced. In this event, fluoroscopy had to be used. This event occurred in 18 cases. After satisfactory positioning of the catheter, the split catheter sheath was removed, and the catheter tip position

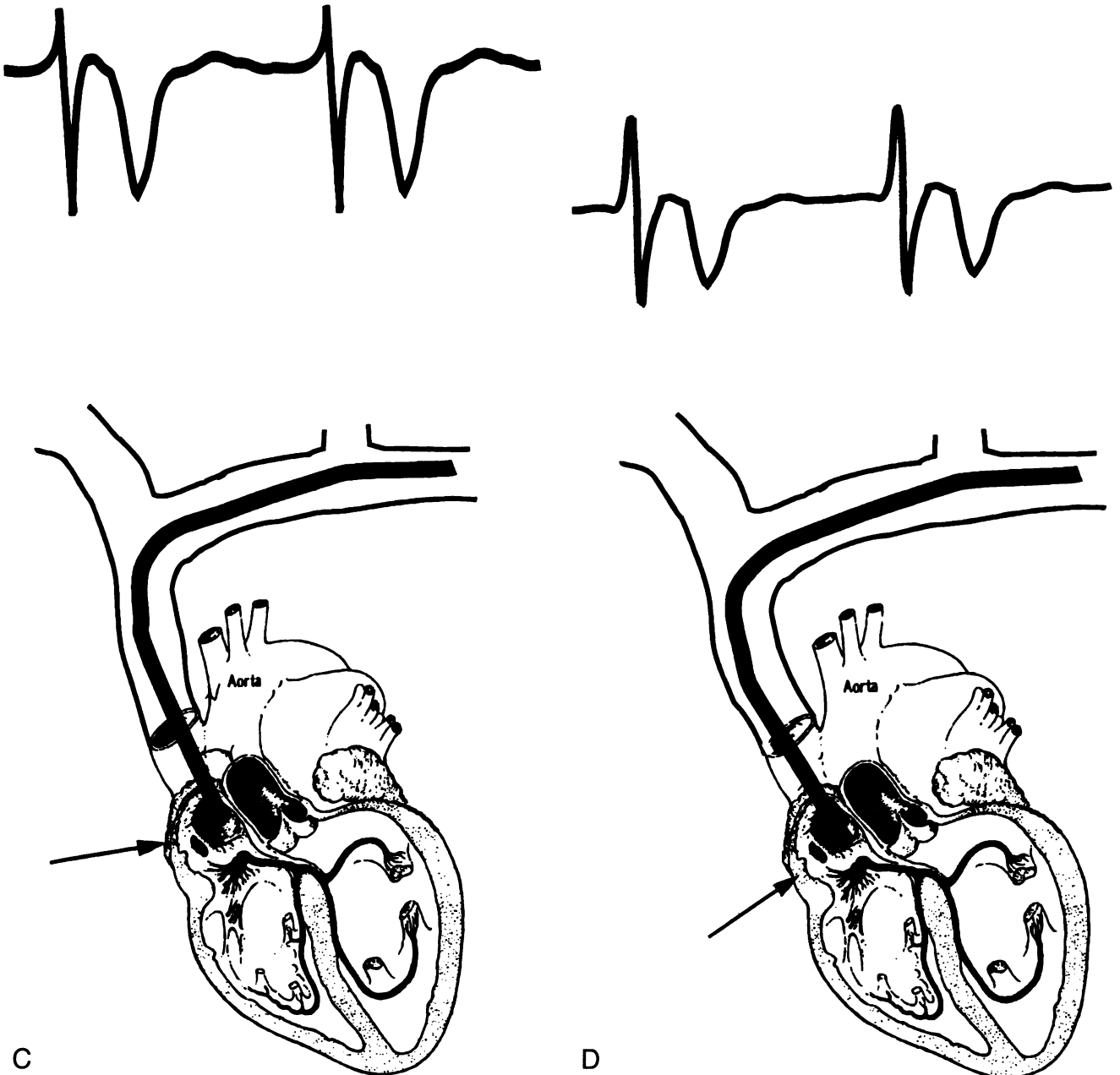


Figure 5 continued (C) Catheter tip just past the sinoatrial node into the right atrium. (D) Catheter tip at desired position, midway between the sinoatrial node and the atrioventricular node.

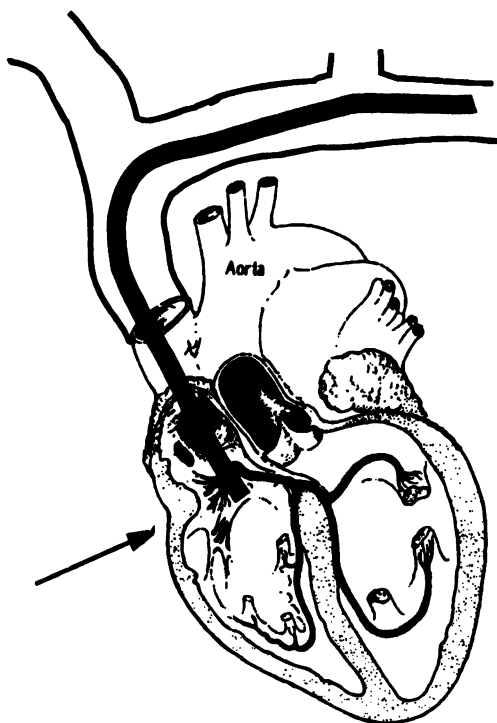

was reconfirmed to ensure it had not been dislodged. The incisions were closed with an absorbable suture at the clavicle, and a 4-0 Nylon suture was placed at the catheter exit site, tying the tails of the suture around the catheter to secure it in place until the tissue in-growth cuff became anchored to the subcutaneous tissues. Sterile dressings were applied.

If the catheter was to be attached to a subcutaneous port, a subcutaneous pocket was fashioned on the anterior chest wall just large enough for the chamber. The catheter

was tunneled from the incision at the clavicle under the skin into the subcutaneous pocket, cut to length, and attached to the subcutaneous port. The port was secured to the fascia with a nonabsorbable suture to prevent migration. The incisions were closed using absorbable sutures. Sterile dressings were applied.

RESULTS

We compared results using the ECG method in the placement of 1236 catheters with the results using the



E

Figure 5 continued (E) Catheter tip advanced too far, approaching the bottom of the right atrium.

fluoroscopic method in the placement of 586 catheters. The position of the catheter tip relative to the junction of the superior vena cava and the right atrium was measured from routine portable, semiupright, postoperative chest x-rays. Both the fluoroscopic and the ECG method of catheter placement resulted in accurate positioning of the catheter tip within the right atrium, with the average position for ECG placement being 1.9 ± 1.3 cm within the right atrium and the average position for fluoroscopic placement being 1.1 ± 1.6 cm. Optimal catheter tip location was thought to be achieved when the P-wave pattern was biphasic.

After catheter placement, a pneumothorax developed

in nine patients, of whom four required placement of a chest tube for 3 to 7 days. A delayed pneumothorax developed in two patients, one at 24 hours and one at 8 days. Both patients required chest tube placement. Four pneumothoraces occurred with the ECG placement method and five with the fluoroscopic method.

An average of 20 seconds (range, 10–120 seconds) of x-ray exposure was required when fluoroscopy was used. The ECG method, avoiding fluoroscopy, used an average of 3.0 minutes less operating room time (44.4 ± 14.9 minutes vs. 47.4 ± 18.0 minutes; $p < 0.04$). The time required for placement of an external catheter was reduced from 42.4 ± 16.1 minutes for fluoroscopic placement to 40.8 ± 11.9 minutes for the ECG method ($p =$ not significant), and the time for placement of a subcutaneous port was reduced from 52.7 ± 16.6 minutes to 47.3 ± 12.6 minutes ($p < 0.009$). The reduction in operating room time and the elimination of fluoroscopy and any contrast material resulted in an average total cost savings of \$279.10 per patient.

Although of potential benefit, the elimination of fluoroscopy and its possible contamination of the operative site was not noted to alter postoperative infectious complications. No postoperative wound infections were observed in either group.

DISCUSSION

Correct positioning of central venous access catheters is important to avoid complications such as venous thrombosis, interval catheter migration, and occlusion of the catheter tip by the venous wall during blood sampling and to enhance safe administration of irritating solutions. We prefer the catheter tip to be just within the right atrium. This study was designed to evaluate a nonfluoroscopic method for proper catheter placement.

Application of the ECG method to catheter placement is dependent on the presence of a P-wave. The method cannot be used in patients with cardiac dysrhythmias resulting in altered P-wave tracings, such as patients with atrial fibrillation and those with functioning cardiac pacemakers. Occasionally, patients with cardiomyopathy have an uninterpretable P-wave as well. In these patients, and in patients in whom the P-wave does not progress as expected, fluoroscopy should be used to assist in positioning the catheter tip correctly.

We used sodium bicarbonate as an electrolyte solution because of its ready availability in the operating room and its low cost. Rarely was more than 10 mL required, and no impact on acid base balance was observed. A 3% sodium chloride solution also would be satisfactory.

We had an occasional problem with 60-cycle interference in the ECG, usually occurring with the more sensitive ECG monitors. A common cause for 60-cycle inter-

ference was loss of good skin contact of the ECG pads, and changing the pads often helped. Interference also may occur because of electrical devices, and disconnecting them may help. Finally, some operating rooms have high 60-cycle noise that cannot be eliminated. Therefore, the ECG method is recommended as a satisfactory alternative to the fluoroscopic method for placement of long-term central venous catheters.

References

1. Heimbach DM, Ivey TD. Technique for placement of a permanent home hyperalimentation catheter. *Surg Gynecol Obstet* 1976; 143:634–636.
2. Vander Salm TJ, Fitzpatrick GF. New technique for placement of long-term venous catheters. *JPEN J Parenter Enteral Nutr* 1981; 5:326–327.
3. Battro A, Bidoggia H. Endocardiac electrocardiogram obtained by heart catheterization in man. *Am Heart J* 1947; 33:604–632.
4. Serafini G, Pietrobono P, Parigi GB, Cornara G. Positioning of a central venous catheter in children by intracavitary ECG. A new technique. *Minerva Anesthesiol* 1985; 51:289–291.
5. Wilson RG, Gaer JA. Right atrial electrocardiography in placement of central venous catheters. *Lancet* 1988; 1:462–463.
6. Luks FI, Picard DL, Pizzi WF. Electrocardiographic guidance for percutaneous placement of central venous catheters. *Surg Gynecol Obstet* 1989; 169:157–158.
7. Francis KR, Picard DL, Fajardo MA, Pizzi WF. Avoiding complications and decreasing costs of central venous catheter placement utilizing electrocardiographic guidance. *Surgery* 1992; 175:208–211.
8. Wilson S, Sparks W, Williams V, Grant J. Modification of patient positioning for subclavian catheter insertion. *JPEN J Parenter Enteral Nutr* 1990; 14(Suppl. 1):17S.
9. Grant JP. *Handbook of Total Parenteral Nutrition*. 2nd ed. Philadelphia: WB Saunders Co; 1992:333–339.