

# Surgical Decision-Making Affected By Clinical and Genetic Screening of a Novel Kindred With Von Hippel-Lindau Disease and Pancreatic Islet Cell Tumors

Steven A. Curley, M.D.,\* Steven T. Lott, B.S.,† James W. Luca, M.S.,†  
Marsha L. Frazier, Ph.D.,‡ and Ann M. Killary, Ph.D.†

*From the Departments of Surgical Oncology,\* Laboratory Medicine,† and Medical Oncology,‡ The University of Texas M. D. Anderson Cancer Center, Houston, Texas*

---

## Objective

We report a unique, previously undescribed multigeneration kindred with von Hippel-Lindau (VHL) disease in whom clinical or genetic screening led to the detection of surgically resectable neoplastic disease in several family members.

## Summary Background Data

Patients with VHL disease have a propensity to develop neoplasms of several different organ sites. Retinal angiomas, cerebellar and spinal hemangioblastomas, solid organ cysts, and renal carcinoma are common lesions; pheochromocytomas and pancreatic islet cell tumors occur less frequently but are important causes of morbidity and mortality.

## Methods

A detailed pedigree was constructed based on clinical screening and family history that describes the development of pancreatic islet cell tumors in four of five female siblings. VHL mutation analysis was performed in an attempt to determine if genotype–phenotype correlations could be made in this interesting family.

## Results

The age of onset of VHL-associated neoplasms for three affected siblings was in the third decade of life and in the fourth decade for the fourth sibling. The mother of the four siblings affected with pancreatic tumors developed bilateral pheochromocytomas in the seventh decade of life; she has no pancreatic or kidney tumors. We identified maternal transmission of a missense mutation in codon 238 in exon 3 of the VHL gene in the four affected siblings with pancreatic islet cell tumors. Mutation screening on unaffected family members showed no abnormalities in the VHL gene. Interestingly, one of the four affected siblings had no evidence of VHL on her initial clinical screening evaluation; however, she was followed closely because of her mutated VHL gene. Four years after initial screening, she developed two pancreatic islet cell tumors and a premalignant renal cyst.

## Conclusions

Clinical and genetic screening for VHL in this family had a significant impact on surgical management by detecting early-stage islet cell tumors or pheochromocytomas. Furthermore, we conclude that the preponderance of pancreatic islet cell tumors in this family cannot be explained by a strict genotype–phenotype correlation. This suggests that additional genetic abnormalities, possibly on chromosome 3p where the VHL gene is located, may be responsible for the variety of VHL-associated neoplasms.

Eugene von Hippel described a patient with “angiomas retinae” in 1895, and Arvid Lindau in 1926 recognized the eye and central nervous system (CNS) manifestations of the disease that bears their names.<sup>1,2</sup> Von Hippel-Lindau (VHL) disease is an autosomal dominant, pleomorphic disorder with almost complete penetrance characterized by a predisposition to develop several types of neoplasms. The tumors most frequently associated with VHL are hemangioblastoma of the CNS and retina, renal cell carcinoma, and pheochromocytoma.<sup>3,4</sup> Renal and pancreatic cysts are common manifestations of VHL; cystic or solid lesions of the liver, spleen, epididymis, and ovary occur infrequently.<sup>5</sup> Pancreatic cysts are seen in 15% to 38% of VHL patients, but solid pancreatic tumors (adenomas, islet cell tumors, and rarely adenocarcinomas) are noted in <10% of patients.<sup>6,7</sup> The incidence of VHL disease is approximately 1:36,000.<sup>8</sup>

Genetic linkage analysis indicated that the gene responsible for VHL was located on the short arm of chromosome 3, within the 3p25-p26 region.<sup>9–11</sup> Nucleotide sequence analysis after cloning of the VHL gene demonstrates a high degree of conservation across diverse species, suggesting a fundamental cellular function for the VHL gene product. Recently, an important function for the VHL gene in inhibition of transcription elongation was described.<sup>12</sup> Somatic VHL gene mutations have also been detected in 57% of sporadic, nonpapillary renal cell carcinomas.<sup>13</sup> Additionally, VHL gene mutations occur at lower frequencies in sporadic hemangioblastomas and lung carcinomas.<sup>14,15</sup> Mutation of VHL codon 238 (Arg-Gln and Arg-Trp) has been correlated with a high incidence (62%) of development of pheochromocytomas.<sup>16</sup> It has been suggested that this genotype–phenotype correlation is critical in screening for VHL-associated pheochromocytomas and in early onset of pheochromocytomas not associated with VHL. However, mutation analysis in VHL-associated neoplasms to establish specific genotype–phenotype correlations has revealed few definitive

criteria. It is possible that other genes may be involved in a cooperative manner with the VHL gene to give rise to the variety of benign and malignant lesions observed in affected persons.

We report a novel, previously undescribed multigeneration kindred with VHL disease. Three female siblings presented with malignant nonfunctioning pancreatic islet cell tumors, and a fourth female sibling developed islet cell tumors during follow-up. The mother of these four siblings is the only person in the three-generation family to develop pheochromocytoma; there is no family history or current evidence of renal cell carcinoma. The rest of the affected persons from this kindred presented with retinal angiomas, CNS hemangioblastomas, or both. This novel kindred presented a unique opportunity to address both specific genotype–phenotype correlations associated with the onset of VHL disease and the impact of clinical and genetic screening on the surgical management of VHL-associated neoplasms.

## METHODS

### Von Hippel-Lindau Screening

After presentation of the index case from this family, a detailed family history was obtained from other family members. The clinical diagnosis of VHL disease was based on established criteria.<sup>4,17,18</sup> All living first- and second-degree family members were contacted; they underwent ophthalmologic evaluation, magnetic resonance imaging (MRI) of the brain and spinal cord, and abdominal ultrasound examination. Family members diagnosed with VHL disease underwent computed tomography (CT) of the abdomen and pelvis. The three most recent generations of the family were born in a single small town; hospital and autopsy reports were available on three of the five deceased persons.

A complete serum pancreatic profile (pancreatic oncofetal antigen, vasoactive intestinal peptide, pancreatic polypeptide, somatostatin, neurotensin, C-peptide, glucagon, gastrin, amylase, and glucose) was obtained for all affected family members. Serum parathyroid hormone, prolactin, calcium, cortisol, adrenocorticotrophic hormone, calcitonin, and serum and urine catecholamine levels were also measured.

Supported by National Cancer Institute Grants RR04999-01, CA62027-02, and the John S. Dunn Research Foundation.

Address reprint requests to Steven A. Curley, M.D., Department of Surgical Oncology—Box 106, The University of Texas M. D. Anderson Cancer Center, 1515 Holcombe Blvd., Houston, TX 77030.

Accepted for publication February 6, 1997.

## Mutation Screening

Blood samples from family members were subjected to VHL mutation analysis regardless of whether they had clinical evidence of VHL disease. The four siblings who underwent surgery for pancreatic islet cell tumors and their mother, who underwent bilateral adrenalectomy for pheochromocytomas, had tumor tissue samples subjected to genetic analysis. Two family members who had no clinical evidence of VHL provided blood samples for mutation analysis.

DNA was isolated from peripheral lymphocytes of persons from the affected kindred using a high salt technique.<sup>19</sup> Primers corresponding to each of the three exons of the VHL gene were manufactured by Genosys (Genosys Biotechnologies, The Woodlands, TX). Polymerase chain reaction (PCR) amplification was carried out according to published conditions.<sup>20</sup> Amplification products were electrophoresed in a 2% NuSieve (FML Corp., Rockland, ME) low-melting-point agarose gel. Bands corresponding to each amplified exon were cut from the gel and purified with the Qiagen PCR Prep Kit (Qiagen Inc., Chatsworth, CA). Sequencing was then performed using the Delta Taq Cycle Sequencing Kit (U.S. Biologicals, Cleveland, OH). Reaction products were analyzed on a 6% denaturing acrylamide gel.

Initially, PCR products were examined by single-strand conformation analysis to identify exons with mutations. This was accomplished by incorporating  $\alpha^{32}\text{P}$  dCTP during PCR amplification, denaturing the PCR amplicons, and then performing electrophoretic separation on a 6% nondenaturing MDE Hydrolink (J.T. Baker Co., Phillipsburg, NJ) acrylamide gel. After electrophoresis, the acrylamide gels were exposed to autoradiography film for 24 to 72 hours. To identify specific mutations, sequencing of exons was performed.

## RESULTS

### Family Description

The proband at age 29 years presented to an ophthalmologist complaining of blurred vision in the right eye. Retinal examination revealed bilateral retinal angiomas. MRI of the brain and spinal cord revealed a midline cerebellar vascular tumor consistent with a hemangioblastoma. Three months later, the patient presented with a 1-week history of abdominal pain. Abdominal CT revealed a 5-cm pancreatic head mass. Cytologic analysis of a fine-needle aspiration specimen was consistent with islet cell neoplasm. The patient had no symptoms or signs of an endocrine syndrome, there were no abnormal values on serum pancreatic and endocrine tests, and serum and urinary catecholamine levels were normal. There was no evidence of metastatic disease on the preoperative screen-

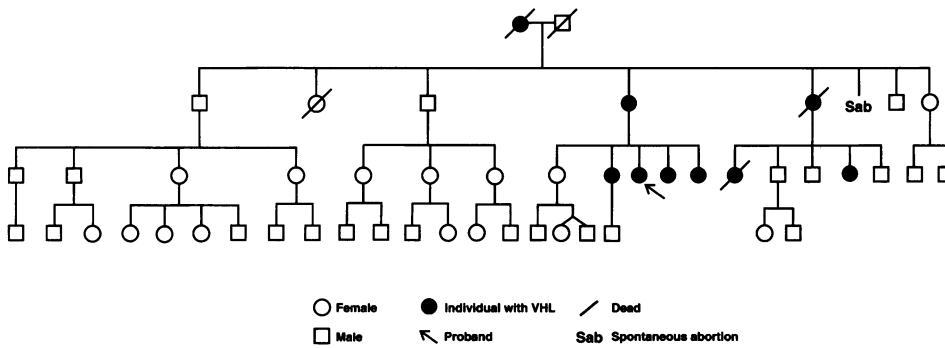
ing evaluation, but at laparotomy multiple 1- to 2-mm bilobar liver lesions were discovered and histologically confirmed to be metastatic islet cell cancer. The primary pancreatic tumor was unresectable because of involvement of the superior mesenteric artery.

Four months after the operation on the index patient, her youngest sibling presented with a 2-week history of abdominal pain, nausea, and vomiting. Retinal examination showed bilateral angiomas; MRI of the brain and spinal cord was normal. Abdominal CT demonstrated a pancreatic head mass with duodenal compression. This patient had normal values on a complete serum pancreatic profile and on serum and urine endocrine studies. She underwent surgery and had multiple 1- to 2-mm bilobar liver lesions, which were histologically confirmed to be metastatic islet cell cancer. Biopsies of the primary pancreatic tumor that involved the superior mesenteric artery also demonstrated an islet cell neoplasm. A loop gastrojejunostomy was performed to bypass the duodenal obstruction.

The three other female siblings of the proband were evaluated. The elder two siblings had no clinical evidence of VHL (the second-eldest sibling had only bilateral, small ovarian cysts), but the third (fourth child in the family) had a 3-cm solid pancreatic head tumor and bilateral renal cysts. She had no retinal or CNS abnormalities. Like her two sisters, she had no clinical or laboratory evidence of a functioning endocrine tumor. At operation, the tumor was confined to the uncinate process of the pancreas with no evidence of metastases or vascular encasement; a pancreaticoduodenectomy was performed. Final pathologic examination confirmed the diagnosis of an islet cell neoplasm. Fluid aspirated from the bilateral renal cysts during the operation showed no evidence of malignant cells.

Because the second sibling had a point mutation in the VHL gene identical to her three younger sisters, she was followed annually with an eye examination, MRI of the spine and head, and CT of the abdomen and pelvis. Four years after her initial screening evaluation, CT revealed two hypervascular pancreatic head tumors <1 cm in diameter, a complex left renal cyst, and enlarged bilateral ovarian cysts. Serum and urine laboratory tests were normal. A pancreaticoduodenectomy and left heminephrectomy was performed, revealing two <1-cm islet cell tumors and a complex renal cyst with severe cellular atypia but no invasive malignancy. There was no evidence of metastatic foci of islet cell malignancy.

The two sisters who had unresectable primary pancreatic tumors and liver metastases were treated on protocol with external beam irradiation to the pancreas followed by systemic chemotherapy with 5-fluorouracil and doxorubicin. The primary pancreatic tumors have been stable for >4 years and there has been minimal progression in the liver metastases. All four siblings are alive and asymptomatic.



**Figure 1.** A simplified pedigree of the described family affected with von Hippel-Lindau (VHL) disease. The four affected female siblings have developed nonfunctioning pancreatic islet cell tumors. Their mother developed bilateral adrenal pheochromocytomas.

In constructing the VHL pedigree, we inferred that the maternal grandmother of the proband was the initiating case (Fig. 1). She developed progressive deterioration of her sight beginning at age 32 years and by age 36 years had complete bilateral blindness. She died suddenly at age 68 years, and an autopsy revealed acute hemorrhage into and around a vascular tumor in the fourth ventricle. Her husband lived to age 61 years and died of a myocardial infarction with no evidence of VHL.

The proband's mother had bilateral retinal angiomas but no CNS abnormalities at initial screening. Two small pancreatic cysts were noted on ultrasound and abdominal CT, but no other visceral abnormalities were detected. She was normotensive at initial screening with normal urinary catecholamine levels. However, 30 months after her evaluation, her blood pressure was 170/90 mmHg; serum and urine catecholamine levels were elevated 3 times above normal values, but all other laboratory values were normal. CT demonstrated hypervascular 2-cm right and 2.5-cm left adrenal tumors. After preoperative adrenergic blockade, she underwent bilateral adrenalectomy with sparing of the superior rim of the left adrenal cortex. Pathologic evaluation demonstrated bilateral adrenal pheochromocytomas. She is again normotensive and does not require steroid replacement medication.

The elder female sibling of the proband's mother died at age 1 year from pneumonia. The immediate younger female sibling died suddenly at age 51 years; autopsy showed hemorrhage into a large cerebellar hemangioblastoma (see Fig. 1). Two of the five children of this latter woman are affected by VHL. The elder female child died suddenly at age 25 years from hemorrhage into a cerebellar hemangioblastoma. The younger female has only bilateral retinal angiomas and multiple pancreatic cysts. The final living four siblings of the proband's mother and their children and grandchildren have no clinical or radiographic evidence of VHL.

**VHL Mutation Screening**

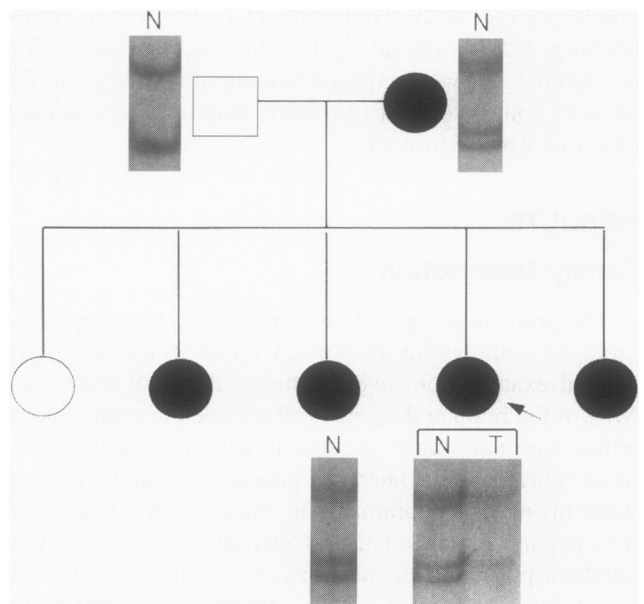
Single-strand conformation analysis of the VHL gene in this pedigree identified an aberrantly migrating band

in affected persons in exon 3 (Fig. 2). In addition, amplification of DNA extracted from the proband's pancreatic islet cell tumor revealed the presence of only one band, corresponding to the mutated allele of the VHL gene. This demonstrates loss of heterozygosity at the VHL locus in this tumor.

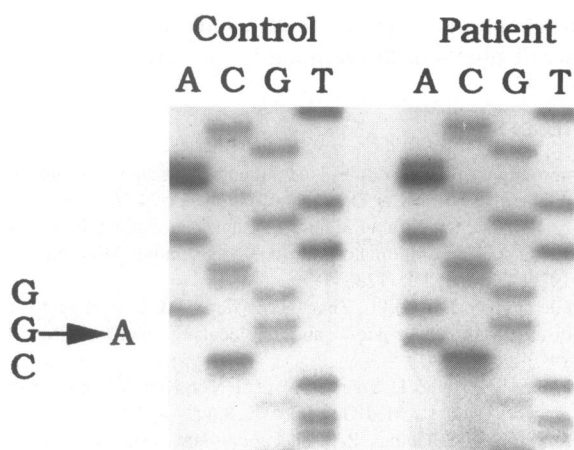
Sequence analysis of the VHL gene in affected persons revealed a missense mutation at nucleotide 713 (Fig. 3). This mutation results in a G to A transition that changes the amino acid encoded at codon 238 from arginine to a glutamine. No unaffected persons tested in this family carry the 713 G→A mutation.

**DISCUSSION**

Identification of an index case of VHL is important for the patient and the family because affected family mem-



**Figure 2.** Single-strand conformation analysis reveals an aberrantly migrating band in all persons from this novel family affected with von Hippel-Lindau disease. In the proband (arrow), loss of the wild type allele of the VHL gene is observed in the DNA extracted from her pancreatic islet cell tumor (T).



**Figure 3.** Nucleotide 713 mutation detected by sequence analysis of codon 3 of the VHL gene in the proband. The three siblings of the proband, affected with pancreatic islet cell tumors, and their mother, affected with bilateral adrenal pheochromocytomas, have identical point mutations in their VHL genes.

bers are at risk to lose vision because of retinal angiomas and may suffer morbidity or early death caused by CNS hemangioblastomas, renal cell carcinomas, or pheochromocytomas. All family members at risk must be screened immediately when VHL is diagnosed, and affected persons should undergo genetic counseling and rigorous follow-up to treat the life-threatening CNS and visceral manifestations of the disease.<sup>21</sup> The importance of screening in VHL families is underscored by the identification of a female sibling of the proband reported herein whose islet cell tumor of the pancreas was detected at a resectable stage. In addition to clinical screening, the availability of a genetic screen for germline transmission of VHL allowed the early detection of a VHL mutation in a woman in her fourth decade of life who was clinically unaffected by VHL at initial screening. During annual testing 4 years after her initial evaluation, two small pancreatic islet cell tumors and a premalignant renal lesion were detected and subsequently resected. Close follow-up of this patient, her children, and other affected family members will greatly enhance detection capabilities for early-stage neoplastic disease.

Pancreatic islet cell tumors are uncommon in VHL. There is a single previous report of clinical pancreatic islet cell tumors in siblings with VHL.<sup>22</sup> Of the four siblings with VHL in that report, two had nonfunctioning, nonmetastatic pancreatic islet cell tumors. The two sisters with locally advanced pancreatic islet cell tumors and liver metastases were treated on protocol with external beam irradiation to the pancreas followed by systemic chemotherapy. However, it is unclear that the prolonged, asymptomatic survival of these two patients is related to this treatment regimen, because many patients with malignant islet cell tumors have slowly progressing can-

cer and long survival without cytotoxic therapy. The majority of islet cell tumors in patients with VHL do not cause endocrine syndromes, but hormone production and metastasis from islet cell tumors in VHL patients has been described.<sup>23</sup>

Pheochromocytomas are more common than islet cell tumors as a neoplastic endocrine manifestation of VHL. Approximately 20% of VHL patients present with or develop pheochromocytomas, although in specific VHL families the incidence can range from 0% to 90%.<sup>21,24-26</sup> Pheochromocytomas also occur at a high frequency (40%) in another disorder with an autosomal dominant pattern of inheritance, multiple endocrine neoplasia type 2 (MEN-2). A study of 82 patients with pheochromocytomas indicated that 19 (23%) were carriers of either VHL (19%) or MEN-2 (4%).<sup>27</sup> The patients with familial pheochromocytomas were significantly younger at diagnosis and had a higher incidence of multifocal or bilateral adrenal tumors than those with sporadic pheochromocytoma. It is interesting that pheochromocytoma was the only manifestation of VHL disease in 38% of the VHL patients. Clearly, pheochromocytoma can be a major cause of morbidity and mortality; an adrenal mass in a VHL patient must be evaluated carefully for pheochromocytoma, and bilateral disease must be excluded.<sup>28-30</sup> Careful follow-up in the novel VHL kindred reported herein permitted early detection of bilateral adrenal pheochromocytomas in the mother of the four siblings with islet cell tumors before she developed complications related to poorly controlled hypertension. This patient underwent an uneventful resection of the pheochromocytomas and is now normotensive. We performed a cortical-sparing adrenalectomy of the left adrenal gland. The patient has normal postoperative plasma corticosteroid levels and does not require oral steroid replacement therapy. Her 24-hour urine catechols, vanillylmandelic acid, and metanephrine levels are normal. We have reported this cortical-sparing adrenalectomy technique in 14 patients with familial bilateral adrenal pheochromocytomas.<sup>31</sup> Thirteen of these 14 patients (93%) had normal plasma cortisol levels and adrenocorticotrophic hormone stimulation tests after surgery and did not require steroid hormone supplementation. At a median follow-up of 138 months, no patient had suffered Addisonian crisis, and 3 patients (21%) had recurrent pheochromocytomas (at 118, 176, and 324 months after operation). Long-term follow-up is necessary after cortical-sparing adrenalectomy because recurrent pheochromocytoma may develop many years after operation.

In a large study of multikindred VHL, Binkovitz et al.<sup>32</sup> reported a higher prevalence of pheochromocytoma in VHL patients with islet cell tumors (33%) than those without islet cell tumors (7%). Other reports document an association of pancreatic islet cell tumors and pheo-

chromocytoma in 63% of VHL patients.<sup>28</sup> In the multigeneration kindred presented in this report, four of five siblings were affected with pancreatic islet cell tumors, and their mother developed bilateral adrenal pheochromocytomas. We have identified a single missense VHL mutation in the family that was maternally inherited and is in a region of the gene (codon 238) thought to be correlated with an increased risk of pheochromocytoma.<sup>16</sup> In this kindred, maternal transmission of the VHL mutation that predisposed to late-onset pheochromocytoma in the mother resulted in malignant pancreatic tumors in four of her daughters. These data confirm an association between pheochromocytoma and pancreatic islet cell tumors and suggest the need for strict follow-up to monitor the siblings with pancreatic tumors for onset of pheochromocytoma. However, it is extremely interesting to note that the same mutation in the VHL gene predisposed the mother of the siblings to develop bilateral pheochromocytomas at age 63 years, even though four of her daughters were affected with pancreatic islet cell tumors before the age of 40 years. It is possible that inheritance of this point mutation in the VHL gene may predispose to late-onset pheochromocytoma; however, inheritance of the VHL mutation followed by loss of additional genetic loci may be involved in pancreatic islet cell tumorigenesis. Thus, the four siblings were predisposed to develop early-onset pancreatic islet cell tumors and may still later develop pheochromocytomas.

Other genes may be involved in a cooperative manner with the VHL gene to produce the variety of benign and malignant lesions observed in affected persons. Studies on sporadic and familial renal carcinoma suggest that genes at 3p13-p14 and 3p21.3 are involved in tumorigenesis.<sup>33</sup> Familial renal carcinoma is also characterized by a specific translocation involving 3p13-p14.<sup>34,35</sup> Functional studies in renal carcinoma cells show that introduction of a normal proximal chromosome 3p fragment results in marked tumor suppression.<sup>36</sup> To detect proximal 3p involvement in VHL-associated renal carcinoma, Kovacs et al.<sup>37</sup> examined renal carcinomas of different sizes and stages of disease in VHL patients. Loss of most of the short arm of chromosome 3 (3p13-pter) was the only genetic abnormality identified in the smallest (<1 cm) early-stage renal carcinomas. The cumulative data suggest that loss of additional 3p loci may be a prerequisite for malignant conversion in VHL-associated renal carcinoma. Based on this information, it is possible that loss of 3p alleles in addition to the VHL gene is involved in pancreatic islet cell tumorigenesis.

Further microsatellite polymorphism analyses are being performed to determine the nature of the genetic defect(s) that may follow VHL gene mutation in this family. Family members affected with VHL disease and patients with sporadic islet cell tumors are being evaluated to identify

additional tumor-suppressor genes involved in pancreatic islet cell function, differentiation, or both.

## References

1. von Hippel E. Vorstellung eines Patienten mit einer sehr ungewöhnlichen Netzhaut. *Ber Ophthalmol Ges* 1895;24:269.
2. Lindau A. Studien über Kleinhirncysten: Bau, Pathogenese und Beziehungen zur Angiomatosis retinae. *Acta Pathol Microbiol Scand* 1926;23:Suppl 1:1-128.
3. Glenn GM, Choyke PL, Zbar B, Linehan WM. Von Hippel-Lindau disease: clinical review and molecular genetics. *Prob Urol* 1990;4:312-330.
4. Maher ER, Iselius L, Yates JRW, et al. Von Hippel-Lindau disease: a genetic study. *J Med Genet* 1991;28:443-447.
5. Jennings CM, Gaines PA. The abdominal manifestation of von Hippel-Lindau disease and a radiological screening protocol for an affected family. *Clin Radiol* 1988;39:363-367.
6. Neumann HPH, Dinkel E, Brambs H, et al. Pancreatic lesions in the von Hippel-Lindau syndrome. *Gastroenterology* 1991;101:465-471.
7. Hough DM, Stephens DH, Johnson CD, Binkovitz. Pancreatic lesions in von Hippel-Lindau disease: prevalence, clinical significance, and CT findings. *Am J Roentgenol* 1994;162:1091-1094.
8. Phipps ME, Maher ER, Affara NA, et al. Physical mapping of chromosome 3p25-p26 by fluorescence in situ hybridization (FISH). *Hum Genet* 1993;92:18-22.
9. Knudson AG Jr. Genetics of human cancer. *Ann Rev Genet* 1986;20:231-251.
10. Seizinger BR, Rouleau GA, Ozelius LJ, et al. Von Hippel-Lindau disease maps to the region of chromosome 3 associated with renal cell carcinoma. *Nature* 1988;332:268-269.
11. Latif F, Tory K, Gnarr J, et al. Identification of the von Hippel-Lindau disease tumor suppressor gene. *Science* 1993;260:1317-1320.
12. Tsuchiya H, Iseda T, Hino O. Identification of a novel protein (VBP-1) binding to the von Hippel-Lindau (VHL) tumor suppressor gene product. *Cancer Res* 1996;56(13):2881-2885.
13. Gnarr JR, Tory K, Weng Y, et al. Mutations of the VHL tumour suppressor gene in renal carcinoma. *Nature Genet* 1994;7:85-90.
14. Kanno H, Kondo K, Ito S, et al. Somatic mutations of the von Hippel-Lindau tumor suppressor gene in sporadic central nervous system hemangioblastomas. *Cancer Res* 1994;54:4845-4847.
15. Sekido Y, Bader S, Latif F, et al. Molecular analysis of the von Hippel-Lindau disease tumor suppressor gene in human lung cancer cell lines. *Oncogene* 1994;9:1599-1604.
16. Crossey PA, Foster K, Richards FM, et al. Molecular genetic investigations of the mechanism of tumorigenesis in von Hippel-Lindau disease: analysis of allele loss in VHL tumours. *Hum Genet* 1994;93:53-58.
17. Melmon KL, Rosen SW. Lindau's disease. Review of the literature and study of a large kindred. *Am J Med* 1964;36:595-617.
18. Huson SM, Harper PS, Hourihan MD, et al. Cerebellar haemangioblastoma and von Hippel-Lindau disease. *Brain* 1986;109:1297-1310.
19. Schwartz CE, Ulmer J, Brown A, et al. Allan-Herndon syndrome. II. Linkage to DNA markers in Xq21. *Am J Hum Genet* 1990;47:454-458.
20. Gnarr JR, Tory K, Weng Y, et al. Mutations of the VHL tumour suppressor gene in renal carcinoma. *Nature Genetics* 1994;7:85-90.
21. Neumann HPH. Basic criteria for clinical diagnosis and genetic counselling in von Hippel-Lindau syndrome. *Vasa* 1987;16:220-226.

22. Hull MT, Warfel KA, Muller J, Higgins JT. Familial islet cell tumors in von Hippel-Lindau's disease. *Cancer* 1979;44:1523-1526.
23. Cornish D, Pont A, Minor D, Coombs JL, Bennington J. Metastatic islet cell tumor in von Hippel-Lindau disease. *Am J Med* 1984;77:147-150.
24. Atuk NO, McDonald T, Wood T, et al. Familial pheochromocytoma, hypercalcemia and von Hippel-Lindau disease: a ten-year study of a large family. *Medicine (Baltimore)* 1979;58:209-218.
25. Jennings AM, Smith C, Cole DR, et al. Von Hippel-Lindau disease in a large British family: clinicopathological features and recommendations for screening and follow-up. *Q J Med* 1988;66:233-249.
26. Lamiell JM, Salazar FG, Hsia YE. Von Hippel-Lindau disease affecting 43 members of a single kindred. *Medicine* 1989;68:1-29.
27. Neumann HPH, Berger DP, Sigmund G, et al. Pheochromocytomas, multiple endocrine neoplasia type 2, and von Hippel-Lindau disease. *N Engl J Med* 1993;329:1531-1538.
28. Aprill BS, Drake III AJ, Lasseter DH, Shakir KMM. Silent adrenal nodules in von Hippel-Lindau disease suggest pheochromocytoma. *Ann Intern Med* 1994;120:485-487.
29. Chew SL, Dacie JE, Reznik RH, et al. Bilateral pheochromocytomas in von Hippel-Lindau disease: diagnosis by adrenal vein sampling and catecholamine assay. *Q J Med* 1994;87:49-54.
30. Tisherman SE, Tisherman BG, Tisherman SA, et al. Three-decade investigation of familial pheochromocytoma. *Arch Intern Med* 1993;153:2550-2556.
31. Lee JE, Curley SA, Gagel RF, et al. Cortical-sparing adrenalectomy for patients with bilateral pheochromocytoma. *Surgery* 1996;120:1064-1070.
32. Binkovitz LA, Johnson CD, Stephens DH. Islet cell tumors in von Hippel-Lindau disease: increased prevalence and relationship to the multiple endocrine neoplasias. *Am J Roentgenol* 1990;155:501-505.
33. Yamakawa K, Takahashi E-I, Murata M, et al. Detailed mapping around the breakpoint (3:8) translocation in familial renal cell carcinoma and FRA3B. *Genomics* 1992;14:412-416.
34. Cohen AJ, Leu FP, Berg S, et al. Hereditary renal cell carcinoma associated with a chromosomal translocation. *N Engl J Med* 1979;301(11):592-595.
35. Pathak S, Strong LC, Ferrell RE, Trindale A. Familial renal cell carcinoma with a 3;11 chromosome translocation limited to tumor cells. *Science* 1982;217(3):939-941.
36. Sanchez Y, El-Naggar A, Pathak S, Killary AM. A tumor suppressor locus within 3p14-p12 mediates rapid cell death of renal cell carcinoma *in vivo*. *Proc Natl Acad Sci USA* 1994;91:3383-3387.
37. Kovacs G, Emanuel A, Neumann HPH, Kung H. Cytogenetics of renal cell carcinomas associated with von Hippel-Lindau disease. *Gen Chrom and Cancer* 1991;3:256-262.