

# Hürthle Cell Neoplasms of the Thyroid

## Are There Factors Predictive of Malignancy?

Herbert Chen, MD,\* Theresa L. Nicol, MD,† Martha A. Zeiger, MD,\* William C. Dooley, MD,\* Paul W. Ladenson, MD,‡ David S. Cooper, MD,‡ Matthew Ringel, MD,‡ Sara Parkerson, RN,\* Maria Allo, MD,§ and Robert Udelsman, MD\*

*From the Division of Endocrine and Oncologic Surgery, Department of Surgery,\* Department of Pathology,† and Division of Endocrinology and Metabolism, Department of Medicine, The Johns Hopkins Medical Institutions and The Johns Hopkins Thyroid Tumor Center, Baltimore, Maryland,‡ and the Department of Surgery, Santa Clara Valley Medical Center San Jose, California§*

### Objective

To determine if any preoperative or intraoperative factors can reliably predict malignancy in patients with Hürthle cell neoplasms.

### Summary Background Data

Most experienced surgeons recommend total thyroidectomy for Hürthle cell carcinomas and reserve thyroid lobectomy for Hürthle cell adenomas. However, delineation between Hürthle cell adenoma versus carcinoma often cannot reliably be made either before or during surgery.

### Methods

Medical records from 57 consecutive patients who underwent thyroid resections for Hürthle cell neoplasms between October 1984 and April 1995 at The Johns Hopkins Hospital were analyzed to determine if any factors were predictive of malignancy.

### Results

Of the 57 patients with Hürthle cell neoplasms, 37 had adenomas and 20 had carcinomas, resulting in a 35% prevalence

of malignancy. Patients with adenomas did not differ from those with carcinoma with respect to age, sex, or history of head and neck irradiation. However, patients with Hürthle cell carcinomas had significantly larger tumors ( $4.0 \pm 0.4$  cm vs.  $2.4 \pm 0.2$  cm,  $p < 0.005$ ). Furthermore, although the incidence of malignancy was only 17% for tumors 1 cm or less and 23% for tumors 1 to 4 cm, tumors 4 cm or greater were malignant 65% of the time ( $p < 0.05$ ). Both fine-needle aspiration and intraoperative frozen section analysis had low sensitivities in the detection of cancer (16% and 23%, respectively). With up to 9 years of follow-up, there has been no tumor-related mortality.

### Conclusions

These data demonstrate that the size of a Hürthle cell neoplasm is predictive of malignancy. Therefore, at the time of initial exploration for large Hürthle cell neoplasms ( $>4$  cm), definitive resection involving both thyroid lobes should be considered because of the higher probability of malignancy.

Hürthle cell adenomas and carcinomas are uncommon, representing 3% to 10% of epithelial thyroid tumors and accounting for only 15% to 20% and 2% to 8% of follicular and papillary cancers, respectively.<sup>1,2</sup> Thus, few institutions have extensive experience with Hürthle cell neoplasms.

Earlier studies suggested that the clinical behavior of

these neoplasms was unpredictable.<sup>3,4</sup> Subsequent investigators have shown that the distinction between Hürthle cell adenomas and carcinomas can be made on permanent histology based on the fact that capsular or vascular invasion occurs exclusively in carcinomas.<sup>5-7</sup> Furthermore, Hürthle cell carcinomas have been reported to behave in a more aggressive fashion than other well-differentiated thyroid cancers, as evidenced by a higher incidence of metastases and a lower survival rate.<sup>4,8,9</sup> In addition, they have decreased avidity for <sup>131</sup>I.<sup>4,8,9</sup> Accordingly, most experienced surgeons recommend aggressive surgical treatment of Hürthle cell carcinomas, usually in the form of a total

Address correspondence and reprint requests to Robert Udelsman, MD, Director of Endocrine and Oncologic Surgery, Blalock 688, The Johns Hopkins Hospital, 600 N. Wolfe St., Baltimore, MD 21287.

Accepted for publication October 7, 1997.

thyroidectomy.<sup>1,9-11</sup> In contrast, Hürthle cell adenomas are generally treated with a thyroid lobectomy.<sup>1,9-11</sup>

Complicating this decision-making paradigm is the inability to distinguish between Hürthle cell adenomas and carcinomas either before or during surgery. Although both fine-needle aspiration (FNA) and frozen-section analysis can detect the presence of a Hürthle cell neoplasm, they cannot reliably distinguish between an adenoma and a carcinoma.<sup>1,11-13</sup> Therefore, to determine what preoperative or intraoperative factors can be predictive of malignancy, we reviewed our experience with Hürthle cell neoplasms over a 9.5-year period.

## METHODS

Patients who underwent thyroidectomy at The Johns Hopkins Hospital for a Hürthle cell neoplasm between October 1984 and April 1995 were identified from The Johns Hopkins Hospital pathology database. A Hürthle cell neoplasm was defined as an encapsulated thyroid lesion consisting of at least 50% Hürthle cells.<sup>14</sup> The definitive diagnosis of a Hürthle cell carcinoma required the presence of vascular or capsular invasion, or both, on permanent histologic sections.

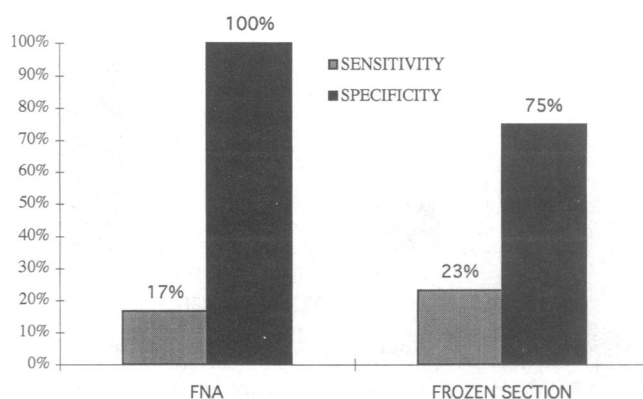
On pathologic review, 57 consecutive patients met these criteria during this interval. Medical records from these patients were retrospectively analyzed. Patient follow-up was achieved by reviewing outpatient medical records, contacting the patient's primary physician, or interviewing the patient directly at least 6 months after surgery. All FNA, frozen-section evaluation, and permanent histology results were reviewed by a single pathologist, and tumor characteristics including size, bilaterality, multicentricity, and concomitant cancers were recorded.

Statistical analysis was performed using Student's *t* test, chi square analysis, and the Mann-Whitney rank sum test when appropriate. Significance was defined as a *p* value of less than 0.05.

**Table 1. PATIENT DEMOGRAPHICS**

	Adenomas	Carcinomas	<i>p</i>
N	37	20	NA
Age (yrs)			
Median	48	56	NS
Range	5-83	21-83	
Gender			
Male	3 (8%)	3 (15%)	NS
Female	34 (92%)	17 (85%)	
Prior head and neck radiation	2 (5.4%)	1 (5.0%)	NS

NA = not applicable; NS = not significant.



**Figure 1.** Sensitivity and specificity of FNA and frozen-section analysis in the detection of Hürthle cell carcinoma.

## RESULTS

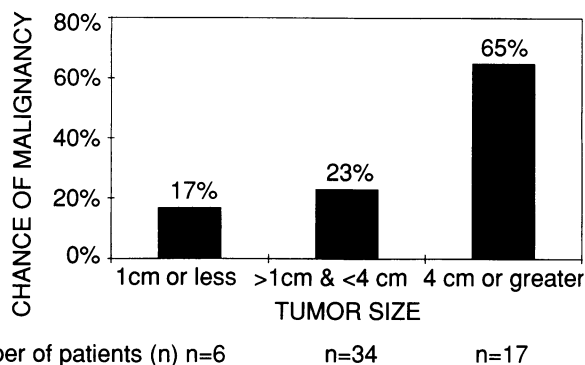
### Patient Demographics

Of the 57 patients with Hürthle cell neoplasms, 37 had adenomas and 20 had carcinomas, resulting in a 35% prevalence of malignancy (Table 1). There was no difference in median age or gender between the two groups. Of the patients with adenomas, the median age was 48 years (range 15 to 83 years), and 8% were male. Of the patients with carcinomas, the median age was 56 years (range 21 to 83 years), and 15% were male. The percentage of patients in both groups who had a previous history of head and neck irradiation was similar (adenoma 5.4%, carcinoma 5%).

### Diagnostic Studies

Of the 57 patients, 36 had adequate preoperative FNAs. Of these, 33 were reported as a Hürthle cell neoplasm (permanent histologic diagnosis: 23 Hürthle cell adenomas, 10 Hürthle cell carcinomas), 1 was interpreted as Hashimoto's thyroiditis (permanent histologic diagnosis: Hürthle cell adenoma), 1 was suspicious for malignancy (permanent histologic diagnosis: Hürthle cell carcinoma), and 1 was diagnostic of papillary thyroid cancer (permanent histologic diagnosis: Hürthle cell carcinoma). Thus, in patients with Hürthle cell neoplasms, FNA had a 16% sensitivity and a 100% specificity for cancer (Fig. 1).

Forty-one patients had intraoperative frozen-section analysis. Of these, 37 were interpreted as a "follicular neoplasm, defer diagnosis to permanent section" (permanent histologic diagnosis: 27 Hürthle cell adenomas, 10 Hürthle cell carcinomas). In four cases, capsular or vascular invasion was seen on frozen section, leading to the diagnosis of cancer on frozen section. Although three of these four patients had carcinoma on permanent histology, one did not. Thus, frozen-section analysis had a 23% sensitivity and a 75% specificity for malignancy.



**Figure 2.** With Hürthle cell neoplasms, tumor size is predictive of malignancy. With increasing tumor size, the chance of malignancy increases.

### Tumor Size Is Associated With Malignancy

The relation between Hürthle cell tumor size and malignant potential is illustrated in Figure 2. With tumors 1 cm or less, there was a 17% incidence of cancer. The risk of malignancy increased to 23% with lesions between 1 and 4 cm. However, with tumors 4 cm or greater, the chance of malignancy rose to 65% ( $p < 0.05$ ). Mean tumor size was significantly different in patients with Hürthle cell adenomas ( $2.4 \pm 0.2$  cm) versus carcinomas ( $4.0 \pm 0.4$  cm;  $p < 0.005$ ) (Table 2).

No patients in the adenoma group had bilateral Hürthle cell tumors. In the carcinoma group, three (16%) had bilateral foci of Hürthle cell carcinoma requiring total thyroidectomies for complete resection. Both groups had a low frequency of concomitant non-Hürthle cell thyroid cancers. One patient in the adenoma group had a 0.5-cm contralateral follicular variant of papillary thyroid cancer, and three patients in the carcinoma group had contralateral papillary thyroid cancers less than 1 cm.

### Patient Management

The surgical management of patients with Hürthle cell adenomas differed from those with carcinoma (Table 3).

**Table 2. TUMOR CHARACTERISTICS**

	Adenomas	Carcinomas	p
Tumor size (cm) (means $\pm$ SEM)	$2.4 \pm 0.2$	$4.0 \pm 0.4$	$<0.005$
Frequency of bilateral tumors	0 (0%)	3 (16%)*	NS
Concomitant thyroid cancers	1 (3%)†	3 (15%)‡	NS

SEM = standard error of the mean; NS = not significant.

\* In one patient, laterality of the initial tumor could not be assessed.

† 0.5 cm contralateral follicular-variant of papillary thyroid cancer.

‡ Three contralateral papillary thyroid cancer, all  $< 1$  cm in size.

**Table 3. PATIENT MANAGEMENT**

	Adenoma	Carcinoma
N	37	20
Operation		
Thyroid lobectomy/isthmusectomy	27 (73%)	1 (5%)
Total thyroidectomy	10 (27%)	19 (95%)
Initial	9	15
Completion*	1	2
+MRND	0	2
$^{131}\text{I}$ Scan	0 (0%)	15 (75%)
$^{131}\text{I}$ ablation	0 (0%)	10 (50%)
$^{131}\text{I}$ uptake beyond thyroid bed	NA	1 (5%)

MRND = modified radical neck dissection; NA = not applicable.

\* Initial thyroid lobectomy with completion thyroidectomy after the results of permanent histology.

Twenty-seven of the 37 (73%) adenoma patients had a thyroid lobectomy/isthmusectomy; the remaining 10 (27%) patients with adenomas were managed with a total or near-total thyroidectomy. Of these 10 patients, 9 had an initial total or near-total thyroidectomy and 1 patient had an initial thyroid lobectomy/isthmusectomy followed by a staged completion thyroidectomy after the results of the permanent histology were obtained. Three patients in the adenoma group had operative complications. One patient who had a total thyroidectomy had transient hypocalcemia. The other two patients had had thyroid lobectomies: one sustained a unilateral recurrent nerve injury and the other had transient hypocalcemia.

Virtually all patients (19/20, 95%) with Hürthle cell carcinomas underwent total or near-total thyroidectomies. Of these 19 patients, 15 had initial total thyroidectomies, 2 had completion total thyroidectomies after the diagnosis of carcinoma was made on permanent histology after an initial thyroid lobectomy, and 2 had total thyroidectomies with modified radical neck dissection for tumor extending beyond the thyroid capsule. One patient with a Hürthle cell

**Table 4. PATIENT OUTCOMES**

	Adenoma	Carcinoma
Follow-up (mo)		
Mean $\pm$ SEM	$49 \pm 5$	$50 \pm 6$
Median	39	42
Range	6–102	19–105
Tumor recurrences	0 (0%)	2 (11%)*
Total mortality	2 (7%)†	0 (0%)
Disease-related mortality	0 (0%)	0 (0%)

\* One patient with one episode of tumor recurrence in the neck and in an unknown location as evidenced by a rise in serum thyroglobulin and another patient with recurrence in hilar lymph nodes that was responsive to  $^{131}\text{I}$  therapy.

† Non-tumor-related deaths due to a motor vehicle accident and a primary lung cancer.

carcinoma was managed by a thyroid lobectomy only. Only one patient in the carcinoma group had an operative complication (transient hypocalcemia).

No patients in the adenoma group received postoperative  $^{131}\text{I}$  treatment. In the carcinoma group ( $n = 20$ ), 15 patients underwent postoperative  $^{131}\text{I}$  scans and 10 patients (50%) received  $^{131}\text{I}$  ablation therapy after a total thyroidectomy. However, in only one patient was  $^{131}\text{I}$  uptake noted outside the thyroid bed (pulmonary hilum).

## Patient Outcomes

Follow-up (>6 months) was available in 31 of 37 patients (84%) with adenomas and in 18 of 20 patients (90%) with carcinomas (Table 4). Mean and median follow-up times in adenoma patients were  $49 \pm 5$  and 39 months, respectively (range, 6 to 102 months). Mean and median follow-up times in carcinoma patients were  $50 \pm 6$  and 42 months, respectively (range, 19 to 105 months). There were no episodes of tumor recurrence in patients with adenomas. However, two patients (11%) in the carcinoma group had recurrent disease. One patient had one tumor recurrence in the neck managed with surgical resection and a subsequent thyroglobulin-positive recurrence in an unknown site. Another patient had a single pulmonary hilar recurrence that responded to  $^{131}\text{I}$  therapy. Two patients in the adenoma group died of nondisease-related causes (motor vehicle accident and primary lung cancer); no deaths have occurred in the carcinoma group. To date, there has been no disease-related mortality in either adenoma or carcinoma patients.

## DISCUSSION

Hürthle cells are large polygonal eosinophilic cells with pleomorphic hyperchromatic nuclei and fine granular cytoplasm containing an abundance of mitochondria. They are commonly associated with Hashimoto's thyroiditis and nodular goiters as well as with well-differentiated thyroid cancers. True Hürthle cell neoplasms are encapsulated collections of Hürthle cells. In reviewing their experience with Hürthle cell lesions, Azadian et al.<sup>11</sup> showed that of 47 patients initially thought to have Hürthle cell neoplasms, only 11 had true neoplastic lesions on re-review. Therefore, the incidence and rates of malignancy of Hürthle cell neoplasms in various institutions are highly variable; the rate of malignancy ranged from 14% to 67%.<sup>3,5,9,11,15</sup> In our series, 35% of Hürthle cell neoplasms were carcinomas.

Hürthle cell carcinomas have been reported to be more aggressive than other well-differentiated thyroid cancers due to their higher rate of metastasis, the lower survival rate, and the low probability that these cancers take up  $^{131}\text{I}$ .<sup>4,8,9</sup> However, in this series, no deaths occurred in patients with carcinoma, and only two patients had tumor recurrences during the period of follow-up. This lack of disease-related mortality and low recurrence rate could be due to our relatively short follow-up, averaging 50 months. However,

Carcangiu et al.<sup>5</sup> have shown that local recurrence of Hürthle cell carcinoma is correlated with the extent of surgery, with recurrence rates for nodulectomy, thyroid lobectomy, and total thyroidectomy of 75%, 40% and 15%, respectively. Virtually all carcinoma patients in our series were managed with a total thyroidectomy, which is different from other series in which higher mortality and recurrence rates were reported with a median follow-up of 9 years.<sup>5</sup> In the 29 patients who had a near-total or total thyroidectomy in this series, no long-term operative complications, including recurrent nerve injury or permanent hypocalcemia, were seen.

Based on these data, we agree with several authors that total or near-total thyroidectomy is indicated for Hürthle cell carcinoma, and we reserve thyroid lobectomy/isthmusectomy for adenomas.<sup>9-11</sup> The moderate number of total or near-total thyroidectomies performed in patients with adenomas in our series was due to a number of patients with a history of head and neck irradiation, the presence of bilateral nodular disease, or symptoms due to a concomitant goiter. In one case, a completion total thyroidectomy was performed early in the series due to data from the University of Michigan indicating that the biologic behavior of Hürthle cell lesions was unpredictable.<sup>3</sup>

The role of  $^{131}\text{I}$  therapy in the treatment of Hürthle cell carcinoma is unclear. We selectively treat patients with carcinoma after near-total or total thyroidectomy with  $^{131}\text{I}$  therapy to ablate residual thyroid tissue. Although most Hürthle cell neoplasms are not responsive to  $^{131}\text{I}$ , most secrete thyroglobulin, which can be used to detect recurrent disease. Furthermore, some metastases from Hürthle cell carcinomas have been reported to be responsive to  $^{131}\text{I}$ ,<sup>9,16</sup> and in our series one patient with recurrent disease was  $^{131}\text{I}$  avid.

Several studies have shown that FNA can reliably recognize Hürthle cell neoplasms.<sup>11,17,18</sup> However, in the vast majority of patients, the delineation between an adenoma and a carcinoma cannot be made before surgery. If the diagnosis of a Hürthle cell neoplasm is rendered by FNA, we recommend surgical evaluation and excision. In some instances, such as the two patients with carcinoma in our study, cytologic findings such as nuclear atypia suggest malignancy. In these cases, we have proceeded with an initial total thyroidectomy because of our confidence in the skill and experience of the cytopathologists at our institution. However, these instances are rare, and definitive recommendations cannot be made based on two cases.

Intraoperative frozen sections are often performed in patients with Hürthle cell neoplasms. However, we and others have shown that for follicular thyroid lesions, including Hürthle cell neoplasms, frozen-section analysis is of minimal value, rendering no additional diagnostic information 87% of the time and incorrect information 5% of the time.<sup>13,19</sup> In this series of patients with Hürthle cell neoplasms, 37 of the 41 frozen sections (90%) yielded no additional information. In the remaining four patients, the

frozen section indicated malignancy and a total thyroidectomy was performed; however, in one of the four patients, an adenoma was seen on permanent histology. Accordingly, we do not advocate routine frozen-section evaluation for Hürthle cell neoplasms.

Although FNA and intraoperative frozen-section analysis cannot reliably differentiate between Hürthle cell adenomas and carcinomas, some authors have suggested that other factors, such as increasing patient age, male sex, and childhood head and neck irradiation, are associated with an increased risk of cancer.<sup>1,5,15</sup> In this series, the ages of patients with adenomas and carcinomas were not statistically different—indeed, the ranges of ages in both the adenoma and carcinoma groups were virtually identical. Similarly, there was no gender difference between the two groups. Both groups had a similar incidence of previous head and neck irradiation (5.4% vs. 5%). Thus, these patient characteristics were not predictive of malignancy in this series.

Several authors have previously suggested that there is an increased risk of malignancy with larger Hürthle cell neoplasms.<sup>3,5,11</sup> In reviews by Thompson et al.,<sup>3,20</sup> tumor size greater than 2 cm was thought to be associated with an increased risk of malignancy. In a series of 16 Hürthle cell neoplasms reported by Azadian et al.,<sup>11</sup> the mean size was 2.3 cm for adenomas and 4.3 cm for carcinomas, suggesting an increased risk of cancer with size. However, no statistical analysis was reported. In a review of 153 Hürthle cell tumors, Carcangiu et al.<sup>5</sup> showed that no malignant tumors were less than 1 cm and no benign tumors were larger than 10 cm. Our data clearly demonstrate that Hürthle cell tumor size is predictive of malignancy. Adenomas were on average smaller than carcinomas (2.4 cm vs. 4 cm). Furthermore, although tumors 1 cm or less were malignant 17% of the time, 65% of tumors 4 cm or greater were malignant. It is nevertheless noteworthy that Hürthle cell tumors 1 cm or less can still be malignant.

These findings have led us to modify our surgical approach to Hürthle cell tumors. If a patient has a thyroid nodule with an FNA demonstrating a Hürthle cell neoplasm, we consider this an indication for operative exploration. If the tumor is 4 cm or greater on intraoperative gross inspection, based on the data presented in this paper, we would consider performing a total or near-total thyroidectomy because of the high risk of cancer. During surgery, if there is evidence of malignant disease (*i.e.*, tumor invasion into adjacent structure, nodal disease) or contralateral nodular disease, or if the patient has a history of head and neck irradiation, we would advocate an initial total or near-total thyroidectomy. However, if none of these findings is present and the tumor is less than 4 cm, we perform an ipsilateral thyroid lobectomy/isthmusectomy and await permanent his-

tologic analysis. If permanent histology is diagnostic of carcinoma, we generally perform a completion thyroidectomy as soon as possible after the initial surgery.

## Acknowledgment

The authors thank Marjorie Ewertz, RN, for her assistance.

## References

1. Chen H, Udelsman R. Hürthle cell adenoma and carcinoma. In: Clark OH, Duh QY, eds. *Textbook of Endocrine Surgery*. Philadelphia: WB Saunders; 1997.
2. Cooper DS, Schneyer CR. Follicular and Hürthle cell carcinoma of the thyroid. *Endocrinol Metab Clin North Am* 1990; 19(3):577–591.
3. Thompson NW, Dunn EL, Batsakis JG, et al. Hürthle cell lesions of the thyroid gland. *Surg Gynecol Obstet* 1974; 139:555–560.
4. McLeod MK, Thompson NW. Hürthle cell neoplasms of the thyroid. *Otol Clin North Am* 1990; 23(3):441–452.
5. Carcangiu ML, Bianchi S, Savino D, et al. Follicular Hürthle cell tumors of the thyroid. *Cancer* 1991; 68:1944–1953.
6. Grant CS, Barr D, Goellner JR, et al. Benign Hürthle cell tumors of the thyroid: a diagnosis to be trusted? *World J Surg* 1988; 12:488–495.
7. Bronner MP, LiVolsi VA. Oxyphilic (Ashanazy/Hürthle cell) tumors of the thyroid: microscopic features predict biologic behaviour. *Surg Pathol* 1988; 1:137–150.
8. Watson RG, Brennan MD, Goellner JR, et al. Invasive Hürthle cell carcinoma of the thyroid: natural history and management. *Mayo Clin Proc* 1984; 59:851–855.
9. Bondeson L, Bondeson A, Ljungberg O, et al. Oxyphil tumors of the thyroid: follow-up of 42 surgical cases. *Ann Surg* 1981; 194:677–680.
10. Gosain AK, Clark OH. Hürthle cell neoplasms. *Arch Surg* 1984; 118:529–532.
11. Azadian A, Rosen IB, Walfish PG, Asa SL. Management considerations in Hürthle cell carcinoma. *Surgery* 1995; 118:711–715.
12. Kini SR, Miller JM, Hamburger JL. Cytopathology of Hürthle cell lesions of the thyroid gland by fine needle aspiration. *Acta Cytol* 1981; 25:647–652.
13. Chen H, Nicol TL, Udelsman R. Follicular lesions of the thyroid: does frozen section evaluation alter operative management? *Ann Surg* 1995; 222:101–106.
14. Bronner MP, Clevenger CV, Edmonds PR, et al. Flow cytometric analysis of DNA content in Hürthle cell adenomas and carcinomas of the thyroid. *Am J Clin Pathol* 1988; 89:764–769.
15. Arganini M, Behar R, Wu T-C, et al. Hürthle cell tumors: a 25-year experience. *Surgery* 1986; 100:1108–1114.
16. Samaan NA, Schultz PN, Haynie TP, et al. Pulmonary metastasis of differentiated thyroid carcinoma: treatment results in 101 patients. *J Clin Endocrinol Metab* 1985; 60:376.
17. Chen H, Nicol TL, Rosenthal DL, Udelsman R. The role of fine needle aspiration in the evaluation of thyroid nodules. In: Norton JA, ed. *Problems in General Surgery: Surgery of the Thyroid Gland*. New York: Lippincott-Raven; 1997; 14:1–13.
18. McIvor NP, Freeman JL, Rosen I, et al. Value of fine-needle aspiration in the diagnosis of Hürthle cell neoplasms. *Head Neck Surg* 1993; 15:335–341.
19. Bronner MP, Hamilton R, Livolsi VA. Utility of frozen section on follicular lesions of the thyroid. *Endocrinol Pathol* 1994; 5:154–161.
20. Gundry SR, Burney RE, Thompson NW, Lloyd R. Total thyroidectomy for Hürthle cell neoplasms of the thyroid. *Arch Surg* 1983; 118:529–533.