

Repeat Ileal Pouch-Anal Anastomosis to Salvage Septic Complications of Pelvic Pouches

Clinical Outcome and Quality of Life Assessment

Victor W. Fazio, MB, MS, FRACS, FACS, James S. Wu, MD, and Ian C. Lavery, MB, BS

From the Department of Colorectal Surgery, Cleveland Clinic Foundation, Cleveland, Ohio

Objective

To evaluate the outcome of repeat ileal pouch-anal anastomosis (IPAA) for septic complications of pelvic pouch surgery; to assess the relationship between diagnosis and outcome; to assess quality of life after surgery.

Summary Background Data

Pelvic and perineal sepsis due to ileal pouch-anal anastomotic leaks frequently results in pouch loss. Many surgeons believe that pelvic sepsis and/or dense pelvic fibrosis makes salvage surgery unsafe or that pouches salvaged under these circumstances may not function well. As a result, there are few studies of pouch salvage procedures for septic indications.

Methods

The authors reviewed records of Cleveland Clinic Foundation patients who had undergone repeat IPAA surgery after septic complications from previous pelvic pouch surgery and who had completed at least 6 months of follow-up. Final diagnoses included ulcerative colitis ($n = 22$), Crohn's disease ($n = 10$), indeterminate colitis ($n = 1$), and familial polyposis ($n = 2$). Patients with functioning pouches were interviewed about functional problems and quality of life using an in-house questionnaire and the validated SF-36 Health Survey.¹

Results

Of 35 patients, 30 (86%) had a functioning pouch 6 months after repeat IPAA. In 4 patients, complications led to pouch removal or fecal diversion. One patient declined stoma closure. Of the patients with mucosal ulcerative colitis (MUC), 95% (21/22) had a functioning pouch 6 months after surgery. For patients with Crohn's disease (CD) 60% (6/10) have maintained a functioning pouch. Of the 30 patients with functioning pouches, 17 (57%) rated their quality of life as either "good" or "excellent," the remaining 13 (43%) selected "fair" or "poor." All said they would choose repeat IPAA surgery again. An SF-36 Health Survey¹ completed by all patients with a functioning pouch at follow-up showed a mean physical component scale of 46.4 and a mean mental component scale of 47.6, scores well within the normal limit.

Conclusions

Repeat IPAA can often salvage pelvic pouches in patients with MUC who suffer major chronic perianastomotic and pelvic sepsis. Patients who had successful repeat IPAA surgery often report functional problems but would still choose to have the surgery again. For patients with CD, ultimate pouch excision or fecal diversion have been required in 40% indicating a guarded prognosis for these patients. Data on the success of the procedure for patients with indeterminate colitis and familial adenomatous polyposis were inconclusive because of small sample sizes.

Since its initial description in 1978², ileal pouch-anal anastomosis (IPAA) has become an accepted treatment for mucosal ulcerative colitis (MUC) and familial adenomatous

polyposis coli. Complication rates of IPAA have declined with increased operative experience.^{3,4} Ileal pouch-anal anastomosis preserves the normal route of defecation usually with good functional results; however, complications are common, and the incidence of pouch failure ranges from 5% to 12%.⁵⁻⁷ Observation or local procedures will be sufficient to resolve some pouch-related problems, but complications that persist or recur may require radical revisional surgery to salvage the pouch. Ileoanal anastomotic disconnection, revision, and repeat IPAA are examples of such an

Presented at the 118th Annual Meeting of the American Surgical Association, April 3, 1998, Palm Beach, Florida.

Address correspondence and reprint requests to Victor W. Fazio, MB, MS, FRACS, FACS, Chairman, Department of Colon and Rectal Surgery, The Cleveland Clinic Foundation, Cleveland, Ohio 44195.

Accepted for publication April 1998.

approach that is being examined by several groups with special expertise in pelvic pouch surgery.⁸⁻¹² Such radical repeat pelvic surgery has not been popular among surgeons because of concerns about the risks of 1) injury to pelvic nerves, vascular structures, and ureters, 2) of recurrent anastomotic complications and sepsis, and 3) poor functional outcomes because of pelvic fibrosis that may encase the pouch and reduce pouch compliance. Pelvic sepsis is a feared complication because it may lead to pouch loss despite revisional surgery, and some studies have even identified pouch-related sepsis as a contraindication for repeat IPAA.¹³⁻¹⁵ In this study, we evaluated the outcome of abdominoanal revision of the ileoanal anastomosis as a salvage operation on patients with septic complications.

METHODS

Records of all patients with ileal pouch-anal anastomoses seen at the Cleveland Clinic Foundation between 1983 and March 1998 were reviewed. Patients were included in the study if they had undergone ileoanal anastomotic disconnection by a combined abdominoanal approach and repeat IPAA for septic complications. Patients were excluded if they were operated on for nonseptic complications or if they did not have at least 6 months of follow-up. We collected data on patient demographics, original diagnoses, changes in diagnoses, original pouch design, previous operations, age at repeat-pelvic surgery, institution of original surgery, complications after original surgery, procedures done before revision, findings at repeat operation, and details of operation. We noted the outcome of repeat IPAA including complications requiring pouch excision or fecal diversion, functional results, and quality of life.

Surgery was performed in the modified Trendelenburg's position with Lloyd-Davies' stirrups. Ureteral stents were used in most of the cases. A transanal approach was used at the outset to see whether a perineal approach alone was feasible and to minimize sphincter injury from the abdominal mobilization of the pouch and ileoanal anastomotic (IAA) disconnection. The previous abdominal incision was used for abdominal access. The pouch was mobilized from both abdominal and transanal approaches using sharp dissection. Typically, the pelvic dissection was started posteriorly after entering the presacral space behind the superior mesenteric vessels. The dissection then proceeded caudally, laterally, and anteriorly to the level of the *levator ani* muscles, and the surgeon took care to avoid injury to the *nervi erigentes*. After IAA disconnection, the small bowel was lifted out of the pelvis, freed of all adhesive attachments, and filled with saline to detect any defects. All enterotomies and serosal tears were repaired. Anal canal, perianal, and presacral abscess cavities were thoroughly curetted to remove all granulation tissue. Fibrotic tissue narrowing at the ano-rectal ring was removed by sharp dissection. Completion proctectomy and anal mucosectomy

Table 1. MAIN COMPLAINT BEFORE REPEAT IPAA IN 35 PATIENTS

Complaint	Patients (n)
Vaginal stool	10
Perianal abscess/fistula	9
Evacuation difficulty	8
Anal/pelvic pain	7
Fecaluria/painful erection	1

IPAA = ileo-pouch anal anastomosis.

were carried out unless they had been performed in the previous surgery.

The repeat IAA was made by sewing the pelvic pouch to the anal canal at the level of the dentate line using interrupted 2-0 polyglycolic acid suture. New pouches, when needed, were constructed in a J configuration.¹⁶ A covering loop ileostomy was placed in all cases except one. Follow-up evaluations included physical examination and pouch endoscopy and in most patients anal manometry and a water-soluble contrast enema. Loop ileostomy closure routinely was performed 3 months after redo-IPAA. Successful resolution of the problem leading to revisional surgery and pouch preservation was the primary endpoint. A secondary goal was to determine the relationship between the primary diagnosis and the outcome of repeat surgery. Patient satisfaction after redo-IPAA was assessed using the Cleveland Clinic Foundation (CCF) Pelvic Pouch Questionnaire, which assesses bowel frequency (number of bowel movements per 24 hours), urgency (inability to defer bowel movements more than 15 minutes), leakage (soiling during day or night), fecal incontinence (inadvertent passage of liquid or solid stool), need to wear pads, medication requirements, sexual function, and by the validated SF-36 Health Survey.¹

RESULTS

Of the 1680 patients who underwent restorative proctocolectomy at CCF between January 1983 and March 1998, 13 patients had undergone repeat IPAA using a combined abdominoanal approach; an additional 33 were referred from outside institutions for a total of 46 patients. Reoperations took place between 1985 and 1998, with 45 of the 46 between 1994 and 1998. Eleven patients were excluded from the study. Seven of them had undergone reoperation for septic complications within 3 months of the study and not yet had ileostomy closure. The other 4 patients had undergone reoperation for nonseptic indications (IPAA stricture 2, proctitis 1, small pelvic reservoir 1). Our study group was composed of 35 patients who had undergone reoperation for septic indications and had more than 6 months follow-up after restoration of intestinal continuity.

Table 2. PROCEDURES PERFORMED BEFORE REPEAT IPAA IN 35 PATIENTS

Complication	Procedure	Patient (n)	Procedures (n)
IPAA stricture	Dilation	9	31
Pelvic abscess	Transanal curettage abscess	7	9
Pouch vaginal fistula	Transanal advancement flap	7	11
Ano/pelvic sepsis	Reinstate ileostomy	5	5
Pelvic abscess	Laparotomy to drain pelvic abscess	5	6
Perianal abscess	I&D perianal abscess	4	11
IPAA leak	Transanal repair anastomosis	5	6
Abdominal abscess	Percutaneous drainage of abscess	3	5
Pouch vaginal fistula	Laparotomy, repair PVF	3	3
Leak-body of pouch	Laparotomy, repair fistula	1	1
Leak-body of pouch	Transanal repair	1	1
Anovaginal fistula	Fistulotomy, repair	1	1
Pelvic sepsis	Repeat IPAA	1	1

IPAA = ileo-pouch anal anastomosis; I&D = incision and drainage; PVF = pouch-vaginal fistula.

There were 14 men with a mean age of 37.8 (SD 12.5) years and 21 women with a mean age of 33.6 (SD 8.5) years. In 32 patients, the first restorative operation had been a pelvic pouch. Three patients who had their first operations performed at other institutions received a straight IAA. The first restorative proctocolectomy operation was performed at CCF in 12 cases and at other institutions in 23. The original pouch designs were J (n = 27), S (n = 5), and W (n = 1). The anastomotic technique at the original operation was: hand-sewn with mucosectomy (n = 14); double-stapled (n = 10); single stapled (n = 3); and unknown (n = 8). The median interval between first RP and abdominoanal revision was 24 months (range, 4–155). The original diagnoses were MUC (n = 33) and familial adenomatous polyposis (n = 2). After the first restorative operation, the diagnosis of 11 patients thought to have MUC was changed to Crohn's disease (CD) (10) and IC (1). All final histologic analyses were reviewed by CCF pathologists.

The most frequent symptoms indicating pouch complications are shown in Table 1. The most common were pain, fistulae, and unsatisfactory bowel function. Many patients had multiple symptoms and physical findings. Although anal or pelvic pain was not always the primary concern, it was almost always present. In all perianastomotic stricture cases, a pelvic or perianal septic event was documented before revisionary surgery.

As shown in Table 2, procedures performed in attempt to correct the pouch problem before repeat IPAA ranged from 0 to 12 (median 3). One patient had a second repeat IPAA.

IAA Disconnection and Repeat IPAA

Reoperative surgery was performed by four CCF surgeons, most (28/35) by the principal author. The findings at CCF repeat surgery are shown in Figure 1. Multiple problems were identified (Table 3). In particular, pelvic sepsis

was never an isolated finding and was always associated with other problems, such as stricture, fistulae, or anastomotic leak. Details of surgery are shown in Table 4.

FOLLOW-UP

There have been no deaths in the series to date and no intraoperative ureteral or vascular injuries. The median im-

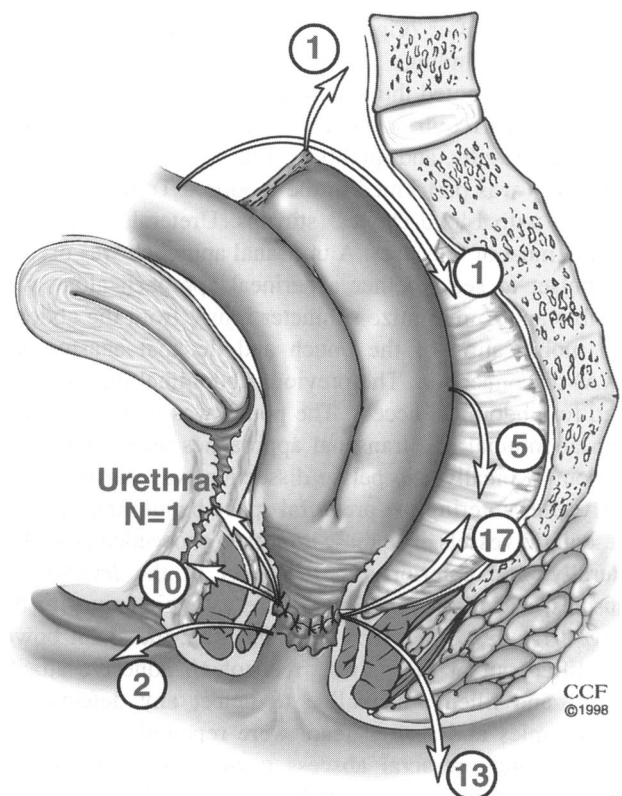


Figure 1. Intraoperative findings at repeat ileal pouch-anal anastomosis in 35 patients.

Table 3. PROBLEMS IDENTIFIED DURING REPEAT IPAA SURGERY ON 35 PATIENTS WITH SEPTIC COMPLICATIONS FROM PREVIOUS PELVIC POUCH SURGERY

Patient	IPAA Leak	Pelvic Abscess	Anal Stricture	Perianal Fistula	Pouch Vaginal Fistula	Pouch Body-Leak	Proctitis	Anovaginal Fistula	Straight IAA	Urethral Fistula	Other
1	*	*			*	2					
2	*	*		*		*	*				
3	*	*	*	*		*					
4	*	*	*	*			*				
5	*	*	*				*	*			
6	*	*		*							Entero-enteric fistula
7	*	*		*	*						
8	*		*	*	*						
9	*	*			*						Long exit conduit
10	*	*		*	*						
11	*		*		*						Twisted small bowel
12	*	*	*							*	Urethral fistula
13	*	*	*						*		
14	*	*	*								
15	*	*			*						
16	*	*	*								
17	*	*		*							
18	*			*	*						
19		*				2					
20	*	*	*								
21	*	*		*	*						
22	*	*		*							
23	*	*	*								
24		*					*		*		
25	*	*									
26		*	*								Small pouch
27	*	*									
28	*				*						
29	*			*							
30	*	*									
31		*	*								
32	*	*									
33			*								
34	*										
35								*			
Total	29	25	14	12	10	6	4	2	2	1	5

IPAA = ileo-pouch anal anastomosis; IAA = ileoanal anastomosis.

mediate postoperative hospitalization was 7 days (range, 5–24). Complications during the postoperative hospitalization included the need for perioperative transfusion in 7 patients (average, 2.7 units; range, 1–5 units), fever (n = 2), and prolonged ileus (n = 3). Intestinal continuity with greater than 6 months follow-up was achieved in 34 of 35 patients. One patient with MUC whose original operation was complicated by two leaks from the body of the pouch declined loop ileostomy closure, despite a normal pouchogram and anoscopy.

Rediversion or pouch excision has been carried out in four patients. One patient with CD had the revised pouch removed because of recurrent perianal fistulae. Three addi-

tional patients with CD whose original operations were complicated by pouch-vaginal (n = 1) or perianal fistulae (n = 2) experienced recurrent fistulae after repeat IPAA and have undergone rediversion by ileostomy. Of 22 patients with MUC, 21 have functioning pouches. To date, 30 of 35 patients (86%) have a functioning pouch. The patients have been followed for a median of 18 months (range, 6–105 months).

Several complications occurred among the 34 patients who had a functioning pelvic pouch after reoperation. Four patients developed strictures which were dilated. Two patients developed vaginal fistulas. One patient who had indeterminate colitis underwent fistula drainage using a silas-

Table 4. PROCEDURE AT REPEAT IPAA IN 35 PATIENTS

Procedure	Patients (n)
Abdominoanal mobilization of IAA	35
Ileostomy	34
Repeat IPAA: same pouch	31
Anal muscosectomy	18
Curette presacral abscess	22
Repair perianal/gluteal fistula	13
Repair vaginal fistula	12
Completion proctectomy	7
Pouch augmentation	7
Excise long exit conduit	1
Repair pouch body leaks	5
Omentopexy	3
Straight IAA to IPAA	2
Anal sphincter repair	2
Excise IPAA: new IPAA	2
Repair pouch urethral fistula	1
Repair enteroenteric fistula	1
Repair small bowel twist	1

IAA = ileoanal anastomosis; IPAA = ileo-pouch anal anastomosis.

tic seton, but declined further surgery. The second patient, who had MUC, underwent reoperation because of pelvic abscess with associated anastomotic leak and stricture. Symptoms of vaginal drainage did not appear until more than 2 years after reoperation. After a pouch advancement procedure, the fistula returned. Symptoms were then controlled medically. One patient developed a ventral hernia which was repaired. One patient developed an anal fissure and underwent a fissurectomy. The other complications, mucosal prolapse (n = 1), incontinence (n = 1), persistent painful erection (n = 1), and impotence (n = 1) are being managed without surgery at present. The salvage rate among the 35 patients in the study, divided into subgroups by diagnosis, is summarized in Table 5. The 30 patients with functioning pouches were interviewed about their quality of life using the CCF Pelvic Pouch Questionnaire, which is routinely used for all pelvic pouch patients (Table 6). Many reported functional problems. Of the 30, 21 (70%) reported seepage during the day, and 22 (73%) reported seepage at night. Nevertheless, 17 of 30 (57%) described their quality of life as excellent or good. The remaining 13 (43%) selected fair or poor. All patients said they would have salvage surgery again. An SF-36 Health Survey also was completed by all 30 patients with functioning pouches. A mean physical component scale of 46.4 and a mean mental component scale of 47.6 were found (a score of 50 is equal to the national average, standard deviation of ± 10).

DISCUSSION

Although restorative proctocolectomy has become increasingly popular in the treatment of MUC and familial

adenomatous polyposis, pouch-related complications remain common. Often local therapy will suffice for certain problems, including anastomotic stricture,¹⁷ anastomotic separation,¹⁸ anovaginal fistula,¹⁹ and pouch-vaginal fistula.²⁰⁻²³

When local procedures fail to solve a pouch-related problem, more aggressive intervention is warranted if the patient perceives that the problem is disabling. Although this intervention may require permanent fecal diversion and pouch excision, many patients will choose major restorative surgery if this is a realistic alternative.

Radical pouch revision has been performed for septic and nonseptic conditions. The two major nonseptic indications are mechanical pouch outlet obstruction and lack of reservoir capacity.¹⁰⁻¹² Many authors are concerned about the safety of repeat IPAA for sepsis, and Sagar et al.⁹ concluded that sepsis and Crohn's disease appear to be contraindications for the procedure. The sepsis of the patients in this study was characterized by a well-defined fibrotic pelvic abscess cavity lined with granulation tissue and colonized with enteric micro-organisms. Often the pouch itself comprised a wall of the abscess cavity. These changes were most commonly secondary to anastomotic disruption that resulted in chronically infected sinus tracts, pouch fistulas, and anastomotic strictures. The significance of this type of chronic sepsis is that any attempt at repair without complete eradication of the abscess cavity and inflamed tissue is unlikely to succeed. Sepsis as an indication for radical pouch revision is controversial primarily because of perceived increased risk of pouch failure. Olagunju et al.²⁴ reported their experience with 27 patients with pouch-specific complications requiring pouch salvage operations. The authors identified pelvic sepsis as a major cause of pouch failure, being present in 8 of 16 (50%) of failed salvage procedures and accounting for 7 of 12 (58%) of pouch excisions. However, when sepsis is drained and controlled, there are situations where radical surgery is advised.

Table 5. OUTCOME OF REPEAT IPAA FOR SEPSIS IN 35 PATIENTS BY DIAGNOSIS*

Diagnosis	Patients (n)	Functioning Pouch	Pouch Excised	Rediverted
Ulcerative colitis	22	21†	0	0
Crohn's disease	10	6	1	3
Indeterminate colitis	1	1	0	0
Familial polyposis	2	2	0	0

* >6 months follow-up.

† One patient declined stoma closure.

IPAA = ileo-pouch anal anastomosis.

Table 6. CLEVELAND CLINIC PELVIC POUCH FOLLOW-UP QUESTIONNAIRE RESULTS IN 30 PATIENTS*

Variable	MUC (n = 21)	IC (n = 1)	CD (n = 6)	FAP (n = 2)
Bms/24 hrs (median, range)	9.6 (4–35)	5 (5)	8.5 (8–18)	6 (6)
Urgency				
Always, n (%)	4 (19)			
Sometimes, n (%)	14 (67)	1 (100)	3 (50)	2 (100)
Never, n (%)	3 (14)		3 (50)	
Seepage				
Day, n (%)	13 (62)	1 (100)	5 (83)	2 (100)
Night, n (%)	14 (57)	1 (100)	5 (83)	2 (100)
Pads				
Day, n (%)	12 (57)	1 (100)	5 (83)	2 (100)
Night, n (%)	11 (52)	1 (100)	5 (83)	2 (100)
Dietary restriction, n (%)	11 (52)	0	5 (83)	1 (50)
Antidiarrheal medications	13 (62)	1 (100)	2 (33)	1 (50)
Other medications				
Antibiotics	2 (10)	0	2 (33)	1 (50)
Steroids	1 (5)	0	1 (17)	0
Social restriction	9 (43)	0	1 (17)	1 (50)
Impotence	1	0	0	0
Quality of life				
Good/excellent, n (%)	13 (62)	1 (100)	2 (33)	1 (50)
Fair, n (%)	7 (33)		4 (67)	1 (50)
Poor, n (%)	1 (5)			
Energy level				
Good/excellent, n (%)	11 (52)	1 (100)	3 (50)	1 (50)
Fair, n (%)	9 (43)		3 (50)	1 (50)
Poor, n (%)	1 (5)			
Would have salvage surgery again?				
Yes	21 (100)	1 (100)	6 (100)	2 (100)
No				

* Median follow-up 18 (range 6–105) months after successful repeat IPAA.

MUC = ulcerative colitis; IC = indeterminate colitis; CD = Crohn's disease; FAP = familial adenomatous polyposis; Bms = bowel movements; IPAA = ileo-pouch anal anastomosis.

Hultén⁸ reported that laparotomy with repeat IPAA is often needed to treat complex pouch-vaginal fistulas in addition to some poorly functioning pouches or those with grossly fibrotic strictures. Lindquist¹¹ reviewed 10 cases of patients with S pouches, cuff abscesses, and ileoanastomotic separations and found that major surgery with reconstruction of the pouch was necessary for definite cure in all but one patient. Poggioli et al.²¹ found pelvic sepsis in 11 of their 140 patients who had undergone RP. Five of these underwent a repeat pouch procedure with good results. In addition, the authors proposed that for patients with pelvic sepsis who undergo “minimal procedures” to cure the sepsis, pouch loss is often caused by pelvic fibrosis. Therefore, they recommend that repeat pouch procedures should be performed before pelvic fibrosis can become established.

If an existing pelvic pouch cannot be salvaged, creation of a new pelvic pouch is an option. In a recent study by Cohen et al.,²⁵ 14 of 24 pouches were salvaged with repeat surgery. The other 10 patients had a new pouch fashioned. Recently, Korsgen et al.²⁶ describe three patients in whom the original pouch was excised and a new pouch created. The indication for surgery in one patient was chronic pelvic

sepsis and IPAA stricture. We agree with the authors' admonition that the decision to excise one pouch and create a new pouch must be made carefully because the risk of a second failure carries with it the possibility of significant loss of small intestinal length. All patients were believed to have UC at the time of the original pelvic pouch operation. The diagnosis was ultimately changed to CD in 10 patients. Repeat RP was performed on two patients with histologically proven CD. Both of these patients were highly motivated to retain their pelvic pouch, and repeat IPAA was performed after a thorough discussion of the possibility of future recurrent disease. These patients have done well so far, each having 9 months of follow-up after loop ileostomy closure. In most of the cases (8/10), the diagnosis of CD was not made until after repeat IPAA. The role of RP in CD remains controversial because of the perception of an unacceptably high failure rate in these patients. However, the outcome of RP in CD is not necessarily disastrous. Hyman et al.²⁷ examined 25 patients diagnosed with CD after RP. With a mean follow-up time of 38.1 months, 16 (64%) patients had a functioning pouch. In our experience with 1005 cases of RP, a postoperative diagnosis of CD was

made in 67 patients.³ Of these, pouch removal ultimately occurred in 17 (25.4%). Although this rate is much higher than the 1.8% pouch excision rate seen among patients with MUC, most CD patients with a pelvic pouch will maintain the reservoir for a substantial period of time—not unlike the outcome of patients with ileorectal anastomosis and CD.²⁸

In this study, we examined the results of abdominoanal mobilization of an existing ileoanal anastomosis and repeat IPAA. Repeat IPAA surgeries were performed for septic indications including anastomotic dehiscence, stricture with associated pelvic abscess, and a variety of fistulae to perianal skin, vagina, buttock, and urethra. The patients were selected for major pelvic pouch revision after conservative measures or lesser procedures had either proven inadequate or seemed unlikely to resolve the patient's problem. Most patients underwent several local procedures before major revision was considered. The decision to proceed with complete pouch mobilization often was made intraoperatively when it became clear that less aggressive measures would not suffice. Based on our previous reports of local (transanal) repair of pouch and pouch-anastomotic complications, we began all revisional operations transanally.^{19,22,23} Local repair may be attempted if:

- gross sepsis and edema are absent
- the granulation tissue associated with abscess cavities is minimal and can be completely eradicated
- fistulas, if present, are close to the anal verge and thereby accessible from a transanal approach
- strictures, if present, are short.

If the above conditions are not met, then we proceed directly to laparotomy and complete pouch mobilization so that the granulation tissue and fibrotic scar can be completely excised and all pouch defects can be repaired under direct vision.

Complete pouch mobilization offers the distinct advantage of allowing all problem areas to be identified and repaired. Of the 35 patients in our study group, only 30 had been diagnosed with sepsis before surgery. Sepsis was discovered intraoperatively in the remaining five patients. Complete pouch mobilization facilitated the extensive debridement necessary to eliminate the abscess cavity. Other problems identified at reoperation that were unsuspected before repeat surgery include enteroenteric fistula ($n = 1$), enteropelvic fistula ($n = 1$), a 360° mesoaxial twisting of the small bowel ($n = 1$), and inadequate or incomplete pouch ($n = 5$). In two cases, a leak from the body of the pouch was recognized before surgery. However, it was not until reoperation, when the pouch was inspected after being lifted out of the pelvis, that a second leak was found. Finally, complete pouch mobilization permitted pouch augmentation ($n = 6$), omentopexy ($n = 2$), and reanastomosis without tension (all patients).

CONCLUSIONS

Thirty-five patients underwent repeat IPAA for septic complications after previous RP and IPAA. With a median follow-up of 18 months (range, 6–105), 30 (86%) had a functioning pouch including 96% (21/22) of patients with MUC and 60% (6/10) of patients with CD. Postoperative seepage and pad use is common but patient perception of quality of life is good to excellent in approximately half of cases. The validated SF-36 Health Survey indicates that physical and mental components are well within the national normal limits.

Repeat IPAA often can salvage pelvic pouches in patients with MUC who suffer from major chronic perianastomotic and pelvic sepsis. It is not clear from our study whether the procedure is as effective with CD, indeterminate colitis, or familial adenomatous polyposis. Patients who had successful repeat IPAA often report functional problems such as seepage but still say they would choose to have surgery again.

Acknowledgments

The authors thank Ms. Jane Bast, Department of Colorectal Surgery; Mr. Joe Pangrace, Department of Surgical Illustration; Ms. Geri A. Locker, Department of Biostatistics; Ms. Jessica Ancker, and then Department of Scientific Publications for their assistance in preparing this work.

References

1. Ware JE, Jr. SF-36 Health Survey. Manual and Interpretation Guide. The Health Institute, New England Medical Center, Boston, 1993.
2. Parks AG, Nicholls RJ. Proctocolectomy without ileostomy for ulcerative colitis. *Br Med J* 1978;2:85–88.
3. Fazio VW, Ziv Y, Church JM, et al. Ileal pouch-anal anastomoses. Complications and function in 1005 patients. *Ann Surg* 1995;222:120–127.
4. Marcello PW, Roberts PL, Schoetz DJ, et al. Long-term results of the ileopouch procedure. *Arch Surg* 1993;128:500–504.
5. Dozois RR. Management of failed pelvic pouch procedures. In: Rob & Smith's Operative Surgery. Surgery of the colon, rectum, and anus. 5E. Fiedling LP, Goldberg SM (eds) Butterworth-Heinemann Ltd, 1993:682–688.
6. Gemlo BT, Wong WD, Rothenberger DA, Goldberg SM. Ileo pouch-anal anastomosis. Patterns of failure. *Arch Surg* 1992;127:784–786.
7. Setti-Carraro P, Ritchie JK, Wilkinson KH, et al. The first 10 years' experience of restorative proctocolectomy for ulcerative colitis. *Gut* 1994;35:1070–1075.
8. Hultén L. Problems after ileo-pouch anal anastomosis for ulcerative colitis. How can we prevent it? What can we do? *Neth J Med* 1994;45:80–85.
9. Sagar PM, Dozois RR, Wolff BG, and Kelly KA. Disconnection, pouch revision and reconnection of the ileal pouch anal-anastomosis. *Br J Surg* 1996;83:1401–1405.
10. Liljeqvist L, Lindquist K. A reconstructive operation of malfunctioning S-shaped pelvic reservoirs. *Dis Colon Rectum* 1985;28:506–511.
11. Lindquist K, Nilsell K, Liljeqvist L. Cuff abscess and ileoanal anastomotic separations in pelvic pouch surgery. *Dis Colon Rectum* 1987;30:355–359.
12. Herbst F, Seilezneff I, Nicholls RJ. Salvage surgery for ileal pouch outlet obstruction. *Br J Surg* 1996;83:368–371.
13. Dozois RR. Perspectives. *Colon Rectal Surg* 1988;1:113–121.

14. Scott NA, Dozois RR, Beart RW, et al. Postoperative intraabdominal and pelvic sepsis complicating ileal pouch-anal anastomosis. *Int J Colorectal Dis* 1988;3:149–152.
15. Galandiuk S, Scott NA, Dozois RR, et al. Ileo pouch-anal anastomosis. Reoperation for pouch-related complications. *Ann Surg* 1990;212:446–452.
16. Utsunomiya J, Iwama T, Imajo M, et al. Total colectomy, mucosal proctectomy, and ileoanal anastomosis. *Dis Colon Rectum* 1980;23:459–466.
17. Lewis W G, Kuzu A, Sagar PM, Holdsworth PJ, Johnston D. Stricture at the pouch-anal anastomosis after restorative proctocolectomy. *Dis Colon Rectum* 1994;37:120–125.
18. Fleshman JW, McLeod RS, Cohen Z, Stern H. Improved results following use of an advancement technique in the treatment of ileoanal anastomotic complications. *Int J Colorectal Dis* 1988;3:161–165.
19. Fazio VW, Tjandra JJ. Pouch advancement and neoileoanal anastomosis for anastomotic stricture and anovaginal fistula complicating restorative proctocolectomy. *Br J Surg* 1992;79:694–696.
20. Wexner SD, Rothenberger DA, Jensen L, et al. Ileal pouch vaginal fistulas: incidence, etiology, and management. *Dis Colon Rectum* 1989;32:460–465.
21. O'Kelly TJ, Merrett NJ, Mortensen TC, et al. Pouch-vaginal fistula after restorative proctocolectomy: aetiology and management. *Br J Surg* 1994;81:1374–1375.
22. Lee PY, Fazio VW. Pouch vaginal fistula following restorative proctocolectomy: characteristics and outcome. *Dis Colon Rectum* 1997;40:752–759.
23. Ozuner G, Hull T, Lee P, Fazio VW. What happens to a pelvic pouch when a fistula develops? *Dis Colon Rectum* 1997;40:543–547.
24. Olagunju A, Ogunbiya OA, Korsgen S, Keighley MRB. Pouch salvage-long-term outcome. *Dis Colon Rectum* 1997;40:548–552.
25. Cohen Z, Smith D, McLeod R. Reconstructive surgery for pelvic pouches. *World J Surg*, 1998;22:342–346.
26. Korsgen S, Nikiteas N, Ogunbiya OA, Keighley MRB. Results from pouch salvage. *Br J Surg* 1996;83:372–374.
27. Hyman NH, Fazio VW, Tuckson WB, et al. Consequences of ileal pouch-anal anastomosis for Crohn's colitis. *Dis Colon Rectum* 1991;34:653–657.
28. Longo WE, Oakley JR, Lavery IC, et al. Outcome of ileorectal anastomosis for Crohn's colitis. *Dis Colon Rectum* 1992;35:1066–1071.

Discussion

DR. ROBERT W. BEART, JR. (Los Angeles, California): First of all, Dr. Fazio, let me welcome you to the American Surgical Association. The large clinical experience that you have, together with the careful analysis which has become the hallmark of your unit, is certainly going to add significantly to this meeting. From an historical prospective it is interesting to reflect on the comments of President Spencer when he was welcoming the new members. How often the sentinel papers describing a new procedure are presented at this meeting. It was just 18 years ago in 1984 at this meeting, in fact at this venue, that the first large series of ileal pouch anal anastomosis was presented. It is also interesting that it has taken 18 years to develop this series of complications, which I think is some testament to the surgical skill and perhaps safety with which this procedure has been performed in the past decade. You have, I think, made a very significant contribution here. Although we have published on complications and revisions, this is really the first large series that truly hones in on one particular complication which has been vexing for all of us. Your outstanding results I think will be a benchmark for those of us who are going

to look at this in the future. Just a couple of questions. First of all, you mentioned pelvic sepsis as one indication. Can you more clearly define what you mean by that? For instance, would you take a patient who is acutely septic in the postoperative period and do the same sort of revision that you might do in somebody who has a more chronic problem, such as you demonstrated with your slides? Secondly, I think the whole issue of Crohn's disease is undergoing reevaluation, and I would be interested in your perspective of the role of ileal-anal not only in the primary situation with Crohn's but also in those patients who have subsequent complications and are determined to have Crohn's Disease. Third, the whole issue of function is going to be critical as we revise these patients. Do you see any role for physiologic testing, in segregating patients who are good candidates or not? Finally, your unit has published a substantial series of local revision versus this more aggressive disconnection. I personally have found the local revision to be difficult, often having to operate through a somewhat narrowed, fibrotic anorectal ring. But your success has been good. So how do you decide today whether you are going to use the local approach or this more aggressive pouch disconnection?

DR. VICTOR W. FAZIO (Cleveland, Ohio): First, sepsis was defined as any infective process in the peripouch, presacral, anastomotic or perianal area which has persisted or resulted in sequelae such as stricture where a clear relationship is demonstrable. In the patient with acute septic process, reconstructive procedures are avoided or deferred until control of active sepsis is achieved by drainage (e.g., setons) and/or antibiotics. At surgery, in the vast majority of the patients in this series, exuberant granulation tissue lining a sinus or fistulous tract, or a pyogenic membrane was evident. The acute process had usually been previously drained by techniques such as CT-guided drainage, incision and drainage of perirectal or gluteal abscess with or without seton insertion. Occasionally abscesses drain spontaneously leaving a fistulous or sinus tract. Regarding Crohn's disease and repeat abdomino-anal disconnection and neo-IPAA, the fact is that a diagnosis of Crohn's disease may often only be made after historical review of ileal tissue (usually the outlet of the pouch) following the redo procedure. The big question is, "Would you perform a complex operation—such as a redo IPAA—in a patient who has a failed IPAA and in whom a diagnosis of Crohn's disease has been established?" Our data suggests that in the relatively short term, successful restoration of continuity of the intestine can be achieved in about half of these cases of Crohn's disease (6/10 patients). However, long-term follow-up is lacking. Incontinence and quality of life assessment is worse than in similar patients undergoing redo IPAA for ulcerative colitis. In general, I would discourage patients with Crohn's disease, known or strongly suspected, from undergoing repeat IPAA. If pressed, one would have to concede that there is not enough data from which to make firm conclusions or recommendations. Only one-third of our patients with Crohn's disease and repeat IPAA had what they consider to be a good quality of life. Possibly this could improve as manometric and functional evidence of anal sphincter improvement has been observed with passage of time. Regarding psychological testing, most patients underwent manometric study preoperatively to provide supportive data indicating good sphincter function. Studies of compliance or maximum tolerated volume are less helpful preoperatively as these values are usually abnormal as one might expect with presacral sinus or sepsis—and fibrotic encasement of part of the pouch. Once sepsis has been eliminated at repeat IPAA with or