

## Matters Arising

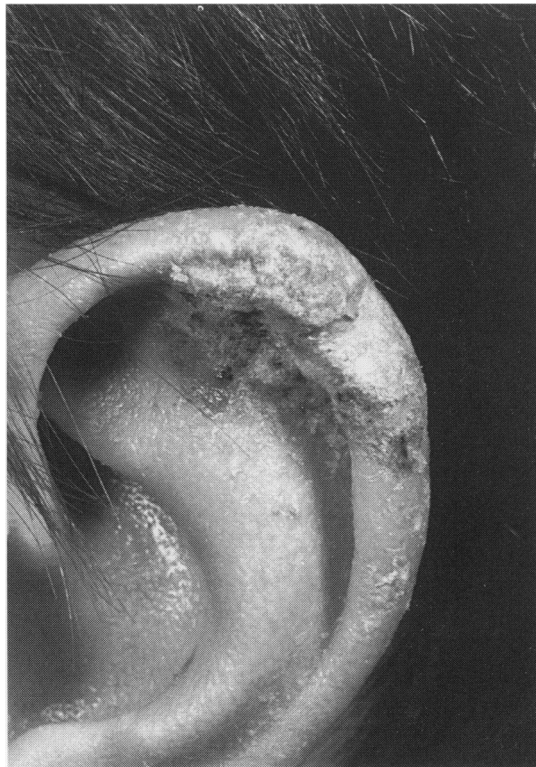
### Crusted ("Norwegian") scabies in a specialist HIV unit

Corbett and colleagues highlight the importance of an effective infection control policy in preventing nosocomial transmission of crusted scabies.<sup>1</sup> Our experience of five patients with crusted scabies in late HIV disease who were treated with a combination of topical scabicides and oral ivermectin, suggests that treatment failure may still occur unless additional measures are taken to reduce the cutaneous mite burden.

Following an outbreak of scabies amongst staff at the HIV in-patient ward at King's College Hospital, in which the index case, a Ugandan male with HIV-associated dementia and *Pneumocystis carinii* pneumonia, was unsuccessfully treated with both topical scabicides and oral ivermectin (200 µg/kg), we amended our infection control policy to include the physical removal of scabies crusts. Therefore, in addition to the measures mentioned by Corbett *et al*, the management policy for crusted scabies at King's includes the following patient regimen:

**Days 1 to 3:** Daily application of 5% permethrin dermal cream to the entire body including to the scalp, neck, face and ears for 18 to 24 hours. Crusts are removed by soaking in a hot bath, which is thoroughly cleaned afterwards.

**Day 5:** If viable mites present; topical 1% lindane or 0.5% malathion for 24 hours (including to the head and neck) combined with single dose oral ivermectin (200 µg per kg).



Scabetic crust on the ear of a patient with late-stage HIV disease, which persisted despite multiple applications of topical lindane, permethrin and malathion. Scabies was eradicated only after topical therapy was combined with physical crust removal and oral ivermectin.

Using this protocol, HIV-associated crusted scabies has been successfully treated in two patients after skin scrapings confirmed large numbers of eggs and live mites. In our experience, recurrent scabies in HIV-infected patients results from failure of mite eradication rather than reinfestation, particularly as sheltered sites (such as behind the ears) may not be treated effectively (see fig). The half-life of ivermectin (150 µg per kg) in humans is 16 hours,<sup>2</sup> producing peak tissue levels 5-6 hours after dosing, and remaining high for 24 hours. We postulate that it is important to reduce the cutaneous load of *Sarcoptes scabiei* as much as possible prior to ivermectin dosing in order to prevent reinfestation from mites or larvae present in the layer of keratinocytes forming the scabetic crust. Finally, as ivermectin is currently only available in the UK on a named patient basis, we would support its licensing in humans with crusted scabies.

R NANDWANI  
A L POZNIAK  
Department of HIV Medicine  
L C FULLER  
Department of Dermatology  
J WADE  
Department of Medical Microbiology,  
King's College Hospital,  
15-22 Caldcot Road  
London SE5 9RS, UK

Address correspondence to: Dr R Nandwani.

- 1 Corbett EL, Crossley I, Holton J, Levell N, Miller RF, De Cock KM. Crusted ("Norwegian") scabies in a specialist HIV unit: successful use of ivermectin and failure to prevent nosocomial transmission. *Genitourin Med* 1996;72: 115-7.
- 2 Elkassaby MH. Ivermectin uptake and distribution in the plasma and tissue of Sudanese and Mexican patients infected with *Onchocerca volvulus*. *Trop Med Parasitol* 1991;42:79-81.

### Balanitis and balanoposthitis: a review

We read with interest S Edward's review on balanitis<sup>1</sup> and would like to make some comments.

In our opinion, dermatological disorders affecting the penis such as psoriasis, lichen planus or sclerosus, fixed drug eruptions and bullous diseases should be excluded from the spectrum of balanitis. From a practical point of view, however, inflammation of the penis may occur in these conditions secondary to an irritation and/or infection.

It is important to note that the clinical aspect of infective balanitis is often non specific and is of little value in predicting the type of infectious agent associated with balanitis. In a recent prospective study of 100 consecutive patients with balanitis and 60 men without balanitis attending our STD clinic,<sup>2</sup> only the presence of pustules was highly suggestive of candidal balanitis.

Among the several microorganisms associated with balanitis, some acting as pathogens and other as saprophytes,<sup>2</sup> *Gardnerella vaginalis* is of special interest after the study of Kinghorn *et al*.<sup>3</sup> However, in our experience, this bacterium is rarely associated with balani-