

Case  
report

# When is bacterial vaginosis not bacterial vaginosis?—a case of cervical carcinoma presenting as recurrent vaginal anaerobic infection

M M T Hudson, J A Tidy, T A McCulloch, K E Rogstad

Vaginal anaerobic infection is the most common cause of vaginal discharge in women. We present a case of recurrent vaginal anaerobic infection and cervical carcinoma and discuss the association of the two conditions. More frequent cytology/colposcopy may be indicated in women who give a history of recurrent or persistent vaginal anaerobic infection.

(*Genitourin Med* 1997;73:306-307)

Keywords: bacterial vaginosis; cervical carcinoma

## Introduction

Bacterial vaginosis is the most common cause of vaginal discharge in women with a prevalence of 29% in gynaecology outpatient attenders with symptoms of vaginitis<sup>1</sup> and accounting for 55 539 new female attendances in genitourinary medicine clinics in the UK.<sup>2</sup> In 35% of women who initially respond to therapy bacterial vaginosis recurs within 3 months.<sup>3</sup> Recurrences, especially when early, are usually associated with persistent residual biochemical abnormalities and probably represent relapse rather than reinfection.<sup>3</sup> We present a case of recurrent vaginal anaerobic infection and cervical carcinoma and discuss the association between the two conditions.

## Case report

A 34 year old white woman presented to the genitourinary medicine clinic in April 1995 with a 2 month history of offensive yellow vaginal discharge and irregular menstruation. Metronidazole and Augmentin had been prescribed by the general practitioner with no benefit. Gynaecological history included polycystic ovarian disease; cervical cytology in 1992 had been negative.  $\beta$  Haemolytic strep-

tococci and ureaplasma were isolated from a high vaginal swab, and erythromycin was commenced. Anaerobes were isolated from a post-treatment sample and were repeatedly isolated for the succeeding 9 months despite numerous courses of metronidazole, clindamycin, and doxycycline. On some but not all of these visits, bacterial vaginosis was diagnosed by the presence of three of the four Amsel criteria<sup>1</sup> (the amine test is not performed in this clinic). None of these courses of treatment resulted in significant symptomatic improvement and all post-treatment high vaginal swabs grew anaerobes. In September 1995 it was noted that the patient remained very symptomatic despite treatment. The patient subsequently defaulted and was recalled in November 1995 at which time she complained of intermenstrual bleeding. Cervical cytology was performed and was associated with bleeding. Cytology was reported as borderline changes with numbers of unusual possibly atypical glandular cells present (fig 1). The patient was referred to the gynaecologists for colposcopy and further investigation. On review in January 1996 the cervix appeared necrotic in keeping with malignancy. Radical surgery confirmed the presence of a stage IB2 poorly differentiated cervical adenosquamous carcinoma (fig 2).

Department of  
Genitourinary  
Medicine, Royal  
Hallamshire Hospital,  
Sheffield

M M T Hudson  
K E Rogstad

Department of  
Obstetrics and  
Gynaecology,  
Northern General  
Hospital, Sheffield  
J A Tidy

Department of  
Histopathology, Royal  
Hallamshire Hospital,  
Sheffield

T A McCulloch

Correspondence to:  
Dr M M T Hudson,  
Department of Genitourinary  
Medicine, Royal Hallamshire  
Hospital, Glossop Road,  
Sheffield S10 2JF.

Accepted for publication  
19 March 1997

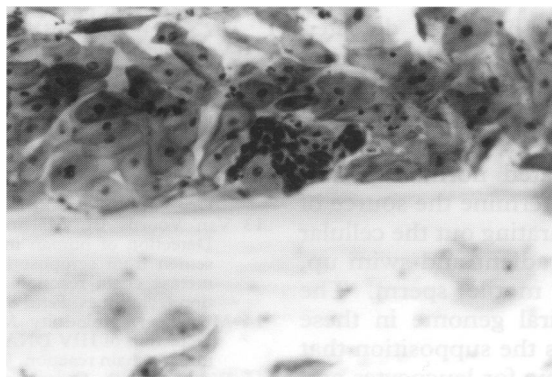


Figure 1 Cytology smear showing a group of small atypical cells. Normal squamous cells are present in the background (original magnification  $\times 160$ ).

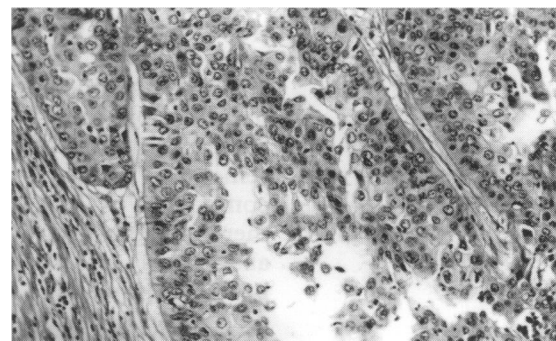


Figure 2 Invasive adenosquamous carcinoma of the cervix (original magnification  $\times 160$ ).

### Discussion

Most studies have shown that bacterial vaginosis occurs significantly more often in patients with cervical precancerous changes or early cancer as opposed to women with normal cervixes.<sup>4-6</sup> Barten found bacterial vaginosis in 54% of women with cervical precancer or early cancer compared with 38% of controls.<sup>4</sup> Neuer and Menton demonstrated *Gardnerella vaginalis* and mycoplasma in 22% of 216 patients with cervical intraepithelial neoplasia (CIN) I-III and in 5% of symptom free controls.<sup>5</sup> In a retrospective re-examination of 6150 Papanicolaou stained smears for clue cells the relative risk of CIN III/carcinoma in situ if the women had bacterial vaginosis was 5.0 with 95% confidence interval of 2.2–11.6.<sup>6</sup> However, Peters *et al*, in an uncontrolled study of 280 women with dyskaryotic cervical smears, failed to confirm these findings.<sup>7</sup> In all these studies smoking and sexual behaviour are possible confounding factors in establishing an aetiological link (no barrier contraception was used by our patient).

It is not possible to say if the association between anaerobic vaginosis and cervical precancer is causal or incidental. Pavic suggested that locally produced nitrosamines may act synergistically with other aetiological agents in the development of cervical neoplasia.<sup>8</sup> It has been suggested that raised colonic pH may be important in the aetiology of colorectal carcinoma.<sup>9</sup> The important aetiological factor in cervical cancer may be the relative absence of hydrogen peroxide producing lactobacilli that may have a protective role in the development of cervical dysplasia.<sup>10</sup> It has been suggested that a raised vaginal pH may arrest squamous metaplasia in the postpubertal cervix and prolong the period in which the transformation zone is vulnerable to agents promoting dysplasia such as human papilloma virus.<sup>11</sup> It is, however, also probable that in patients with cervical malignancy the disruption of the normal vaginal environment by necrotic tissue and blood contributes to an alteration in the vaginal flora.

This patient had persistent vaginal anaero-

bic infection and was distressed by her symptoms. Cytology within the last 4 years had been normal and even when performed changes were borderline. This has been seen in cases of frank carcinoma of the cervix.<sup>12</sup> In view of the association between bacterial vaginosis and cervical carcinoma perhaps women who give a history of recurrent/persistent vaginal anaerobic infection should have cytology performed more frequently. The role of colposcopy in this group with no or minimal changes on cytology needs to be considered. It remains to be determined how to recognise the very small number of all women attending genitourinary medicine or other clinics with bacterial vaginosis who have an underlying precancer or cancer. The association between cervical cancer and anaerobic vaginal infection deserves further study.

- 1 Amsel R, Totten PA, Spiegel CA, Chen KCS, Eschenbach DA, Holmes KK. Nonspecific vaginitis: diagnostic criteria and microbial and epidemiological associations. *Am J Med* 1983;74:14–22.
- 2 Department of Health. New cases seen at NHS genitourinary medicine clinics, 1994. Annual figures. Summary information from KC60. London: DoH, 1995.
- 3 Cook RL, Redondo-Lopez V, Schmitt C, Meriwether C, Sobel JD. Clinical, microbiological, and biochemical factors in recurrent bacterial vaginosis. *J Clin Microbiol* 1992;30:870–7.
- 4 Barten G. Infectiose Genitalerkrankungen und ihre Bedeutung bei der Entstehung des Zervixkarzinoms und seiner Vorstufen. *Zentralbl Gynakol* 1990;112:431–5.
- 5 Neuer A, Menton M. Bacteriological findings in patients with cervical intra-epithelial neoplasia. *Zentralbl Gynakol* 1995;117:435–8.
- 6 Platz-Christensen JJ, Sundstrom E, Larsson PG. Bacterial vaginosis and cervical intraepithelial neoplasia. *Acta Obstet Gynecol Scand* 1994;73:586–8.
- 7 Peters N, Van Leeuwen AM, Pieters WJ, Hollema H, Quint WG, Burger MP. Bacterial vaginosis is not important in the etiology of cervical neoplasia: a survey on women with dyskaryotic smears. *Sex Transm Dis* 1995; 22:296–302.
- 8 Pavic N. Is there local production of nitrosamines by the vaginal microflora in anaerobic vaginosis/trichomoniasis? *Med Hypotheses* 1984;15:433–6.
- 9 Thornton JR. High colonic pH promotes colorectal cancer. *Lancet* 1981;i:1081–2.
- 10 Blackwell AL. Association of anaerobic vaginosis with cervical intraepithelial neoplasia. In: Templeton A, ed. *The prevention of pelvic infection*. London: Royal College of Obstetricians and Gynaecologists, 1996:87.
- 11 Blackwell AL, Phillips I. Anaerobic vaginosis. In: Reeves DS, Geddes A, eds. *Recent advances in infection*. Edinburgh: Churchill Livingstone, 1989:171–87.
- 12 Kurman RJ, Schiffman MH, Lancaster WD, Reid R, Bennett Jensen A, Temple GF, *et al*. Analysis of individual human papillomavirus types in cervical neoplasia: a possible role for type 18 in rapid progression. *Am J Obstet Gynecol* 1988;159:293–6.