

# Amyloid tumour of the urethra presenting as non-specific urethritis

Olwen E Williams, Howard Kynaston, Glen Dixon, O P Arya

## Abstract

**Amyloid tumour involving the urethra is a well recognised but rare occurrence. Chronic inflammation secondary to gonococcal urethritis is thought to be a possible predisposing factor. We report the case of a young man who presented with non-gonococcal urethritis and haematuria and was subsequently found to have primary amyloid of the urethra.**

## Case report

A 27 year old Caucasian male forestry worker, presented to the Genitourinary Medicine (GUM) outpatient department complaining of dysuria, pain in the base of his penis and haematuria, which occurred at the beginning of micturition for the past four days. His symptoms had not responded to treatment with co-trimoxazole 960 mg twice daily for two days prescribed by his general practitioner. There were no other symptoms. He had no past history of any significant illness or sexually transmitted disease.

Genital examination revealed a profuse muco-purulent urethral discharge and meatal erythema. No other abnormality was noted.

On Gram stain of the urethral discharge, greater than 10 polymorphonuclear leucocytes per high power field were seen in several fields. Haematuria was detected on dipstick urinalysis. Endourethral swabs for *Neisseria gonorrhoea*, and chlamydia ELISA were negative. Syphilis serology was also negative.

A diagnosis of non-gonococcal urethritis was made and the patient was commenced on Deteclo (triple tetracycline) one tablet twice daily for 14 days. A midstream sample of urine was subsequently reported to show an excess of white and red blood cells ( $50 \text{ cells} \times 10^6/\text{l}$ ), but no growth.

At review, two weeks later he continued to complain of intermittent macroscopic haematuria associated with exercise, frequency of micturition, nocturia and poor urinary stream, with some degree of hesitancy.

Microscopic haematuria was again present. Phase contrast microscopy of the urine showed 75% dysmorphic red blood cells suggesting a renal cause for the bleeding. Plasma chemistry, full blood count, immunological profile and intravenous urogram were all normal. In view of the presence of dysmorphic red blood cells a renal biopsy was considered, but the patient declined this procedure.

Urological investigations revealed an obstructive pattern of micturition. At urethroscopy, extensive ulceration of the posterior urethra, with polypoid lesions projecting from these areas were seen. Histological examination of the urethral mucosa showed islands of amorphous eosinophilic material associated with foreign body giant cell reaction within the stroma suggestive of amyloid. Bifringence with Congo red was present but there was no typical apple green bifringence of amyloid.

Following urethroscopy the patient continued to complain of a poor urinary flow and a micturating cystogram showed an irregular area in the lining at the junction of bulbar and spongy urethra (fig 1). In view of these findings, the patient's symptoms and the inconclusive histology, repeat cystourethroscopy was performed.

On this occasion the lesion was resected and a full thickness biopsy taken. The site bled profusely, but was controlled by digital pressure and a catheter was inserted for two days post-operatively. After removal of catheter, he had no problems voiding. Histology on this occasion confirmed amyloid (fig 2).

Follow up to date has been uneventful. The patient has declined a rectal biopsy to exclude systemic amyloidosis.

## Discussion

Isolated urethral amyloidosis is a rare condition, with only 16 cases reported in the world literature.<sup>1-14</sup> It is of interest to the genitourinary physician because the symptoms mimic urethritis per se and gonococcal urethritis has

University  
Department of  
Medical Microbiology  
and Genitourinary  
Medicine, Royal  
Liverpool University  
Hospital, Liverpool  
L7 8XP, UK  
O E Williams  
O P Arya

Department of  
Urology, Broadgreen  
Hospital, Liverpool  
H Kynaston

Department of  
Pathology, Broadgreen  
Hospital, Liverpool  
G Dixon

Address correspondence to:  
Dr O E Williams

Accepted for publication  
26 March 1992

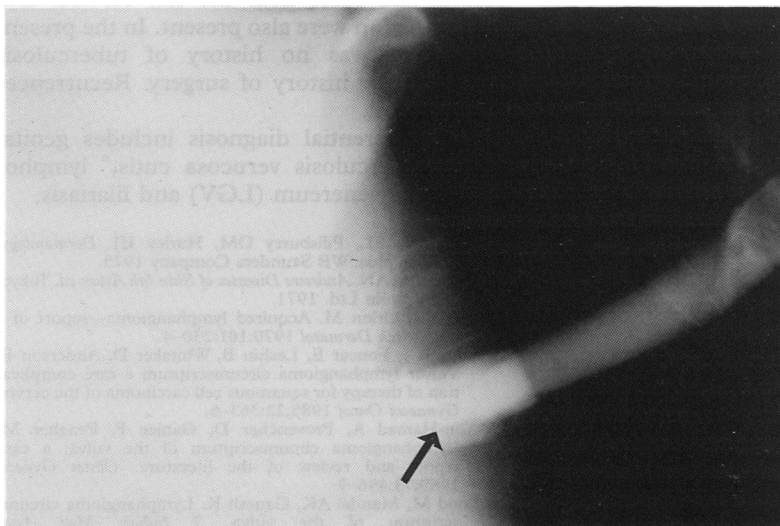


Figure 1 Micturating cystogram showing irregular area at junction of bulbar and spongy urethra.

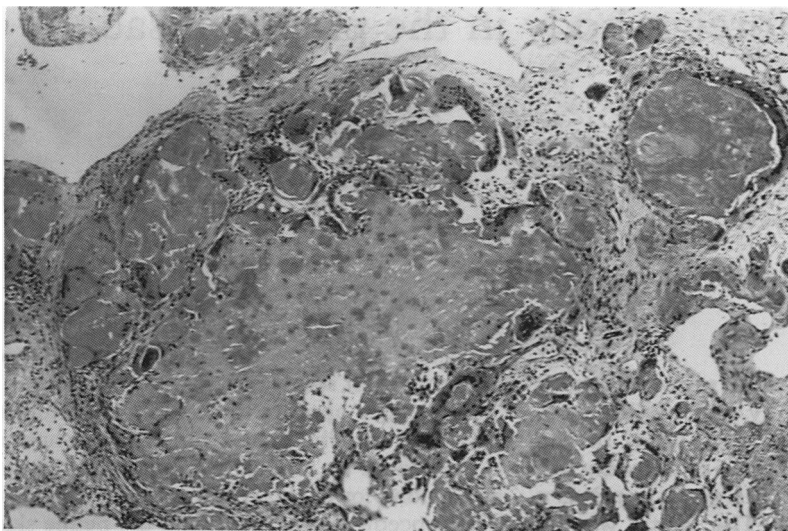


Figure 2 Histology confirming amyloid. (H and E,  $\times 100$ ).

been implicated as a possible aetiological factor.<sup>2 3 13</sup>

The first case was reported at autopsy in 1909 by Tilp,<sup>2</sup> and subsequently there have been a further 15 reports in males aged between 27 and 82 years of age (mean 53 years). A past history of gonorrhoea was obtained in five patients. However, this predated the diagnosis of amyloid by 30 to 48 years and hence may be a coincidental finding rather than an aetiology.

The commonest presenting complaints are macroscopic haematuria (eight cases) or a bloody urethral discharge (two cases). This is probably due to ulceration of the amyloid tumour and distortion of the blood vessels by the amyloid. Massive haemorrhage has been reported from amyloid deposits in the bladder.

Urethral symptoms suggestive of an obstructive lesion were reported in nine cases, and a palpable mass in the penile shaft in two cases. These are all clinical features that are shared with neoplastic lesions, most commonly carci-

noma. Hence to distinguish between the two diseases cystourethroscopy and biopsy are mandatory.

The aetiology of amyloid is thought to be an immunocytic response probably produced by adjacent monoclonal plasmacytic infiltrates resulting from local infection. If gonorrhoea is implicated, then the incidence of isolated urethral amyloid should be much higher.

The management of urethral amyloid has varied, depending largely on the clinical characteristics of the lesion and the presumptive initial diagnosis. The majority of patients had no treatment, but urethroscopy, cystotomy, and in some cases, transurethral resection for removal of tumour or relief of urethral obstruction have been necessary. Urethrectomy was performed on one patient where an erroneous clinical diagnosis of carcinoma was made.<sup>3</sup>

This case illustrates the need for careful assessment of patients with non-specific urethritis and concomitant haematuria.

- 1 Tilp A. Uber lokales tumor formiges Amyloid de Harnbohe. *Zentralbl Allg Pathol* 1909;20:913-6.
- 2 Ullmann AS, Fine G, Johnson AJ. Localized amyloidosis (amyloid tumor) of the urethra. *J Urol* 1964;92:42-4.
- 3 Van Albertin A. Local amyloid of urethra. *Frankfurter Zeitschrift fur Pathologie* 1925;33:248-57.
- 4 Herxheimer G, Reinhart A. Uber locale amyloidosis (insbesondere die sogenannten Amyloid tumoren). *Klin Wochenschr (Berlin)* 1913;50:1648-54.
- 5 Schmid KO. Localized amyloidosis (paramyloidosis) of the urethra, with a contribution to the knowledge of urethral pseudo tumours. *Krebsarz Wein* 1956;11:329.
- 6 Chawalla R. A case of amyloidosis at the bladder neck resembling a tumour. *Urology and Cutaneous Review* 1932;32:248.
- 7 Christie AJ, Weingarten CJ. Amyloidosis presenting in the urethra. *J R Soc Med* 1988;8:174-5.
- 8 Fujime M, Tajima A, Minowada S, et al. Localized amyloidosis of urethra, report of 2 cases. *Eur Urol* 1981;7:189-92.
- 9 Karisary AV. Primary localized amyloidosis of the urethra. *Eur Urol* 1985;11:209.
- 10 Ordonez N, Ayala A, Gresik M, et al. Primary localized amyloidosis of the male urethra (amyloidoma). *Urology* 1979;14:617-9.
- 11 Walzer Y, Bear RA, Colpinto V, et al. Localized amyloidosis of the urethra. *Urology* 1983;21:406-7.
- 12 Vasuderam P, Stein A, Pum V, et al. Primary amyloidosis of the urethra. *Urology* 1981;17:181-3.
- 13 Geram S, Easley CW, Payan H. Primary localized amyloidosis of the urethra and bladder. *Am Surg* 1970;36:375-7.
- 14 Constantian HM, Wyman P. Localized amyloidosis of the urethra; report of a case. *J Urol* 1980;124:728-9.