

Blue sclerae and keratoglobus

Ocular signs of a systemic connective tissue disorder

S. W. HYAMS*, H. DAR†, AND E. NEUMANN*

From the Departments of Ophthalmology and Paediatrics†, and the Sol Gold Laboratory†, Rothschild Government-Municipal Hospital, Haifa, Israel.*

The following case is reported because of the rarity with which keratoconus or keratoglobus is associated with blue sclerae. Examination of the family of the propositus and a study of the literature suggest that these findings may be the ocular manifestations of a distinct, heritable disorder of connective tissue.

Case report

A 4-year-old girl was referred to the department of ophthalmology of the Rothschild Hospital, Haifa, because of a blue discoloration of the sclerae from birth, bulging of the eyes which had been first noticed at the age of 4 months, and apparent short sight. The child was the product of a normal pregnancy and a normal full-term delivery. The birth weight was 3.6 kg. There had been three episodes of bronchopneumonia in the past which responded satisfactorily to antibiotics. There was no history of fractures or dislocations.

PHYSICAL EXAMINATION The child was reasonably well nourished and in good general condition. Her height was 103 cm. (50th percentile) and her weight 15 kg. (25th percentile). There was marked hypotony of the limbs, hyperextensibility of the joints throughout the body (Fig. 1), and a small umbilical hernia. The skull was elongated in its antero-posterior axis, giving the impression of scaphocephaly. The skin was highly freckled but of normal texture and elasticity. The hair was

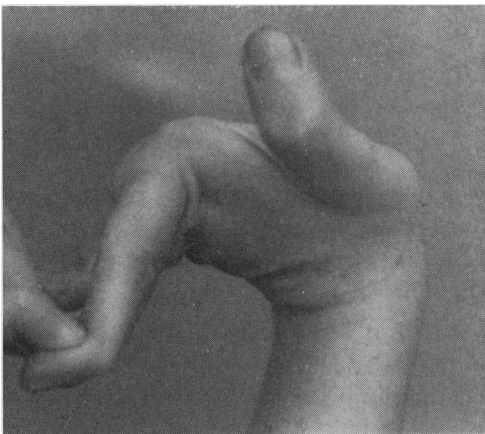


FIG. 1 *Left hand of propositus, showing hyperextension of wrist and metacarpophalangeal joints*

ginger in colour. There was a bilateral hearing loss due to chronic otitis media and cholesteatoma. The teeth were in poor condition and dental examination established a diagnosis of dentinogenesis imperfecta. The rest of the physical examination was normal.

X-ray examination confirmed the relatively increased antero-posterior diameter of the skull and revealed an absence of the usual symmetrical relationship between the cranial vault and the facial bones. The long bones and vertebral column were normal.

BLOOD ANALYSIS Hb 13.5 g. per cent. Red blood count 4,200,000. White blood count 8,400 with normal differential count. Serum calcium, phosphorus, and alkaline phosphatase normal. Urine analysis, including aminoacid chromatography, normal.

Chromosome analysis was made on cultured leucocytes from peripheral blood, using a modification of the method of Moorhead, Nowell, Mellman, Battips, and Hungerford (1960). The analysis revealed a normal female karyotype.

OPHTHALMOLOGICAL EXAMINATION Uncorrected visual acuity 1/60 in each eye. Alternating esotropia with an angle of 15°. No nystagmus. In both eyes the sclera was a deep Wedgwood blue and there was gross keratoglobus (Fig. 2). The corneal diameter was 11 × 11.5 mm. in both eyes.

Slit-lamp examination revealed that the entire cornea was about 0.2 mm. in thickness. There were many linear tears in Descemet's membrane, most marked at the centre. The iris, pupil, and lens were normal. The fundus was normal.

The radius of curvature of the cornea in the horizontal meridian was 5.6 mm. (60.25 D) in the right eye and 5.5 mm. (60.75 D) in the left. The corneal curvature in the vertical meridian of both eyes was too great to be measured with the Haag-Streit keratometer.

Retinoscopy with cycloplegia revealed high myopia and astigmatism: -33 D sph., -4.5 D cyl., 180° in the right eye, and -25.5 D sph., -5.5 D cyl., 180° in the left.

The best corrected vision in each eye was 6/90 with -20 D sph., not improved further with full correction or with contact lenses.

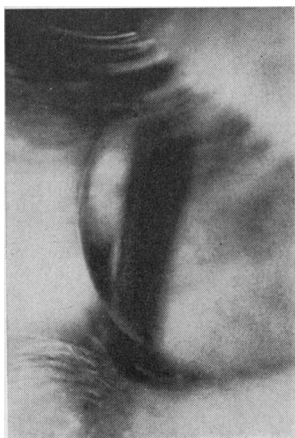

FIG. 2 Side view of left eye of *propositus* before injury, showing keratoglobus

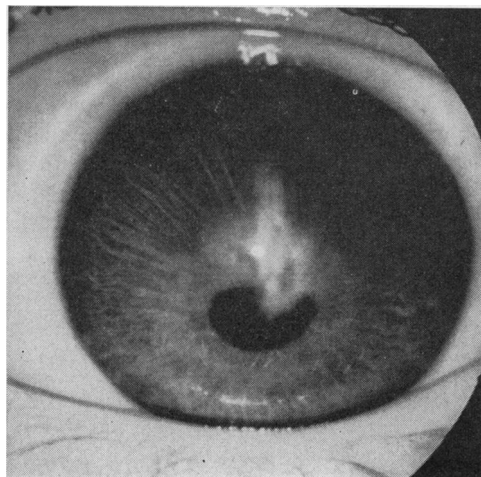


FIG. 3 Left eye of *propositus* 3 months after injury, showing linear corneal scar, anterior synechia, and irregular pupil

About a year after the initial examination the child was brought to the clinic with a perforation of the left cornea. She had awakened in the night with pain in the left eye and thought that her brother, who slept in the same bed, had inadvertently hit her in the eye with his hand. Examination revealed a linear, gaping perforation of the cornea, from its centre to the limbus at 12 o'clock. The anterior chamber was absent, the pupil round, and the lens transparent.

When the wound was examined under general anaesthesia with the help of the operating microscope it was found that the cornea at the edges of the wound was thinner than the 83 Grieshaber needle. No attempt to suture the cornea was made and the wound was covered by a conjunctival

flap taken from the upper fornix. A binocular bandage was applied, and 2 days later, the conjunctival flap had begun to recede and the anterior chamber was well formed. On the fourth post-operative day, the anterior chamber was absent but gradually re-formed with continued binocular occlusion and complete rest in bed.

At the first slit-lamp examination, 2 weeks after the injury, the wound was seen to be well closed and there was an anterior synechia involving the upper two-thirds of the corneal wound. There was separation of Descemet's membrane from the rest of the cornea, which was oedematous. The corneal hydrops occupied two-thirds of the depth of the anterior chamber and gradually receded during the ensuing 3 months. The present visual acuity is 6/90, the same as before the injury, in spite of a vertical scar involving the centre of the cornea (Fig. 3).

Examination of the family

The pedigree (Fig. 4) represents six generations of a Jewish family, immigrants from Tunisia. Consanguineous marriages are common in this family, and the parents of the propositus are cousins once removed. The pedigree consists of 82 members, of whom 46 were examined by the authors, and information, apparently reliable, was obtained about thirteen other members. Nineteen persons, fourteen females and five males, in three successive generations, have blue sclerae of slight, moderate, or marked degree. Four, all with blue sclerae of moderate to marked degree, were found to have hyperextensibility of the joints.

Discussion

The present case appears to represent an heritable disorder of connective tissue which has not hitherto been fully recognized and is characterized by blue sclerae, keratoglobus or keratoconus, fragile corneae, hyperextensibility of the joints, and dentinogenesis imperfecta. There have been six previous reports of twelve cases which resemble the present one to a greater or lesser degree.

Stein, Lazar, and Adam (1968) have treated two brothers with blue sclerae, thin fragile corneae, and hyperextensibility of the joints. It was not possible to say whether keratoglobus existed in these cases since both presented with severe lacerations of the cornea in the only remaining eye, the other eye having been lost from trauma some years previously. Both of the brothers were ginger-haired, and many members of the family had blue sclerae. In one of the brothers it was impossible to save the only, lacerated eye. The other case was treated successfully by placing a 12-mm. full-thickness corneal disc over the lacerated cornea without removing the host epithelium. The corneal disc was sutured to the surrounding episclera and its periphery covered by conjunctiva. It is possible that these two brothers are distant relatives of our case since the two families come from the same town in Tunisia. However, no common ancestor could be found.

Badtke (1941) reported the presence of blue sclerae and keratoconus in two sisters who also had hyperelasticity of the ligaments and tendons throughout the body, dry skin and hair, poor dental development, and mental retardation. It was not possible to reconstruct the family tree in detail but it was known that there had been much intermarriage and blindness in the family. Badtke pointed out that one might well expect to find keratoconus associated more frequently with blue sclerae.

Arkin (1964) reported blue sclerae and keratoglobus in a 17-year-old boy, who also had hyperelasticity of the joints, brittle bones, and poor teeth.

Tucker (1959) reported two sisters with blue sclerae, thin corneae, and hyperextensibility of the fingers; one gave a history of a single fracture, and the other had congenital

corneal oedema due to tears in Descemet's membrane, which was at first thought to be due to glaucoma. The parents were first cousins.

Attiah and Sobhy Bey (1931), and Attiah (1933) reported three cases of blue sclerae with myopia which he considered to be incidental and unrelated to the syndrome; one suffered from recurrent dislocations of the joints and in two the cornea were thin and conical.

Behr (1913) reported two brothers with blue sclerae, keratoconus, and recurrent dislocations of the joints; one had a bilateral hearing defect.

The clinical features of the above cases and of the present case are summarized in the Table.

Table Summary of clinical features of present case and of similar cases reported previously

Author	Date	Case No.	Clinical features							
			Blue sclerae	Kerato-globus/-conus	Fragile corneae	Lax ligaments	Poor teeth	Fractures	Deafness	Consanguinity
Stein and others	1968	1	+	?	+	+				+
		2	+	?	+	+				+
Badtke	1941	1	+	+		+	+			+
		2	+	+		+	+			+
Arkin	1964		+	+		+	+	+		
Tucker	1959	1	+	?	*	+				+
		2	+	?		+		±**		+
Attiah and Sobhy Bey	1931	1	+	+		+				
		2	+	+						
Attiah	1933	3	+							
Behr	1913	1	+	+		+				
		2	+	+		+			+	
Present case	1968		+	+	+	+	+		+	***

*Congenital corneal oedema

**One fracture as a result of a fall from a chair

***Due to otitis media

Buchanan (1903, 1923) described the ocular pathology in two cases with blue sclerae and conical corneae. The cornea was $\frac{3}{5}$ of its normal thickness and the sclera $\frac{1}{3}$ of its normal thickness. Other reports by Casanovas (1934), De Leonibus and Gemelotto (1954), and Ruedemann (1953) have confirmed that the main histological finding in cases of blue sclera is a thinning and breakdown of the collagen.

The differential diagnosis in the present case and in the similar cases reported in the literature is osteogenesis imperfecta tarda, the Ehlers-Danlos syndrome, or a distinct but possibly related connective tissue disorder.

The characteristic features of osteogenesis imperfecta are blue sclerae, brittle bones, deafness, hyperextensibility of the joints, and dentinogenesis imperfecta. Our propositus is now 6 years old and has suffered no fractures, and x-ray examinations have shown normal bone structure. There was a history of only one fracture (from severe trauma)

among the 59 members of the family investigated. The propositus had bilateral hearing loss but this was due to chronic otitis media with cholesteatoma, and there was no deafness in the family.

The characteristic features of the Ehlers-Danlos syndrome are hyperelasticity and fragility of the skin, blue sclerae, poor teeth, and muscular hypotony. Abnormalities of the skin were not present in the family reported here nor were they noted in any of the similar cases reported in the literature.

The pedigree of our case (Fig. 4) indicates that the syndrome is inherited by a dominant gene with varying expressivity and incomplete penetrance. As in osteogenesis imperfecta, the gene has a high penetrance with regard to its effect on the sclera, especially in females.

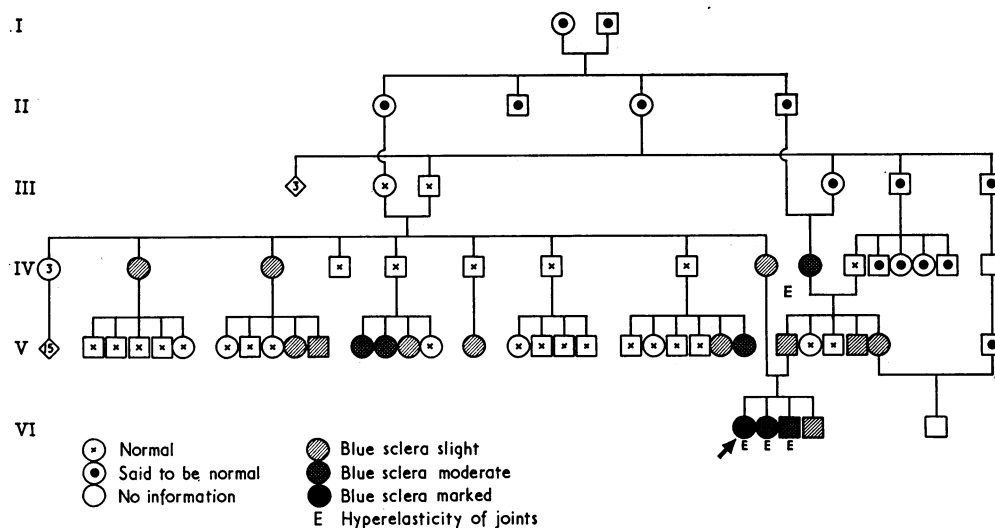


FIG. 4 Family tree. Nineteen members of the family have blue sclerae—slight, moderate, or marked. Four have hyperelasticity of the joints. The parents of the propositus are cousins once removed

However, the gene has a low penetrance with regard to bone fragility and deafness (if it has any such effect at all), both in the family reported here and in the similar cases reported in the literature. This is in contrast to the gene for osteogenesis imperfecta which has a penetrance of 60 per cent. for bone fragility and 63 per cent. for deafness (Bell, 1928).

Four members of the family reported here exhibit more than one feature of the syndrome and all are children of consanguineous marriages, as are the two brothers reported by Stein and others (1968), and the two sisters reported by Tucker (1959). Badtke (1941) stated that there was much intermarriage in the family of the two sisters he reported. It is possible that these cases represent the homozygous state with its enhanced expressivity. This again is in contrast to the mode of inheritance of osteogenesis imperfecta, in which consanguinity is not a significant factor (Bell, 1928; Fuss, 1935; Hills and McLanahan, 1937; Kellogg, 1947).

McKusick (1960) suggested that osteogenesis imperfecta, the Ehlers-Danlos syndrome, Marfan's syndrome, Hurler's syndrome, and pseudoxanthoma elasticum each represent an abnormality of a single element or biochemical mechanism of connective tissue. It is possible that the present case and the similar ones reported in the literature represent an additional syndrome in this group of connective tissue disorders.

Summary

(1) A case of blue sclerae, keratoglobus, and fragile corneae associated with hyperextensibility of the joints throughout the body and dentinogenesis imperfecta is described. Blue sclerae were extremely common in the family and hyperextensibility of the joints was present in three members of the family in addition to the propositus.

(2) Twelve more or less similar cases appearing in the literature are reviewed, and it is suggested that these cases as well as the present one represent a distinct heritable disorder of connective tissue which has not hitherto been fully recognized.

The authors wish to thank Dr. A. Berger and Dr. S. H. Reisner, from the paediatric department of the Rothschild Hospital, for examining the propositus and the family and for their help and advice in writing the paper, Dr. D. Gutman, head of the maxillo-facial unit of the Rambam Government Hospital, Haifa, for carrying out the dental examination of the propositus, and Dr. S. Winter, head of the paediatric department of the Rothschild Hospital, for referring the case.

This work was carried out with the help of the H.E.W. Children's Bureau Project, Israel/17.

Addendum

In July, 1968, the patient returned to the clinic with a perforation of the right cornea. She said that she had run into a wall while playing. There were no signs of injury to the forehead or eyelids. Her spectacles, which she was wearing at the time of the injury, did not fall and were not broken. There was a star-shaped perforation of the cornea reaching the limbus above and below. The eye was treated in the same way as the left eye by covering the cornea with a conjunctival flap and the perforation healed with the formation of large iris adhesions. At the time of writing the visual acuity is 1/60.

References

- ARKIN, W. (1964) *Amer. J. Ophthalm.*, **58**, 678
- ATTIAH, M. A. H. (1933) *Bull. ophthalm. Soc. Egypt*, **26**, 96
- and SOBHY BEY, M. (1931) *Ibid.*, **24**, 67
- BADTKE, G. (1941) *Klin. Mbl. Augenheilk.*, **106**, 585
- BEHR, C. (1913) *Ibid.*, **n.s.** **16**, 281
- BELL, J. (1928) "The Treasury of Human Inheritance", ed. K. Pearson, vol. 2, "Anomalies and Diseases of the Eye" (Nettleship Memorial Volume); Part III. "Blue Sclerotics and Fragility of Bone". Eugenics Laboratory Memoirs. XXIV. University Press, Cambridge
- BUCHANAN, L. (1903) *Trans. ophthalm. Soc. U.K.*, **23**, 267
- (1923) *Ibid.*, **43**, 352
- CASANOVAS, J. (1934) *Arch. Ofial. hisp.-amer.*, **34**, 133
- DE LEONIBUS, F., and GEMOLOTTI, G. (1954) *Boll. Oculist. (Paris)*, **33**, 789
- FUSS, H. (1935) *Dtsch. Z. Chir.*, **245**, 279
- HILLS, R. G., and MCLANAHAN, S. (1937) *Arch. intern. Med.*, **59**, 41
- KELLOGG, C. S. (1947) *Ibid.*, **80**, 358
- MCKUSICK, V. A. (1960) "Heritable Disorders of Connective Tissue", 2nd ed., p. 17. Mosby, St. Louis
- MOORHEAD, P. S., NOWELL, P. C., MELLMAN, W. J., BATTIPS, D. M., and HUNGERFORD, D. A. (1960) *Exp. Cell Res.*, **20**, 613
- RUEDEMANN, A. D. (1953) *A.M.A. Arch. Ophthalm.*, **49**, 6
- STEIN, R., LAZAR, M., and ADAM, A. (1968) *Amer. J. Ophthalm.*, **66**, 67
- TUCKER, D. P. (1959) *Ibid.*, **47**, 345