

New implant for drainage in glaucoma

Animal trial

A. C. B. MOLTENO

Department of Ophthalmology, University of the Witwatersrand and Baragwanath Hospital, Johannesburg

The implant described in this communication is the direct descendent of a long series of artificial drainage devices which began when Zorab (1912) inserted a silk thread through the limbus in order to drain aqueous into the subconjunctival space in cases of glaucoma (see also Mayou, 1912). Among the more recently described devices are teflon drainage tubes in man (Richards, 1955; Epstein, 1959; Ellis, 1960) and gel film strips in rabbits (Laval, 1955; Barsky and Schimek, 1958). While short-term results with these implants have been promising, long-term results have been uniformly disappointing. The translimbal tubes of Ellis and Epstein have certainly maintained a patent fistula yet drainage has ceased.

This failure of drainage has been ascribed to fibrosis in the bleb wall, the fibrosis itself being caused by a hypothetical action of the draining aqueous on the tissues (Stanworth, 1958; Tribin-Piedrahita, 1965).

To prevent any reduction in area of the bleb by fibrosis, an implant has been designed consisting of a translimbal tube rigidly attached to and opening onto the external surface of a thin acrylic plate. This plate, curved to fit the sclera lies under the conjunctival and episcleral tissues. *The tube guarantees patency of the fistula while the plate, sutured to the sclera, forms the floor of a bleb which cannot shrink to an area less than that of the plate.*

In order to develop a mechanically satisfactory implant experimental work has been carried out on rabbits.

Experiment

Implants

These were made from "Stellon" brand dental and neurosurgical acrylic monomer which was mixed with catalyst and moulded into shape while pliable.

It was found essential to boil each implant in three changes of distilled water for a total period of 6 hours in order to remove all traces of monomer and catalyst. Insufficiently boiled implants excited a severe reaction with necrosis of the overlying conjunctiva followed by extrusion of the implant.

The implant finally adopted had the following specifications (see Fig. 1a, b, overleaf):

PLATE	Length	7.5 mm.
	Width	8.5 mm.
	Thickness	0.75 mm. tapering to edge.
	Radius of curvature of undersurface	5 mm. at right angles to the limbus and 8 mm. parallel to the limbus.

TRANSLIMBAL TUBE	Diameter external	1.5 mm.
	Diameter internal	0.8 mm.
	Length of 1st portion	0.5 mm.
	Length of 2nd portion	1.8 mm.
	Angle between 2nd portion and tangent to anterior limit of plate	15°.

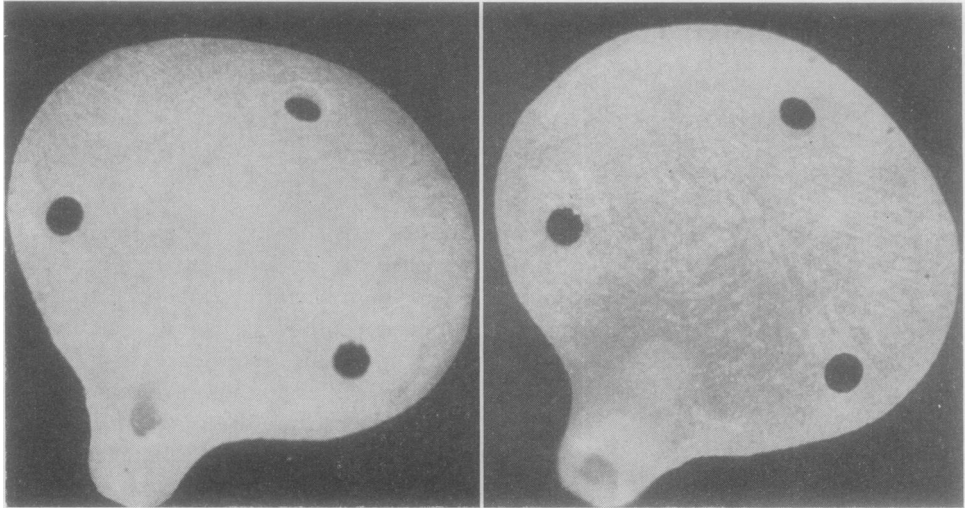


FIG. 1 *Implant viewed from above (a) and below (b). ×6*

Important points in design

1. A translimbal tube curved through 120° fitting a limbal trephine hole in such a way as to prevent movement of the plate.
2. A plate slightly more steeply curved than the sclera so that the edges could not elevate and erode the conjunctiva.
3. Two holes for sutures placed anteriorly in the plate allowing more accurate placing of the sutures when the eye was soft after it had been opened.

45 implants based on the above principle have been inserted into rabbit eyes, but only eight of these were of the final type specified above. These eight, together with four of an earlier type, proved mechanically satisfactory and were followed up for from 2 to 19 months.

These twelve examples are the subject of this communication.

Animals used

Young adult chinchilla rabbits of both sexes, bred by the South African Institute for Medical Research in Johannesburg, were examined to exclude ocular or general disease. The animals weighed between 2 and 4.5 kg. and ranged in colour from albino to black.

METHOD OF MEASURING INTRAOCULAR PRESSURE AND OUTFLOW

A standard Schiötz tonometer with a 5.5 g. weight was used for most of the tensions recorded. The usual precautions were taken and the instrument was checked before use on the standard provided. Later in the experiment a Goldmann applanation tonometer was used. Individual readings with this instrument were probably more accurate as the animals did not struggle.

Tonography was done over a 4-minute period using a 5.5 g. weight on a Schwartzer electronic tonometer with recorder.

PREPARATION AND METHODS USED FOR TONOMETRY AND TONOGRAPHY

1. Both corneae were anaesthetized by local drops of Novesine 0.4 per cent.
2. The animal was gently but firmly wrapped in a towel and its struggles allowed to die away.
3. It was laid on one side on the assistant's lap.
4. After gently retracting the eyelids using two fingers, the tonometer was placed centrally on the cornea and held vertical.
5. The lids were released and the readings taken.
6. Tonography was done in an identical manner except that the tonometer was allowed to rest on the cornea for 4 minutes while the tracings were recorded.
7. Applanation tonometry was done with a Goldmann applanation tonometer fitted to a Haag-Streit slit lamp.

The animal was wrapped and anaesthetized as for indentation tonometry but was held horizontal and upright by an assistant who rested her forearm on the chin rest of the slit lamp.

Errors arising from inadvertent pressure on the second eye of an animal undergoing tonometry or tonography were avoided by alternately doing right and then left eyes first and by waiting 2 hours before tonography of the fellow eye.

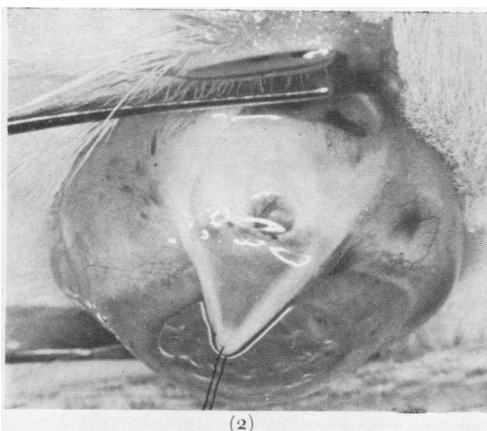
PREPARATION FOR HISTOLOGICAL STUDIES

The animals were killed by intravenous injection of Nembutal, and then perfused *via* the aorta with warm formol-saline. The eyes were then enucleated, fixed in 10 per cent. formol saline, embedded in wax, and sectioned. The sections were stained with haematoxylin and eosin.

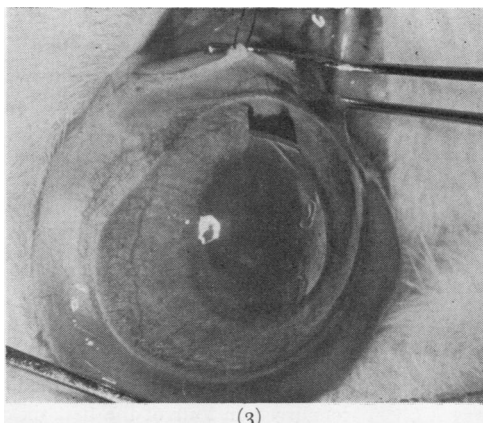
Techniques for insertion of implants (see Figs 2-5)

General anaesthesia with intravenous Nembutal was supplemented by retrobulbar injection of lignocaine *without* adrenaline.

1. The lids were retracted with a speculum.
2. A limbus-based conjunctival flap was dissected up in the supero-posterior quadrant (Fig. 2).
3. A limbal trephine was made beneath the flap and the disc of sclera removed, followed by a full iridectomy (Fig. 3).



(2)



(3)

FIGS 2-5 *Stages in operative technique*

4. The implant was inserted and carefully positioned, and its plate was sutured firmly to the sclera (Figs 4 and 6).
5. The flap was replaced and Tenon's capsule and the conjunctiva were sutured separately using 7/0 silk (Figs 5 and 7).

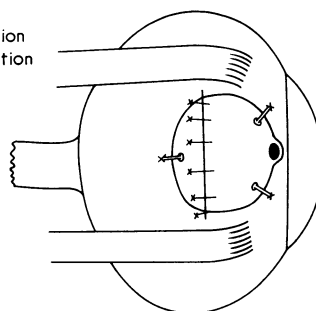
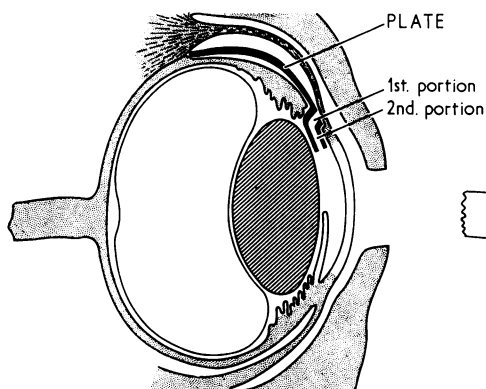
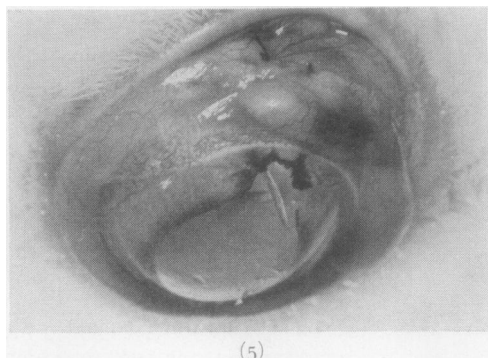
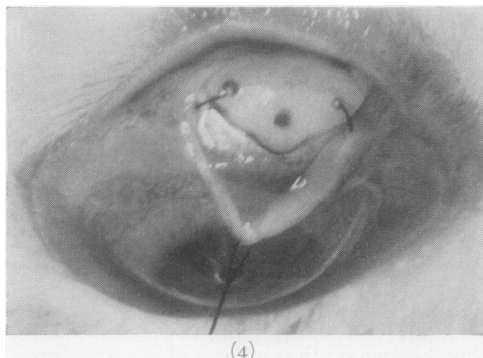


FIG. 6 Diagram showing section of implant in position

FIG. 7 Diagram showing implant sutured to conjunctiva and Tenon's capsule

Postoperative management and course

A steroid-antibiotic drop was given daily for 2 weeks after which it was discontinued. The eyes were examined by slit lamp at 3-weekly intervals throughout the experiment.

The postoperative course was remarkably smooth. Initially the conjunctiva was diffusely oedematous, but this gradually decreased until after 3 weeks only a bleb remained (Fig 8, opposite). This was thick-walled and moderately vascular and in all twelve cases could easily be distended by moderate pressure on the eye.

Complications encountered in the course of 45 operations

Shallow anterior chambers were never encountered. Postoperative sepsis did not occur except in the early cases when it followed extrusion of the implants. Hyphaema occurred in three cases, bleeding following the iridectomy. The blood appeared to drain into the subconjunctival space and in all cases had disappeared by the third day. A single case of uveitis occurred. Transient lens opacity was noted immediately postoperatively in one case. Sloughing of the conjunctiva occurred in four of the first six cases but was later avoided by careful asepsis, boiling the implants more thoroughly, and avoiding the use of vasoconstrictors in the local anaesthetic solutions.

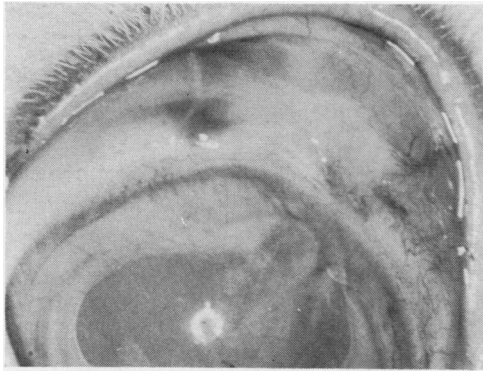

FIG. 8 *Bleb one year after operation*

Table I *Results in five normal and twelve operated eyes*

<i>Eyes</i>	<i>Normal</i>		<i>Operated</i>	
	<i>Schiötz</i>	<i>Applanation</i>	<i>Schiötz</i>	<i>Applanation</i>
No. of readings	35	10	75	16
Range	12-25	16-22	4-17	4-12
Mean	19	19.4	10.78	10.25
Average	19.1		10.67	

Table II *Cases in which tonography was carried out twice*

<i>Operated</i>			<i>Unoperated</i>		
<i>Rabbit No.</i>	<i>C. Value</i>	<i>Po/C</i>	<i>Rabbit No.</i>	<i>C. Value</i>	<i>Po/C</i>
42R	0.30 0.24	21.6 46.6	45L	0.22	60.9
48R	0.24 0.15	51.0 <28.0	48L	0.15 0.13	89.3 112.0
51L	0.23 >0.48	37.0 28.0	67L	0.48 0.22	27.9 75.5
68R	>0.45 0.33	28.0 28.0	68L	0.25	58.4
67R	>0.45 0.30	<23.0 16.3	83L	0.18 0.36	81.1 54.6
83R	0.28 0.35	25.4 45.3			
63L	>0.63 0.35	<38.7 54.0			
Average	>0.33	36.4	Average	0.22	62.1

Results

Measurements of intraocular pressure

Readings taken from twelve eyes having satisfactory implants were compared with readings from five normal unoperated eyes (Table I). Seven animals survived long enough for tonography to be carried out twice on each eye, after which the experiment was terminated (Table II); the remaining five died of natural causes before tonography could be done.

In order to detect any trend of intraocular pressure with time after operation, readings were grouped in 50- and 100-day periods, and an average was calculated for each period (Table III and Fig. 9). It is apparent that after the first 50 days the intraocular pressure remained almost constant.

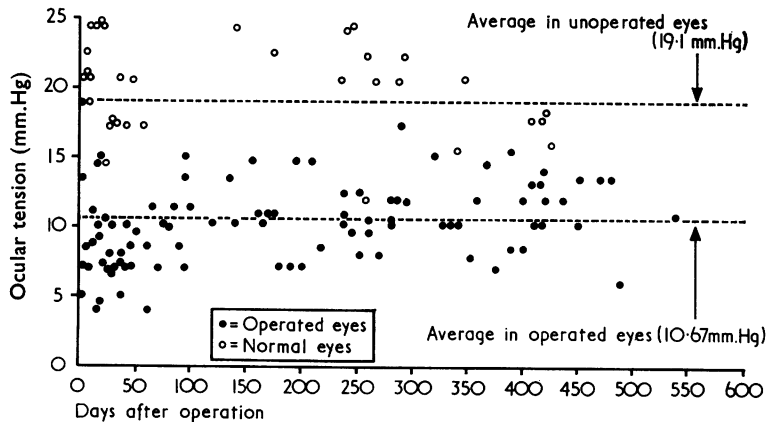


Table III *Average postoperative ocular tension*

No. of days postoperative	Average tension (mm. Hg)
0-50	9.0
51-100	10.5
101-200	11.5
201-300	11.75
301-400	11.5
401-500	11.25

FIG. 9 *Ocular tension in operated and unoperated eyes*

The readings of individual eyes were recorded graphically in order to separate eyes with very low tensions from the rest. However, no clear separation was possible, individual readings in most cases covering the full range.

The values found for coefficient of facility of outflow (C) and intraocular pressure in unoperated normal eyes fell within the range of previously reported values (Kornbluth and Linnér, 1955; Becker and Constant, 1956; Levene and Bloomgarden, 1961; Luntz, 1966).

In all twelve cases operated on, the intraocular pressure was markedly reduced. This fall in intraocular pressure was associated in six out of seven cases studied tonographically with a C value greater than 0.22.

Histology (see Figs 10A, B, opposite)

Histological evaluation of twelve eyes with implants revealed one eye with a subclinical iridocyclitis, which showed a mild inflammatory infiltrate consisting of plasma cells and lymphocytes.

In all twelve cases a well-formed bleb was found. The wall consisted of connective tissue with few blood vessels. In the bleb wall itself inflammatory infiltrate was evident only at points of movement between the implant and the surrounding tissues. The infiltrate consisted of plasma cells, lymphocytes, and occasional polymorphonuclear and eosinophil leucocytes.

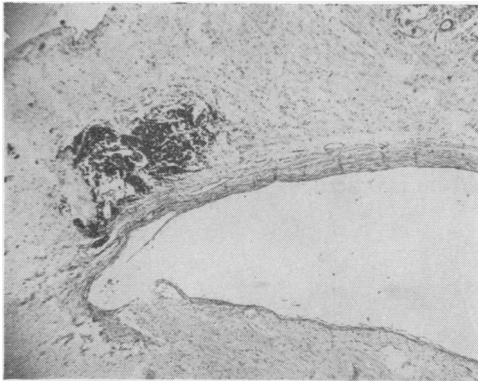


FIG. 10A *Histological section, showing sclera below, bleb cavity, bleb wall, and suture remnant. Haematoxylin and eosin. $\times 20$*

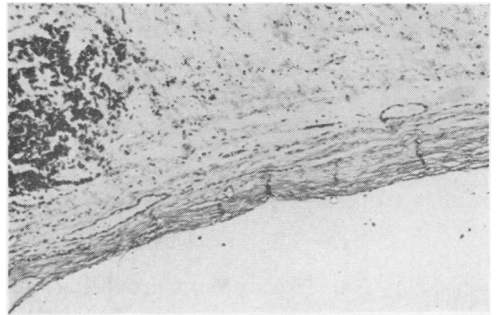


FIG. 10B *High-power view of bleb wall and suture remnant, showing absence of nuclei on inner half of bleb wall. $\times 100$*

Nine of the twelve blebs were lined by pale-staining fibrous tissue, and one bleb had a complete lining of endothelium identical to that covering Descemet's membrane. The other two were lined by scattered patches of epithelium which could have been derived from iris or ciliary body.

During the whole experiment only one severe uveitic reaction occurred. (Animals were examined by slit lamp every 3 weeks and on the day of killing.) This severe reaction occurred 2 weeks after insertion of an implant into one eye only. It was bilateral and granulomatous, formed dense posterior synechiae, and persisted undiminished for 4 weeks until the animal was killed. Histological examination revealed an intense iridocyclitis characterized by innumerable plasma cells containing Russell bodies and by numerous eosinophils. Nodules, epithelioid cells, and lymphocytes were not present and the choroid was completely spared.

This picture suggested an intense immune reaction but not a true sympathetic ophthalmitis. Only this one case of clinically manifest uveitis occurred in this series of 45 operations involving disturbances of the uvea and foreign body implantation within the eye.

Discussion

Fundamentally the implant described above maintains fistula and bleb in spite of fibrosis. In normal adult rabbit eyes the fibrous reaction to the operation, to aqueous fluid, and to the implant was mild, allowing free drainage associated with a marked fall in intraocular pressure.

The histological features of these eyes closely resembled those reported previously in human eyes after successful drainage procedures (Verhoeff, 1915; Holth, 1922, 1930, 1931; Teng, Chi, and Katzin, 1959).

The collagen fragmentation reported by Teng and others (1959) was not noticed in these blebs; in the fibrous tissue forming the bleb wall the inner half was paler than the outer half, while nuclei were fewer in the inner half, being almost absent in the older blebs.

The large area available for drainage probably diminished the intensity of any action exerted by the aqueous on the connective tissue.

The fact that these bleb walls consist of avascular relatively non-nucleated connective tissue suggests that in man it should be possible to insert a similar implant, wait until the

bleb wall has "matured", and then carefully remove the implant. If the incision into the bleb were then to be carefully sutured the patient would be left with a large translimbal fistula communicating with a thick-walled bleb. Both fistula and bleb would be lined by mature fibrous tissue which would be unlikely to contract any further. Such a fistula and bleb would be likely to function permanently while the complications from long-term retention of intraocular acrylic would be avoided.

Summary

1. The importance of bleb fibrosis in failure of fistulizing procedures is emphasized.
2. An implant providing both fistula and adequate bleb area is described.
3. An experiment to assess the long-term performance of the implant in rabbits is described.

I wish to thank Prof. M. H. Luntz for his help and encouragement at all times. The assistance of Miss Dawn Trupos and the Laboratory staff of the Department of Ophthalmology is acknowledged.

This work was supported by grants from the University of the Witwatersrand and the South African Council for Scientific and Industrial Research.

References

- BARSKY, D., and SCHIMEK, R. A. (1958) *A.M.A. Arch. Ophthalm.*, **60**, 1044
 BECKER, B., and CONSTANT, M. A. (1956) *Ibid.*, **55**, 305
 ELLIS, R. A. (1960) *Amer. J. Ophthalm.*, **50**, 733
 EPSTEIN, E. (1959) *Brit. J. Ophthalm.*, **43**, 641
 HOLTH, S. (1922) *Ibid.*, **6**, 10
 ——— (1930) *Arch. Ophthalm. (Chicago)*, **4**, 803
 ——— (1931) *Ibid.*, **6**, 151
 KORNBLUTH, W., and LINNÉR, E. (1955) *Ibid.*, **54**, 717
 LAVAL, J. (1955) *Ibid.*, **54**, 677
 LEVENE, R. Z., and BLOOMGARDEN, C. (1961) *Ibid.*, **66**, 273
 LUNTZ, M. H. (1966) *Amer. J. Ophthalm.*, **61**, 665
 MAYOU, S. (1912) *Trans. ophthalm. Soc. U.K.*, **32**, 234
 RICHARDS, R. D. (1955) *Eye, Ear, Nose Thr. Mthly*, **44**, No. 8, p. 54
 STANWORTH, A. (1958) *Trans. ophthalm. Soc. U.K.*, **78**, 43
 TENG, C. C., CHI, H. H., and KATZEN, H. M. (1959) *Amer. J. Ophthalm.*, **47**, 16
 TRIBIN-PIEDRAHITA, A. (1965) *Ibid.*, **60**, 140
 VERHOEFF, F. H. (1915) *Arch. Ophthalm. (N.Y.)*, **44**, 129
 ZORAB, A. (1912) *Trans. ophthalm. Soc. U.K.*, **32**, 217