

Classification of eccentric fixation

S. R. K. MALIK, A. K. GUPTA, AND S. CHOUDHRY

Department of Ophthalmology, Maulana Azad Medical College, New Delhi, India

The literature on eccentric fixation includes numerous systems of classification devised by different workers. At the orthoptic and pleoptic centre at this hospital, we have tried to use some of these classifications, but have observed certain discrepancies which are discussed below.

Some classifications are based on anatomical landmarks (Mayweg and Massie, 1958; von Noorden, 1959; Scully and Naylor, 1961; von Noorden and Lipsius, 1964) and others on the relationship of the fovea with the fixation target (Byron, 1960; Agarwal, Khosla, and Angra, 1964).

Table I (opposite) shows much disparity in nomenclature. The same degree of eccentric fixation has been differently described by different workers: *e.g.* 3° eccentric fixation was included under paramacular fixation by Byron (1960) but under parafoveal fixation by Agarwal and others (1964). Similarly, 5° eccentric fixation was termed "centrocaecal" by Byron (1960) and "paramacular" by Agarwal and others (1964).

Some classifications are incomplete:

- (a) The "divergent" type of fixation is described only by Agarwal and others (1964).
- (b) The "wandering or indefinite" type of fixation is not mentioned by Byron (1960), but von Noorden (1959) and von Noorden and Lipsius (1964) have included "wavering".
- (c) "Unsteady foveal fixation" is not mentioned by von Noorden (1959), Byron (1960), von Noorden and Lipsius (1964), and Agarwal and others (1964).

Urist (1961) used the position of the uniocular corneal reflex and the ophthalmoscopic streak to measure the degree of eccentric fixation, but others have used the projectoscope, the visuscope, or the fixation star incorporated in the ophthalmoscope.

Results of present investigations

In the investigation of cases of eccentric fixation in our clinic, we observed that the readings of the visuscope and the projectoscope fitted with the Linkz star (Fig. 1) did not correspond

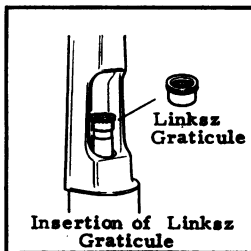


FIG. 1 *The Linkz graticule*

Table I *Systems of classification of eccentric fixation*

Authors	Date	Classification	
		Name	Description
Mayweg and Massie	1958	(1) Central	With nystagmus Without nystagmus
		(2) Eccentric	Parafoveal, around the fovea Paramacular, around the macula Peripheral, between the fovea and the disc, or nasal to the disc
		(3) Indefinite	No particular area takes up fixation
von Noorden	1959	(1) Central	Star appears on fovea
von Noorden and Lipsius	1964	(2) Parafoveal	Star appears around fovea but within the macular depression
		(3) Paramacular	Star appears in an area just outside or adjacent to the macula
		(4) Wavering	No preference for any non-foveal area The eye makes searching movements when the patient is asked to fix the star
Byron	1960	(1) Erratic	No definite area of fixation around the true fovea
		(2) Parafoveal	Star fixed by an area 2° from the fovea
		(3) Paramacular	Star fixed by an area 2 to 4° from the fovea
		(4) Centrocaecal	Star fixed by an area more than 4° from the fovea but not around the disc
		(5) Paracentral	Star fixed by area of retina around the disc
Scully and Naylor	1961	(1) Unsteady central	Star hovers over fovea and parafoveal area but is not steadily fixed on the fovea
		(2) Parafoveal	Star fixes steadily at side of fovea
		(3) Paracentral	Star fixes steadily at edge of macula
		(4) Eccentric	Star fixes steadily between fovea and disc, and may even rest on the disc or nasal to it
		(5) Wandering	Star wanders irregularly between fovea and disc
Urist	1961	(1) Centric macular	Corneal reflex normal; light reflex at one side of the fovea; visual acuity 20/200 or better
		(2) Uncertain	Corneal reflex at one side of normal position; light reflex 5 to 10° from macula; with effort transitory centric fixation may be achieved; visual acuity less than in (1)
		(3) Wandering	Corneal reflex changes with position of eye; light reflex moves over retina and occupies no constant position; amblyopia denser than in (2)
		(4) Eccentric	Corneal reflex far from normal position; light reflex fixed by an area far from the macula and may correspond to the degree of abnormal corneal reflex; amblyopia usually severe
Agarwal, Khosla, and Angra	1964	(1) Erratic	Unsteady central fixation just around fovea
		(2) Parafoveal	Within 3° of fovea
		(3) Paramacular	Between 3° and 6° from fovea
		(4) Centrocaecal	Between disc and macula
		(5) Paracaecal	Around disc and about 12° from fovea
		(6) Divergent	Beyond 6° on temporal side
		(7) Non-fixing	No preference for any non-foveal area

This author did not use the visuscope, but diagnosed eccentric fixation by the position of the uniocular corneal reflex when the other eye is occluded and by noting the relation of a streak of light projected over the retina by the ophthalmoscope and its relation to the fovea when the patient is asked to fix the centre of the streak.

with each other. It is our impression that the projectoscope with the star has certain advantages over the conventional visuscope. It permits better focusing and definition of the star, and better appreciation of fine movements in the foveal area. The latter is due to the clear area in the Linkz star, through which these fine foveal movements can be observed (Fig. 2). We, therefore, recommend the use of the Linkz star to measure the degree of eccentric fixation and suggest the following classification (Table II).

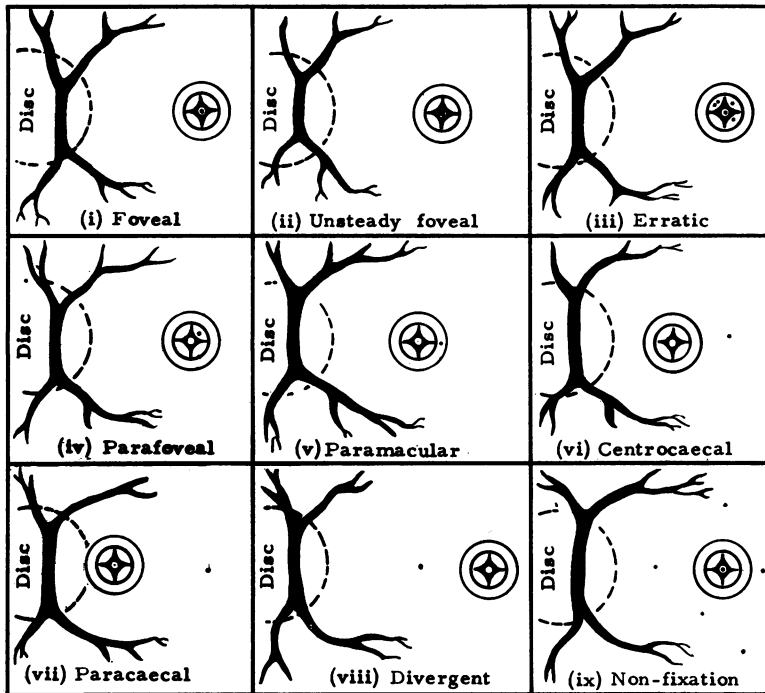


FIG. 2 *Nine types of fixation, as seen with the Linkz graticule superimposed on the retina through the projectoscope*

Table II *Proposed classification using the projectoscope with the Linkz star*

(1) Normal or foveal	The Linkz star is focused on the fovea
(2) Unsteady foveal	The fixation is foveal, but there are very fine movements of the fovea in the central clear area of the Linkz star (but never outside it)
(3) Erratic	Parafoveal fixation in which the fovea comes to the centre of the star momentarily and moves away again, but remains within 3°
(4) Parafoveal	The star is focused on the retina at a point outside the fovea but within 3°
(5) Paramacular	The star is focused on a retinal point 3 to 6° from fovea
(6) Centrocaecal	The star is focused on a retinal point between the disc and an area 6° from the fovea
(7) Paracaecal	The star is focused on a retinal point around or over the disc, usually about 12° from the fovea
(8) Divergent	The star is focused on a retinal point more than 6° away on the temporal side of the fovea
(9) Non-fixing	No definite point is focused, and the star is seen to move all over the retina

Summary

The previous confusion in nomenclature and standards in classifying different types of eccentric fixation has created difficulties in pleoptic studies, because the existing classifications are so diverse that widely different results have been reported by various workers according to the system used. Only an internationally accepted scheme of classification will allow the results of pleoptic treatment to be fairly assessed and compared. A new classification is suggested which covers all the clinical varieties of eccentric fixation, and may help to clarify the diagnosis of this condition in orthoptic clinics.

References

- AGARWAL, L., KHOSLA, P. K., and ANGRA, S. K. (1964) *Indian J. Orthopt. Pleopt.*, **1**, No. 1, p. 12
BYRON, H. M. (1960) *A.M.A. Arch. Ophthal.*, **63**, 675
MAYWEG, S., and MASSIE, H. H. (1958) *Brit. J. Ophthal.*, **42**, 257
NOORDEN, G. K. VON (1959) *Amer. J. Ophthal.*, **47**, 809
——— and LIPSUS, R. M. C. (1964) *Ibid.*, **58**, 41
SCULLY, J., and NAYLOR, E. J. (1961) *Brit. med. J.*, **2**, 81
URIST, M. J. (1961) *Amer. J. Ophthal.*, **52**, 19